

SAVE THE DATE
JAN. 16-19, 2017

LOEWS MIAMI BEACH HOTEL

MIAMI

WWW.PICSYMPOSIUM.COM



LIVE CASE DEMONSTRATIONS • ABSTRACT
SESSIONS • "MY NIGHTMARE CASE IN THE
CATH LAB" • HOT DEBATES • WORKSHOPS
• SMALLER BREAKOUT SESSIONS •

Editorial Board

Editor-in-Chief

Ziyad M. Hijazi Sidra Medical & Research Center
(Doha-qatar)

Co-Editor-in-Chief

Horst Sievert CardioVascular Center
Sankt Katharinen Hospital
(Frankfurt, Germany)

Assistant Editors

Damien Kenny Rush University Medical Center
(Chicago, IL)

Michael Kim University of Colorado
(Aurora, CO)

Editorial Board

Teiji Akagi Okayama University
(Okayama, Japan)

Bagrat Alekyan Bakoulev Scientific Center for
Cardiovascular Surgery
(Moscow, Russia)

Zahid Amin Children's Hospital of Georgia
(Augusta, GA)

Vasilis Babaliaros Emory University
(Atlanta, GA)

Steven Bailey University of Texas, San Antonio
(San Antonio, TX)

Lee Benson Hospital for Sick Kids
(Toronto, Canada)

Lisa Bergersen Boston Children's Hospital
(Boston, MA)

Younes Boudjemline Hospital Necker
(Paris, France)

Elchanan Bruckheimer Schneider's Children's
Medical Center
(Petach Tikva, Israel)

Maurice Buckbinder Stanford University
(Palo Alto, CA)

Massimo Caputo Rush University Medical Center
(Chicago, IL)

Mario Carminati San Donato Milanese
(Milan, Italy)

John Carroll University of Colorado Denver
(Aurora, CO)

John P. Cheatham Ohio State University
(Columbus, OH)

Jae Young Choi Severance Cardiovascular Hospital
(Seoul, Korea)

Antonio Colombo St. Rafaele Hospital
(Milan, Italy)

Costantino Costantini Hospital Cardiológico Costantini
(Curitiba, Brazil)

Alain Cribier Charles Nicolle Hospital
(Rouen, France)

Associate Editors

Clifford J. Kavinsky Rush University Medical Center
(Chicago, IL)

Bray Patrick Lake PFO Research Foundation
(Boulder, CO)

John Messenger University of Colorado
(Aurora, CO)

Managing Editor

Hussam Suradi Rush University Medical Center
(Chicago, IL)

Roberto Cubeddu Aventura Hospital
(Miami, FL)

Bharat Dalvi Glenmark Cardiac Centre
(Mumbai, India) Jo De Giovanni
Birmingham Children's Hospital

(Birmingham, United Kingdom)

Helene Eltchanninof University Hospital
(Rouen, France)

Maiy El Syed Ain Shams Univesity
(Cairo, Egypt)

Thomas Fagan University of Colorado
(Denver, CO)

Ted Feldman Evanston Northshore Hospital
(Evanston, IL)

Olaf Franzen University Heart Center Hamburg
(Hamburg, Germany)

Yun Ching Fu Taichung Veterans General Hospital
(Taichung, Taiwan)

David Gao Shanghai Children's Medical Center
(Shanghai, China)

Eulogio Garcia Hospital Clinico San Carlos
(Madrid, Spain)

Marc Gewillig University of Lueven
(Lueven, Belgium)

Matt Gillespie Children's Hospital of Philadelphia
(Philadelphia, PA)

Omer Goktekin BezmiAlem Vakif University
(Istanbul, Turkey)

Steven Goldberg University of Washington
(Seattle, WA)

William Gray Columbia University
(New York, NY)

Eberhard Grube Heart Center Siegburg
(Siegburg, Germany)

Rebecca Hahn Columbia University Medical Center
(New York, NY)

Jeff Harrisberg Pediatric Cardiology
(Gauteng, South Africa)

William E. Hellenbrand	Yale University (New Haven, CT)		Washington University (St. Louis, MO)
James Hermiller	The Care Group (Indianapolis, IN)	Martin B. Leon	Columbia University (New York, NY)
Howard Herrmann	University of Pennsylvania (Philadelphia, PA)	Daniel Levi	UCLA Medical Center (Los Angeles, CA)
David Holmes	Mayo Clinic (Rochester, MN)	Scott Lim	University of Virginia Health System (Charlottesville, VA)
Noa Holoshitz	Rush University Medical Center (Chicago, IL)	Michael Mack	Baylor Healthcare System (Plano, TX)
Ralf Holzer	Sidra Medical & Research Center (Doha, Qatar)	Francesco Maisano	University of Zurich (Zurich, Switzerland)
Eric Horlick	University of Toronto (Toronto, Canada)	Raj Makkar	Cedars Sinai Medical Center (Los Angeles, CA)
Reda Ibrahim	Montreal Heart Institute (Montreal, Canada)	Robert March	Rush University Medical Center (Chicago, IL)
Michel Ilbawi	Rush University Medical Center (Chicago, IL)	Gwen Mayes	VP National Patient Advocate Foundation (Washington, DC)
Frank Ing	LA Children's Hospital (Los Angeles, CA)	Pat McCarthy	Northwestern Memorial Hospital (Chicago, IL)
Alexander Javois	Hope Children's Hospital (Oak Lawn, IL)	Doff McElhinney	New York University (New York, NY)
Thomas Jones	Seattle Children's Hospital (Seattle, WA)	John Messenger	University of Colorado (Denver, CO)
Saibal Kar	Cedars Sinai Medical Center (Los Angeles, CA)	Friedrich Mohr	Herzzentrum Universitaet Leipzig (Leipzig, Germany)
Clifford Kavinsky	Rush University Medical Center (Chicago, IL)	Tarek Momenah	Prince Salman Cardiac Center (Riyadh, Saudi Arabia)
Joseph Kay	University of Colorado (Denver, CO)	Issam Moussa	(Jacksonville, FL)
Damien Kenny	Rush University Medical Center (Chicago, IL)	Michael Mullen	The Heart Hospital (London, England)
Morton Kern	University of California Irvine (Irvine, CA)	David Muller	St. Vincent's Hospital (Sydney, Australia)
Michael Kim	University of Colorado (Aurora, CO)	William O'Neill	Henry Ford Hospital (Detroit, MI)
Seong-Ho Kim	Cheju Halla General Hospital (South Korea)	Igor Palacios	Mass General Hospital (Boston, MA)
Susheel Kodali	Columbia University Medical Center (New York, NY)	SJ Park	University of Ulsan College of Medicine (Seoul, Korea)
Jackie Kreutzer	Pittsburgh Children's Hospital (Pittsburgh, PA)	Carlos Pedra	Danta Pazzanese Instituto de Cardiologia (Sao Paulo, Brazil)
Shelby Kutty	Children's Hospital and University of Nebraska Medical Center (Omaha, NB)	Alejandro Peirone	Children's Hospital of Cordoba (Cordoba, Argentina)
Bray Patrick-Lake	PFO Research Foundation (Boulder, CO)	Giacomo Pongiglione	Bambino Gesu Hospital (Rome, Italy)
Michael Landzberg	Boston Children's Hospital (Boston, MA)	Matthew Price	Scripps Clinic (La Jolla, CA)
Geoffrey Lane	Royal Melbourne Hospital (Melbourne, Australia)	Robert Quaife	University of Colorado (Denver, CO)
Roberto Lang	University of Chicago Medical Center (Chicago, IL)	Shakeel Qureshi	Evelina Children's Hospital (London, UK)
John Lasala	Barnes Jewish Hospital,		

Steve Ramee	Oschner Clinic (New Orleans, LA)	Corrado Tamborino	University of Catania (Catania, Italy)
Mark Reisman	Swedish Medical Center (Seattle, WA)	Vinod Thourani	Emory University (Atlanta, GA)
John Rhodes	Miami Children's Hospital (Miami, FL)	Jonathan Tobis	UCLA Medical Center (Los Angeles, CA)
Charanjit Rihal	Mayo Clinic (Rochester, MN)	Murat Tuczu	Cleveland Clinic Foundation (Cleveland, OH)
Richard Ringel	Johns Hopkins Medical Center (Baltimore, MD)	Zoltan Turi	Robert Wood Johnson Medical School (Camden, NJ)
Carlos Ruiz	Lenox Hill Hospital (New York, NY)	Alec Vahanian	Bichat University Hospital (Paris, France)
Ernesto Salcedo	University of Colorado (Denver, CO)	Joseph J. Vettukattil	Spectrum Health (Grand Rapids, MI)
Joachim Schofer	Hamburg University Cardiovascular Center (Hamburg, Germany)	Kevin Walsh	Our Lady's Hospital (Dublin, Ireland)
Paul Sorajja	Minneapolis Heart Institute Foundation (Minneapolis, MN)	John Webb	St. Paul Hospital Vancouver (British Columbia, Canada)
Christian Spies	Queen's Heart Physician Practice (Honolulu, HI)	Brian Whisenant	Intermountain Medical Center (Salt Lake City, Utah)
Frank Silvestry	University of Pennsylvania Hospital (Philadelphia, PA)	Matthew Williams	Mount Sinai Medical Center (New York, NY)
Gregg Stone	Columbia University (New York, NY)	Neil Wilson	University of Colorado (Denver, CO)
		Evan Zahn	Cedars Sinai Medical Center (Los Angeles, CA)

ORIGINAL RESEARCH ARTICLES

91 Percutaneous Balloon Angioplasty for Aortic Coarctation in Newborns and Infants: Is It Still an Option?

Shehla Jadoon, Milad El-Segaier, Mohammed Omar Galal

98 Periventricular and Percutaneous Closure of Traumatic Ventricular Septal Defects Following Blunt Chest Trauma

Karim A. Diab, Kamel Shibbani, John Nigro, Stephen Pophal, Ernerio T. Alboliras

102 Resolution of Migraine After Transcatheter Closure of Atrial Communication: Migraine and Atrial Communication Closure

Yoichi Takaya, Teiji Akagi, Yasufumi Kijima, Koji Nakagawa, Syoichiro Kono, Kentaro Deguchi, Shunji Sano, Hiroshi Ito

STATE-OF-THE-ART REVIEW

108 Use of Intracardiac Echocardiography for Congenital and Structural Heart Disease Interventions

Mike Saji, D. Scott Lim

MEETING ABSTRACTS

118 CSI 2016 Frankfurt, Germany Scientific Abstracts

Ziyad M. Hijazi

Journal of Structural Heart Disease (ISSN 2325-4637) is an online open-access journal issued bi-monthly (6 issues per year, one volume per year) by Science International Corporation.

All correspondence should be directed to: Ziyad M. Hijazi, MD, Editor-in-Chief, Journal of Structural Heart Disease, PO Box 26999, Doha, Qatar. Tel.: +974-4003-6601, E-Mail: jshd@scienceinternational.org

All inquiries regarding copyrighted material from this publication should be directed to Science International Corporation: 70 Forest Street, Suite 6-C, Stamford, CT, 06901, USA. Tel.: +1-203-329-8842, Fax: +1-203-329-8846, E-Mail: skorn@scienceinternational.org

Percutaneous Balloon Angioplasty for Aortic Coarctation in Newborns and Infants: Is It Still an Option?

Shehla Jadoon, MRCPCH¹, Milad El-Segaier, MD, PhD^{1,2}, Mohammed Omar Galal, MD, PhD, MBA^{3,4*}

¹ Department of Pediatric Cardiology, King Fahad Medical City, King Salman Heart Center, Riyadh, Saudi Arabia

² Department of Pediatric Cardiology, Skåne University Hospital, Lund, Sweden

³ Department of Pediatric Cardiology, Essen University, Essen, Germany

⁴ Department of Pediatric Cardiology, King Faisal Specialist Hospital and Research Center, Jeddah, Saudi Arabia

Abstract

Background: Coarctation of aorta may present as severe heart failure in infants and may lead to myocardial dysfunction. Current evidence supports surgical management of neonatal coarctation; however, it can be precarious in sick infants. Thus, percutaneous balloon angioplasty may be a beneficial alternative palliation before possible surgical treatment.

Methods: To investigate the safety, efficacy, immediate, and mid-term outcome of percutaneous balloon angioplasty for aortic coarctation in infants who present late and have additional risk factors for surgical treatment, a retrospective case series was examined, reviewing the charts of all patients under six months of age who underwent balloon angioplasty for aortic coarctation.

Results: Between January 2008 and April 2014, 14 infants with coarctation were included. Their mean weight was 3.5 kg (1.9–5 kg) and they had a mean age of 69 days (4–142 days). All patients were sick, needed admission in an intensive care unit for inotropic and/or ventilator support, and had different additional risk factors for surgery. All underwent successful percutaneous balloon angioplasty with minor complications. Following which their clinical condition and left ventricular function improved leading to weaning from inotropes and ventilator support. On further follow up, seven underwent elective surgical repair, two needed re-dilation, and three continued without any further intervention.

Conclusions: Surgical repair for native neonatal and infantile coarctation is a preferred choice of treatment, but it can be challenging in sick patients with additional risk factors. However, percutaneous balloon angioplasty remains a safe and effective temporary palliation. Despite a high incidence of restenosis, some patients do not need mid-term further intervention.

Copyright © 2016 Science International Corp.

Key Words

Neonates • Infants • Balloon dilation • Aortic coarctation • Percutaneous balloon angioplasty

Introduction

Coarctation of aorta (CoA) accounts for 5–7% of all congenital heart diseases [1, 2]. Native CoA in infancy may present with symptoms of congestive heart failure, low cardiac output, and/or shock. Since introduction, four decades ago, the role of percutaneous balloon angioplasty in this age group remains controversial [3–5].

It is accepted that surgical repair is the preferred treatment for neonatal and infancy CoA. One of the most important arguments being that percutaneous balloon angioplasty in the first months of life has an extremely high re-stenosis rate [6, 7].



In certain circumstances, such as low body weight, critical patient condition with severe myocardial dysfunction and/or other organ failure, surgical repair is not preferable [8-10]. Additional risk factors like late presentation or other systemic disease may influence treatment option decisions. Under these conditions, whilst acknowledging that percutaneous balloon angioplasty is associated with high re-stenosis rate and possible aneurysm formation [5, 11, 12], it is argued that it can provide short to midterm solutions for stabilization of patients allowing surgical repair to be performed later with less risks.

The aim of this study was to present our experience with balloon angioplasty in neonates and infants with aortic coarctation who were referred late to us and/or had confounding risk factors precluding surgical treatment. Additionally, we were evaluating the immediate and mid-term outcome of this procedure in our patient population.

Methods

A retrospective cohort study was performed between January 2008 and April 2014. Fourteen neonates and infants (age less than 6 months) who underwent balloon angioplasty for aortic coarctation were identified and included in the study. All patients were admitted in an intensive care unit either due to need of respiratory support or poor cardiac output state. Additionally, they had different confounding factors which might have increased their risk of surgical treatment. Ethical clearance and permission to publish the related clinical information was obtained from the hospitals institutional review board (IRB).

Inclusion Criteria

All patients less than 6 months of age who presented with hemodynamic instability (low cardiac output) and/or any additional risk factors which may have increased their risk of surgery were included. The additional risk factors which were considered were: Late referral combined with no improvement to medical therapy, low body weight, long ventilator support, chronic lung disease, and serious systemic disease.

Exclusion Criteria

Patients less than 6 months of age, who showed stable hemodynamics with good cardiac output and no additional risk factors for surgical treatment. These patients were sent electively to surgery.

Patients underwent clinical and complete echocardiography evaluation before and after the percutaneous balloon an-

gioplasty and at follow up. The following echocardiographic factors were evaluated: Doppler gradient across the segment of coarctation, existence of diastolic run off, patency of arterial duct, right and left ventricular cardiac function and diameters, any associated cardiac lesion, aortic arch dimensions (proximal arch, transverse arch between first branch and left common carotid artery, and distal arch between left common carotid and subclavian arteries, narrowest segment), associated mitral valve involvement, and any left ventricular outflow obstruction.

Procedure Details

Percutaneous balloon angioplasty was performed in all patients. During procedure patients received heparin boluses to keep activated clotting time (ACT) more than 200 seconds. After establishing an arterial access with a 4-Fr sheath in the majority of patients (more recently a 3-Fr sheath had been utilized in two patients), a pigtail catheter (Medtronic, Minneapolis, Minnesota, USA) was advanced into the descending and ascending aorta. The pressures across the isthmus were measured. The aortogram in lateral and antero-posterior projection was performed. The transverse arch, the isthmus distal to the left subclavian artery and narrowest diameter were measured. Percutaneous transluminal coronary angioplasty (PTCA) balloon of different sizes and lengths were used for intervention in most cases (Medtronic, Minneapolis, Minnesota, USA). Balloon size was chosen according to aortic size immediately above the stenosis and was one mm smaller than this diameter. The balloon was usually inflated three-four times across the narrowest region. Pressures after the procedure were obtained, making sure not to cross the dilated region a second time with the wire. Repeat aortogram was performed to document the angiographic results of the intervention. To avoid aortic wall injury, the pigtail catheter used for angiogram was advanced and withdrawn over a wire through the dilated segment.

Results

In 14 patients (3 female, 11 male), their mean weight was 3.5 kg (1.9–5 kg) and their mean age was 69 days (4–142 days) (Table 1).

Risk Factors for Surgical Treatment

Risk factors for surgical treatment for each patient are presented in Table 2. Many patients showed no improvement despite medical therapy including inotropes and prostaglandin E₁ (PGE₁). Another risk factor was low body weight especially for those born premature where we had to delay the intervention whilst awaiting their growth. Additionally some patients were referred late, some were on ventilation

Table 1: Demographic and clinical data of patients.

Age (days)	Gender	Weight (kg)	Urine output (ml/kg/hr)		PGE ₁ before	Ventilator mode	Duration of respiratory support before PBA	Inotropes support
			before	after				
62	M	3.5	1.2	4.8	N	MV	58	N
20	M	4	1.7	3.4	Y	None	N	N
132	F	3.4	1.5	3.1	N	MV	91	N
12	F	2.4	0.6	2.3	N	MV	12	Y
4	F	1.9	2.1	3.1	Y	CPAP	2	N
124	M	4.3	1.1	1.4	N	MV	5	Y
142	M	5	1.3	2.9	N	MV	62	N
64	M	4	0.9	2.8	N	Oxygen via NC	3	Y
24	M	3.7	2.7	3.6	Y	None	N	N
65	M	4.5	0.8	2.5	N	MV	22	Y
94	M	3.1	1.3	3.2	N	MV	53	N
103	M	4.5	2.1	2.7	N	Oxygen via NC	6	N
46	M	2.1	2.7	4.3	Y	Oxygen via NC	4	N
82	M	2.7	2.1	3.3	Y	Oxygen via NC	3	N

PGE₁ = prostaglandin E₁; M = male; F = female; N = none; Y = yes; MV = mechanical ventilation; CPAP = continuous positive airway pressure; NC = nasal cannula; PBA = percutaneous balloon angioplasty.

for a long time and some had chronic or systemic disease.

Associated Cardiac Lesions

Associated cardiac lesions and echocardiographic findings at presentation for each patient are presented in [Table 2](#). Two thirds of the patients had moderate to severe right ventricular dilatation. Half of the patients had patent arterial duct, and few had hypoplasia of arch. One third of patients had large significant ventricular septal defects. Other associated cardiac lesions were double orifice mitral valve in one patient and severe aortic valve stenosis in another

Immediate Outcome after Balloon Dilatation

Mean fluoroscopy time was 15.3 minutes (range 2–62 min), and procedure time (skin-to-skin) was 72 minutes (range 34–174 min). Two patients needed transfusion due to blood loss during procedure. Four patients had cold leg with absent pulses and were treat-

ed with heparin infusion for 48 hours which resulted in an improvement (these were not the infants who were cannulated with a 3-Fr sheath). The mean gradient across the coarctation dropped from 37 (range 6–90 mm Hg) to 14 mm Hg (range 0–40 mm Hg). The drop was of clinical relevance and statistically significant ($p < 0.0024$, 95% confidence interval 9.02–37.41). Detailed catheterization data are presented in [Table 3](#).

Hospital Course until Discharge

All patients were weaned off ventilation or oxygen supplement within 72 hours after intervention, except two who continued to need support for six days. Before the procedure, four patients required inotrope support and five patients were on prostaglandin. Prostaglandin was stopped in all five patients within 48 hours of intervention. Two patients needed inotropes for a longer period of time (more than 48 hours) and ventilator support due to sepsis (*Pseudomonas aeruginosa* and *Staphylococcus* in blood culture).

Table 2: indication criteria for ballooning and echocardiography finding of all patients at presentation.

Associated cardiac lesions	Risk factors for surgical treatment	Presence of PDA	RV dilatation (function)	Aorta dimensions			
				AA	TA	DA	Isthmus
Discrete coarctation	Prolonged ventilation	Moderate	Severe (good)	7.2	6.6	4.6	2.9
Discrete coarctation, moderate ASD, large apical VSD	No response to medical therapy, large apical VSD	None	Mild (good)	7.5	7.1	3.1	2.7
Discrete coarctation, double orifice MV, subaortic membrane	Late referral, SCD, prolonged ventilation (130 days), CLD	Large	Normal, RVH (good)	10	6.6	4.3	2.0
Long segment coarctation, large unrestrictive inlet membranous VSD, mitral stenosis	Post-surgical arch reconstruction, poor myocardial function	Tiny	Mild, RVH (good)	6.4	2.5	2.4	2.1
Discrete coarctation, ASD secundum, large VSD	Low body weight associated with arch hypoplasia	Large	Mild (good)	5.7	3.1	2.3	1.4
Discrete coarctation	RSV infection, poor myocardial function, no improvement with medical therapy	None	Normal (good)	10	5	3.2	1.2
Discrete coarctation, moderate ASD	Late referral, CLD, dysmorphism, severe pharyngeal dysphagia.	Small	Moderate (good)	7	6	4.8	2.6
Discrete coarctation	Low cardiac output despite medical therapy	None	Mild (good)	7.8	5.6	6	1.8
Discrete coarctation	Poor myocardial function, no response to medical therapy	None	Mild, RVH (good)	10	3.7	4.3	2.2
Tight coarctation, bicuspid AoV with stenosis, ASD secundum	Prolonged ventilation, severe AoV stenosis, poor myocardial function despite prolong inotropes, (underwent dilatation for AoV, CoA)	None	Normal (good)	7.3	3.3	3.0	1.7
Long segment coarctation, large VSD	Extreme preterm, low birth weight (1.4 kg), Down's syndrome	Large	Normal (good)	5.8	3.2	2.3	1.7
Discrete coarctation	Late referral, pulmonary hypertension	Large	Severe (good)	5.1	3.6	3.5	1.8
Discrete coarctation, mild arch hypoplasia, ASD, bicuspid aortic valve	Premature, low body weight 1.7 kg. No response to PGE ₁	None	Normal (good)	6.5	2.9	2.5	1.8
Discrete coarctation	No response to medical therapy	None	Normal (good)	7.4	4.8	3.2	1.2

ASD = atrial septal defect; VSD = ventricular septal defect; PDA = patent ductus arteriosus; RV = right ventricle; RVH = right ventricular hypertrophy; AoV = aortic valve; AA = ascending aorta; TA = transverse arch; D = descending aorta; SCD = sickle cell disease; CLD = chronic lung disease; RSV = respiratory syncytial virus; PGE₁ = prostaglandin E₁.

The clinical status improved in all patients. Echocardiographic assessment showed improvement in cardiac function. Mean urine output before intervention of all patients was 1.6 ml/kg/hour (0.6–2.7) which improved to 3.1 ml/kg/hour (1.4–4.8 ml/

kg/hour) after dilatation. This improvement was statistically significant ($p < 0.0001$, 95% confidence interval -2.1 to -0.93). Detailed results are presented in [Table 1](#).

Table 3: Catheterization data with outcome.

PGB	PGA	Gradient drop	Transfusion	Heparin	Follow up
65	22	43	None	None	Surgical repair
10	10	No change in gradient	None	None	Surgical repair
47	28	19	None	None	Surgical repair
40	40	No change in gradient	None	Needed for 48 hrs.	Surgical repair
28	13	15	None	None	Surgical repair
55	15	40	None	Needed for 24 hrs.	Redilation
40	12	28	Needed	Needed for 48 hrs.	Lost
22	0	22	None	None	Redilation
48	20	28	None	None	Surgical repair
10	6	4	None	None	No recoarctaion
30	0	30	Needed	None	Surgical repair
6	0	6	None	None	Lost
30	10	20	None	Needed for 48 hrs.	No recoarctaion
90	20	70	None	None	No recoarctaion

PGB = pressure gradient before the percutaneous balloon angioplasty; PGA = pressure gradient after the percutaneous balloon angioplasty.

Follow Up and Further Management

The mean follow up time was 25 months (range 15–58 months). One month survival was 100%, two year survival was 86% (two deaths, both not related to intervention). One patient died after 6 weeks of intervention due to *P. aeruginosa* and staphylococcal sepsis. The other died 13 months after intervention due to sickle cell crisis. Seven patients needed surgical repair due to recoarctation within a mean time of 12 weeks of intervention. Two patients needed redilation within 12 months of intervention. Three patients did not require any further intervention (follow up time: 15–31 months).

Discussion

The current paper presents the effectiveness of percutaneous balloon angioplasty in 14 patients with infantile aortic coarctation. All patients were considered for balloon angioplasty due to their multiple risk factors (Table 2) although surgical repair is the gold standard for this age group [13]. After percutaneous balloon angioplasty all infants showed significant clinical and hemodynamic improvement. No mortal-

ity was recorded in relation to the procedure. However, as reported in other studies, the restenosis rate was high. These results confirm previous reports that demonstrate that percutaneous balloon angioplasty is effective for stabilizing patients and, in some cases, improving survival [8, 14].

Successful percutaneous balloon angioplasty for neonatal aortic coarctation was reported in the early eighties [3]. It was initially described to be effective in neonates with discrete coarctation and good clinical condition [15, 16]. In the successive years, different authors have concluded that there is a prohibitive high incidence of recoarctation, especially in neonates [6, 7, 17]. Therefore, the role of angioplasty in this age group remained controversial [17]. Surgery remains the preferred choice for neonates and young infants, due to lower restenosis and aneurysmal rate as compared to percutaneous balloon angioplasty [18]. However morbidity as well as mortality has been reported to be higher in infants with poor preoperative clinical status, low cardiac output, associated cardiac lesions including long segment arch hypoplasia, additional systemic disease, and low body weight [19-22].

The dilemma arises when confronted with sick infants and those with associated general risk fac-

tor, as found in our series. In these cases, probably percutaneous balloon angioplasty is an effective and temporary alternative to surgery in order to minimize the operative risk and prepare them for safer final management [8, 14]. Other authors have proven the efficacy and safety of this treatment option in this category of infants [8, 14, 23]. Interestingly 35% of our patients did not require further surgical management.

At the time of intervention, our patients were relatively old (mean age 69 days). The main contributory reasons for this were prematurity (two patients), low birth weight (three patients), and late referral (seven patients). The patients with low birth weight needed time to achieve an acceptable weight in order to perform balloon angioplasty. Late referrals were those born in small rural hospitals where, unfortunately, there were fewer facilities and less experienced primary health care providers.

PGE₁ infusion is the primary medical management for stabilizing sick neonates with aortic coarctation [24-26]. This treatment option was not suitable for our patients as some referred late and some did not respond favorably to PGE₁.

Limitations of the Study

The authors acknowledge that the major limitations of this study are its retrospective nature as well as the relatively small number of patients. On the other hand, this category of patients is rare and hence a prospective study will take considerable time. It would have been interesting to compare our population to a control group of infants with similar clinical

presentation undergoing surgical repair. Our treatment option and the previous similar reports confirm safety and efficacy of this management. Thus, such a prospective study would be unethical.

Conclusions

Percutaneous balloon angioplasty of aortic coarctation is safe and effective for neonates and infants with low body weight and hemodynamic instability. The procedure is not only helpful for stabilization of the extremely ill patients but also provides a bridging for them until future surgical repair. It should be considered as an emergent palliative procedure in this particular group of patients where other treatment alternatives are more risky.

Acknowledgements

We acknowledge Ms. Penelope Swift BSN, RM, RGN, RSCN, nurse manager, Comprehensive Cancer Centre, King Fahad Medical City. Ms. Swift is a native English speaker who assisted us with language editing and correction.

Conflict of Interest

The authors have no conflicts of interest relevant to this publication.

[Comment on this Article or Ask a Question](#)

References

- Nadas AS, Fyler DC. Pediatric Cardiology, 3rd Edition. Philadelphia: Saunders; 1972.
- Keith JD, Rowe RD, Vlad P. Heart Disease in Infancy and Childhood, 3rd Edition. New York: Macmillan Publishers Limited; 1978.
- Lababidi Z. Neonatal transluminal balloon coarctation angioplasty. Am Heart J. 1983;106:752-753. DOI: [10.1016/0002-8703\(83\)90098-4](https://doi.org/10.1016/0002-8703(83)90098-4)
- Cowley CG, Orsmond GS, Feola P, McQuillan L, Shaddy RE. Longterm, randomized comparison of balloon angioplasty and surgery for native coarctation of the aorta in childhood. Circulation. 2005;111:3453-3456. DOI: [10.1161/CIRCULATIONAHA.104.510198](https://doi.org/10.1161/CIRCULATIONAHA.104.510198)
- Hernández-González M, Solorio S, Conde-Carmona I, Rangel-Abundis A, Ledesma M, Munayer J, et al. Intraluminal aortoplasty vs. surgical aortic resection in congenital aortic coarctation. A clinical random study in pediatric patients. Arch Med Res. 2003;34:305-310. DOI: [10.1016/S0188-4409\(03\)00055-9](https://doi.org/10.1016/S0188-4409(03)00055-9)
- Galal MO, Schmaltz AA, Joufan M, Benson L, Samatou L, Halees Z. Balloon dilation of native aortic coarctation in infancy. Z Kardiol. 2003;92:735-741. DOI: [10.1007/s00392-003-0956-x](https://doi.org/10.1007/s00392-003-0956-x)
- Redington AN, Booth P, Shore DF, Rigby ML. Primary balloon dilation of coarctation of the aorta in neonates. Br Heart J. 1990;64:277-281. DOI: [10.1136/hrt.64.4.277](https://doi.org/10.1136/hrt.64.4.277)
- Doshi AR, Rao PS. Coarctation of aorta: management options and decision making. Pediatr Therapeut. 2012;5(6):1-10. DOI: [10.4172/2161-0665.s5-006](https://doi.org/10.4172/2161-0665.s5-006)
- Salahuddin N, Wilson AD, Rao PS. An unusual presentation of coarctation of the aorta in infancy: role of balloon angioplasty in the critically ill infant. Am Heart J. 1991;122:1772-1775. DOI: [10.1016/0002-8703\(91\)90300-7](https://doi.org/10.1016/0002-8703(91)90300-7)

10. Rao PS. Current status of balloon angioplasty for neonatal and infant aortic coarctation. *Progress Pediatr Cardiol.* 2001;14:35-44. DOI: [10.1016/S1058-9813\(01\)00114-X](https://doi.org/10.1016/S1058-9813(01)00114-X)
11. Marvin WJ, Mahoney LT, Rose EF. Pathologic sequelae of balloon dilation angioplasty of unoperated coarctation of the aorta in children. *J Am Coll Cardiol.* 1986;7:117A.
12. Cooper RS, Ritter SB, Rothe WB, Chen CK, Griep R, Golinko RJ. Angioplasty for coarctation of the aorta: long-term results. *Circulation.* 1987;75:600-604. DOI: [10.1161/01.CIR.75.3.600](https://doi.org/10.1161/01.CIR.75.3.600)
13. Crafoord C, Nylin G. Congenital coarctation of the aorta and its surgical treatment. *J Thorac Surg.* 1945;14:347.
14. Bouzguenda I, Marini D, Ou P, Boudjemline Y, Bonnet D, Agnoletti G. Percutaneous treatment of neonatal aortic coarctation presenting with severe left ventricular dysfunction as a bridge to surgery. *Cardiol Young.* 2009;19:244-251. DOI: [10.1017/S1047951109003837](https://doi.org/10.1017/S1047951109003837)
15. Rao PS, Galal O, Smith PA, Wilson AD. Five- to nine-year follow-up results of balloon angioplasty of native aortic coarctation in infants and children. *J Am Coll Cardiol.* 1996;27:462-470. DOI: [10.1016/0735-1097\(95\)00479-3](https://doi.org/10.1016/0735-1097(95)00479-3)
16. Patel HT, Madani A, Paris YM, Warner KG, Hijazi ZM. Balloon angioplasty of native coarctation of the aorta in infants and neonates: is it worth the hassle? *Pediatr Cardiol.* 2001;22:53-57. DOI: [10.1007/s002460010153](https://doi.org/10.1007/s002460010153)
17. Park Y, Lucas VW, Sklansky MS, Kashani IA, Rothman A. Balloon angioplasty of native aortic coarctation in infants 3 months of age and younger. *Am Heart J.* 1997;34:917-923. DOI: [10.1016/S0002-8703\(97\)80015-4](https://doi.org/10.1016/S0002-8703(97)80015-4)
18. Fiore AC, Fischer LK, Schwartz T, Jureidini S, Balfour I, Carpenter D, et al. Comparison of angioplasty and surgery for neonatal aortic coarctation. *Ann Thorac Surg.* 2005;80:1659-1664. DOI: [10.1016/j.athoracsur.2005.03.143](https://doi.org/10.1016/j.athoracsur.2005.03.143)
19. Chang AC, Hanley FL, Lock JE, Castañeda AR, Wessel DL. Management and outcome of low birth weight neonates with congenital heart disease. *J Pediatr.* 1994;124:461-466. DOI: [10.1016/S0022-3476\(94\)70376-0](https://doi.org/10.1016/S0022-3476(94)70376-0)
20. Rossi AF, Seiden HS, Sadeghi AM, Nguyen KH, Quitana CS, Gross RP, et al. The outcome of cardiac operations in infants weighing two kilograms or less. *J Thorac Cardiovasc Surg.* 1998;116:28-35. DOI: [10.1016/S0022-5223\(98\)70239-9](https://doi.org/10.1016/S0022-5223(98)70239-9)
21. Bacha EA, Almodovar M, Wessel DL. Surgery for coarctation of the aorta in infants weighing less than 2 kg. *Ann Thorac Surg.* 2001;71:1260-1264. DOI: [10.1016/S0003-4975\(00\)02664-3](https://doi.org/10.1016/S0003-4975(00)02664-3)
22. Quaegebeur JM, Jonas RA, Weinberg AD, Blackstone EH, Kirklin JW. Outcomes in seriously ill neonates with coarctation of the aorta: a multi-institutional study. *J Thorac Cardiovasc Surg.* 1994;108:841-854.
23. Francis E, Gayathri S, Vaidyanathan B, Kannan BR, Kumar RK. Emergency balloon dilation or stenting of critical coarctation of the aorta in newborns and infants: an effective interim palliation. *Ann Pediatr Cardiol.* 2009;2:111-115. DOI: [10.4103/0974-2069.58311](https://doi.org/10.4103/0974-2069.58311)
24. Sidi D, Duval-Arnould M, Kachaner J, Villain E, Pedroni E, Piéchaud JF. Treatment by prostaglandin E1 of isolated coarctations in newborn infants with acute cardiac failure. *Arch Fr Pediatr.* 1987;44(1):21-25.
25. Cheliakine-Chamboux C, Chantepie A, Godde F, Vaillant MC, Saliba E, Gold F, et al. Effects of PGE1 in neonatal aortic coarctation. *Thérapie.* 1991;46(3):231-233.
26. Liberman L, Gersony WM, Flynn PA, Lamberti JJ, Cooper RS, Stare TJ. Effectiveness of prostaglandin E1 in relieving obstruction in coarctation of the aorta without opening the ductus arteriosus. *Pediatr Cardiol.* 2004;25(1):49-52. DOI: [10.1007/s00246-003-0549-5](https://doi.org/10.1007/s00246-003-0549-5)

Cite this article as: Jadoon S, Segaiar, ME, Galal, MO. Percutaneous Balloon Angioplasty for Aortic Coarctation in Newborns and Infants. *Structural Heart Disease.* 2016;2(4):91-97. DOI: <http://dx.doi.org/10.12945/j.jshd.2016.005.15>

Periventricular and Percutaneous Closure of Traumatic Ventricular Septal Defects Following Blunt Chest Trauma

Karim A. Diab, MD, FACC^{1*}, Kamel Shibbani, MD², John Nigro, MD³, Stephen Pophal, MD³, Ernerio T. Alboliras, MD, FACC⁴

¹ Department of Pediatric Cardiology, Rush University Medical Center, Chicago, Illinois, USA

² Lieber Institute for Brain Development, Johns Hopkins University, Baltimore, Maryland, USA

³ Department of Pediatric Cardiology, Phoenix Children's Hospital, Phoenix, Arizona, USA

⁴ Department of Pediatric Cardiology, Banner Children's Hospital, Mesa, Arizona, USA

Abstract

Traumatic ventricular septal defects (VSDs) are very rare and can result from either penetrating or blunt chest trauma. They can lead to significant hemodynamic changes and heart failure and can be challenging to manage. We present two patients with muscular VSDs resulting from nonpenetrating trauma to the chest in whom Amplatzer Muscular VSD Occluders were successfully used for defect closure via percutaneous and periventricular approaches.

Copyright © 2016 Science International Corp.

Key Words

Traumatic ventricular septal defect • Percutaneous closure • Periventricular closure • Blunt chest trauma • Post-infarct Amplatzer VSD occluder

Introduction

Blunt trauma to the chest usually results from high-speed motor vehicle accidents and can cause significant cardiac injury including ventricular septal defects (VSDs) [1]. These defects can be asymptomatic but

can also result in life-threatening hemodynamic effects. This report describes two cases of traumatic VSDs resulting from blunt chest trauma that were successfully managed by percutaneous and periventricular device closure.

Case Series

First Case

A 19-year-old male involved in an automobile collision was admitted to the intensive care unit in shock with hypotension and pneumothorax. After resuscitation, he continued to have significant pulmonary edema and elevated troponin I at 27.99 ng/mL. An electrocardiogram (ECG) showed sinus rhythm with ST elevation in the inferior leads. An echocardiogram revealed an apical muscular VSD measuring 6–8 mm with left-to-right shunting, a transventricular pressure gradient of 55 mm Hg, mild mitral regurgitation, normal systolic function biventricularly, and no effusions (Figure 1).

Cardiac MRI showed an VSD and a focal area of thinning of the mid left lateral ventricular septal wall. Cardiac catheterization revealed a Qp:Qs of 2:1 with a



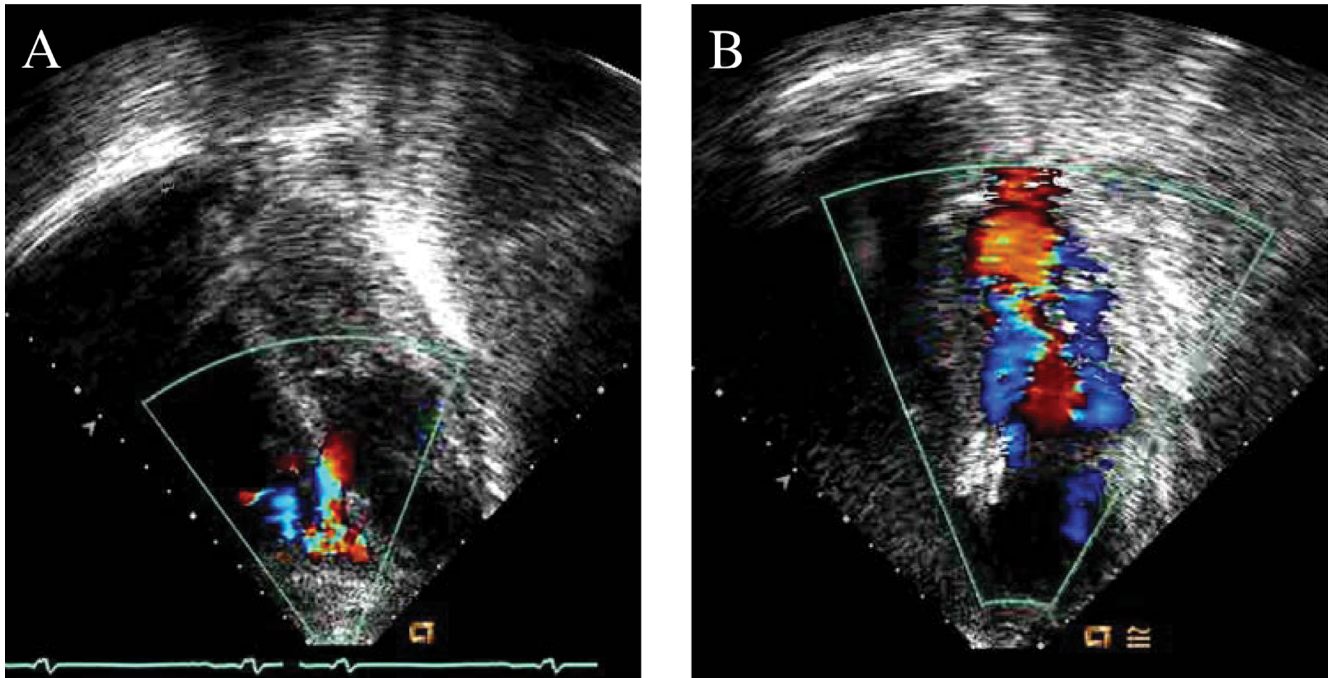


Figure 1. (Panels A, B). Transthoracic echocardiogram views before (Panel A) and after (Panel B) closure of the defect showing a posterior-apical muscular ventricular septal defect (VSD) that was successfully closed with a 12 mm Amplatzer muscular VSD device.

right ventricular (RV) pressure of 42/7 mm Hg, pulmonary artery pressure of 41/17 mm Hg, and normal pulmonary vasculature resistance. Transesophageal echocardiogram (TEE) showed a posterior-apical muscular VSD measuring 10 mm with left-to-right shunting. Angiography demonstrated a significant VSD measuring about 8 mm at its narrowest point. After the VSD was crossed and an arteriovenous loop was established, a 12 mm Amplatzer muscular VSD device (AGA/St. Jude Medical Corporation, St. Paul, MN) was successfully deployed that left only minimal residual shunting seen on TEE. The patient did well post-closure and was extubated and eventually discharged home. A follow-up echocardiogram 1.5 years later revealed a tiny residual shunt.

Second Case

A 31-year-old male involved in a motorcycle accident was hospitalized in a severe state of shock due to large hemothorax, tamponade, abdominal compartment syndrome, and multiple skeletal fractures. He underwent emergent exploratory laparotomy, thoracotomy, and pericardiectomy. Postoperatively,

he continued to require ventilatory support and subsequently developed pulmonary embolism. ECG revealed sinus tachycardia and incomplete right bundle branch block. An echocardiogram revealed an avulsed tricuspid valve with severe regurgitation, as well as a large apical muscular VSD measuring about 18 mm in diameter, mild pulmonary hypertension, and normal left ventricular (LV) systolic function. Cardiac catheterization showed a Qp:Qs of 2.4:1. As the patient required repair of the tricuspid valve and VSD closure, he was taken to the operating room for periventricular hybrid closure of the VSD followed by tricuspid valve repair.

After median sternotomy, TEE-guided needle puncture through the lower inferior RV surface created access for insertion of a delivery sheath and subsequent closure of the defect with an 18 mm Amplatzer Postinfarct Muscular VSD Occluder (Figure 2).

The device was deployed, and TEE showed only a small residual shunt. This was followed by tricuspid valve repair on cardiopulmonary bypass using an anuloplasty band. The patient was discharged from the hospital 4 days after VSD closure. A follow-up

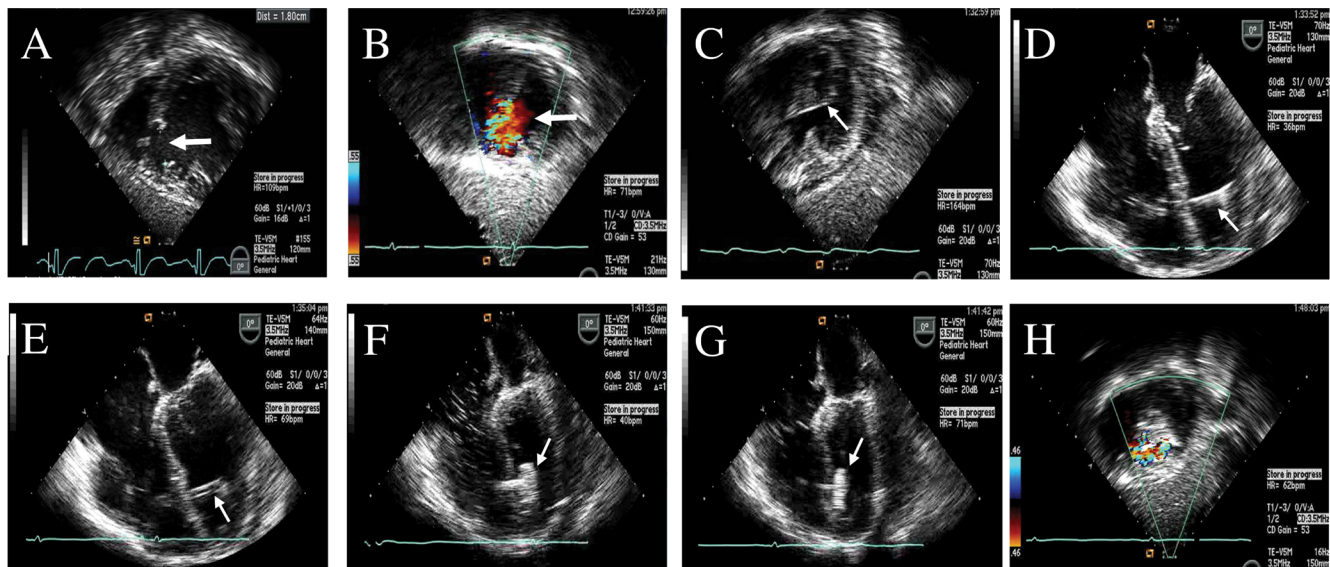


Figure 2. TEE images during hybrid or periventricular device closure of a traumatic muscular ventricular septal defect (VSD). (Panels A, B). Transesophageal echocardiogram (TEE) images without and with color Doppler demonstrating the defect in the muscular septum (arrows). (Panels C, D). TEE images during passage of the guide wire (arrow) across the VSD and into the left ventricle (LV) following needle puncture of the right ventricular free wall. (Panels E). Passage of the delivery sheath into the LV cavity (arrow). (Panels F). Deployment of the LV disk of the 18 mm Amplatzer Postinfarct Muscular VSD Occluder (arrow) in the LV cavity and then (Panels G), aligned to the ventricular septum (arrow). (Panels H). Image taken after device release demonstrating good device position with the right and left disks in their respective position and a small residual shunt.

echocardiogram after 6 months showed a small residual VSD and mild tricuspid regurgitation, absence of pulmonary hypertension, and normal global ventricular systolic function.

Discussion

An acute onset left-to-right cardiac shunt after a blunt chest trauma results mostly from acquired VSD [1-6]. These traumatic VSDs most commonly involve the muscular portion of the septum, particularly the apical portion due to its thin structure [1, 3-7]. The mechanisms include anteroposterior compression of the heart between the sternum and spine secondary to high intrathoracic pressures at impact and myocardial infarction from rapid deceleration causing coronary damage [1, 3]. Trauma can result in damage to the valves or rupture of the septum that can occur immediately or be delayed for several days [4].

Patients with traumatic VSDs can be asymptomatic or present with fulminant acute cardiogenic shock. Elevated troponin levels or ST-segment elevation

with no wall-motion abnormalities should increase our suspicion for traumatic VSD after blunt trauma to the chest, as was the case in our first patient.

Traumatic VSD management depends on the size of the defect, the degree of shunting, and the presence of heart failure [8]. A conservative approach is usually recommended for asymptomatic small traumatic VSDs as these defects might close spontaneously [1, 8]. On the other hand, indications to close these defects include Qp:Qs >2:1, hemodynamic instability, the presence of pulmonary hypertension, and left-sided chamber dilatation. Closure can be accomplished either surgically through a right ventriculotomy or using a percutaneous approach [5, 7, 8]. In patients with a low left-to-right shunt and mild heart failure, medical treatment can be attempted first for 2 to 3 weeks followed by repair once the myocardial tissue surrounding the VSD shows signs of fibrous ring formation [3, 6]. Device closure can then be performed using either the percutaneous or hybrid/periventricular approach. The latter was helpful in our case as the patient also

required tricuspid valve repair. The use of device closure in this case was also helpful as closure of apical muscular VSDs can be surgically challenging.

Different devices have been used for traumatic VSD closure depending on the defect size and configuration. ASD occluder devices have been associated with hemolysis because of their wire mesh configuration and cloth barrier not being designed for the high-pressure ventricular system [5]. Hence, it is preferable to use the postinfarct Amplatzer VSD Occluder for large traumatic VSDs, as was the case in our second patient.

In conclusion, cardiac injury, particularly valvular rupture and VSDs, should always be considered in all cases of trauma to the chest whether penetrating or

blunt. Percutaneous device closure of these defects is effective and can help avoid surgical repair in these high-risk patients. Hybrid or periventricular closure is an alternative to percutaneous closure in those who need additional intracardiac repair of associated lesions.

Conflict of Interest

The authors have no conflict of interest relevant to this publication.

[Comment on this Article or Ask a Question](#)

References

1. Genoni M, Jenni R, Turina M. Traumatic ventricular septal defect. *Heart*. 1997;78:316-318. DOI: [10.1136/hrt.78.3.316](https://doi.org/10.1136/hrt.78.3.316)
2. Pruitt CM, Titus MO. Ventricular septal defect secondary to a unique mechanism of blunt trauma: a case report. *Pediatr Emerg Care*. 2007;23:31-32. DOI: [10.1097/PEC.0b013e31802c61c3](https://doi.org/10.1097/PEC.0b013e31802c61c3)
3. Muyskens S, Lasala J, Balzer D. Percutaneous closure of a complex posttraumatic muscular ventricular septal defect. *Catheter Cardiovasc Interv*. 2008;72:408-412. DOI: [10.1002/ccd.21659](https://doi.org/10.1002/ccd.21659)
4. Kadner A, Fasnacht M, Kretschmar O, Prêtre R. Traumatic free wall and ventricular septal rupture – ‘hybrid’ management in a child. *Eur J Cardiothorac Surg*. 2007;31:949-951. DOI: [10.1016/j.ejcts.2007.01.068](https://doi.org/10.1016/j.ejcts.2007.01.068)
5. Suh WM, Kern MJ. Transcatheter closure of a traumatic VSD in an adult requiring an ASD occluder device. *Catheter Cardiovasc Interv*. 2009;74:1120-1125. DOI: [10.1002/ccd.22141](https://doi.org/10.1002/ccd.22141)
6. Terui G, Kaneko K, Miura M, Kawazoe K. Ventricular septal defect secondary to non-penetrating chest trauma. *Jpn Circ J*. 1997;61:951-953. DOI: [10.1253/jcj.61.951](https://doi.org/10.1253/jcj.61.951)
7. Jeon K, Lim WH, Kang SH, Cho I, Kim KH, Kim HK, et al. Delayed diagnosis of traumatic ventricular septal defect in penetrating chest injury: small evidence on echocardiography makes big difference. *J Cardiovasc Ultrasound*. 2010;18:28-30. DOI: [10.4250/jcu.2010.18.1.28](https://doi.org/10.4250/jcu.2010.18.1.28)
8. Pesenti-Rossi D, Godart F, Dubar A, Rey C. Transcatheter closure of traumatic ventricular septal defect: an alternative to surgery. *Chest*. 2003;123:2144-2145. DOI: [10.1378/chest.123.6.2144](https://doi.org/10.1378/chest.123.6.2144)

Cite this article as: Diab KA, Shibbani K, Nigro J, Pophal S, Alboliras ET. Periventricular and Percutaneous Closure of Traumatic Ventricular Septal Defects Following Blunt Chest Trauma. *Structural Heart Disease*. 2016;2(4):98-101. DOI: <http://dx.doi.org/10.12945/j.jshd.2015.007.15>

Resolution of Migraine After Transcatheter Closure of Atrial Communication

Migraine and Atrial Communication Closure

Yoichi Takaya, MD¹, Teiji Akagi, MD^{2*}, Yasufumi Kijima, MD¹, Koji Nakagawa, MD¹, Syoichiro Kono, MD³, Kentaro Deguchi, MD³, Shunji Sano, MD⁴, Hiroshi Ito, MD¹

¹ Department of Cardiovascular Medicine, Okayama University Graduate School of Medicine, Dentistry, and Pharmaceutical Science, Okayama, Japan

² Cardiac Intensive Care Unit, Okayama University Graduate School of Medicine, Dentistry, and Pharmaceutical Science, Okayama, Japan

³ Department of Neurology, Okayama University Graduate School of Medicine, Dentistry, and Pharmaceutical Science, Okayama, Japan

⁴ Department of Cardiovascular Surgery, Okayama University Graduate School of Medicine, Dentistry, and Pharmaceutical Science, Okayama, Japan

Abstract

Background: Limited information is available regarding migraine in patients with atrial septal defect (ASD), and the clinical effects of transcatheter closure are controversial. We aimed to demonstrate the clinical features of migraine in patients with ASD compared with those in patients with patent foramen ovale (PFO) and evaluate the impact of transcatheter closure.

Methods: We investigated the prevalence of migraine in 68 patients with ASD and 27 patients with PFO who underwent transcatheter closure. Migraine prevalence, frequency, and severity were evaluated before and after the procedure.

Results: Twenty patients (29%) with ASD and 15 patients (56%) with PFO suffered from migraine. Characteristics such as migraine frequency and severity and incidence of aura were not different between the ASD and PFO patients. Among the 20 ASD patients, migraine disappeared in 10 (50%) and improved in 7 (35%) patients after a mean follow-up of 20 ± 8 months. Among the 15 PFO patients, migraine disappeared in 11 (73%) and improved in 3 (20%) patients.

Conclusions: Approximately 30% of patients with ASD experience migraine. The improvement in migraine

after transcatheter closure is observed in the majority of those with ASD, similar to the rate of patients with PFO with improvement. These findings suggest that transcatheter closure may be beneficial for migraine in patients with atrial communication.

Copyright © 2016 Science International Corp.

Key Words

Atrial septal defect • Migraine • Patent foramen ovale • Transcatheter closure

Introduction

Migraine is a common, recurrent, and potentially disabling headache. The prevalence of migraine in the overall population is 10–12%, 6% in males and 15–18% in females [1]. Although the pathophysiology of migraine is not fully understood, a causal relationship between migraine and right-to-left communication has been proposed. In particular, patent foramen ovale (PFO) has been associated with an increase in the prevalence of migraine [2-4]. Transcatheter PFO



closure seems to be associated with the improvements in migraine prevalence and severity [2, 3, 5-7].

Atrial septal defect (ASD) is characterized by a predominant left-to-right communication, but the occurrence of right-to-left communication is detected during a Valsalva maneuver or exercise [8]. Therefore, some patients with ASD may suffer from migraine, and transcatheter closure may contribute to migraine improvement. However, limited information is available regarding migraine in patients with ASD [9-11]. This study aimed to evaluate the prevalence of migraine and the effect of transcatheter closure on migraine in patients with ASD, compared with those in patients with PFO.

Methods

Study Population

We investigated 68 consecutive patients with ASD who underwent transcatheter closure between December 2012 and November 2014; specifically, we assessed the prevalence rates of migraine before and after the procedure. Twenty-seven consecutive patients with PFO who underwent transcatheter closure for the secondary prevention of cerebral ischemia between March 2007 and November 2014 were also included. Transcatheter ASD closure was performed for a significant left-to-right communication and/or clinical symptoms of heart failure or cerebral ischemia. All patients gave written informed consent for the procedure. The study was approved by our institution's ethical committee.

Echocardiographic Assessment

Atrial communication was diagnosed by transesophageal echocardiography. For PFO detection, agitated saline contrast injection (aerated saline solution) was administered via the antecubital vein with and without the Valsalva maneuver. PFO was defined as a flap-like opening in the atrial septum secundum, with the septum primum serving as a one-way valve allowing for permanent or transient right-to-left communication. PFO diameter was obtained by measuring the maximum opening of the PFO in the end-diastolic frames. Atrial septal aneurysm was defined as an aneurysm with a base diameter ≥ 15 mm and an excursion of the septum ≥ 10 mm [12].

Transcatheter Closure of Atrial Communication

Transcatheter closure of atrial communication was performed as described previously under the guidance of transesophageal echocardiography and/or intracardiac echocardiography [13, 14]. The Amplatzer Septal Occluder, Amplatzer Cribriform, and Amplatzer PFO Occluder (St. Jude Medical, St. Paul, MN, USA) were used. All patients received

100 mg/day aspirin 48 h before the procedure, which was continued for 6 months after the procedure. Clopidogrel was administered at a dose of 75 mg/day for 1 month after the procedure.

Migraine Evaluation

Migraine was diagnosed by independent neurologists according to the criteria of the International Headache Society [15]. Migraine prevalence, frequency, severity, and medications were evaluated at baseline, 3 months, and >6 months after the procedure. Severity was estimated according to three-grade scale: none-mild (not interfering with usual activity), moderate (interfering with usual activity), or severe (confined to bed). Follow-up comprised a combined cardiologic and neurologic visit or a telephone interview. Postprocedural changes in migraine were classified into four groups according to migraine frequency and severity of migraines: disappeared (complete disappearance), improved ($\geq 50\%$ decrease in frequency and ≥ 1 -grade decrease in severity), no change ($<50\%$ change in frequency or no change in severity), or worsening ($\geq 50\%$ increase in frequency and ≥ 1 -grade increase in severity).

Statistical Analysis

Data are presented as mean \pm standard deviation for continuous variables and as number and percentage for categorical variables. Significant differences between two groups were analyzed using the *t* test or Mann-Whitney *U* test for continuous variables and the χ^2 test for categorical variables. Differences between baseline and follow-up in each group were analyzed by the paired *t* test and Wilcoxon signed-rank test. Statistical analysis was performed with JMP version 8.0 (SAS Institute Inc., Cary, NC, USA), and significance was defined as $p < 0.05$.

Results

Characteristics

Characteristics in patients with ASD and PFO are shown in Table 1. Patients with ASD were older than those with PFO. The frequency of atrial septal aneurysm was higher in patients with PFO than those with ASD. There were no significant differences in comorbidities between the two groups except for cerebral ischemia. Transcatheter closure of ASD or PFO was successfully performed in all patients without procedural complications. Among the patients with ASD, the Amplatzer Septal Occluder was used in 66 patients and the Amplatzer Cribriform in 2 patients. Among the patients with PFO, the Amplatzer PFO Occluder,

Cribriform, and Septal Occluder were used in 10, 5, and 12 patients, respectively.

Migraine Prevalence

Twenty (29%) of 68 patients with ASD suffered from migraine, including 12 patients with migraine with aura. Fifteen (56%) of 27 patients with PFO suffered from migraine, including 8 patients with migraine with aura. The prevalence of migraine was lower in

patients with ASD than in those with PFO (Table 1). Migraine characteristics such as the frequency, severity, incidence of aura, and the need for medications were not different between the 20 patients with ASD and the 15 patients with PFO (Table 2).

Short-Term Effect of Transcatheter Closure on Migraine

Among the 20 patients with ASD, migraine had disappeared in 10 (50%) patients and improved in 8 (40%) patients 3 months after the procedure. Among the 15 patients with PFO, migraine disappeared in 9 (60%) patients and improved in 5 (33%) patients (Figure 1).

Mid-Term Effect of Transcatheter Closure on Migraine

Among the 20 patients with ASD, migraine disappeared in 9 (45%) patients and improved in 7 (35%) patients at a mean follow-up of 20 ± 8 months after the procedure. Among the 15 patients with PFO, migraine disappeared in 11 (73%) patients and improved in 3 (20%) patients at a mean follow-up of 44 ± 29 months (Figure 2). No patients with ASD or PFO experienced worsening of migraine after the procedure. New-onset migraine was not observed in patients without migraine.

The frequency of migraine decreased significantly at the last follow-up in patients with ASD (2.8 ± 3.3 to 0.6 ± 0.8 times/month, $p = 0.008$) and

Table 1: Characteristics in patients with ASD and PSO

	ASD (n = 68)	PFO (n = 27)	p
Age at procedure, years	51 ± 19	43 ± 12	0.034
Female	41 (60%)	15 (56%)	0.676
Hypertension	16 (24%)	6 (22%)	0.893
Dyslipidemia	16 (24%)	3 (11%)	0.176
Diabetes mellitus	6 (9%)	1 (4%)	0.394
Smoking	6 (9%)	1 (4%)	0.394
Cerebral ischemia	11 (16%)	27 (100%)	<0.001
Defect diameter, mm	18 ± 8	3 ± 2	<0.001
Atrial septal aneurysm	11 (16%)	10 (37%)	0.027
Eustachian valve	7 (10%)	5 (19%)	0.281
Migraine	20 (29%)	15 (56%)	0.017

Data are presented as mean ± standard deviation or n (%).
ASD = atrial septal defect; PFO = patent foramen ovale.

Table 2: Migraine in patients with ASD and PFO

	ASD with Migraine (n = 20)	PFO with Migraine (n = 15)	p
Age at migraine onset, years	23 ± 12	24 ± 11	0.786
Frequency of migraine, times/month	2.8 ± 3.3	4.1 ± 4.7	0.324
Severity of migraine			
None-mild (not interfering with usual activity)	8 (40%)	3 (20%)	0.219
Moderate (interfering with usual activity)	10 (50%)	9 (60%)	0.570
Severe (confined to bed)	2 (10%)	3 (20%)	0.418
Incidence of aura	12 (60%)	8 (53%)	0.704
Migraine medications	12 (60%)	8 (53%)	0.704

Data are presented as mean ± standard deviation or n (%).
ASD = atrial septal defect; PFO = patent foramen ovale.

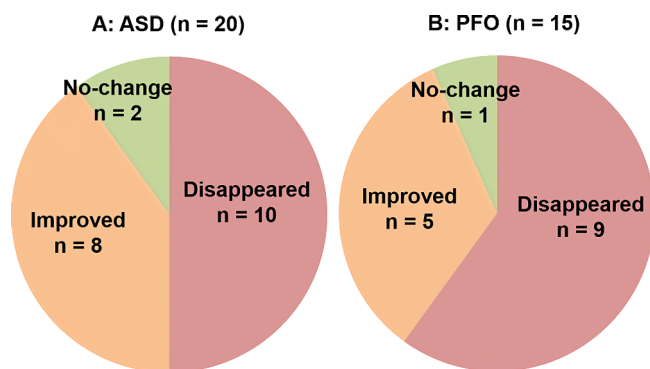


Figure 1. Short-term effect of transcatheter closure on migraine in patients with ASD (Panel A) and PFO (Panel B). ASD = atrial septal defect; PFO = patent foramen ovale.

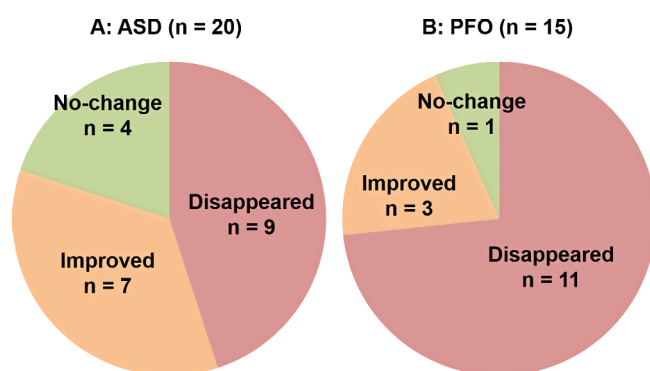


Figure 2. Mid-term effect of transcatheter closure on migraine in patients with ASD (Panel A) and PFO (Panel B). ASD = atrial septal defect; PFO = patent foramen ovale.

those with PFO (4.1 ± 4.7 to 0.2 ± 0.6 times/month, $p = 0.004$) (Figure 3). Migraine severity decreased at last follow-up in 11 (92%) of 12 patients with ASD and 11 (92%) of 12 patients with PFO who had moderate or severe migraine at baseline (Figure 4). Among those who used medications for migraine at baseline, they were not required in 8 (67%) of the 12 patients with ASD and 7 (88%) of the 8 patients with PFO.

Discussion

The major findings of the present study are as follows: 1) the prevalence of migraine was lower in patients with ASD than those with PFO but still affected approximately 30% of ASD patients; 2) migraine characteristics were similar in the ASD

and PFO groups; and 3) improvement in migraine after transcatheter closure was observed in the majority of patients with ASD, similar to those with PFO.

Although the pathophysiology of migraine is unclear, the presence of PFO is thought to be a potent trigger of migraine. Normally, trigger substances in the venous circulation will be filtered in the lungs. However, PFO may allow vasoactive chemicals or microemboli to bypass the lungs through right-to-left communication and reach the cerebral circulation, leading to migraine [16, 17]. This hypothesis is enforced by improvements in migraine prevalence and severity after PFO closure [2, 3, 5-7]. In contrast with PFO, ASD is mainly characterized by a left-to-right communication. However, during a Valsalva maneuver or exercise, a right-to-left communication can be detected with contrast echocardiography in patients with ASD [8]. Because this communication permits bypass of the lung filter, ASD may be also associated with migraine; however, little is known about migraine in this population [9-11, 18].

In the present study, the prevalence of migraine was lower in patients with ASD compared to those with PFO, but approximately 30% experienced migraine. This improved after transcatheter closure in 16 (80%) of the 20 patients with ASD, including 9 patients with complete disappearance. The benefit of transcatheter closure on migraine was similar in patients with ASD and PFO. Our findings suggest that ASD is associated with migraine and that transcatheter closure may be beneficial for migraine in patients with atrial communication.

There are some limitations in the present study. First, we included a small number of patients, and the follow-up period was short. Larger trials are required to confirm our findings. Second, we did not include a control group. Migraine is known to have a placebo response rate of 20–30%. However, the improvement rate of migraine in the present study was higher than the accepted placebo response rate [19]. Third, antiplatelet therapy might modify migraine prevalence, frequency, and severity [20]. However, aspirin was administered for 6 months and clopidogrel for 1 month. The improvement in migraine was eval-

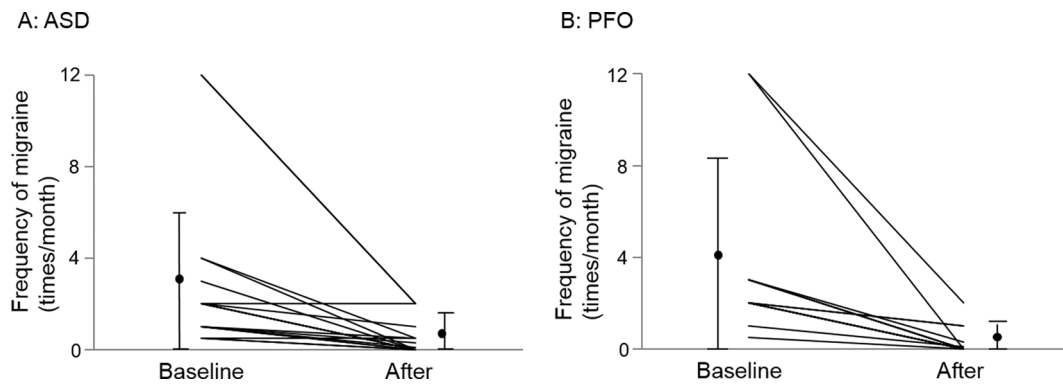


Figure 3. Changes in migraine frequency after transcatheter closure in patients with ASD (Panel A) and PFO (Panel B). $p = 0.008$ and 0.004 , respectively. ASD = atrial septal defect; PFO = patent foramen ovale.

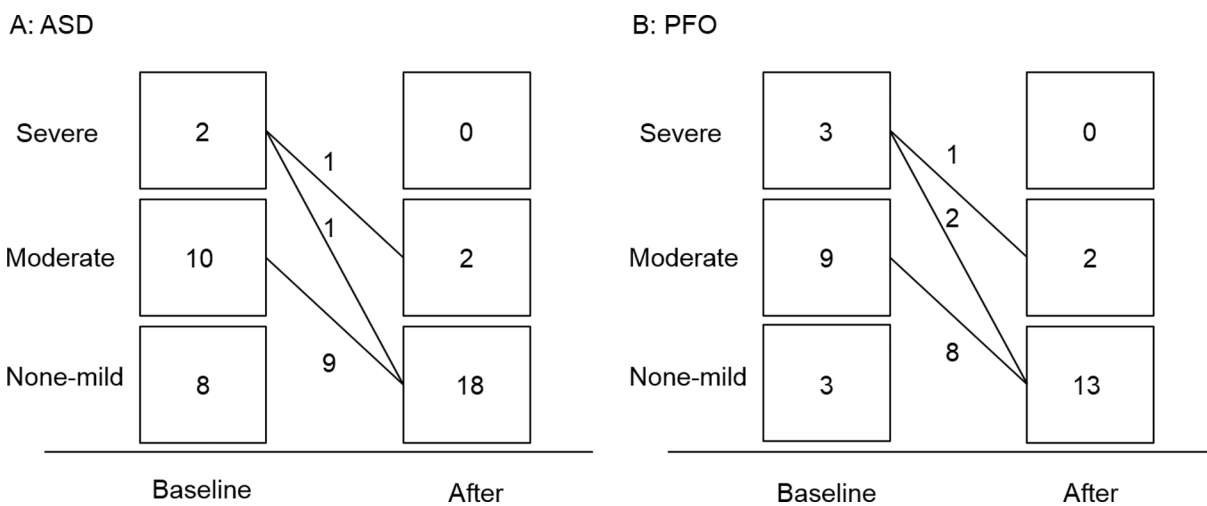


Figure 4. Changes in migraine severity after transcatheter closure in patients with ASD (Panel A) and PFO (Panel B). ASD = atrial septal defect; PFO = patent foramen ovale.

uated when these medications were not given. Fourth, the timing of transcatheter closure and the follow-up period differed between the ASD and PFO group. Finally, there was a selection bias as we only included patients who underwent transcatheter closure.

Conclusions

Approximately 30% of patients with ASD experience migraine, the characteristics of which are similar in ASD and PFO. An improvement in headache after transcatheter closure was observed in the majority of patients with ASD, similar to those with PFO. These findings suggest that PFO and ASD are both associ-

ated with migraine, and transcatheter closure may be beneficial for migraine in patients with atrial communication.

Conflict of Interest

Dr. Akagi is a consultant for St. Jude Medical, Inc. The other authors have no conflict of interest relevant to this publication.

[Comment on this Article or Ask a Question](#)

References

1. Stewart WF, Shechter A, Rasmussen BK. Migraine prevalence. A review of population-based studies. *Neurology*. 1994;44:S17-S23. PMID: [8008222](#)
2. Post MC, Thijs V, Herroelen L, Budts W. Closure of a patent foramen ovale is associated with a decrease in prevalence of migraine. *Neurology*. 2004;62:1439-1440. DOI: [10.1212/01.WNL.0000120756.25236.37](#)
3. Reisman M, Christofferson RD, Jesurum J, Olsen JV, Spencer MP, Krabill KA, et al. Migraine headache relief after transcatheter closure of patent ovale. *J Am Coll Cardiol*. 2005;45:493-495. DOI: [10.1016/j.jacc.2004.10.055](#)
4. Schwedt TJ, Demaerschalk BM, Dodick DW. Patent foramen ovale and migraine: a quantitative systematic review. *Cephalalgia*. 2008;28:531-540. DOI: [10.1111/j.1468-2982.2008.01554.x](#)
5. Wilmshurst PT, Nightingale S, Walsh KP, Morrison WL. Effect on migraine of closure of cardiac right-to-left shunts to prevent recurrence of decompression illness or stroke or for haemodynamic reasons. *Lancet*. 2000;356:1648-1651. DOI: [10.1016/S0140-6736\(00\)03160-3](#)
6. Trabattoni D, Fabbiochi F, Montorsi P, Galli S, Teruzzi G, Grancini L, et al. Sustained long-term benefit of patent foramen ovale closure on migraine. *Catheter Cardiovasc Interv*. 2011;77:570-574. DOI: [10.1002/ccd.22826](#)
7. Rigatelli G, Dell'Avvocata F, Ronco F, Cardaioli P, Giordan M, Braggion G, et al. Primary transcatheter patent foramen ovale closure is effective in improving migraine in patients with high-risk anatomic and functional characteristics for paradoxical embolism. *JACC Cardiovasc Interv*. 2010;3:282-287. DOI: [10.1016/j.jcin.2009.11.019](#)
8. Kai H, Koyanagi S, Hirooka Y, Sugimachi M, Sadoshima J, Suzuki S, et al. Right-to-left shunt across atrial septal defect related to tricuspid regurgitation: Assessment by transesophageal Doppler echocardiography. *Am Heart J*. 1994;127:578-584. DOI: [10.1016/0002-8703\(94\)90666-1](#)
9. Mortelmans K, Post M, Thijs V, Herroelen L, Budts W. The influence of percutaneous atrial septal defect closure on the occurrence of migraine. *Eur Heart J*. 2005;26:1533-1537. DOI: [10.1093/eurheartj/ehi170](#)
10. Luermans JG, Post MC, Temmerman F, Thijs V, Schonewille WJ, Plokker HW, et al. Is a predominant left-to-right shunt associated with migraine? A prospective atrial septal defect closure study. *Catheter Cardiovasc Interv*. 2009;74:1078-1084. DOI: [10.1002/ccd.22226](#)
11. Azarbal B, Tobis J, Suh W, Chan V, Dao C, Gaster R. Association of interatrial shunts and migraine headaches: impact of transcatheter closure. *J Am Coll Cardiol*. 2005;45:489-492. DOI: [10.1016/j.jacc.2004.09.075](#)
12. Mügge A, Daniel WG, Angermann C, Spes C, Khandheria BK, Kronzon I, et al. Atrial septal aneurysm in adult patients. A multicenter study using transthoracic and transesophageal echocardiography. *Circulation*. 1995;91:2785-2792. DOI: [10.1161/01.CIR.91.11.2785](#)
13. Thanopoulos BD, Laskari CV, Tsaousis GS, Zarayelyan A, Vekiou A, Papadopoulos GS. Closure of atrial septal defects with the Amplatzer occlusion device: preliminary results. *J Am Coll Cardiol*. 1998;31:1110-1116. DOI: [10.1016/S0735-1097\(98\)00039-4](#)
14. Kijima Y, Akagi T, Nakagawa K, Taniguchi M, Ueoka A, Deguchi K, et al. Catheter closure of patent foramen ovale in patients with cryptogenic cerebrovascular accidents: initial experiences in Japan. *Cardiovasc Interv Ther*. 2014;29:11-17. DOI: [10.1007/s12928-013-0193-9](#)
15. Headache Classification Subcommittee of the International Headache Society. The International Classification of Headache Disorders: 2nd edition. *Cephalalgia*. 2004;24:9-160. PMID: [14979299](#)
16. Wilmshurst P, Nightingale S. Relationship between migraine and cardiac and pulmonary right-to-left shunts. *Clin Sci (Lond)*. 2001;100:215-220. DOI: [10.1042/cs1000215](#)
17. Kurth T, Tzourio C, Bousser MG. Migraine: a matter of the heart? *Circulation*. 2008;118:1405-1407. DOI: [10.1161/CIRCULATIONAHA.108.807198](#)
18. Truong T, Slavov L, Kashani R, Higgins J, Puri A, Chowdhry M, et al. Prevalence of migraine headaches in patients with congenital heart disease. *Am J Cardiol*. 2008;101:396-400. DOI: [10.1016/j.amjcard.2007.08.047](#)
19. van der Kuy PH, Lohman JJ. A quantification of the placebo response in migraine prophylaxis. *Cephalalgia*. 2002;22:265-270. DOI: [10.1046/j.1468-2982.2002.00363.x](#)
20. Wilmshurst PT, Nightingale S, Walsh KP, Morrison WL. Clopidogrel reduces migraine with aura after transcatheter closure of persistent foramen ovale and atrial septal defects. *Heart*. 2005;91:1173-1175. DOI: [10.1136/hrt.2004.047746](#)

Cite this article as: Takaya Y, Akagi T, Kijima Y, Nakagawa K, Kono S, Deguchi K, Sano S, Ito H. Resolution of Migraine After Transcatheter Closure of Atrial Communication. *Structural Heart Disease*. 2016;2(4):102-107. DOI: <http://dx.doi.org/10.12945/j.jshd.2016.010.15>

Use of Intracardiac Echocardiography for Congenital and Structural Heart Disease Interventions

Mike Saji, MD*, D. Scott Lim, MD

Division of Cardiovascular Medicine, Department of Medicine, Advanced Cardiac Valve Center, University of Virginia, Charlottesville, Virginia, USA

Abstract

Intracardiac echocardiography (ICE) has been commonly utilized for intraprocedural monitoring during structural heart interventions, and AcuNav is the most widely used device. Its imaging quality has been dramatically improved with the addition of a phased-array system in recent years, and it has been used as an alternative to transesophageal echocardiography (TEE), especially in cases of atrial septal defect and patent fossa ovale closure. One advantage of ICE over TEE is that it does not require general anesthesia with endotracheal intubation, which means it is less invasive procedure. However, its application during other structural interventions remains in an early stage due to technologic limitations. Multiplanar imaging and wide-sector three-dimensional imaging are required to improve its utility.

Copyright © 2016 Science International Corp.

Key Words

Intracardiac echocardiography • Phased-array system • Real-time imaging • Three-dimensional imaging • Advantage • Transesophageal echocardiography

Clinical Use of Intracardiac Echocardiography

Intracardiac echocardiography (ICE) has been commonly used as an intraprocedural modality during structural heart interventions. It provides real-time anatomical assessment, and in certain procedures it has been used as an alternative to transesophageal echocardiography (TEE). ICE imaging quality was dramatically improved with the recent addition of

a phased-array system [1]. There are currently five types of commercially available ICE catheter systems: AcuNav (Siemens Medical Solutions, Malvern, PA, USA), UltraICE (Boston Scientific, Marlborough, MA, USA), EP Med View Flex (St. Jude Medical, St. Paul, MN, USA), ClearICE (St. Jude Medical), and SoundStar Catheter (Biosense Webster Diamond Bar, CA, USA) [2]. AcuNav is currently the most widely utilized system during structural heart interventions. There are 8- and 11-French (F) catheters, and either the femoral or jugular vein is commonly used. It is capable of producing frequencies between 5 and 10 MHz, resulting in adequate imaging up to 10 to 14 cm from the transducer. This allows visualization of most left-sided structures from the right side of the heart. For selected interventions, ICE can be introduced into the left ventricle or atrium to produce additional images. The orientation marker on the screen shows the position of the handle such that inferior and superior structures are on the left and side of the screen, respectively. Four-way articulation of the catheter tip enables excellent maneuverability for optimal imaging, and full Doppler capabilities including color, tissue, and spectral Doppler provides additional information.

Compared with TEE, ICE provides many advantages. It does not require general anesthesia with endotracheal intubation and is therefore less invasive. Furthermore, fluoroscopy time, interventional procedural time, and hospital stay have are shortened [3], all of which could reduce total intervention cost.

Potential complications that may result from right-sided ICE imaging are extremely rare and include



those associated with right heart catheterization such as pericardial tamponade, pulmonary embolism, infection, and bleeding.

Structural Views

Home View (Figure 1)

The ICE catheter is advanced into the right atrium under fluoroscopic guidance from the femoral vein. Since ICE does not have a wire lumen and uses a relatively stiff shaft, careful advance is necessary to avoid vascular complications. The probe in the neutral position within the right atrium allows for visualization of the right atrium, right ventricle, and tricuspid valve. It is often useful to return to this view when the operator is confronted with an unfamiliar view following multiple steering manipulations.

Right Ventricular Outflow Tract View (Figure 2)

From home view, clockwise rotation of approximately 30° brings the right ventricular outflow tract (RVOT), pulmonary artery, and aortic valve into view.

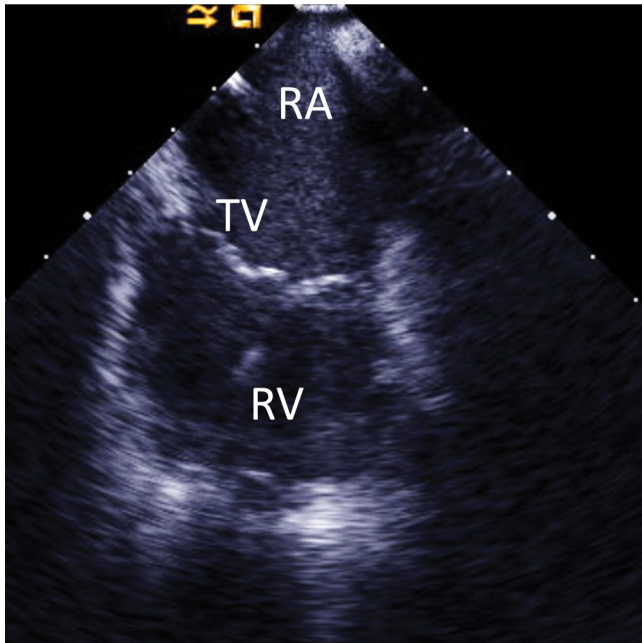


Figure 1. Home view. The catheter is advanced into mid RA with a neutral position. RA = right atrium; RV = right ventricle; TV = tricuspid valve.

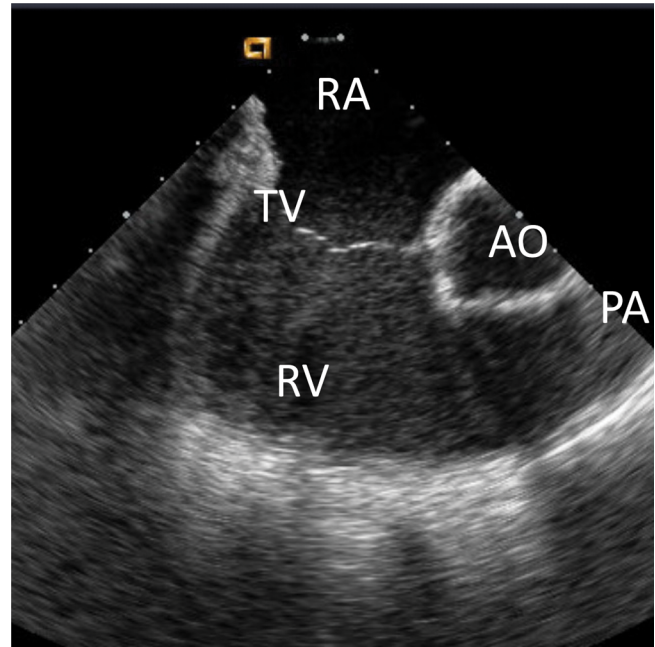


Figure 2. Right ventricular outflow tract view. The catheter is rotated clockwise with approximately 30° from home view. AO = ascending aorta; PA = pulmonary artery; RA = right atrium; RV = right ventricle; TV = tricuspid valve.

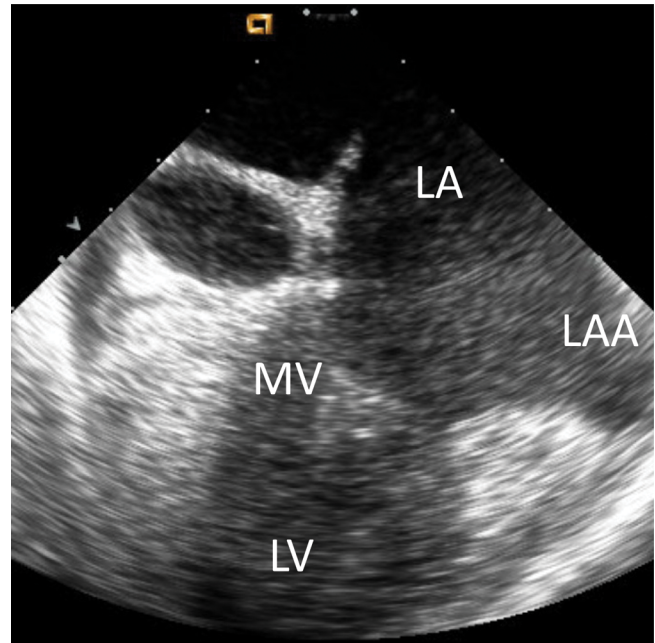


Figure 3. Left atrial appendage, mitral valve view. The catheter is rotated with approximately 60° from home view. LA = left atrium; LV = left ventricle; MV = mitral valve.

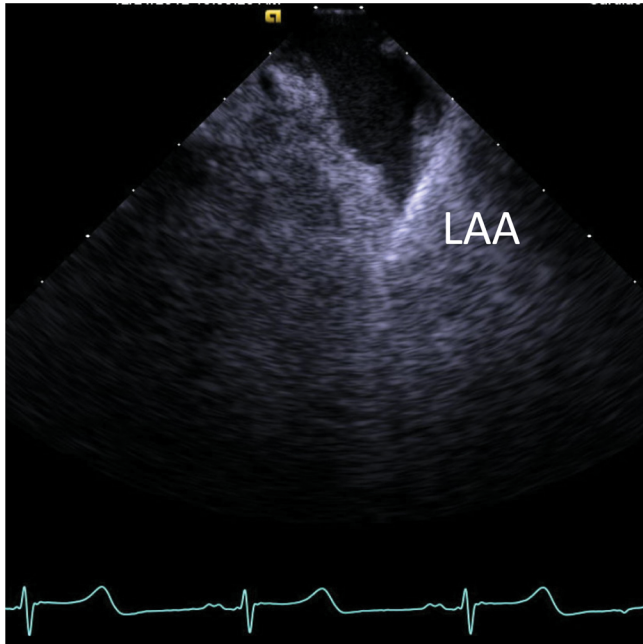


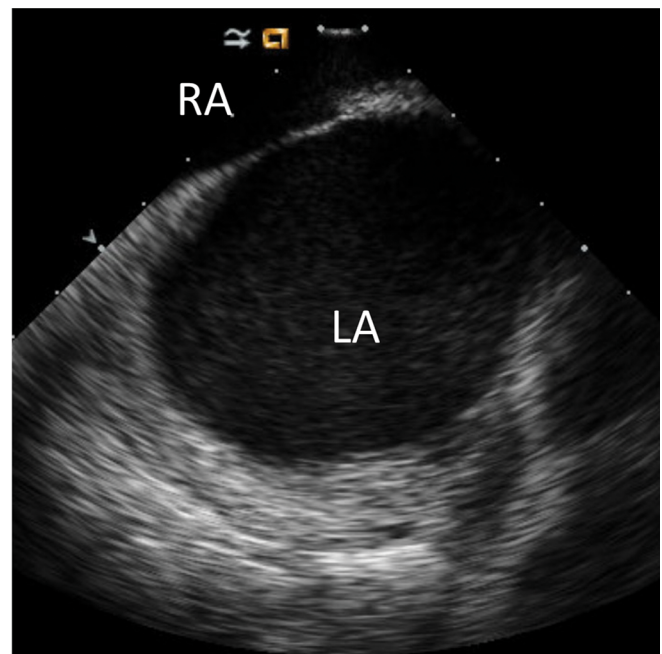
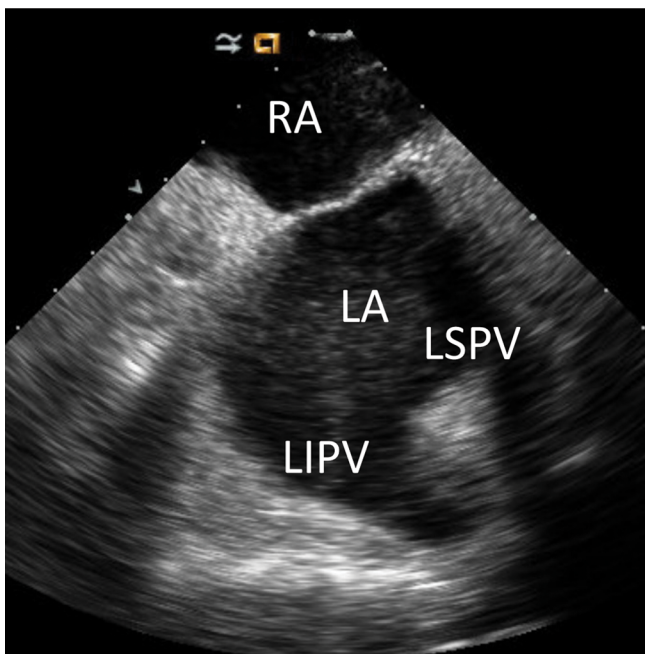
Figure 4. Image of the left atrial appendage (LAA) obtained from left atrium (LA) through the transseptal sheath. Intracardiac echocardiography advanced into the LA shows no thrombus in the LAA.

Left Atrial Appendage, Mitral Valve View (Figure 3)

Further rotation of the catheter approximately 60° brings the mitral valve and the left atrial appendage. In selected patients, the left atrial appendage can be adequately evaluated from the right atrium to be sure it is clear of thrombus by two-dimensional ICE due to highly morphological variety of left atrial appendages. If there is not adequate visualization from the right side, the ICE catheter must be introduced into the coronary sinus [4], RVOT, left pulmonary artery [5], or left atrium [6] following transseptal puncture to confirm that the appendage is free of thrombus (Figure 4).

Left Pulmonary Vein, Fossa Ovalis View (Long Axis View) Figures 5 and 6

Another rotation of more than 90° from the home view brings the left atrium and left pulmonary veins into view. Posterior tilt allows clear visualization of the fossa ovalis. The superior vena cava (SVC) can be seen by advancing the ICE catheter further to the superior right atrium, while the inferior vena cava (IVC) can be seen by



Figures 5 and 6. Left pulmonary vein, fossa ovalis view (long axis view of the septum). The catheter is rotated more than 90° from home view. Posterior tilt allows visualization of the fossa ovalis. LA = left atrium; LSPV = left superior pulmonary vein; LIPV = left inferior pulmonary vein; RA = right atrium.

retracting the ICE catheter to the inferior right atrium in this view. The superior rim, SVC rim, and IVC rim can be evaluated in this view in atrial septal defect (ASD) closure.

Short Axis View (Figure 7)

The ICE catheter is retracted to the inferior right atrium and tilted posteriorly and rightward. This brings the interatrial septum and aortic valve into view. This view is used to evaluate paravalvular leakage after transcatheter aortic valve replacement (TAVR), as well as measurement of aortic and posterior rims during ASD closure.

Left Ventricular Long Axis View (Figure 8)

The posterior-tilted catheter is rotated clockwise and then advanced into the right ventricle. The left ventricle can be imaged across the ventricular septum. Left ventricular function, mitral regurgitation, the subvalvular apparatus, and pericardial effusion can also be evaluated in this view. It may be of limited utility for interventions on the mitral valve and ventricular septum in this view.

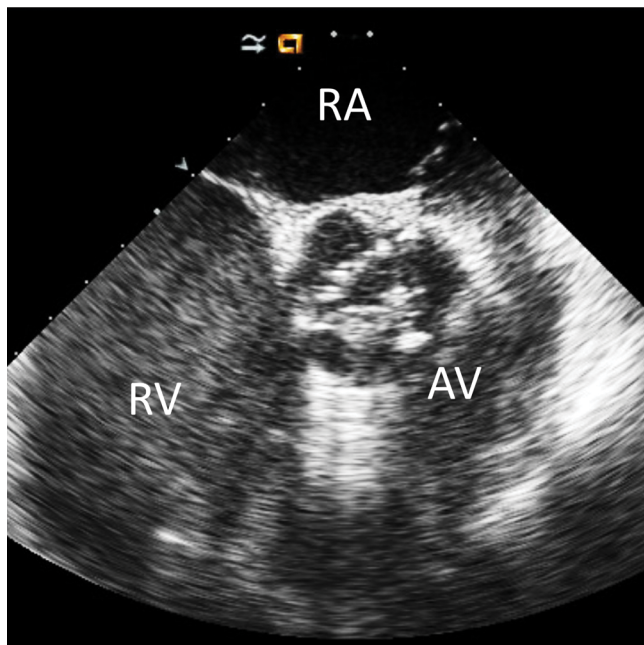


Figure 7. Short axis view. The catheter is retracted to the inferior right ventricle with a posterior tilt. AV = aortic valve; RA = right atrium; RV = right ventricle.

Specific Procedure Use

Current clinical applications of ICE in cardiac interventional procedures include guidance of transseptal puncture [7], ASD/patent foramen ovale (PFO) closure [8, 9], percutaneous mitral balloon valvuloplasty [10], and TAVR [11]. It can be also used to guide diagnostic evaluation of cardiac mass [12], coronary sinus pacemaker lead placement [13], ventricular septal defect closure [14], transluminal septal ablation for hypertrophic cardiomyopathy [15], and potentially other structural heart interventions such as transcatheter mitral valve repair with the MitraClip and left atrial appendage closure.

Guidance of Transseptal Puncture

ICE enables safe navigation of transseptal puncture compared with traditional fluoroscopy guidance, particularly if patients have an unusual anatomical abnormality [7] (Figure 9). It may also help to reduce and immediately identify complications related to transseptal puncture. Optimal septum imaging is obtained by the long axis view such that the interatrial septum is perpendicular to the ultrasound beam. Tenting of the septum indicates stable contact of the needle or dilator with the

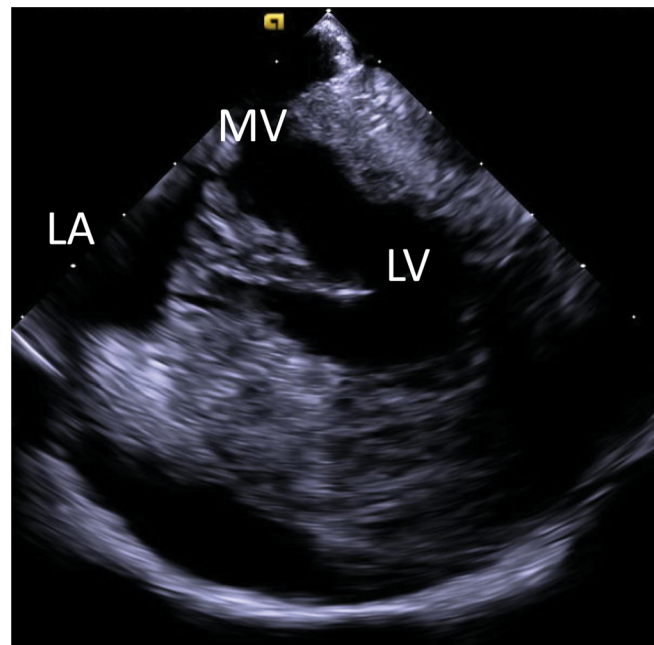


Figure 8. Transventricular long axis view. Posterior-tilted catheter is advanced into right ventricle. LA = left atrium; LV = left ventricle; MV = mitral valve; RV = right ventricle.

septum (Figure 10). During the puncture, the transseptal needle inserted into the transseptal sheath is directed to the fossa ovalis and carefully advanced. Successful puncture can be confirmed by contrast or agitated saline injection through the transseptal needle to the left atrium (Figure 11). The puncture site is tailored to the intended procedure. The superior-inferior position is evaluated in this long axis view, while the anterior-posterior position is evaluated by the short axis view.

Atrial Septal Defect/Patent Foramen Ovale Closure

Previous studies have shown that ICE provides excellent utility for percutaneous closure of ASD and PFO [8, 9]. There is an increasing trend toward the use of ICE in the majority of these two procedures. Direct visualization may identify septum morphology (Figures 12, 13). The short axis view allows for evaluation of the anterior and posterior side of the rim, while the long axis view allows visualization of the superior and inferior side of the rim, as mentioned earlier. During the procedure, this view also allows visualization of guidewire insertion from the right to left atrium; wire positioning; optimal device sizing, positioning, and deployment; and presence of residual shunt (Figures 14, 15).

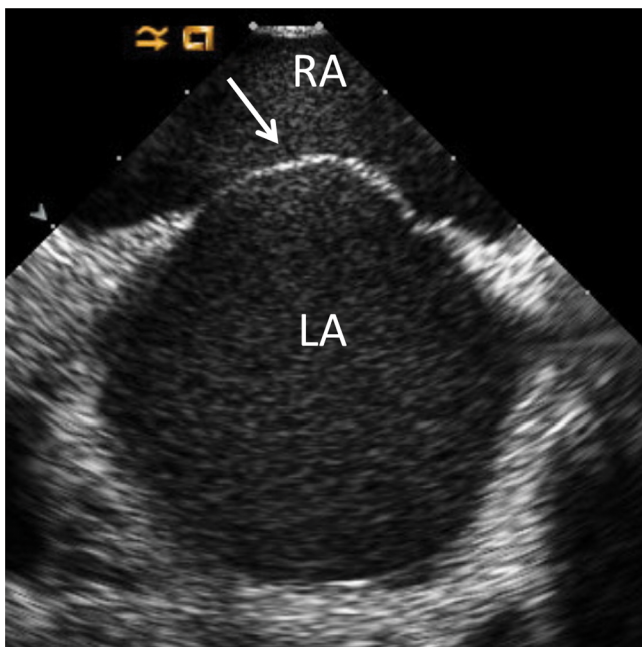


Figure 9. Long axis view. An atrial septal abnormality can be confirmed (arrow). LA, left atrium; RA, right atrium.

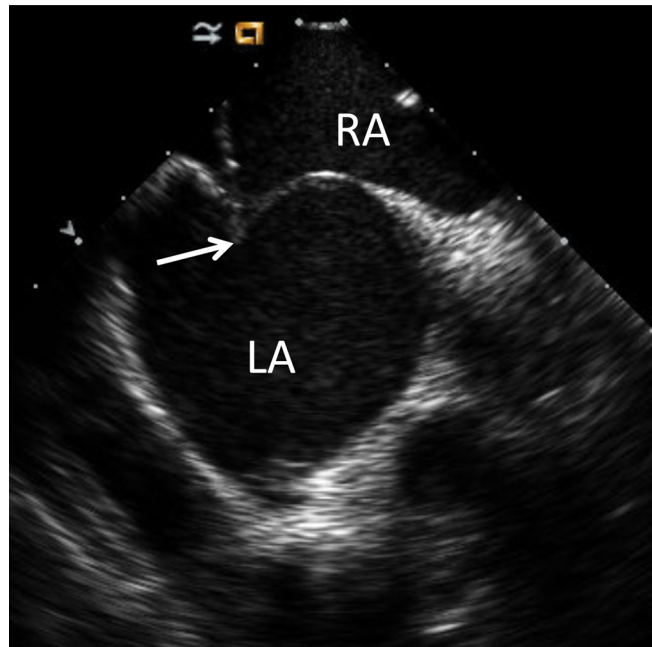


Figure 10. Long axis view. Tenting of the septum indicates stable contact of the needle with septum (arrow). LA = left atrium; RA = right atrium.

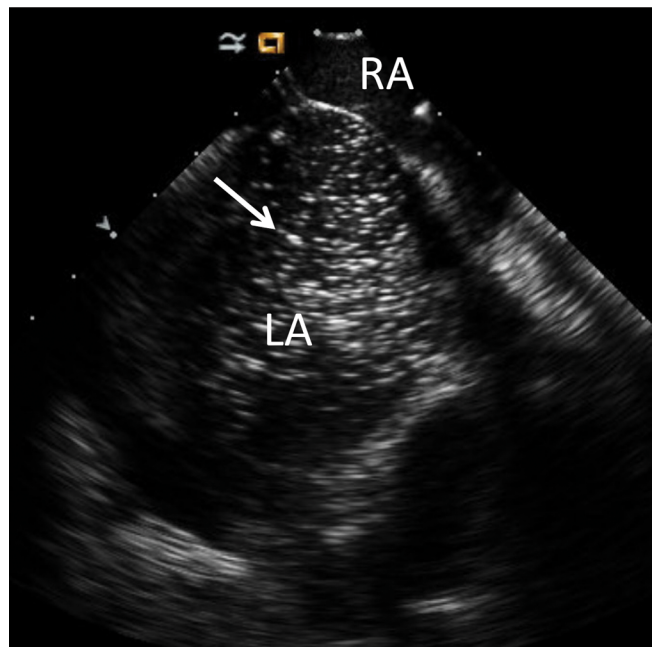


Figure 11. Long axis view. Successful puncture can be confirmed by contrast injection through the transseptal needle into left atrium (arrow). LA = left atrium; RA = right atrium.

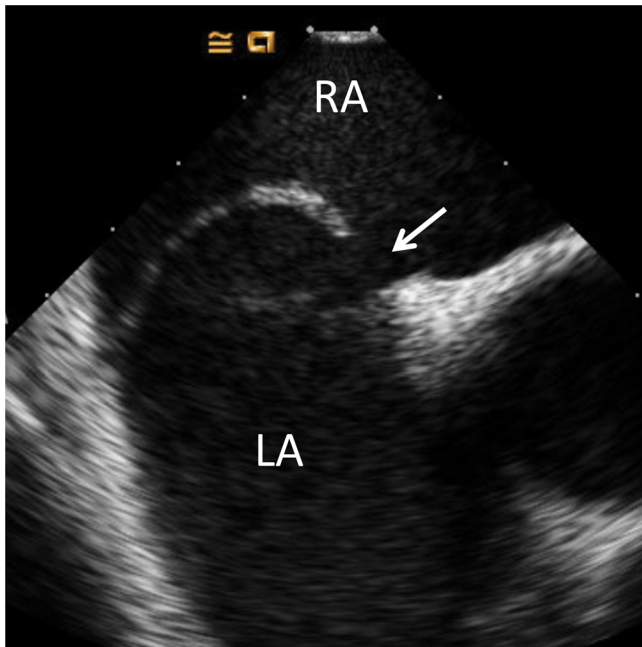


Figure 12. Long axis view. A secundum atrial septal defect can be seen (arrow). LA = left atrium; RA = right atrium.

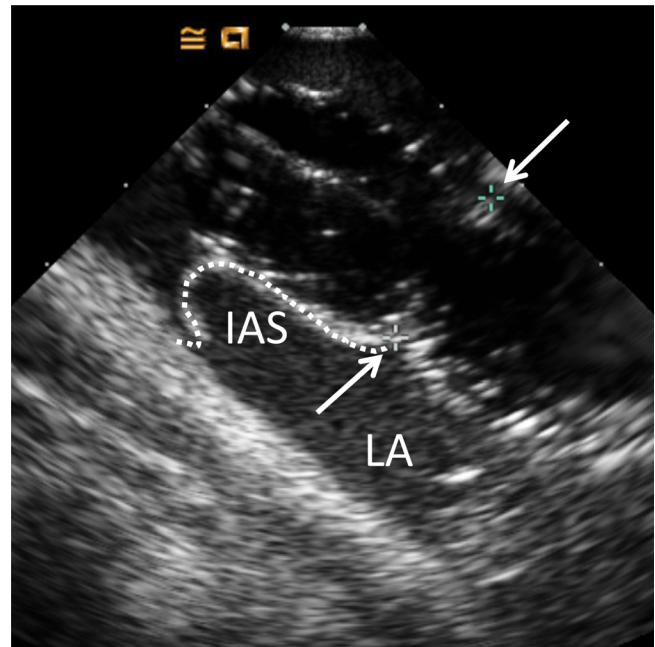


Figure 14. Balloon sizing before device deployment. Atrial septal defect is evaluated using sizing balloon (arrow). IAS = intra-atrial septum; LA = left atrium.

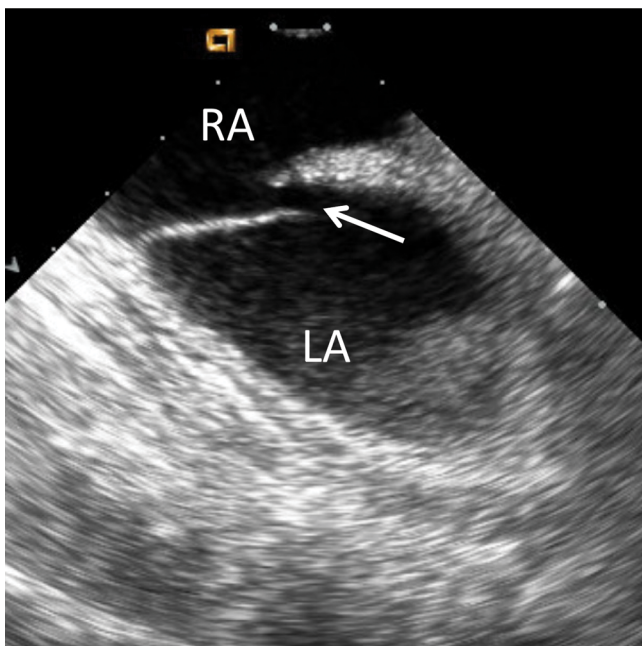


Figure 13. Long axis view. Patent foramen ovale can be seen (arrow). LA = left atrium; RA = right atrium.

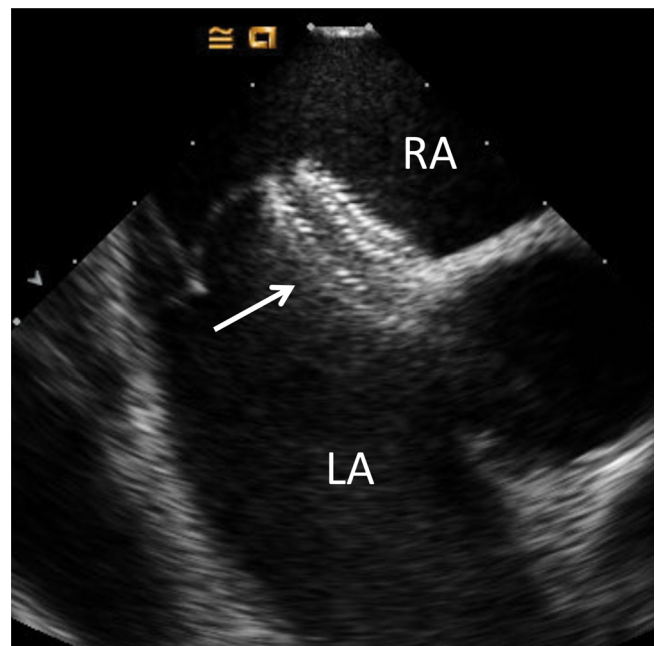


Figure 15. Atrial septal defect (ASD) closure device deployment. The ASD closure device is implanted (arrow). LA = left atrium; RA = right atrium.

Mitral Stenosis with Percutaneous Mitral Balloon Valvuloplasty

Percutaneous mitral balloon valvuloplasty is a treatment of choice in patients with rheumatic mitral stenosis. ICE facilitates safer transseptal puncture, which is the riskiest part of this procedure. In addition, the long axis view can identify mitral apparatus deformity due to rheumatic disease, balloon positioning on the mitral valve, and the transmitral gradient after balloon dilation using Doppler (Figure 16).

Aortic Stenosis with Transcatheter Aortic Valve Replacement

A previous study compared imaging between ICE and TEE during TAVR and demonstrated the safety and feasibility of ICE-guided TAVR [11]. The long axis view (Figures 17, 18) allows visualization of device positioning and deployment. The short axis view (Figure 7) is helpful to grade and evaluate paravalvular leak after device deployment. TEE remains the gold standard

imaging modality for TAVR due to its multiplanar capabilities; however, ICE can be considered as an alternative in selected cases.

Mitral Regurgitation with Transcatheter Mitral Valve Repair

ICE may be useful during transcatheter mitral valve repair with the MitraClip (Abbott Vascular, Menlo Park, CA). As the mitral valve has a more complex morphology than the aortic valve, it needs a specific planar window in which both the A2 and P2 scallops of the mitral valve can be visualized (most frequent location for MitraClip placement), so the current generation of two-dimensional ICE has limited usage. However, if there is difficulty visualizing pathology with TEE because of shadowing from the prior surgical ring or severe mitral annular calcification (Figure 19), adjunctive ICE has been helpful in the authors' experience. To adequately visualize insertion of both the anterior and posterior leaflets into the MitraClip, the 8F ICE

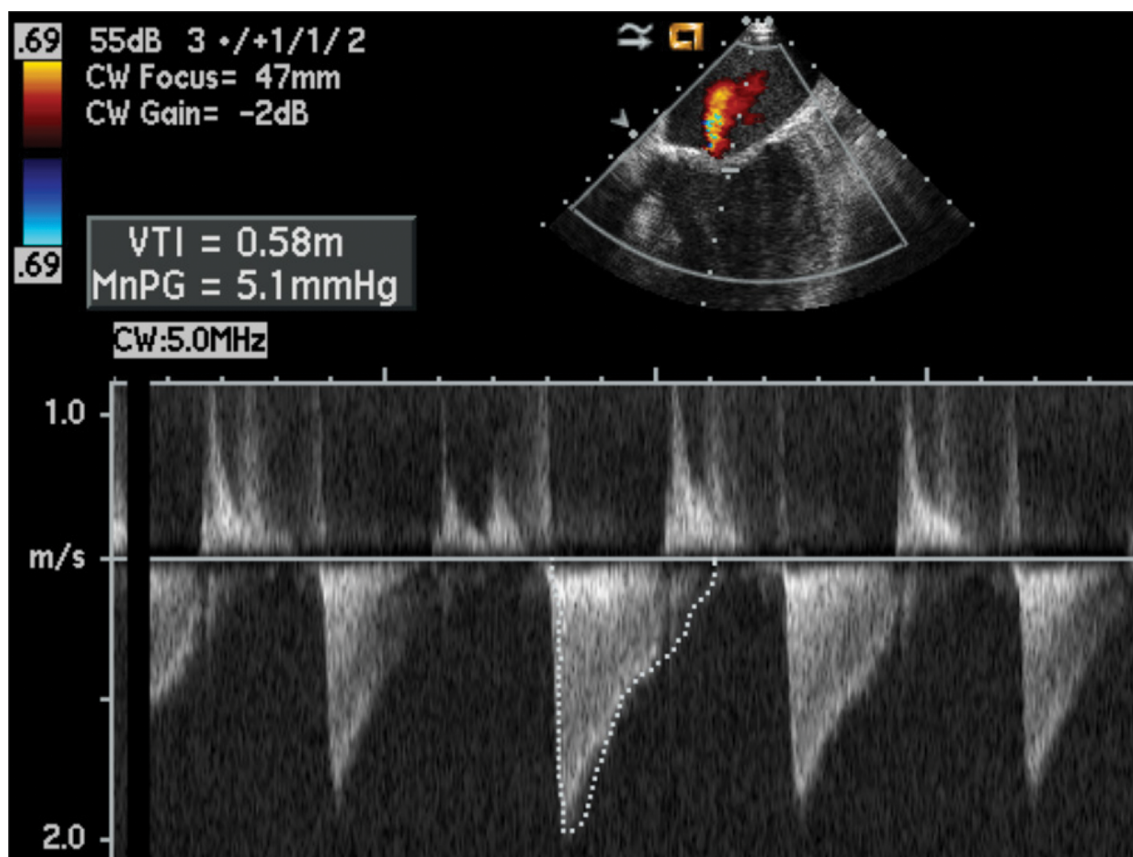
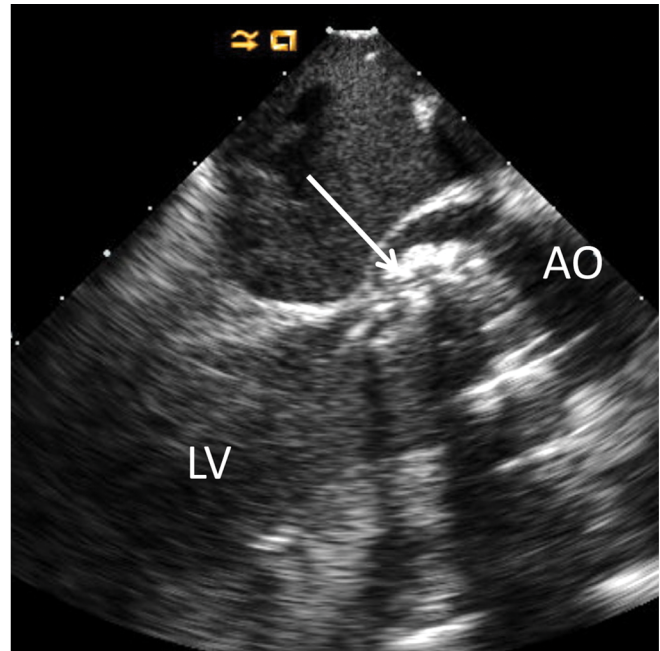
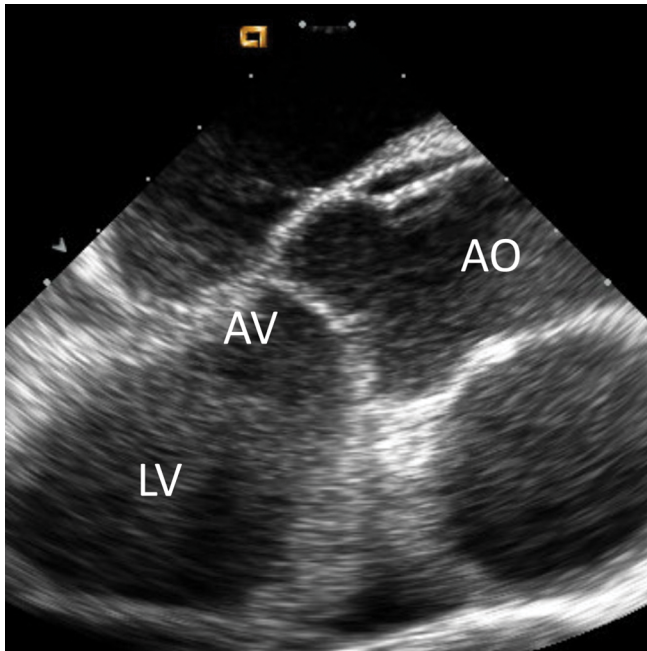


Figure 16. Transmitral gradient obtained by intracardiac echocardiography. Color Doppler identifies the transmitral gradient.



Figures 17 and 18. Long axis view in transcatheter aortic valve replacement. Long axis view from high right atrium allows the visualization of ascending aorta, aortic valve, and left ventricle; outflow tract. A bioprosthetic valve is implanted percutaneously (arrow). AO = ascending aorta; AV = aortic valve; LV = left ventricle; RA = right atrium.

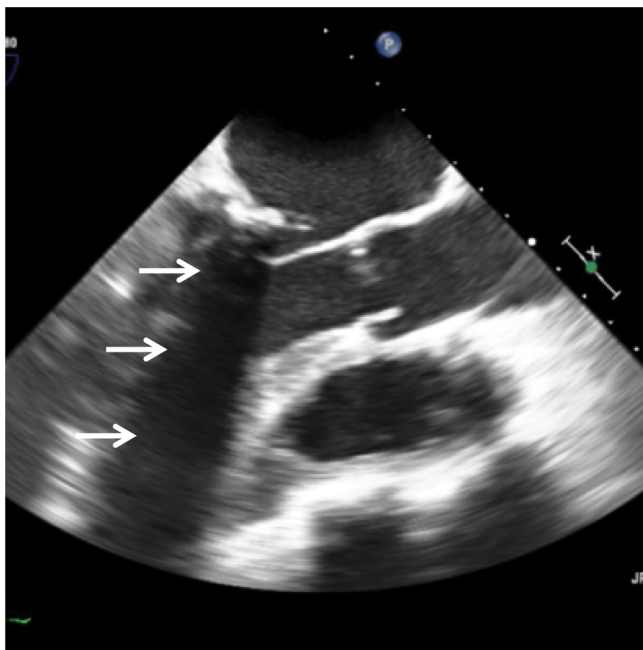


Figure 19. Imaging obtained by transesophageal echocardiography. Posterior leaflet is difficult to see because of shadowing from the prior surgical ring (arrow).

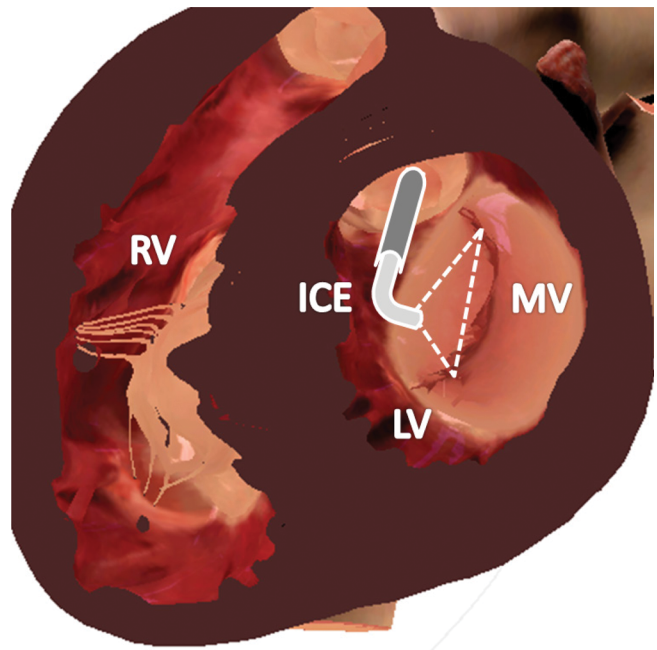


Figure 20. Retrograde and transarterial introduction of the 8-French intracardiac echocardiography catheter into the left ventricle. LV = left ventricle; MV = mitral valve; RV = right ventricle.

catheter is introduced retrogradely and transarterially into the left ventricle and flexed to image across the mitral valve (Figure 20). The double-orifice mitral valve created by the MitraClip can be visualized by

ICE (Figure 21). Notably, in transcatheter mitral valve repair, three-dimensional ICE remains of limited utility due to its relatively narrow sector width and inadequate resolution (Figure 22).

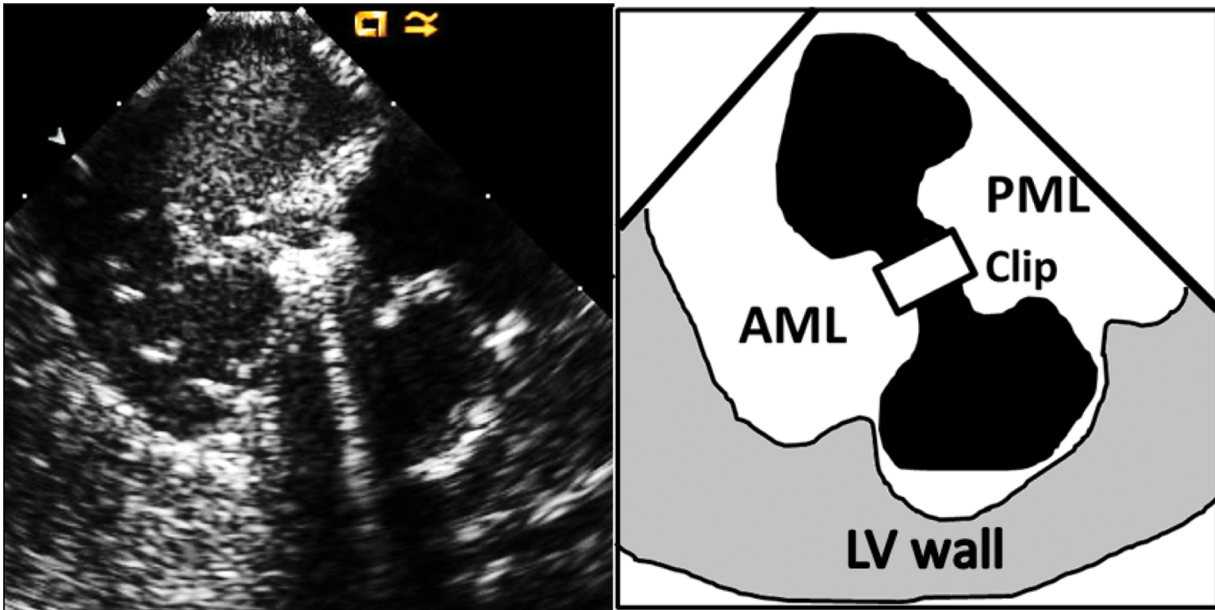


Figure 21. The left ventricle short axis view obtained by intracardiac echocardiography (ICE). ICE can demonstrate appropriate insertion of both leaflets into the MitraClip creating the double-orifice mitral valve. AML = anterior mitral leaflet; LV = left ventricle; PML = posterior mitral leaflet.

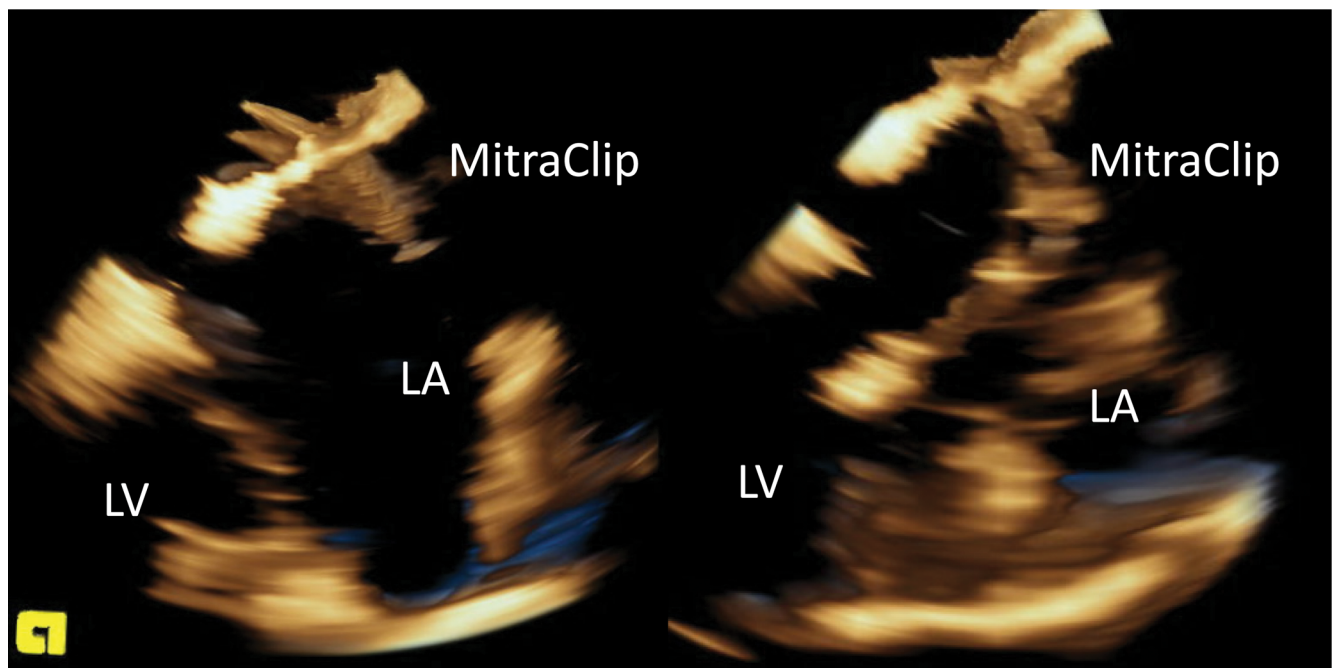


Figure 22. Three-dimensional intracardiac echocardiography (ICE) imaging. Three-dimensional ICE guides the MitraClip delivery system. LA, = left atrium; LV = left ventricle.

Left Atrial Appendage Closure

The current generation of single-plane ICE catheter that creates imaging from the right atrium is rarely sufficient to fully visualize the complicated anatomy of the left atrial appendage [16], and there have been only case reports describing successful appendage closures with ICE monitoring [6, 17]. Future ICE iterations with multiplanar capability would allow more accurate measurement of the ostial diameter, which is not circular, and postprocedural color Doppler to check for device leaks.

Conclusions

ICE has been used to a variable degree in structural heart interventions. While it has an excellent clinical

role for guiding ASD/PFO closure, technologic limitations hamper its application during other structural interventions. Multiplanar imaging and wide-sector three-dimensional imaging are required to improve ICE utilization during transcatheter interventional procedures.

Conflict of Interest

The authors have no conflict of interest relevant to this publication.

Comment on this Article or Ask a Question

References

- Kort S. Intracardiac echocardiography: evolution, recent advances, and current applications. *J Am Soc Echocardiogr.* 2006;19:1192-1201. DOI: [10.1016/j.echo.2006.04.033](https://doi.org/10.1016/j.echo.2006.04.033)
- Hijazi ZM, Shivkumar K, Sahn DJ. Intracardiac echocardiography during interventional and electrophysiological cardiac catheterization. *Circulation.* 2009;119:587-596. DOI: [10.1161/CIRCULATIONAHA.107.753046](https://doi.org/10.1161/CIRCULATIONAHA.107.753046)
- Ali S, George LK, Das P, Koshy SK. Intracardiac echocardiography: clinical utility and application. *Echocardiography.* 2011;28:582-590. DOI: [10.1111/j.1540-8175.2011.01395.x](https://doi.org/10.1111/j.1540-8175.2011.01395.x)
- Baran J, Stec S, Pilichowska-Paszkiel E, Zaborzka B, Sikora-Frac M, Kryński T, et al. Intracardiac echocardiography for detection of thrombus in the left atrial appendage: comparison with transesophageal echocardiography in patients undergoing ablation for atrial fibrillation: the Action-Ice I Study. *Circ Arrhythm Electrophysiol.* 2013;6:1074-1081. DOI: [10.1161/CIRCEP.113.000504](https://doi.org/10.1161/CIRCEP.113.000504)
- Reddy VY, Neuzil P, Ruskin JN. Intracardiac echocardiographic imaging of the left atrial appendage. *Heart Rhythm.* 2005;2:1272-1273. DOI: [10.1016/j.hrthm.2005.06.027](https://doi.org/10.1016/j.hrthm.2005.06.027)
- Fassini G, Dello Russo A, Conti S, Tondo C. An alternative transseptal intracardiac echocardiography strategy to guide left atrial appendage closure: the first described case. *J Cardiovasc Electrophysiol.* 2014;25:1269-1271. DOI: [10.1111/jce.12480](https://doi.org/10.1111/jce.12480)
- Bidart C, Vaseghi M, Cesario DA, Mahajan A, Fujimura O, Boyle NG, et al. Radiofrequency current delivery via transseptal needle to facilitate septal puncture. *Heart Rhythm.* 2007;4:1573-1576. DOI: [10.1016/j.hrthm.2007.07.008](https://doi.org/10.1016/j.hrthm.2007.07.008)
- Bartel T, Konorza T, Arjumand J, Ebradlize T, Eggebrecht H, Caspari G, et al. Intracardiac echocardiography is superior to conventional monitoring for guiding device closure of interatrial communications. *Circulation.* 2003;107:795-797. DOI: [10.1161/01.CIR.0000057547.00909.1C](https://doi.org/10.1161/01.CIR.0000057547.00909.1C)
- Earing MG, Cabalka AK, Seward JB, Bruce CJ, Reeder GS, Hagler DJ. Intracardiac echocardiographic guidance during transcatheter device closure of atrial septal defect and patent foramen ovale. *Mayo Clin Proc.* 2004;79:24-34. DOI: [10.4065/79.1.24](https://doi.org/10.4065/79.1.24)
- Green NE, Hansgen AR, Carroll JD. Initial clinical experience with intracardiac echocardiography in guiding balloon mitral valvuloplasty: technique, safety, utility, and limitations. *Catheter Cardiovasc Interv.* 2004;63:385-394. DOI: [10.1002/ccd.20177](https://doi.org/10.1002/ccd.20177)
- Bartel T, Bonaros N, Müller L, Friedrich G, Grimm M, Velik-Salchner C, et al. Intracardiac echocardiography: a new guiding tool for transcatheter aortic valve replacement. *J Am Soc Echocardiogr.* 2011;24:966-975. DOI: [10.1016/j.echo.2011.04.009](https://doi.org/10.1016/j.echo.2011.04.009)
- Oishi Y, Okamoto M, Sueda T, Hashimoto M, Karakawa S, Akita T, et al. Cardiac tumor biopsy under the guidance of intracardiac echocardiography. *Jpn Circ J.* 2000;64:638-640. DOI: [10.1253/jcj.64.638](https://doi.org/10.1253/jcj.64.638)
- Cohen TJ, Juang G. Utility of intracardiac echocardiography to facilitate transvenous coronary sinus lead placement for biventricular cardioverter-defibrillator implantation. *J Invasive Cardiol.* 2003;15:685-686.
- Cao QL, Zabal C, Koenig P, Sandhu S, Hijazi ZM. Initial clinical experience with intracardiac echocardiography in guiding transcatheter closure of perimembranous ventricular septal defects: feasibility and comparison with transesophageal echocardiography. *Catheter Cardiovasc Interv.* 2005;66:258-267. DOI: [10.1002/ccd.20463](https://doi.org/10.1002/ccd.20463)
- Pedone C, Vijayakumar M, Lighthart JM, Valgimigli M, Biagini E, De Jong N, et al. Intracardiac echocardiography guidance during percutaneous transluminal septal myocardial ablation in patients with obstructive hypertrophic cardiomyopathy. *Int J Cardiovasc Intervent.* 2005;7:134-137. DOI: [10.1080/14628840500280575](https://doi.org/10.1080/14628840500280575)
- Desimone CV, Asirvatham SJ. ICE Imaging of the left atrial appendage. *J Cardiovasc Electrophysiol.* 2014;25:1272-1274. DOI: [10.1111/jce.12536](https://doi.org/10.1111/jce.12536)
- MacDonald ST, Newton JD, Ormerod OJ. Intracardiac echocardiography off piste? Closure of the left atrial appendage using ICE and local anesthesia. *Catheter Cardiovasc Interv.* 2011;77:124-127. DOI: [10.1002/ccd.22652](https://doi.org/10.1002/ccd.22652)

Cite this article as: Saji M, Lim DS. Use of Intracardiac Echocardiography for Congenital and Structural Heart Disease Interventions. *Structural Heart Disease.* 2016;2(4):108-117. DOI: <http://dx.doi.org/10.12945/jjshd.2016.006.15>

HOSPITAL
DEFECTS

Successful Percutaneous Closure of Large and Malalignment Atrial Septal Defects with Pulmonary Hypertension

Masao Imai, MD, Shin Watanabe, MD, Toshiaki Toyoda, MD, Takeshi Kimura, MD
Department of Cardiovascular Medicine, Graduate School of Medicine, Kyoto University, Kyoto, Japan

Background
Therapeutic strategies for pulmonary arterial hypertension (PAH) associated with atrial septal defects (ASD) remain a matter of debate.

Methods and Results
A 60-year-old female patient with a history of secundum ASD presented with complaints of shortness of breath. Transesophageal echocardiography showed a secundum large ASD with pulmonary hypertension (PH) (systolic pulmonary artery pressure [sPAP] and Qp:Qs ratio was 4.6). Preoperative echocardiography also showed large ASD with short septum (0.5 mm) and malalignment (Figure 1). Although this patient had PH, catheter showed low PVR (25 dyne/cm⁵). Therefore, we thought that PH was associated with the volume overload from left to right through large ASD and catheter closure of ASD proceeded.

Result
To avoid worsening PH, pre balloon occlusion was enforced and no elevation of pulmonary artery pressure observed. Using the percutaneous method accompanied by transesophageal echocardiography guidance, the defect was successfully closed with a 30-mm Amplatzer ASD closure device to involve malalignment rim each other (Figure 2). Postprocedural echocardiographic control showed no leaks and postprocedural CT (Figure 3) also indicated complete closure of ASD with no worsening of PH.

CSI 25-27 June 2015- Frankfurt, Germany



SCIENTIFIC ABSTRACTS

2016

[A] COARCTATION AND DUCTS

A1	Medium-term follow-up treatment of severe native coarctation of aorta using balloon angioplasty in young infants less than one year of age	7
A2	The “Dog Bone Technique” – a novel easy and safe catheter maneuver for aortic arch and coarctation stenting	8
A3	Percutaneous PDA closure in a challenging pediatric case	9
A4	Coarctoplasty in a case of interrupted aortic arch with peripheral CTO technique	10
A5	Closure of very large PDA with pulmonary hypertension: initial clinical case series with the new Occlutec® PDA Occluder	11
A6	Interventional re-opening of a PDA for Reverse-Pott shunt circulation after ADO-implantation in a child	13
A7	Early clinical experience with the Medtronic Micro Vascular Plug™ in congenital cardiac interventions in children	15
A8	Stenting for aortic coarctation in small children: acute and mid-term outcomes	16
A9	Ductal closure using various devices	17
A10	Coarctation stenting in patients under 20 kg of weight	18
A11	Coarctation stenting in a 60-year-old woman	19
A12	Stenting of vertical duct using carotid artery access without surgical cut-down: a single institution experience	21
A13	Transverse aortic arch hypoplasia and aortic coarctation – treating one and not the other: geometrical quantification of aortic arch obstruction by 3D rotational angiography and MIMICS®	22
A14	Atrial duct stenting for rehabilitation of a disconnected left pulmonary artery in fallot’s tetralogy with absent pulmonary valve	23
A15	PDA closure with CeraFlex™ Occluder: is there any additional benefit?	26
A16	Transfemoral approach for PDA closure in a patient with azygos continuation of the inferior vena cava with the ADO II device without arterio-venous loop	27

[B] PULMONARY CIRCULATION

B1	Challenging cases of CHD transcatheter intervention	29
B2	Two centre experience with VesselNavigator for 3D guidance of percutaneous pulmonary valve implantation	30
B3	Transcatheter implantation of the Edwards SAPIEN XT and Sapien 3 valves: options for treatment of right heart valvular lesions – a two center experience	31
B4	A rare cause of cyanosis in a previously operated congenital heart disease	32
B5	Percutaneous closure of pulmonary aneurysm	33
B6	A case of percutaneous modified Blalock-Taussig shunt downsize with stent-in-stent technique	35
B7	Bronchial compression by mass effect following pulmonary artery stenting in single ventricle lesions: its prevention and decompression	37
B8	Rotational angiography and 3D reconstruction before Melody valve positioning	38
B9	Accurate hemodynamic evaluations before and after Fontan completion by phase-contrast cardiac MRI and catheterization	39
B10	Patent ductus arteriosus morphology in ductal dependent pulmonary circulation – How does computed tomogram angiography help?	41
B11	Percutaneous reconstruction of the right heart: tricuspid and pulmonary valve-in-valve in combination with a pulmonary artery stent in a single procedure	43
B12	Unilateral hypertensive lung in a correctable lesion, how does it respond?	45
B13	Experience with the Absorb Bioreabsorbable Vascular Scaffold (BVS) in various scenarios of congenital heart disease	48

B14	Results of transcatheter pulmonary valvulation in children < 30 kg	49
B15	Stenting of the native right ventricular outflow tract in symptomatic infants with tetralogy of fallot (TOF)	50
B16	One coil and three collaterals	51
B17	Isolated branch pulmonary stenosis and unilateral pulmonary hypertension: relationship and outcome	53

[C] SEPTAL DEFECTS

C1	Device closure in adults with atrial septal defect: a single center study	55
C2	Long-term outcomes of treat and repair strategy for atrial septal defect with pulmonary arterial hypertension	56
C3	Incidence of paradoxical embolism mediated by patent foramen ovale at acute-care hospital	57
C4	Feasibility and safety of transcatheter closure of atrial septal defect in small children weighing 10 kg or less	58
C5	Seven Nit-Occlud LE-VSD devices for the transcatheter closure of multiple VSDs – a case report	59
C6	Embolizations/dislocations of atrial septal defect and patent ductus arteriosus occluders; single center experience	61
C7	Transcatheter closure of perimembranous ventricular septal defect by Nit-Occlud Coil – a single center experience	63
C8	Closing perimembranous type ventricular septal defects by AMPLATZER Duct Occluder II	64
C9	High incidence of right to left shunt in adult patients with atrial septal defect	65
C10	A successful failure	66
C11	Implantation of AndraStents XL/XXL for dilation of different vessels	67
C12	One center comparative study of six different nitinol wire mesh occluders in transcatheter closure of atrial septal defect	68
C13	Device sizing for atrial flow regulation in HFpEF: a computer simulation model	69
C14	Retrograde transcatheter closure of ventricular septal defects	70
C15	Transcatheter management of perimembranous ventricular septal defect and subaortic ridge with or without AR	71
C16	Are AMPLATZER Duct Occluder II additional sizes devices dedicated only for smaller children?	72
C17	Residual postsurgery perimembranous VSD closure	73
C18	Survey into current perceptions and practice of device closure of patent foramen ovale for cryptogenic stroke in the United Kingdom	76
C19	Transcatheter closure of coronary cameral fistula	77
C20	Initial experience of Cocoon Septal Occluder in chinese patients in Hong Kong	79
C21	Transcatheter septation of a sinus venosus ASD with partial anomalous pulmonary venous drainage	80
C22	Is only a patent foramen ovale responsible for paradoxical brain embolism in a young man? A case with coexisting pulmonary arteriovenous malformation	81
C23	Apical post infarct ventricular septal defect treated with a GORE Septal Occluder	84
C24	Survived a myocardial infarction and presenting with ventricular septal rupture	86

[D] VALVES

D1	Restrictive right ventricular performance assessed by cardiac magnetic resonance after balloon valvuloplasty of critical pulmonary valve stenosis	88
D2	Valve in valve TAVI in a failing 29 mm shellhigh conduit using a 27 mm Lotus Valve	89
D3	Off pump minimally invasive treatment of severe degenerative mitral valve disease and concomitant coronary artery disease: hybrid approach	91
D4	TAVI in a late failing TAVI	93
D5	Innovative percutaneous solution to treat tricuspid valve disease	95
D6	A simplified and reproducible method to size the mitral annulus; implications for transcatheter mitral valve replacement	97
D7	Peratrial device closure of different locations of mitral paravalvular leaks using a probe-assisted delivery system	99
D8	Correlation of CoreValve implantation “true cover index” with short and mid-term aortic regurgitation; implantation depth really matters	102
D9	Angioplasty for paravalvular leak closure	103
D10	Dealing with ductal aneurysm – interventional solutions	105
D11	The forgotten Eustachian Valve	107
D12	First case of percutaneous closure of a tricuspid paravalvular leak in Sri Lanka	109
D13	Pacemaker and LIMA graft are not contraindications for transcatheter aortic valve replacement through left axillary arterial access	111
D14	Transapical mitral valve implant for the treatment of degenerated bioprosthesis	113
D15	Therapeutic challenges in treating bicuspid aortic valve	116
D16	Paravalvular leak device closure – catch me if you can	117
D17	Does patient frailty influence the use of regional or general anesthesia for trans-femoral trans-catheter aortic valve replacement?	119
D18	Percutaneous pulmonary valve implantation with Edwards SAPIEN XT in patients with native and large right ventricular outflow tract; early results	120
D19	Redo transapical off-pump NeoChord implantation to treat severe degenerative mitral regurgitation	121
D20	The alliance of structural and coronary equipment and techniques to facilitate closure of paravalvular leaks	123
D21	A novel clipping strategy in degenerative mitral regurgitation – targeting an indentation between segments P1 and P2	127
D22	Innovative solution to treat tricuspid disease	129
D23	Clinical presentation, management and outcomes of patients who developed post transcatheter aortic valve replacement thrombosis: global case series	130
D24	Procedural outcomes of percutaneous transcatheter paravalvular leak closure	131

[E] VARIOUS TOPICS

E1	Multivessel versus culprit-only revascularization for patients with ST-segment elevation myocardial infarction and multivessel disease undergoing primary percutaneous coronary intervention	132
E2	Characteristics and correlations of anatomical and functional parameters of left atrial appendage in patients with or without atrial fibrillation: a three-dimensional transesophageal echocardiography study	133
E3	Endovascular repair of petrous part of internal carotid artery in two cases	134
E4	Patient selection for a percutaneous ventricular partitioning device implantation after antero-apical myocardial infarction with left ventricular systolic dysfunction: a single center experience	135
E5	Understanding the role of 3D TEE in paravalvular leak closure	137

E6	Complication during transcatheter aortic valve-in-ring implantation in a failed mitral valve repair	138
E7	Emergency percutaneous thrombus fragmentation in a neonate with brachial artery thrombus	139
E8	Hepatic vein to atrial fistula – rare cause of cyanosis in a post operative case of Fontan surgery	141
E9	Advanced cardiovascular assessment of ventricular function with tissue motion annular displacement	142
E10	Percutaneous recanalization of a completely occluded right pulmonary artery 3 months after thromboembolism	143
E11	Multicenter experience of Impella devices in Fontan patients with systemic ventricular dysfunction	145
E12	Tunneled dialysis catheter exchange rates: analysis after a departmental switch to the Bard GlidePath	146
E13	Percutaneous left atrial appendage occlusion under monitored anesthetic care: single center one-year experience in Hong Kong	147
E14	Intentional stent fractures in children: intermediate term follow-up	148
E15	Percutaneous circulatory support with Impella devices in pediatric patients: a multicenter study	149
E16	Challenges of transcatheter interventions for congenital heart diseases in dextrocardia	150
E17	Challenges of interventions for associated lesions in cases of apical non-compaction	151
E18	Novel transcatheter intervention in cor triatriatum dexter	152
E19	Device closure in ruptured sinus valsava	153
E20	Stenting arterial shunts for adult congenital patients with single ventricle physiology	154
E21	Transcatheter interventions after Glenn anastomosis and Fontan operation in patients with univentricular heart	155
E22	The novel application of intraprocedural cardiac computed tomography for left atrial appendage occlusion	157
E23	Successful percutaneous repair of an acquired Gerbode defect	159
E24	Patient radiation exposure during interventional procedures in children and adults with congenital heart diseases – a single center experience	161
E25	Percutaneous closure of a post-surgical pseudoaneurysm of the ascending aorta	162
E26	Two center experience with novel image fusion software for 3D guidance of complex cardiac catheterizations	163
E27	Retrograde catheter occlusion of recurrent large systemic venous fistulae after CP shunt	164
E28	Transcatheter occlusion of a large pulmonary AV fistula draining into the scimitar vein in a young infant	165
E29	Stenting the left pulmonary artery after Norwood – perfection is the enemy of good!	167
E30	Transcatheter right ventricle outflow tract stenting after intracardiac repair of tetralogy of fallot	169
E31	A case of congenitally corrected transposition of great arteries: an infrequent happenstance	171
E32	Comparison of device selection for left atrial appendage occlusion using three-dimensional printing and conventional multi-slice computed tomography	173
E33	Optical coherence tomography in children offers new imaging possibilities: 2 cases of heart transplant recipients	174
E34	Stenting of totally occluded SVC	175
E35	Thrombus in the aorta – a late complication of percutaneous closure of a ruptured aneurysm of the sinus of valsava	177
E36	Percutaneous transluminal angioplasty of totally occluded left innominate vein perceived during Pacemaker lead insertion – a needle in the haystack	179
E37	Imaging of intima-media-structure of the carotid artery in childhood: normative data from a cohort of 631 children	181

MEDIUM-TERM FOLLOW-UP TREATMENT OF SEVERE NATIVE COARCTATION OF AORTA USING BALLOON ANGIOPLASTY IN YOUNG INFANTS LESS THAN ONE YEAR OF AGE

Mahdi Ghaderian / Mojdeh Gheysari
Emamhosein Children Hospital, Esfahan, Iran

BACKGROUND

The spectrum of therapeutic approaches for the treatment of native aortic coarctation has widely expanded from surgical correction to balloon angioplasty (BA) and stent implantation.

OBJECTIVE

The aim of this study was to assess the safety and efficacy of BA for native CoA therapy in infants less than one year of age.

METHODS

Sixteen patients (10 male) with discrete COA underwent BA of COA between May 2014 and May 2015 at our center. The age ranged from 23 days to 10 months (mean 4.28 ± 2.84 m) and body weight ranged from 3 to 7 kg (mean 4.76 ± 1.33 kg). Appropriate balloons (mean 6.18 ± 0.91 mm) were chosen and were inflated 2–3 times under fluoroscopic guidance. Successful outcome was defined as peak systolic pressure gradient after balloon angioplasty < 20 mmHg or decreased by more than 50% and at least 50% increase in diameter. Follow up duration was 6.0 ± 3.0 months (1–12 months).

RESULTS

The mean value of the peak-to-peak systolic pressure gradient between ascending to descending aorta significantly decreased from 48.43 ± 11.65 mmHg (range 25–65 mmHg) to 11.43 ± 8.29 mmHg (range 0–30 mmHg) ($P < 0.001$). Echocardiographic peak and mean pressure gradients decreased significantly from 58.81 ± 11.15 and 30.56 ± 6.51 before the procedure to 23.06 ± 11.75 and 12.31 ± 6.86 mmHg during follow up respectively ($P < 0.001$).

CONCLUSION

For native discrete aortic coarctation in young infants < 12 months of age percutaneous BA is a safe and effective treatment alternative to surgical approach.

THE “DOG BONE TECHNIQUE” – A NOVEL EASY AND SAFE CATHETER MANEUVER FOR AORTIC ARCH AND COARCTATION STENTING

Marinos Kantzis¹ / Kai Thorsten Laser¹ / Michael Froehle¹ / Deniz Kececioğlu² / Majed Kanaan¹ / Nikolaus A Haas²

¹ Hdz-Nrw, Bad Oeynhausen, Germany

² Ludwig-Maximilians-Universitaet, Munich, Germany

BACKGROUND

Various techniques are described to facilitate stable stent implantation in aortic arch stenosis or coarctation. We describe an alternative technique, which due to the unique appearance during stent implantation, we have named “Dog Bone Technique” (DBT).

TECHNIQUE

The stent/balloon assembly is placed proximal to the stenosis, the long sheath is retrieved to uncover the distal 20–50% of the stent. The balloon is inflated with the pressure inflator just to expand the stent slightly. Thereafter the proximal end is uncovered and partially inflated; therewith the assembly takes the typical “dog bone” shape before complete inflation and final positioning. Repositioning of the stent and control angiography is possible at each time of this procedure if needed.

RESULTS

Between 1/2010 and 12/2014 we implanted 91 stents in 87 patients (median age 12.5 years). 71 patients had typical native or re-coarctations and 16 patients had transverse aortic arch stenosis. In 38 patients (44%) a pharmacological exercise test with Orciprenaline was performed during implantation resulting in high cardiac output. In none of the patients reduction of cardiac output by adenosine or a rapid pacing of the right ventricle was required for stable stent implantation. All stents were implanted in the targeted position without any displacement using this single balloon technique. There were no acute or short-term complications detected.

CONCLUSION

DBT is a safe and feasible technique for aortic stent implantation even at high cardiac output. Other additional techniques for stent placement are not necessary to obtain a stable final position in the target region.

PERCUTANEOUS PDA CLOSURE IN A CHALLENGING PEDIATRIC CASE

Nazmi Narin / Oezge Pamukcu / Ali Baykan / Suleyman Sunkak / Kazim Uzum
Erciyes University, Kayseri, Turkey

HISTORY AND PHYSICAL

Percutaneous intervention is the method of choice for PDA closure. Invasive procedures sometimes do not go to plan. An interventionalist should take into consideration every surprise that can be faced during the procedure. We would like to share our experience of transcatheter closure of a challenging PDA.

A 70-day-old newborn weighing 2000gr consulted to cardiology for his prolonged intubation, need for oxygen and 3/6 degrees heart murmur. He was born after 24 weeks of gestation. His birth weight was 1800.

IMAGING & INDICATION FOR INTERVENTION

PDA was detected by transthoracic echocardiography. Since the patient had left ventricular overload, percutaneous closure was planned.

INTERVENTION

Both femoral venous and arterial routes were accessed. Anatomy, location and size of PDA were defined by aortography. Conic shaped PDA was seen with 2.5 mm ampulla and length was 3.5mm. The procedure was performed with fluoroscopy and transthoracic echocardiography guidance. We decided to use 4×2 ADO II Additional Size device for closure. We tried to settle the device from pulmonary side but it did not move forward. Therefore it was snared and pulled along to ductus. Then the occluder was positioned on the PDA. Control angiogram was done; no residual shunt was seen. Also it was checked whether there was a pressure gradient on pullback from ascending aorta to the descending aorta to exclude the presence of obstruction on the aortic side. We did not face any complications during procedure. First and 3rd month controls were done and there was no problem.

LEARNING POINTS OF THE PROCEDURE

An interventionalist should always be ready for bad surprises that he/she can face during invasive procedures. We wanted to share our experience. There may be problems that we can face in the cath lab. The important thing is to make logical decisions and find a solution in a short time period. It should be kept in mind that patient safety always comes first. Interventionalists should not permit the challenging cases to be their nightmares.

COARCTOPLASTY IN A CASE OF INTERRUPTED AORTIC ARCH WITH PERIPHERAL CTO TECHNIQUE

Vida Razazikhales / Mohammad Ali Ostovan / Alireza Abdi Ardekani / Pooyan Dehghani
Shiraz University, Shiraz, Iran

HISTORY AND PHYSICAL

The patient was a 24-year-old man, known case of hypertension, bicuspid aortic valve, aortoannular ectasia and coarctation of aorta (interrupted aortic arch) since 2 years. He hadn't sought any medical care until he developed chest pain and dyspnea. He was admitted to the cardiology ward. On physical examination, there were weak femoral pulses and a blood pressure difference of about 60 mmHg between arms and legs was detected. Cardiac examination was unremarkable except for systolic ejection click and S4.

IMAGING

Transesophageal echocardiography (TEE) and CT angiography of thoracic aorta were performed.

TEE showed enlarged left ventricle (LV) with moderate LV dysfunction and global LV ejection fraction of 40%. There was bicuspid aortic valve with mild aortic regurgitation without aortic stenosis associated with aortic root aneurysm with maximal diameter of 5.3–5.5 centimeters. Also severe aortic coarctation with multiple collaterals was noted.

In thoracic CT angiography, there was evidence in favor of complete coarctation and occlusion of distal aortic arch.

INDICATION FOR INTERVENTION

Because of high risk surgery for simultaneous correction of coarctation of aorta plus aortic root and aortic valve replacement (Bentall procedure), the patient was scheduled for coarctoplasty with stenting.

INTERVENTION

Aortogram was done with right radial access. Interrupted aortic arch was passed successfully with Astato XS 20 0.014" guidewire (300 cm). After predilation with noncompliant Empira 3 × 25 balloon and then Hiryu 4 × 20, stenting was done with NuMED Mounted CP Stent 8 zig 34 cm with a good result.

LEARNING POINTS OF THE PROCEDURE

Interrupted aortic arch can be treated successfully by coarctoplasty and stenting in patients who are high risk for surgery.

CLOSURE OF VERY LARGE PDA WITH PULMONARY HYPERTENSION: INITIAL CLINICAL CASE SERIES WITH THE NEW OCCLUTEC® PDA OCCLUDER

Anja Lehner¹ / Sarah Ulrich¹ / Marcus Fischer¹ / Christoph Happel² /
Marinos Kantzis¹ / Nikolaus A. Haas¹

¹ Ludwig-Maximilians University of Munich, Munich, Germany

² Heart and Diabetes Center NRW, Bad Oeynhausen, Germany

BACKGROUND

Although considered a standard procedure in most paediatric cath labs, closure of PDAs with very large diameters (PDA/Ao ratio > 0.5) remains a challenge, especially when elevated pulmonary artery pressures are present. Haemolysis across the meshwork as well as device embolization caused by elevated pulmonary artery pressure may occur. We report our recent experience with the new ODO, which was developed and modified especially for closure of those large PDA sizes.

OBJECTIVE

To assess the efficacy and safety of the new Occlutec PDA Occluder® (ODO) in transcatheter closure of large patent ductus arteriosus (PDA) with pulmonary arterial hypertension (PAH).

METHODS

The ODO was used in eight children and adolescents (age 4–16, median 10.75 years) with a body weight from 14 to 54 kg (median 21 kg) with very large PDAs and PAH: ductal length was 14.5 mm (median), there was a large ampulla (median 16.5 mm) which exceeded the diameter of the aorta (median 12.5 mm) and also large diameter of the duct (5–13 mm, median 10 mm); Median PAP before PDA closure was 61.5 mmHg and the median aortic pressure was 74.5 mmHg (PAP/Ao ratio 0.86). Four different sizes of ODO were selected: Length 6.3–16 mm (median 14 mm), size of the aortic disc 13–24 mm (median 20 mm), minimal diameter 6–14 mm (median 12 mm) and size at the pulmonary end 8–18 mm (median 15 mm). Test balloon occlusion of the PDA was performed in 5 patients in order to evaluate the decline of pulmonary artery pressure or to delineate the exact anatomy of the PDA. Before release of the device, a careful “wiggle manoeuvre” was performed to assess the stability of the implanted device especially to prove the inability to embolize to the aorta (Fig. A: The device is pulled to the pulmonary artery and pushed to the aorta: Fig. B).

RESULTS

A sufficient occlusion of the PDA was documented by angiography and/or echocardiography in all cases. Irrelevant shunting was detected in 4 cases by echocardiography on the subsequent day that did not cause any haemolysis and resolved during the follow up. Mean PAP after intervention decreased by up to 41.7% (median PAP/Ao after closure: 0.5) and decreased even further one year

after PDA closure (median RVP/RR ratio 0.36). No embolization occurred and there was no obstruction of the left or right pulmonary artery or descending aorta despite the large size of the device.

CONCLUSIONS

With the new Occlutec® PDA Occluder closure of very large PDAs and PAH is feasible and efficient. The wider pulmonary artery end of the ODO offers enhanced stability and reduces the risk of device malpositioning and embolization.

Figure A

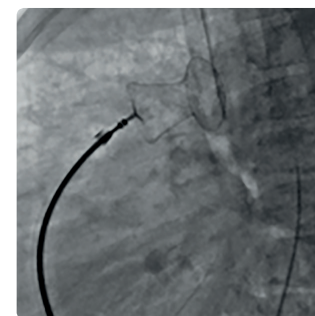
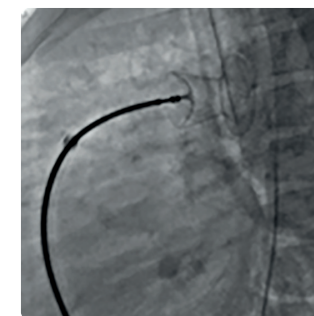

Figure B



INTERVENTIONAL RE-OPENING OF A PDA FOR REVERSE-POTT SHUNT CIRCULATION AFTER ADO-IMPLANTATION IN A CHILD

S. Schubert / B. Peters / O. Miera / M. Kanaan / F. Berger
Deutsches Herzzentrum, Berlin, Germany

HISTORY AND PHYSICAL

A 3.8-year-old ex-preterm (28th pregnancy week) male child was referred to our hospital. At age of 3 years he suffered from syncope and a PDA was diagnosed by echocardiography. PAH was diagnosed during 1st evaluation for PDA-closure and treatment with sildenafil was initiated. PDA closure was then performed 2.5 months later with an ADO I 6/8 mm (Amplatzer, SJM, USA) at a reactive PVR of 5.2 WU and PVRI 3.2 WU*BSA and sildenafil was continued. 7 months later PVR was controlled with 15.9 WU/PVRI 10.3 WU*BSA and bosentan was added. 5 months later patient again had syncope during exercise and showed deterioration of RV-function. Re-cath showed suprasystemic PAH with PVR 23 WU and PVRI 14 WU*BSA under triple therapy (Sildenafil, Bosentan, Ilomedin). Due to clinical signs of RV-decompensation re-opening of the PDA was decided together with our surgical team. Pressures prior Pott shunt were diastolic PA=78 mmHg and AO=53 mmHg, systolic PA=110 and Ao=100 mmHg. Ex-vivo perforation of ADO was performed prior intervention (figure 1). Interventional procedure was performed successfully with the same approach (figure 2). A follow up of > 6 months could be achieved already, with a post ductal saturation of 90–94% and stable clinical condition.

Figure 1:

Ex vivo simulation of stent implantation through a ADO I (6/8 mm, Amplatzer) with (A) transseptal needle, (B) wire, (C) stent (Driver 4.0 mm), (D,E) after stenting.


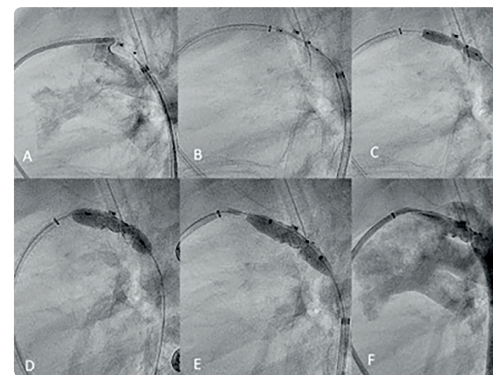


Figure 2:

Stent implantation through an ADO I (6/8 mm, Amplatzer) with (A) transseptal needle, (B,C) wire and coronary balloon (Sprinter 2 mm, Medtronic, USA and Maverick 6 mm, Boston Scientific, USA), (D) stent implantation (Palmaz blue 6/18mm, Cordis USA), (E) post dilatation with Conquest (Bard, USA) 6 mm, (F) post interventional angiography.



INDICATION FOR INTERVENTION

Suprasystemic PAH with RV decompensation (syncope during exercise) and echocardiographic signs of RV dysfunction.

INTERVENTION

Generation of a reverse Pott shunt by re-opening of a PDA via ADO I. Transseptal needle perforation through the meshes of the ADO, wire looping (AO-PA) and balloon dilatation (Sprinter 2 mm, Medtronic, USA and Maverick 6 mm, Boston Scientific, USA), stent implantation (Palmaz blue 6/18 mm, Cordis USA) and post dilatation with Conquest (Bard, USA) 6 mm.

LEARNING POINTS OF THE PROCEDURE

Pott shunt is a therapeutic option for patients with systemic or suprasystemic PAH and re-opening of a PDA might therefore be possible in order to treat RV-dysfunction with maximal medical treatment.

EARLY CLINICAL EXPERIENCE WITH THE MEDTRONIC MICRO VASCULAR PLUG™ IN CONGENITAL CARDIAC INTERVENTIONS IN CHILDREN

Shyam Sathanandam¹ / Henri Justino² / Rush Waller¹ / Wolfgang Radtke³ / Athar M. Qureshi²

¹ University of Tennessee, Knoxville, USA

² Texas Children's Hospital, Houston, USA

³ A.I. Dupont Hospital For Children, Seaford, USA

BACKGROUND

The Medtronic Micro Vascular Plug™ (MVP) can be delivered through a micro-catheter for occlusion of abnormal blood vessels. Therefore, it may be of great benefit to small children with congenital heart disease (CHD).

OBJECTIVES

To describe the early multi-center, clinical experience with MVP in children with CHD undergoing vascular embolization.

METHODS

Retrospective review of embolization procedures performed in 3 centers using MVP.

RESULTS

11 children underwent attempted occlusion of various vessels using MVP. The most common indication was for occlusion of patent ductus arteriosus (PDA) in premature neonates (n = 5), followed by occlusion of tortuous venous or arterial collaterals in patients with a bi-directional Glenn circulation (4) and 2 patients underwent occlusion of coronary artery fistulae. Median weight of the entire cohort was 3.9 kg (IQR 1.2–13.3 kg) and age was 3 months (3 weeks–3 years). Median weight of PDA patients was 1.28 kg (1.1–3.5 kg). Median procedure and fluoroscopy time for the entire cohort was 104 and 18 minutes, and 64 and 9.2 minutes, respectively, for the PDA subgroup. 10 of 11 attempted MVP placements (91%) were successful, with 1 unsuccessful PDA occlusion due to the duct being short and wide. A total of 11 MVP were successfully deployed in 10 patients (1 patient with coronary fistula received 2 MVP). There were no instances of device dislodgement or retrieval after release. Complete angiographic closure was observed in all 10 successful procedures. There were no complications related to the procedure or during follow up of 4 ± 2.7 months.

CONCLUSIONS

The MVP is a new vascular embolization device that can be delivered through a micro-catheter. Therefore, it may play an important role in providing highly effective occlusion of abnormal vessels in small children, including PDA in premature infants.

STENTING FOR AORTIC COARCTATION IN SMALL CHILDREN: ACUTE AND MID-TERM OUTCOMES

Amanda Marques Vicente / Vinicius Cogo Destefani / Marcelo Silva Ribeiro / Rodrigo Nieckel da Costa / Simone Rolim / F. Fontes Pedra / Maria Virginia Santana / Carlos Augusto Cardoso Pedra
Instituto Dante Pazzanese de Cardiologia, Sao Paulo, Brazil

BACKGROUND

The use of stents for aortic coarctation (CoA) in children presents some challenges. We sought to evaluate CoA stenting in children, with emphasis on follow up outcomes.

METHODS

Children under 30 kg who underwent stenting for CoA between April 2009 and December 2015 were enrolled. Stents expandable to large diameters were implanted. Demographic, clinical, hemodynamic and follow up data were collected retrospectively. Endpoints assessed included: gradient reduction, severe adverse events (SAE), persistent high blood pressure and need for reintervention.

RESULTS

37 patients (25 male, 27 with native CoAo) with a mean age and weight of 5.4 ± 3.4 years and 20.7 ± 11.0 kg, respectively, were included. The peak-to-peak gradient decreased from 33.7 ± 15.1 to 5.4 ± 5.3 (p < 0.001) and the ratio of the CoA/descending aorta diameters increased from 0.40 ± 0.16 to 0.95 ± 0.20 (p < 0.001). There were no immediate SAE. 34 patients were followed (43.1 ± 19.4 months). Five patients still needed medication for high blood pressure. Seven patients required percutaneous reintervention (36.1 ± 19.0 months after the index procedure) due to aortic aneurysm (1), residual stenosis (1) and adjustment for somatic growth (5). One patient required surgery due to residual hypoplasia of aortic arch (15.1 months later). All reinterventions were carried out successfully.

CONCLUSION

Stenting for CoA in children was effective. A significant rate of reintervention was observed mainly due to the need to adjust the stent diameter for the somatic growth. SAE were rare. Late dilation of previously implanted stents proved to be feasible, safe and effective.

DUCTAL CLOSURE USING VARIOUS DEVICES

Lungile Pepeta / Mahlubandile Nxele / Zongezile Makrexeni
Dora Nginza Hospital, Walter Sisulu University, Port Elizabeth, South Africa

BACKGROUND

Percutaneous patent ductus arteriosus (PDA) has become standard therapy for this congenital heart disease, with various devices available on the market.

OBJECTIVE

To compare various percutaneous PDA occluders.

METHODS

Data of patients undergoing ductal closure was collected. Demographics, haemodynamic and angiographic characteristics were documented.

RESULTS

From May 2009 to February 2016 (6 years, 10 months); 232 patients were assigned to percutaneous closure of the patent ductus arteriosus. 71 patients had closure using Amplatzer Duct Occluder II Additional Sizes (ADO II AS), 40 with Amplatzer Duct Occluder I; 40 with Amplatzer Duct Occluder II; 58 with Occlutech Duct Occluder; 9 with Ceraflex Device; 4 with Amplatzer Vascular Plug, 2 with coils and 1 with Immediate Release Patch. Patients' mean age was 9 months (range, 1 month–454 months), and weight range was 900 g (ADO II AS) to 82.6 kg (ADO II). The QP:Qs mean ratio ranged from 2.0 to 2.7. The mean ductal size ranged from 2.0 mm (ADO II AS) to 4.9 (ADO I). The majority of patients had Krichenko Type A (conical PDA). There was a total of 10 Embolizations: 2 ADO II AS; 2 ADO II; 2 ADO I; 3 ODO; 1 Ceraflex. Complete ductal occlusion was achieved in 99% of patients.

CONCLUSION

The ADO II AS is a safe and effective device for closure of small ducts even in preterm infants. In patients weighing more than 5 kg, ADO I, ADO II or ODO can be used. Vascular plugs can be used for tubular ducts.

COARCTATION STENTING IN PATIENTS UNDER 20 KG OF WEIGHT

Keyhan Sayadpour Zanjani / Aliakbar Zeinaloo / Alireza Golababaei
Tehran Childrens Medical Center, Teheran, Iran

BACKGROUND

COA stenting is controversial in small children due to the concerns of somatic growth and stent redilation. We used stents dilatable up to 18 mm for small children 10–20 kg as the primary treatment. Whenever either surgery or balloon angioplasty were not good options in a smaller child, we used stenting.

METHODS

Since April 2008, we performed COA stenting in 15 consecutive patients. The procedures were carried out as recommended in the medical literature. In patients < 10 kg, we have not used a long sheath. Palmaz-Genesis XD and Valeo stents were redilatable stents up to 18 mm. Formula and V12 stents were smaller stents used.

RESULTS

The procedure was primarily successful in all patients except one. In a longsegment COA, the stent dislodged proximally and part of COA remained unstented. Later, the stent fractured and the patient was operated. He developed a cancer later. Another Palmaz-Genesis XD was fractured and restented. In two patients 10 kg of weight femoral artery integrity was lost.

CONCLUSION

Primary COA stenting in children >13 kg is feasible and safe. For smaller children, it can be an option if the patient is high risk for surgery and balloon angioplasty is unsuccessful. We recommend stent implantation without a long sheath in patients ≤ 13 kg of weight, and minimal use of x-ray during the life.

COARCTATION STENTING IN A 60-YEAR-OLD WOMAN

Hassan Kamel
Aswan Heart Centre, Aswan, Egypt

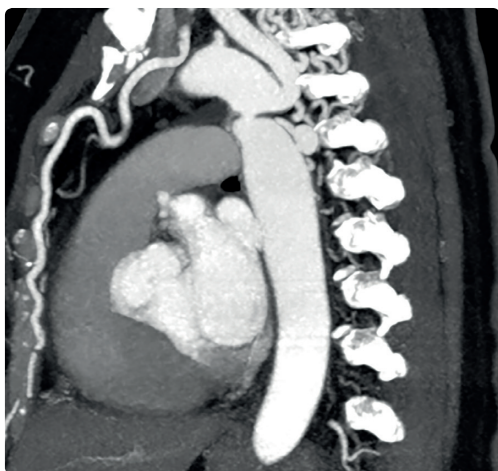
HISTORY AND PHYSICAL

A 60-year-old housewife with 3 offspring presented to her primary care physician with dyspnoea on exertion. She was found to be hypertensive (diagnosed as 1ry hypertension) and was started on anti-hypertensive drugs. Her blood pressure needed 3 medications to be controlled. Her lower limb pulses were weak on exam so a detailed echo was ordered.

IMAGING

A focal coarctation was noted with severe degree of stenosis.

CT was done and confirmed the diagnosis. An area of focal coarctation with a diameter of 5 mm, ascending aorta of 22 mm, descending aorta of 25 mm.



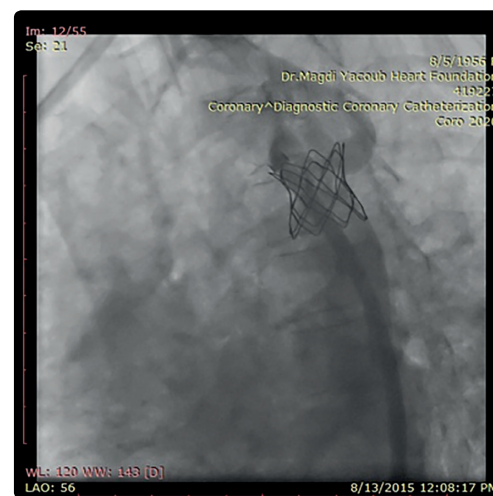INDICATION FOR INTERVENTION

Severe CoA with significant LVH
Uncontrolled hypertension

INTERVENTION

The procedure was done under general anaesthesia and fluoroscopic guidance. Carotid duplex was normal, TEE showed no plaques in aorta. Coronary angiogram showed no abnormalities. Femoral vein and artery were accessed. Using a Terumo wire the coarcted segment was crossed. Cineangiogram using a 6 Fr pigtail showed a tight 5 Mm coarctation just distal to LSCA, causing a pressure drop of 50 mmHg across with a dampened wave in abdominal aorta.

A covered stent (28 mm) was mounted over a BIB balloon (24×4). The stent was positioned across the coarctation, position was confirmed and the stent was successfully deployed.



Peak-to-peak pressure gradient was measured to be 5 mmHg. Post-deployment angiogram showed some encroachment on LSCA with good forward flow and well felt left upper limb pulses, with adequate coaptation with aortic wall.

LEARNING POINTS OF THE PROCEDURE

Search for secondary causes of hypertension
Coarctation dilatation and stenting can still be an option for older patients.

STENTING OF VERTICAL DUCT USING CAROTID ARTERY ACCESS WITHOUT SURGICAL CUT-DOWN: A SINGLE INSTITUTION EXPERIENCE

Himanshu Tyagi / Gaurav Garg / Anil Sivadasan Radha
D.N.B ASTER MEDCITY, Kochi, India

OBJECTIVE

Retrospective analysis of the feasibility, safety and suitability of carotid artery cannulation without surgical cut-down for the purpose of ductal stenting in vertical duct, in patients with duct-dependent pulmonary circulation.

BACKGROUND

Stenting of patent ductus arteriosus (PDA) is a well-known palliative technique for several years as an alternative to shunt surgery. Femoral artery approach has been a standard practice for PDA stenting and can be challenging in patients with vertical ductus.

METHODS

Records of patients who underwent PDA stenting at our institution from July 2009 to Jan. 2014 were reviewed. In this period, we attempted to do PDA stenting in 12 patients with vertical ductus using carotid artery approach. Percutaneous carotid artery cannulation was done under fluoroscopic guidance using a guidewire inside the carotid artery as landmark. Echocardiography, cardiac CT scan and colour Doppler were used for patient selection and assessment of procedural outcome.

RESULTS

Carotid artery cannulation without surgical cut-down was successful in all the 12 patients. Patients' age ranged from 25 days to 24 months and weight ranged from 2.5 to 10 kgs, with 10 amongst them below 8 months of age and 11 amongst them weighing below 6 kgs. PDA stenting could be accomplished in 11 out of 12 patients with good post-procedural outcome. Post-procedure carotid Doppler showed laminar flow in the carotid arteries, and echocardiography showed good flow across the stent into the branch pulmonary arteries.

CONCLUSION

Percutaneous carotid artery cannulation under fluoroscopic guidance is an effective and safe approach for stenting of vertical duct.

TRANSVERSE AORTIC ARCH HYPOPLASIA AND AORTIC COARCTATION – TREATING ONE AND NOT THE OTHER: GEOMETRICAL QUANTIFICATION OF AORTIC ARCH OBSTRUCTION BY 3D ROTATIONAL ANGIOGRAPHY AND MIMICS®

Atsuko Kato / Dariusz Mroczek / Shi-Joon Yoo / Rajiv Chaturvedi / Lee Benson / Kyong-Jin Lee
The Hospital for Sick Children, Toronto, Canada

BACKGROUND

Hypoplasia of the transverse aortic arch (TAA) may become the dominant obstruction after treatment of coarctation of the aorta (CoA). Three-dimensional (3D) imaging may enable better quantification of the important residual aortic arch obstruction.

OBJECTIVE

This study aimed to analyze correlation between 3D imaging measurements of the aortic arch and hemodynamic data before and after CoA intervention.

METHODS

We retrospectively analyzed 23 children with CoA who underwent 3D rotational angiography (3DRA) from 2010 to 2015. The 3DRA images were reconstructed using Mimics® (Materialize, Leuven), where continuous cross sectional area (CSA) from the ascending aorta to descending aorta (DAO) was automatically obtained. Measurements at the proximal TAA, distal TAA, CoA, and DAO obtained by 3DRA and discreet 2D diameters (2DD) were compared and correlated with clinical blood pressures.

RESULTS

Mean age was 7.4 ± 4.0 years and mean weight was 30.8 ± 16.6 kg. 14 patients had stent implantation and 7 had balloon dilation, whose pressure gradient across CoA (CoA-PG) reduced from 26 ± 12 mmHg to 7 ± 8 mmHg. CSA/BSA of CoA closely correlated with 2DD/BSA of CoA ($R=0.82$, $p<0.001$) and inversely correlated with CoA-PG ($R=-0.67$, $p<0.001$). Ratio of CSA \times length of proximal and distal TAA/CSA of DAO was associated with systemic blood pressure percentile in right arm at follow up ($R=-0.56$, $p=0.03$).

CONCLUSION

The 3D imaging provides good delineation of residual TAA hypoplasia. It provides a partial explanation for ongoing systemic hypertension and residual arch obstruction even after effective treatment of CoA.

ARTERIAL DUCT STENTING FOR REHABILITATION OF A DISCONNECTED LEFT PULMONARY ARTERY IN FALLOT'S TETRALOGY WITH ABSENT PULMONARY VALVE

Gemma Penford / Tristan Ramcharan / Oliver Stumper
Birmingham Children's Hospital, Birmingham, UK

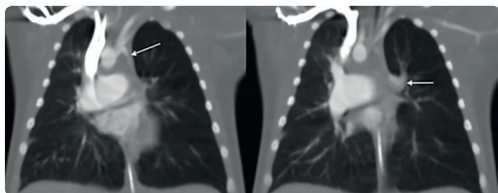
CASE HISTORY AND IMAGING

A 2.8kg female patient with an antenatal diagnosis of Fallot's tetralogy with absent pulmonary valve and right-sided aortic arch was referred to a tertiary cardiac center. The patient required invasive ventilation from birth. Echocardiography confirmed the diagnosis but the left pulmonary artery was not clearly demonstrated. A continuous flow pattern in the left chest and the suggestion of a ductal ampulla at the origin of the innominate artery raised suspicion of aberrant left pulmonary artery.

A CT angiogram demonstrated dilated right and main pulmonary arteries, the central pulmonary arteries were non-confluent, a ductal ampulla arose from the innominate artery and the faint appearance of an arterial duct supplied a slender left pulmonary artery (figure 1.). A prostaglandin infusion was commenced, restoring forward flow to the aberrant pulmonary artery. Following this, the patient was weaned off ventilation and extubated.

Figure 1

CT angiogram in coronal plane. Left hand panel arrow indicates ductal origin from the innominate artery with the stenosed duct just visible. Right hand panel arrow indicates the disconnected left pulmonary artery, visible in the hilum.



INDICATION FOR INTERVENTION

Had the patient failed extubation, high-risk neonatal complete repair, with reconnection of the left pulmonary artery would have to be attempted. Once the patient was extubated, delayed complete repair became an option. In order to avoid loss of the aberrant pulmonary artery, ductal stenting was pursued.

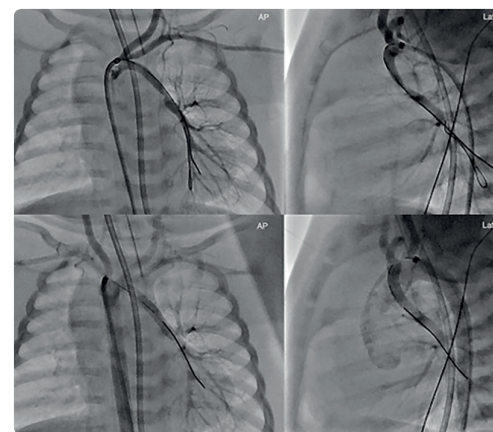
INTERVENTION

Under general anesthetic with full heparinization, a diagnostic study via the femoral arterial approach with a 4 French Judkins Right coronary catheter (Cordis, USA) confirmed the CT findings (figure 2.) A 4 French Cook Flexor (Cook Medical, USA) sheath was utilized over an 0.014" Thruway (Boston scientific, USA) with

an 0.014" BMW (Abbot Vascular, USA) buddy wire for additional stability. Two 3 mm Liberte coronary stents (Boston Scientific, USA) were deployed over the stiffer 014" Thruway, covering the entire length of the duct. Care was taken to avoid protrusion of the proximal stent into the innominate artery. Final oxygen saturations were 91%, exit angiography and echocardiography were satisfactory (figure 2.). The procedure was uncomplicated. A chest x-ray obtained within 6 hours did not show reperfusion injury. The patient was given 20 units/kg of heparin for 24 hours and has been discharged home on dual anti platelet therapy.

Figure 2

Upper panels show AP and lateral angiograms of the ductal supply of the disconnected pulmonary artery. Lower two panels show AP and lateral angiograms of the final result after ductal stenting procedure.



LEARNING POINTS

Patients with absent pulmonary valve syndrome exhibit varying degrees of airway compression and cardiovascular compromise, a proportion will require immediate intubation and ventilation. Largely, the timing of anatomic repair is dictated by the severity of airway compression and in turn, the success or failure of early extubation. If ventilatory weaning cannot be achieved, complex neonatal complete repair must be considered to alleviate airway compression. Repair may involve pulmonary artery plication, Lecompte manoeuvre or anterior pulmonary artery translocation. Furthermore, a valved right ventricle to pulmonary artery conduit may be required if pulmonary vascular resistance is still raised or if the native outflow is unsuitable for transannular patch. For patients managing to self ventilate, a period of somatic growth and time for vascular resistance to fall can be achieved, permitting lower risk, delayed primary repair.

The occurrence of disconnection of the branch pulmonary arteries in the context of absent pulmonary valve syndrome is extremely unusual. Several case reports describe such anatomy with a variety of outcomes ranging from late diagnosis at the age of 6 years, complete neonatal repair, to death in the first days of life.

The disconnected branch pulmonary artery became the dictating factor for timing of repair in the above case. An unprotected ductal origin may result in loss of a disconnected branch pulmonary artery or commit the surgeon to extensive reconstruction with non-native graft material. Alternately, sustained ductal flow can potentiate 'down-stream' growth, simplifying the restoration of confluent central pulmonary arteries at repair.

Ductal stenting offered an attractive, effective option in this unusual setting, allowing the patient to be discharged home to await a lower risk, deferred repair.

Care should be taken to avoid proximal protrusion causing jailing of neighboring systemic arteries when stenting this type of ductal morphology, this measure also facilitates safe re-intubation of the duct, should re-dilation be required.

PDA CLOSURE WITH CERAFLEX™ OCCLUDER: IS THERE ANY ADDITIONAL BENEFIT?

Ahmet Celebi / Ilker Kemal Yucel / Orhan Bulut / Sevket Balli / Emine Hekim Yilmaz / Mehmet Kuecuk
Dr. Siyami Ersek Hospital, Istanbul, Turkey

BACKGROUND

Ceraflex PDA occluder is a new device with similar properties to Amplatzer Duct Occluder (ADO) Device. It is made of knitted nitinol wire mesh similar to ADO except that all metallic structures are plated with TiN bioceramic coating. Device comes preassembled with the delivery cable by a loop connection through the holes and ready to load via the loader on the delivery cable. The loop made of surgical thread allows the device to be flexible in 360° direction and fit to the ductal shape before releasing.

OBJECTIVE

The aim of this study was to evaluate the feasibility, safety, and efficacy of this new device.

METHODS

21 patients underwent transcatheter closure with Ceraflex PDA occluder from November 2015 to February 2015. Decision for device size selection was based on the narrowest diameter of the PDA according to the manufacturer recommendation as the aortic end of the occluder shank to be at least 1.5–2.0 mm larger than the narrowest diameter of the duct. Angiogram was performed to confirm the device position and evaluate residual shunt just before and after the releasing the device. Patients were followed up by clinical examination and echocardiography.

RESULTS

The median age of the patients was 1.2 years (6 months to 28 years) and median weight was 9.6 kg (5.4 to 82 kg). 11 patients were under one year old and 11 had pulmonary hypertension (mean PA pressure > 25 mmHg). All patients had continuous cardiac murmur on examination and all PDAs were type A. Narrowest PDA diameter at pulmonary side was 4.1 ± 1.7 mm (2.2–8.2 mm, median 3.8 mm). Intervention was successful in all. Final angiogram after ten minutes showed complete closure in 17/21 of them. Echocardiography achieved complete occlusion in all on the next day. In a patient with Down syndrome PDA was closed with 4/6 mm device, and device embolized to descending aorta after persistent cough 24 hours later. Then device was snared via femoral vein approach and closed with 6/8 mm device. None of the patients showed evidence of stenosis at branch pulmonary artery and descending aorta by echocardiography during the follow up.

CONCLUSION

Our early preliminary results showed us Ceraflex DO is a safe and efficacious device in closure of moderate to large PDA's in children, adolescents and adults whose duct morphology fit to the ADO I. Its uniquely designed delivery/releasing system has an advantage in view of not applying tension to the device which provides the device in stable position and not changing the device position during and immediate after the releasing. This unique feature may give us an opportunity to be sure that the device does not protrude to the aorta after releasing, which may cause iatrogenic aortic coarctation and is the most frightening complication in infants that have small descending aorta. Major disadvantage of this device when compared to the ADO is that it needs higher profile long sheaths.

TRANSFEMORAL APPROACH FOR PDA CLOSURE IN A PATIENT WITH AZYGOS CONTINUATION OF THE INFERIOR VENA CAVA WITH THE ADO II DEVICE WITHOUT ARTERIO-VENOUS LOOP

Marinos Kantzis¹ / Deniz Kececioglu¹ / Maged Kanaan¹ / Nikolaus A. Haas²

¹ Hdz-Nrw Bad Oeynahusen, Germany

² Ludwig-Maximilians-Universitaet, Munich, Germany

BACKGROUND

Patent arterial duct (PDA) closure is a common and established interventional procedure indicated for patients with either left sided volume load or signs of heart failure. Since the first nonsurgical closure was performed by Porstmann in 1974, many different devices have been used and specifically designed usually by a direct transfemoral pulmonary or aortic approach. We are reporting the closure of a hemodynamic relevant window type arterial duct via a transfemoral vein approach but through an azygos continuation of an interrupted inferior caval vein (IVC).

TECHNIQUE

Eight month old infant (6.65 kg, 69 cm) with signs of volume overload of the left ventricle (Left ventricle end-diastolic pressure of 16 mmHg) and normal pulmonary pressure underwent cardiac catheterization for the closure of a window type PDA. Angiography of a right-sided big vein revealed an azygos continuation of the IVC. Angiography in the descending aorta delineated the anatomy of the PDA, which was measured 3 mm at the narrowest diameter. After failure of stable transaortic placement of the device, a 6 F wedge pressure catheter (Arrow inc.) (Image 1) and a normal exchange guide wire of 0.035 inches were used to approach the PDA from the pulmonary side. A long PDA delivery catheter (AGA) was introduced through the femoral vein across the azygos vein, the superior vena cava and the pulmonary artery and then delivered into the descending aorta. An Amplatzer Duct Occluder ADO II 4/4 was used for the closure of the duct because of the window type anatomy (Image 2). PDA closure was successful without any complications and the infant was discharged two days later.

DISCUSSION

According to our knowledge of literature there are only 7 reported other cases of PDA and interrupted IVC. All patients were older than our patient and in four cases ADO and in 3 ADO II devices were used. In four cases the PDA was approached through the femoral vein using a loop technique, in one case (adult patient) the antegrade approach through the artery was chosen and in one case the approach was succeeded from the internal jugular vein. In one case the side of approach was not made clear. In our case, we have used the femoral vein to approach and close the PDA without using loop technique – enabled by the soft delivery catheter of the device.

CONCLUSION

Antegrade PDA closure via an azygos continuation of the IVC without the establishment of a loop with femoral artery is feasible although the ADO II device may give the option of a retrograde approach.

Image 1

A 6 F wedge pressure catheter is used to approach the main pulmonary artery and then a long exchange wire is positioned in the descending aorta.

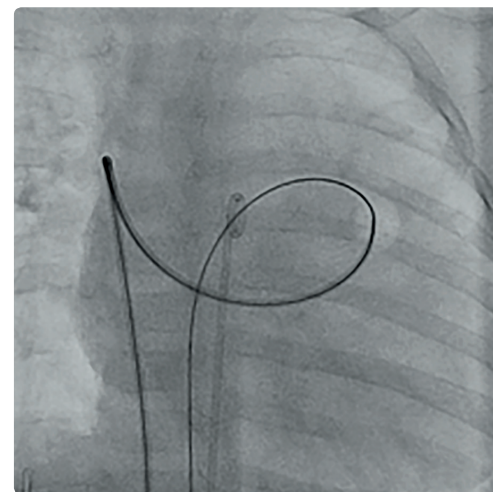
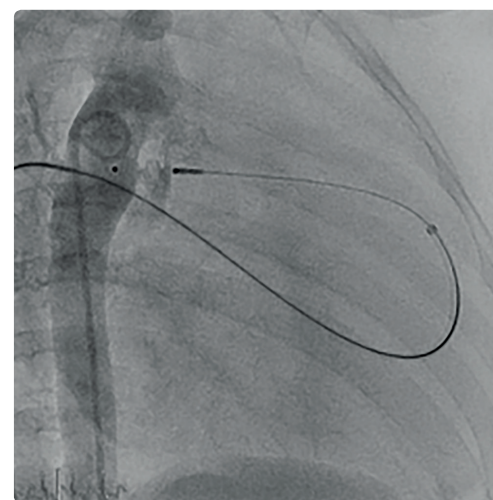


Image 2

Angiography with a pig tail catheter to delineate the good position of the occluder in the aortic ampulla and the pulmonary artery.



CHALLENGING CASES OF CHD TRANSCATHETER INTERVENTION

Akbar Molaei

Tabriz Medical University of Medical Sciences, Tabriz, State of East Azerbaijan, Iran

CASE 1

The patient was a 14-day-old premature infant with 2.2 kg of body weight. She was referred to our center with poor feeding, cyanosis and respiratory distress. After primary evaluation the diagnosis of critical pulmonary valve stenosis and atrial septal defect with right to left shunt in association to right heart failure was made and she underwent prostaglandin E1 infusion. In favor of pediatric cardiology team the infant was a candidate for percutaneous pulmonary valvoplasty.

In the catheterization laboratory the vascular access of both femoral and right jugular and subclavian veins was unsuccessful, therefore we punctured the left internal jugular vein and did the procedure via innominate vein. Because of non-straight forward pathway, the dilation of the right atrium and ventricle and severe tricuspid valve regurgitation, the procedure and fluoroscopy times were long, about 60 and 20 minutes respectively. The radiation dose was 14 mGY (48.3 $\mu\text{GY}/\text{m}^2$).

This is our issue: which procedure is feasible for such patients? Percutaneous procedure or open heart surgery?

CASE 2

The patient was an 8-year-old boy with a continuous murmur at lower LSB which was discovered at routine examination for school sport team. Transthoracic echocardiography revealed significant dilatation of left coronary artery origin and continuous flow into right ventricle.

The CT angiography confirmed the diagnosis of coronary fistula to right ventricle and huge tortuous aneurysm of left circumflex coronary artery (LCX). The patient was a candidate for transcatheter aneurysm closure by occluder devices.

The course of the procedure was complex and the crossing of the fistula by long sheet was unsuccessful, so the fistula was occluded by multiple PFM coils at multiple levels.

CASE 3

The patient was a 48-year-old male with systemic hypertension and severe coarctation of the aorta (COA). The COA was confirmed by CT angiography with post stenotic dilation.

The patient was a candidate for percutaneous transcatheter angioplasty. During the procedure the crossing of the stenotic site via retrograde pathway was unsuccessful. The right transradial ante grade route was established, the stenotic site was crossed and the angioplasty of COA was performed by CP 8 ZIG stent and BIB balloon successfully.

TWO CENTRE EXPERIENCE WITH VESSELNAVIGATOR FOR 3D GUIDANCE OF PERCUTANEOUS PULMONARY VALVE IMPLANTATION

Goreczny Sebastian¹ / Dryzek Pawel¹ / Lukaszewski Maciej¹ / Moll Jadwiga Anna¹ / Moszura Tomasz¹ / Nordmeyer Sarah² / Kuehne Titus² / Berger Felix² / Schubert Stephan²

¹ Polish Mother's Memorial Hospital, Lodz, Poland

² Deutsches Herzzentrum Berlin, Berlin, Germany

INTRODUCTION

Recent improvements in the development of fusion imaging software have led to the introduction of a 3D roadmap based on preregistered Computed Tomography (CT) or Magnetic Resonance (MR) datasets for live guidance of transcatheter interventions. We describe our initial experience with recently available image fusion software for live guidance of percutaneous pulmonary valve implantation (PPVI).

METHODS

We performed a retrospective review of all PPVIs guided with VesselNavigator (Philips) at two reference centres. Patient characteristics and catheterization data were reviewed with focus on fusion of pre-intervention imaging and intervention guidance.

RESULTS

Between 11/2015 and 03/2016, VesselNavigator was applied in 7 patients for live guidance (n=6) or planning (n=1) of PPVI. The median age was 16 years (7.7–64 years) and median weight was 68 kg (29–116 kg). A three-dimensional roadmap was created either from existing CT (n=4) or MR (n=3) datasets. For registration and fusion of the overlay, fluoroscopy images were acquired in 2 projections with calcifications (n=4), spine/vertebrae (n=3), test angiography (n=3) or previously placed artificial mitral valve (n=1) serving as reference points for orientation of the 3D roadmap against live fluoroscopy. Accurate overlay was achieved in all 6 patients without the need for intra-procedural realignment. The median radiation dose was 6498 $\mu\text{Gy}^*\text{m}^2$ (2545–24291 $\mu\text{Gy}^*\text{m}^2$) and the median fluoroscopy time was 32.1 min (5.3–46.4 min).

CONCLUSIONS

With intuitive segmentation and easy fusion with live fluoroscopy, VesselNavigator allows shortening of the diagnostic phase of the procedure and facilitates pulmonary valve placement.

TRANSCATHETER IMPLANTATION OF THE EDWARDS SAPIEN XT AND SAPIEN 3 VALVES: OPTIONS FOR TREATMENT OF RIGHT HEART VALVULAR LESIONS – A TWO CENTER EXPERIENCE

S. Schubert¹ / M. Kanaan¹ / J. Nordmeyer¹ / A. Eicken² / F. Berger^{1,3} / P. Ewert^{2,4}

¹ Deutsches Herzzentrum Berlin, Germany

² German Heart Center Munich, Germany

³ DZHK (German Centre for Cardiovascular Research), Berlin, Germany

⁴ Munich Heart Alliance, DZHK, Munich, Germany

BACKGROUND

Percutaneous valve implantation (PVI) has become an attractive alternative to open heart surgery for right sided valvular lesions in congenital and acquired heart disease. We retrospectively analyzed our patients with implantation of the Edwards SAPIEN XT™ and SAPIEN 3 transcatheter heart valve in pulmonary and tricuspid valve position.

METHODS

Between 01/2012 and 2/2016, 39 patients received the Edwards SAPIEN XT or Sapien 3 valve in either pulmonary (n=27/39; 69%) or tricuspid position (n=12/39; 31%). Median age was 37 (13–78) years and median body weight 80 (31–122) kg. Valves were implanted with a 14–18 French eSheath™: Novaflex+ (n=17; 44%), Commander (n=21; 54%) or transapical Certitude (n=1; 2%) system with Femoral approach in 37 (90%) of patients. Pre-stenting was applied in 21 patients, all in pulmonary position; the remaining 18 patients received a valve-in-valve procedure without pre-stenting, in tricuspid position in 12 patients.

RESULTS

The procedure was successful in all patients (100%) without any serious peri-interventional complication. Paravalvular leakage from the original tricuspid valve required occlusion with a vascular plug 2 months after Sapien XT implantation in one patient. All but one implanted valves showed excellent function without re-intervention or explantation during follow up and with improvement of clinical status in all patients during a median follow up of 1.5 (0.1–3.4) years.

CONCLUSION

“Off-label” use of the Edwards SAPIEN XT™/3 for right sided heart valve diseases is technically feasible and safe. They are extending the application range for pulmonary PVI in structural and congenital heart disease in patients with larger sized target regions. These findings need to be confirmed by further clinical multicenter trials and longer follow up.

A RARE CAUSE OF CYANOSIS IN A PREVIOUSLY OPERATED CONGENITAL HEART DISEASE

J. Pimenta¹ / S. Granja¹ / J.L. Zunzunegui² / J. Moreira¹ / J.C. Silva¹

¹ Centro Hospitalar Sao Joao, Porto, Portugal

² Hospital General Universitario Gregorio Marañon, Madrid, Spain

CASE

We present the case of a girl prenatally diagnosed with truncus arteriosus type I, who underwent surgical correction when three months old (right ventricle [RV] to pulmonary artery [PA] homograft of 15 mm). In the follow up, progressive right ventricle outflow tract stenosis was verified, with no other residual lesions. At the age of ten, she went to the emergency department due to a febrile respiratory infection with thoracic pain. On the physical examination, she presented cyanosis, partially responding to supplementary oxygen (peripheral oxygen saturation [SpO₂] from 83% to 93%), a systolic murmur 3/6 in the left sternal border, with normal respiratory sounds and no other pathological findings. The laboratory data (D-dimers included) and chest x-ray were normal. In order to exclude pulmonary embolism or other causes of cyanosis, an angioCT scan was performed. It showed moderate stenosis of the RV-PA conduit and a vascular structure draining into the left atrium. A contrast echocardiography with injection of contrast in the left radial vein showed immediate filling of left atrium, with small amount of bubbles reaching the right chambers. The hypothesis of a left superior vena cava (LSVC) draining into the roof of the left atrium and connecting to the right sided cava was confirmed through cardiac catheterization. In order to correct the desaturation, an Amplatzer Vascular Plug II of 16 mm was placed in the LSVC. In the control angiography the occlusion of the hemiazygos vein by the device was noticed, which motivated its removal. A second procedure was performed: to relieve the RVOT obstruction, a 20 mm Melody transcatheter pulmonary valve was implanted; an Amplatzer Duct Occluder I of 16 × 14 mm was also placed in the LSVC. At the end of the procedure the pulmonary valve was competent, the Amplatzer device was well placed and the SpO₂ went up to 100%. The next day, the patient's saturations were around 90%. The chest x-ray and cardiac ultrasound showed the embolization of the venous device into the abdominal aorta. An urgent percutaneous removal of the ADO® was successfully performed with the ADO delivery system and a 10Fr sheath. No further percutaneous attempts were made. The surgical ligation of the LSVC was done. At the moment the patient is asymptomatic, with no cyanosis and presents a well-functioning Melody valve.

CONCLUSION

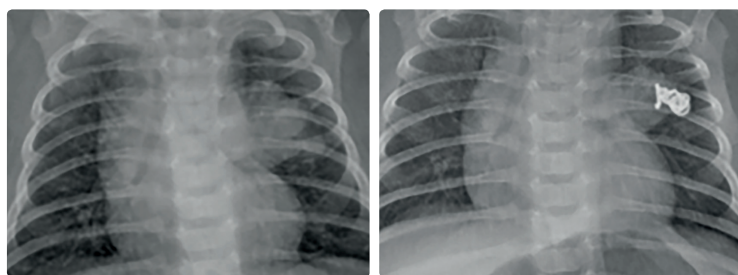
The diagnosis of a LSVC draining to the roof of the left atrium represents a rare cause of desaturation. In this case, the complexity of the major heart defect (truncus arteriosus) associated with the absence of indirect echocardiographic findings (like the dilation of the coronary sinus) could explain the delay in the diagnosis. Respecting to the treatment, the percutaneous approach to both lesions would have been the ideal solution. The embolization of implanted devices is a well-known risk and, as it was the case, urgent management techniques for its removal is mandatory.

PERCUTANEOUS CLOSURE OF PULMONARY ANEURYSM

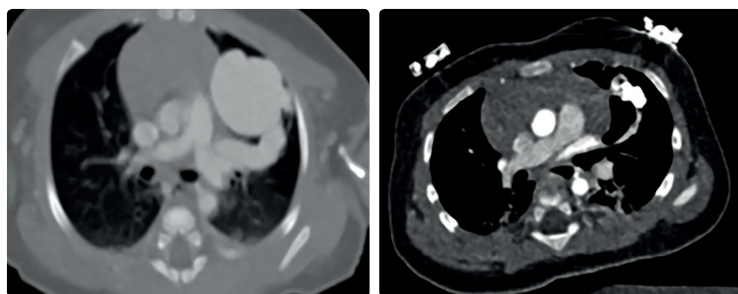
Sherien Abdelsalam Mohamed
Magdi Yacoub Hospital, Aswan, Egypt

We will describe percutaneous closure of two cases of pulmonary aneurysm.

The first case was a 35-day-old neonate that was discovered to have the aneurysm in the neonatal intensive care unit because of respiratory distress. He weighed 3.5 kg and he had a systolic murmur over the parasternal area. His saturation was 92%. The chest radiography showed abnormal shadow of a cystic structure outside the borders of the heart in the left lung. Echocardiography showed a big cystic 23×20 mm structure related to the left pulmonary artery with swirling of blood inside it. Multislice computerized tomography showed a large pulmonary arteriovenous malformation 23×17 mm in size with feeding vessels from the left lower pulmonary artery with an entrance of around 4 mm. It drained directly to a left lower pulmonary vein.



Figures 1a and b show the CXR of the patient before and after closure.



Figures 2a and b show the contrast enhanced tomography of the aneurysm with the feeding vessel before and after closure.

The cyst was closed percutaneously using two coils to embolize the feeding vessel. A 4 Fr MP catheter was introduced along a Terumo wire into the main PA then LPA. Using a BMW wire the feeding vessel was successfully engaged. The 4 Fr MP catheter was exchanged for a 5 Fr MP catheter. A PFM 6×5 coil was chosen and loaded. The coil was deployed at the junction of the feeding vessel and the mass angiography showed some residual flow, so another coil (PFM, 5×4) was loaded and deployed in the middle part of the feeding vessel. A repeat angiography showed minimal residual flow.

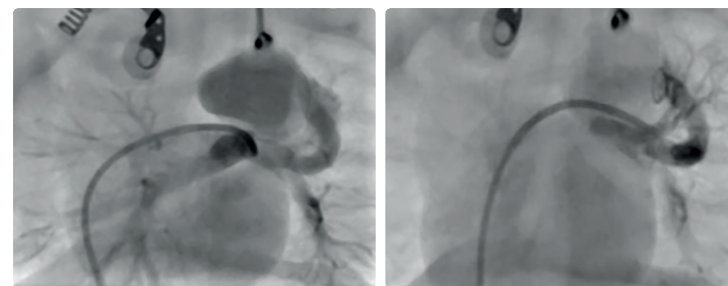
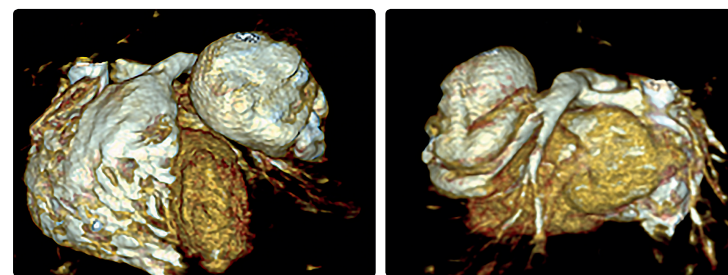
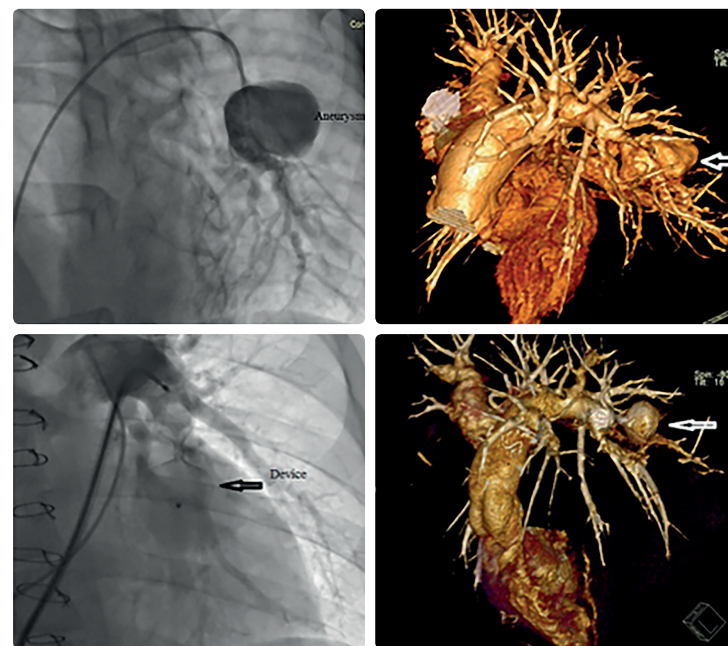


Figure 3a and b showing the angiography before and after embolisation of the feeding vessel.



The second case was a 26-year-old male patient who had recently undergone a resection of a mass in right ventricular outflow tract after presenting with shortness of breath and haemoptysis. Preoperative transthoracic echocardiography revealed a large mass in the wall of RVOT. Contrast enhanced tomography revealed an aneurysm 4×3.5 cm in the left lung.



So the aneurysm was embolised using a 24 Amplatzer septal occluder pushing the left disc to the sac and the right disc in the neck of the sac. Follow up after 6 months showed thrombosed and shrunken sac beside the disappearance of the haemoptysis attacks.

A CASE OF PERCUTANEOUS MODIFIED BLALOCK-TAUSSIG SHUNT DOWNSIZE WITH STENT-IN-STENT TECHNIQUE

Natalia Yashchuk¹ / Malgorzata Szkutnik² / Roland Fiszer² / Jacek Bialkowski²

¹ Amosov National Institute of Cardiovascular Surgery, Kiev, Ukraine

² Congenital Heart Diseases and Pediatric Cardiology Department Medical University of Silesia, Zabrze, Poland

INTRODUCTION

Pulmonary overcirculation is a common complication related to inadequate size of system to pulmonary shunt. There are several surgical solutions for too big shunt described, these include; shunt replacement, shunt banding and placing reversible haemostatic clip. But, to our best knowledge not a single interventional technique of reducing systemic to pulmonary shunt size has been publicized. We are presenting a complex case of percutaneous downsizing modified Blalock-Taussig shunt with stent-in-stent technique in a staged repair of a single ventricle.

HISTORY AND PHYSICAL

A 16-year-old girl with single ventricle, pulmonary artery atresia and great arteries malposition after several paliative surgeries and interventions. At the age of 4 years her pulmonary circulation was separated – right pulmonary artery connected with superior vena cava (hemi-Fontan operation) and left supplied from left modified Blalock-Taussig shunt (LBT). During admission she was extremely cyanotic (saturation < 40%) and total occlusion of her LBT was diagnosed. The occluded LBT was replaced surgically by 8 mm Gore-Tex tube. The saturation increased up to 95%. But a few days later she suffered continuous massive pleural effusion, exercise intolerance and desaturation to 45% on an oxygen mask. Chest X-ray showed total left lung opacity.

INDICATION FOR INTERVENTION

It was clear that the left sided shunt was too large. Surgery used to be the only option for patients with pulmonary overcirculation due to inadequate shunt size. But 7th surgical intervention in our opinion was too risky for the patient. Decision was made to place 4 bare metal stents (Genesis XD) into the shunt in order to reduce internal lumen of LBT, during catheterization. Control angiography confirmed proper devices position.

IMAGING

Figure 1

Angiography in PA projection – visible large (8 mm in diameter) shunt (gore-tex tube) between left subclavian artery and left pulmonary artery. Arrow indicates the position of ADO closing connection between right pulmonary artery and right atrium.

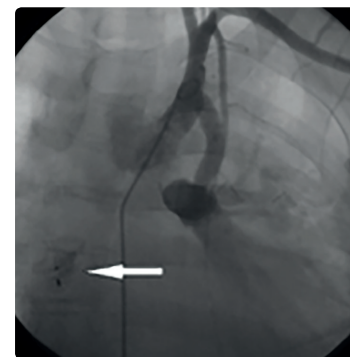
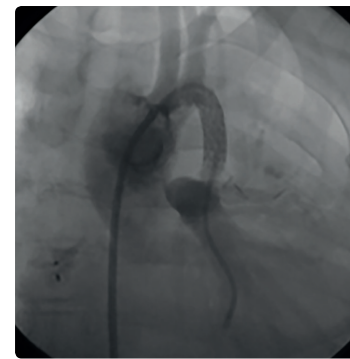


Figure 2

Angiography through the side arm of Mullins sheath. Visible 4 stents inside gore-tex tube reducing the flow in the shunt.



Next day TTE showed that peak gradient across the shunt increased from 10 to 25 mmHg. Saturation increased from 45 to 60% without oxygen, left pleurotorax as well as heart failure disappeared. The 5 months follow up showed that the girl keeps steadily improving. In control catheterization realized 4 months later MPAP in LPA was 42 mmHg.

LEARNING POINT OF THE PROCEDURE

Several bare metal stents implantation to reduce pulmonary overcirculation due to excessive BT shunt seems to be recommendable technique.

BRONCHIAL COMPRESSION BY MASS EFFECT FOLLOWING PULMONARY ARTERY STENTING IN SINGLE VENTRICLE LESIONS: ITS PREVENTION AND DECOMPRESSION

Jochen Grohmann / Brigitte Stiller / Rene Hoehn / Johannes Kroll
Universitäts-Herzzentrum Freiburg, Freiburg, Germany

BACKGROUND

In single ventricle (SV) lesions the branch pulmonary artery (PA) is predominantly affected by compression behind a prominent neo-aortic root. Stent-implantation to treat PA stenosis is a standard procedure with proven long-term follow up. However, ipsilateral airway compression by mass effects is probably an underestimated phenomenon.

OBJECTIVE

To assess bronchial compression during pulmonary artery (PA) intervention.

METHODS

Single-center retrospective analysis of 19 SV patients with branch PA stenosis and close proximity to the ipsilateral main bronchus who underwent cardiac catheterization at a median age and weight of 8.5 years (0.5–25) and 16.5 kg (6–82) between 12/2011 and 05/2015.

RESULTS

Two of the 19 patients suffered from an almost-closed left-main bronchus (LMB) following PA stenting. Fortunately, LMB decompression succeeded in both affected patients by re-shaping the PA-stents via chest compressions while splinting the LMB with an inflated balloon. Thus, to prevent the other 17 patients from this serious complication, we shifted to a thorough preparation strategy: in 13 patients consistent impact assessment was safely performed by simultaneous bronchoscopy and cardiac catheterization. In the remaining 4 patients CT-angiography permitted a proper risk evaluation prior to re-catheterization.

CONCLUSION

Our experience supports thorough preparation via pre-interventional cross-sectional imaging and bronchoscopic guidance during intervention in order to prevent bronchial deterioration. In SV lesions with prominent neo-aorta and branch PA stenosis, test ballooning is mandatory to rule out any airway compression before considering endovascular stent implantation in selected patients. If stent compression has already caused severe bronchial obstruction, the balloon-splinted-decompression should be considered. If decompression fails, redo-surgery must be considered (resection of peribronchial scar tissue, downsizing and elongation of a space occupying neo-aorta, etc.).

ROTATIONAL ANGIOGRAPHY AND 3D RECONSTRUCTION BEFORE MELODY VALVE POSITIONING

Isaac Martinez Bendayan
Hospital A Coruna, A Coruna, Spain

INTRODUCTION

A correct analysis of the right ventricle outflow tract (RVOT), pulmonary trunk and pulmonary branches is mandatory to plan the proper positioning of a prosthesis in the pulmonary position.

MATERIAL AND METHODS

Rotational angiography and 3D reconstruction data was analyzed in all 8 patients who underwent percutaneous implantation of a Melody valve in our institution. Technical issues were contrast volume, quality of the 2D image, quality of the 3D reconstruction and correlation between 2D and 3D measurements. Anatomical issues were measurements of the RVOT, distance between the area of implant and the origin of the pulmonary branches, and particular information from each case.

RESULTS

Diagnostic catheterization was previously performed in 6 cases and during the implant in the other 2. The average of volume needed was $0.91 (\pm 0.14)$ ml/kg at an average flow of $0.22 (\pm 0.03)$ ml/kg/sec. Based on a scale of 0 to 3, the average quality was $2.6 (\pm 0.41)$ for the rotational angiography and $2.0 (\pm 0.63)$ for the 3D reconstruction. The difference between equivalent measurements in 2D and 3D was $0.8 (\pm 0.76)$ mm.

The minimum diameter average of the RVOT was $12.1 (\pm 2.8)$ mm in 2D and $11.5 (\pm 4.7)$ mm in 3D reconstruction; usually the narrowest area run into the area of the ring; the distance between the planned area of implant up to the branch division was $33 (\pm 7.5)$ mm. In 2 cases the diagnosis of branch stenosis allowed planning pretreatment of these. Also additional data as dilation of the infundibulum, the presence of folds and angles of the conduits and its relationship with the sternum were very important in each particular case.

CONCLUSIONS

A better analysis of pulmonary anatomy can be achieved with a single rotational angiography, practically with the same volume of contrast as a conventional angiography. 3D reconstruction is reliable and gives additional information of the pulmonary anatomy.

ACCURATE HEMODYNAMIC EVALUATIONS BEFORE AND AFTER FONTAN COMPLETION BY PHASE-CONTRAST CARDIAC MRI AND CATHETERIZATION

Hirota Oki / Hiroyuki Yamada / Naofumi Sumitomo / Kouichi Miyata / Naoya Fukushima / Masaru Miura / Kazuhiko Shibuya / Masatsugu Terada / Yukihiro Yoshimura / Gen Nishimura
Tokyo Metropolitan Children's Medical Center, Tokyo, Japan

BACKGROUND

Cardiac catheterization (CC) has served as a conventional hemodynamic evaluation tool in patients before and after Fontan completion, but oximetry is questionable from the viewpoint of applying the Fick principle for patients with ubiquitous aortopulmonary collaterals (APC).

OBJECTIVE

The primary aim is to compare conventional oximetry-derived estimates with new measurements obtained by combination of phase-contrast MRI flow analysis and CC pressure studies. The secondary aim is to examine whether these measurements are useful as predictive indicators for prognosis and evaluation indicators of treatments.

METHODS

101 sessions of MRI and CC were performed in the same admission from 2009 to 2015, including 42 sessions before Fontan completion after Glenn procedure and 59 sessions after Fontan completion. Phase-contrast MRI flow analyses were performed in each pulmonary vein, right/left pulmonary arteries, ascending/descending aorta, superior/inferior vena cava. Pulmonary blood flow (Qp) = total pulmonary veins. Systemic blood flow (Qs) = total systemic veins. APC = the mean of total pulmonary veins – total pulmonary arteries (direct method) and ascending aorta – total systemic veins (indirect method). Pulmonary vascular resistance (Rp) = transpulmonary pressure gradient (CC)/Qp (MRI). Hemodynamic data were compared between 31 sessions of patients with assistance of pulmonary vasodilators or home oxygen therapy and 70 sessions of patients with no assistance. 42 sessions performed before and after Fontan completion in 21 patients were compared to evaluate the effectiveness of coil embolization for APC.

RESULTS

Qp (MRI) 3.57 ± 0.96 l/min/m², Qp (CC) 2.26 ± 0.60 l/min/m². Qs (MRI) 3.20 ± 0.77 l/min/m², Qp (CC) 3.26 ± 1.17 l/min/m². Rp (combined MRI/CC) 3.57 ± 0.96 l/min/m², Rp (CC) 2.26 ± 0.60 l/min/m². Qp (MRI) was significantly higher than Qp (CC), and Rp (combined MRI/CC) was significantly lower than Rp (CC) (Wilcoxon test, $p < 0.0001$). The difference between Qp (MRI) and Qp (CC) was correlated with APC (Pearson test, $r = 0.554$, $p < 0.0001$). APC and Rp (combined MRI/CC) were significantly higher in sessions with patients with assistance of pulmonary vasodilators or home oxygen therapy (Mann-Whitney test, $p < 0.0001$). APC was significantly decreased after coil embolization (Wilcoxon test, $p = 0.01$).

CONCLUSION

Conventional oximetry methods are unreliable because of ubiquitous APC before and after Fontan completion. New methods with phase-contrast MRI and CC pressure studies can make more accurate evaluations possible. Quantitative evaluation of APC is useful to estimate prognosis and to evaluate treatments.

PATENT DUCTUS ARTERIOSUS MORPHOLOGY IN DUCTAL DEPENDENT PULMONARY CIRCULATION – HOW DOES COMPUTED TOMOGRAPHY ANGIOGRAPHY HELP?

Anu Ratha Gopal / Haifa Abdul Latiff
Institut Jantung Negara, Kuala Lumpur, Malaysia

BACKGROUND

Patent ductus arteriosus (PDA) stenting is an accepted mode of palliative treatment in duct dependent pulmonary circulation. Morphology of PDA in ductal dependent congenital heart defects (CHD) is diverse and varies according to the lesion. A good understanding of the morphology is crucial for interventional procedures i.e: patent ductus arteriosus stenting. Computed tomography angiogram (CTA) is a non-invasive imaging modality to assess the PDA.

OBJECTIVES

The objectives of this study are to assess the morphology of PDA in duct dependent pulmonary circulation, to determine the PDA pattern in different ventricular morphology and to assess the impact of PDA morphology on the initial palliative treatment.

METHODS

From January 2013 to July 2015, CTA was performed in all patients diagnosed to have ductal dependent pulmonary circulation to assess suitability for PDA stenting as primary procedure. The inclusion criteria were patients less than 6 months of age. All CTA were performed using a 64 slice dual source CT scanner.

The following parameters of the PDAs were evaluated

- i) Number of PDAs
- ii) Sidedness of aortic arch
- iii) Site of origin and site of insertion
- iv) Tortuosity of PDA
- v) Stenosis of branch Pulmonary artery

PDA pattern in different ventricular morphology, i.e: univentricular, biventricular and pulmonary atresia with intact ventricular septum (PAIVS) were assessed. Impact of the PDA morphology to determine the mode of treatment and outcome were evaluated. P value of <0.05 was considered as significant.

RESULTS

A total of 100 patients, aged between 2 days to 6 months were recruited. Weight ranges from 2 kg to 6.9 kg. The study was successful in all patients. 69% were on I.V Prostaglandin infusion to maintain duct patency. 22 (22%) patients had PAIVS, 47 (47%) had biventricular lesions and 31 (31%) had univentricular lesions. 13 (13%) patients had PDA arising from descending aorta, 66 (66%) had PDA origin from distal arch, 13 (13%) had PDA from proximal arch. 7 (7%) had PDA

originating from either right or left subclavian artery. Site of insertion was left pulmonary artery (LPA) in 53 (53.5%), right pulmonary artery (RPA) in 18 (18.18%) and main pulmonary artery (MPA) in 28 (28.28%). One patient had bilateral PDA.

Tortuous PDA deemed not suitable or challenging for stenting was noted in 20 (20%) patients. The relationship of branch PA stenosis and PDA insertion was statistically significant with a p value < 0.05.

PDA morphology study had an impact on 82 patients in determining mode of treatment or site of Blalock-Taussig shunt placement. Tortuosity of PDA and branch PA stenosis are determining factors for suitability of PDA stenting and this is statistically significant. Mean radiation dose was 1.36 m Sev and mean scan time were 2.48 seconds.

CONCLUSION

Imaging the PDA is of paramount importance in interventional arena. It has impact on the feasibility and technique of PDA stenting. CTA in infants is non-invasive, safe and clearly demonstrates the PDA morphology. We recommend CTA in all patients with duct dependent pulmonary circulation as a tool to strategize the mode of initial palliative treatment to avoid unnecessary invasive cardiac catheterization.

PERCUTANEOUS RECONSTRUCTION OF THE RIGHT HEART: TRICUSPID AND PULMONARY VALVE-IN-VALVE IN COMBINATION WITH A PULMONARY ARTERY STENT IN A SINGLE PROCEDURE

Heiko Schneider / Michael R Rigby / Wei Li / Michael Gatzoulis / Anselm Uebing
Royal Brompton Hospital, London, UK

HISTORY

A 32-year-old gentleman with repaired tetralogy of Fallot (ToF) presented with worsening symptomatology in NYHA class II–III. Investigations confirmed significant pulmonary regurgitation (PR) and stenosis (PS) of the previously implanted pulmonary valve prosthesis as well as moderate to severe tricuspid regurgitation (TR) and stenosis (TS) of a prosthetic Mosaic valve. He was also known to have tight proximal left pulmonary artery (LPA) stenosis.

BACKGROUND

At the age of one he underwent ToF repair with a trans-annular patch repair (1st sternotomy). At the age of ten he required resection of a residual right ventricular outflow tract obstruction (2nd sternotomy). Subsequently, he underwent stenting of a significant stenosis of the left pulmonary artery (aged 11) and implantation of a permanent pacing system for symptomatic atrio-ventricular block (aged 14). Ten years later at the age of 24 he was found to be in atrial fibrillation (AF); he had developed severe PR with supra-ventricular PS and moderate tricuspid regurgitation (TR). Via a 3rd sternotomy a 25 mm Mosaic (Medtronic, MN, USA) valve was implanted in the pulmonary position and a 29 mm Mosaic valve in the tricuspid valve position. A pulmonary arterial patch was placed, cryo-ablation was performed and the pacing system was changed to an epicardial system. When seen at the age of 31 years he was in permanent AF after multiple failed electrical cardioversions. Echocardiography confirmed moderate-severe TR, moderate TS (mean gradient 8 mmHg) as well as moderate-severe PR and moderate PS (peak gradient 60 mmHg). There was moderate right ventricular dilatation with moderately to severely impaired systolic function. A cardiopulmonary exercise test confirmed a reduced exercise tolerance with a peak VO_2 of 31% predicted.

PHYSICAL EXAMINATION

On examination he was found to be in NYHA class II–III. Clinically euvoelaemic with no gross signs of right sided heart failure. Height: 183 cm, Weight 82 kg, BMI 24 kg/m²; BP 116/68 mmHg, HR 80 bpm, irregularly irregular. Auscultation of the precordium revealed a normal S1 and S2; 3/6 ejection systolic murmur left upper sternal edge.

MULTIDISCIPLINARY TEAM REVIEW

The multidisciplinary team felt it to be appropriate to offer the patient a percutaneous approach as a further operation would otherwise constitute his fourth sternotomy with considerable risk. The plan was to:

1) dilate the left PA stent which appeared significantly stenosed with over 50% narrowing on CT with a minimal diameter of 6 mm.

2) to perform a valve-in-valve procedure to replace the pulmonary valve (internal diameter 14 x 15 mm on CT) and 3) to implant a new tricuspid valve; again as a valve-in-valve procedure (internal diameter measuring 22 mm). After informed consent was obtained the procedure was performed under general anaesthetic and transesophageal echocardiography (TOE) guidance.

INTERVENTION

Initial haemodynamic measurements were obtained: The mean right atrial (RA) pressure was elevated at 16 mmHg, right Ventricular (RV) pressure was 60% of systemic pressure.

Firstly, the stenosis in the left pulmonary artery (LPA) was treated: a 0.035 Lunderquist wire (Cook Medical, IN, USA) was secured in the distal LPA over which a 28 mm covered CP stent (NuMED, NY, USA) was advanced on a 14x3.5 mm BiB balloon (NuMED, NY, USA) through a 14 Fr sheath. This was post-dilated with a 14 mm Atlas Gold balloon (Bard, AZ, USA). Angiography confirmed excellent stent expansion with no residual gradient across the stent.

Subsequently, a 20 mm Mullins-X balloon (NuMED, NY, USA) was placed across the pulmonary valve and inflated with simultaneous acquisition of an aortic angiogram. This was performed to ensure that there was no coronary compression should the stent flare. Based on CT and angiographic measurements an 18 mm Melody (Medtronic, MN, USA) valve on an 18 mm Ensemble (Medtronic, MN, USA) delivery system was deployed in the previous implanted Mosaic valve. TOE confirmed no significant residual pulmonary regurgitation or stenosis. A peak gradient of 18 mmHg remained across the pulmonary valve with the RV pressure being less than half of the systemic arterial pressure.

The tricuspid valve size was confirmed using a 30 mm sizing balloon. This confirmed that a 22 mm Ensemble delivery system would be appropriately sized to place an 18 mm Melody valve. This was post-dilated with a 20 mm Mullins-X balloon. Angiography and TOE confirmed no residual regurgitation; a mean gradient of 4 mmHg was measured on TOE. The RA pressure at the end of the procedure was 9 mmHg. The final RV angiogram shows the fully deployed pulmonary and tricuspid valves with no residual regurgitation.

There were no immediate complications post procedure or on follow up at 12 weeks. Echocardiography at 12 weeks did not show any significant TR or PR with a mean gradient across the tricuspid valve of 5 mmHg and a peak gradient across the pulmonary valve of 23 mmHg. The patient remained in NYHA class I–II during follow up.

LEARNING POINTS OF THE PROCEDURE

Even though no long term data are available for any valve-in-valve procedures short term outcomes based on case reports are promising. This case adds further insights into the potential clinical applications of complex structural intervention in adult congenital heart disease. Whilst the above procedure may have elements of palliation it will hopefully delay the need for further high risk cardiac surgery or even transplantation in the medium to longer term.

UNILATERAL HYPERTENSIVE LUNG IN A CORRECTABLE LESION, HOW DOES IT RESPOND?

Mahmoud Mohamed Shahat Boraie / Sherin Abdel Salam / Carin van Doorn
Magdi Yacoub Foundation, Aswan Heart Centre, Aswan, Egypt

HISTORY AND PHYSICAL

We report an Egyptian male 2-month-old infant presented to our outpatient clinic with history of SOB, feeding difficulties, FTT and progressive cyanosis on crying and feeding improving with nasal oxygen.

On examination his BP was 75/36 mmHg, HR 145/min, afebrile and with tachypnea.

PHYSICAL EXAMINATION

- He was under weight for age (2.7 kg) and emaciated
- Chest examination revealed tachypnea, subcostal retractions and chest crepitations on left side with good air entry on the right side
- Cardiac examination revealed tachycardia, hyper-dynamic apex with parasternal heave and accentuated 2nd heart sound with no audible murmurs
- Abdominal examination revealed tender hepatomegaly

IMAGING

- CXR revealed cardiomegaly, plethoric left lung and oligemic right fields
- Echo: small ASD shunting right to left, small perimembranous VSD, an absent RPA, small PDA to LPA which was normally connected to MPA and markedly dilated RV, moderate to severe tricuspid regurgitation, dilated right ventricle with impaired contractility with ERVSP around 100 mmHg (above systemic BP figure 1)
- Cardiac CT: confirmed the diagnosis with suspicion of remnant central part of RPA

INDICATION FOR DIAGNOSTIC CATHETERIZATION

After discussion with surgeon diagnostic catheter was planned to check presence of central RPA and further right lung blood supply through MAPCAs.

DIAGNOSTIC CATHETERIZATION AND INTERVENTION

A 4F catheter passed through IVC – RA, then through the ASD to the right upper pulmonary vein and wedged with injection delineated a central RPA supplying the whole right lung lobes. Main pulmonary artery angiography showed a small vessel feeding this central RPA in AP view (cine clips were attached) with no other blood supply to the right lung. Pressures were recorded with supra systemic RV systolic pressure.

The patient was operated and during surgery 2 ducts were present; the right closed ductus to central RPA so repair was done by dividing the right ductal tissue and used as a back wall to connect the RPA to MPA with roofing over with autologous pericardium and division of left ductus.

The baby was received in PCICU on mechanical ventilation, supported by milrinone and noradrenaline. Pulmonary vasodilators were added (sildenafil and milrinone nebulizers) and diuretics continued with a marvelous improvement of RVSP as FUP echo postoperative revealed around 30 mmHg and minimal aliasing across RPA with maximum PG around 15 mmHg.

On discharge the clinical condition improved with good activity, respiratory and feeding pattern with gaining weight (3.4 kg).

After discharge the baby was followed for 1 and 6 weeks in OPC with excellent clinical status and his weight increased to 5 kg. Echocardiography was repeated and showed normal continuity of PA and its branches, normal RV size and normal RVSP. CT was repeated and showed normal continuity and flow of pulmonary branches (figure 2).

LEARNING POINTS OF THE PROCEDURE AND DISCUSSION

- After reviewing the literature, we found that anomalous pulmonary artery branch arising from the ascending aorta in the presence of a main pulmonary artery arising separately from the heart is a rare anomaly, whose incidence is <1% of all the congenital cardiac diseases.
- By far the more common form is anomalous origin of the RPA, seen in 82% of 108 cases of an excellent review by Kutsche and Van Mierop [1].
- The connected lung to the normally arising PA branch receives the entire cardiac output from the right ventricle; as mentioned above commonly the left lung with smaller volume than the right one so the common presentation is congestive cardiac failure and with the onset of early pulmonary hypertension.
- In some, there is an absence of cardiac failure or a very short abbreviated period of failure followed by the development of pulmonary vascular disease. Untreated, pulmonary vascular obstructive disease develops rapidly and 1-year survival may be as low as 30%. Surgical management early in life has improved the outcomes in these patients [2].
- Accurate anatomical diagnosis of this rare CHD with the assessment of diagnostic catheter can guide the management of such a misleading case and improved the outcome.

- Heart team (cardiologist, cardiac surgeons and radiologists) discussion is a corner stone for successful diagnosis and plan.
- Good ICU care with use of pulmonary vasodilators and ventilation strategy improved the outcome.

Figure 1

Continuous wave Doppler across TV with estimated RVSP around 100 mmHg.

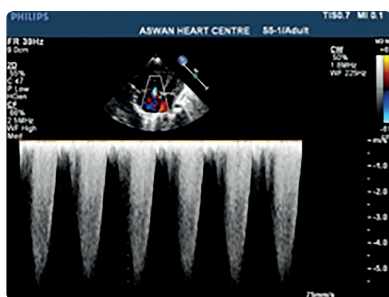
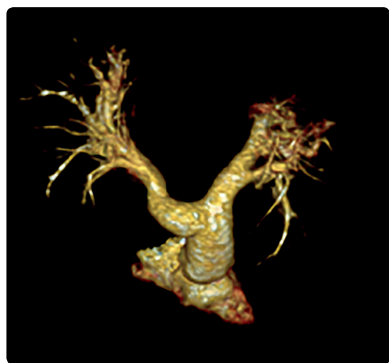

Figure 2

3D reconstruction of the repaired RPA in follow up cardiac CT.



References

- 1) Kutsche LM, Van Mierop LHS: Anomalous origin of a pulmonary artery from the ascending aorta: Associated anomalies and pathogenesis. *Am J Cardiol* 1988; 61:850-856.
- 2) Nathan M, Rimmer D, Piercey G, Del Nido PJ, Mayer JE, Bacha EA, et al. Early repair of hemitruncus: excellent early and late outcomes. *J Thorac Cardiovasc Surg.* 2007; 133: 1329-35.

EXPERIENCE WITH THE ABSORB BIOREABSORBABLE VASCULAR SCAFFOLD (BVS) IN VARIOUS SCENARIOS OF CONGENITAL HEART DISEASE

Alejandro Rodriguez Ogando / Fernando Ballesteros / Jose Luis Zunzunegui Martinez
Gregorio Maranon General University Hospital, Madrid, Spain

OBJECTIVE

To describe our experience with bioresorbable vascular scaffold in the setting of diverse vascular lesions in pediatric population.

BACKGROUND

Children outgrow metal stents, prompting them to undergo future transcatheter dilations and eventual surgical removal. A bioresorbable stent, or a stent that disappears with time, would solve this issue.

METHODS

Clinical records, catheterization data, and operation notes of eleven consecutive patients undergoing bioresorbable stent implantation between July 2013 and December 2014 were studied retrospectively.

RESULTS

Patient median age was 3.8 months (10 days–6.3 years) and median weight was 3.95 kg (2.3–20). The underlying vascular diseases were: Pulmonary vein stenosis (5), pulmonary artery branch stenosis (4), right coronary artery stenosis (1), and aortic arch coarctation (1). Stent sizes (mm) used were 3.5×12 (n=7), 2.5×12, 3×12 (n=2). In 8 patients, subsequent stent overdilation with coronary balloon was required to achieve maximum vessel diameter. Angiographic results were satisfactory in all cases. No related complications or acute obstructions were observed. Improvement in haemodynamic parameters and clinical recovery was achieved in all cases in the acute follow up. Five patients underwent cardiac surgery. At the time of surgery, stent structures were not found by the surgeon, and the procedures were carried out uneventfully.

CONCLUSION

BVS stenting offers a feasible alternative to angioplasty, metal stents, or surgical approach in selected patients, bridging to a more definitive further solution.

RESULTS OF TRANSCATHETER PULMONARY VALVULATION IN CHILDREN < 30 KG

Alejandro Rodriguez Ogando / Fernando Ballesteros / Jose Luis Zunzunegui Martinez
Gregorio Maranon General University Hospital, Madrid, Spain

INTRODUCTION

Although widely accepted, indications for percutaneous pulmonary valve replacement (PPVr), are limited to prosthetic conduits in the right ventricle outflow tract (RVOT) in patients \geq 30 kg.

AIM

To evaluate the outcomes of Melody valve insertion in patients < 30 kg.

METHODS

We analysed procedural and outcomes data from 20 patients < 30 kg (8 patients < 20 kg), who underwent Melody valve implantation for a native/patched RVOT (N=9), prosthetic conduit (10) and bioprosthesis (N=1).

RESULTS

Median age and weight was 5.8 years (1.5–13) and 22 kg (9–29.8). PPVr indication was regurgitation in 9, stenosis in 1 and mixed in 10. All procedures were successful. PPVr was performed through the femoral vein in 11 cases, jugular vein in 8 cases and transapical-periventricular in 1 case. Pre-stenting was performed in 95% of cases, 13/19 in the same procedure. No significant regurgitation was recorded after the procedure, and the trans-pulmonary gradient was significantly reduced. Early minor complications occurred in 2 cases (10%) The median hospital stay was 3 days (2–5). Median follow up was 44 months (4–82). During follow up, one patient underwent a new PPVr (valve-in-valve procedure); one patient required overdilation of the prosthesis; and one patient developed stent fracture. Follow up with MRI demonstrated significant improvements in right ventricular volumes and function.

CONCLUSION

PPVr is highly feasible in children < 30 kg, in both, native RVOT and prosthetic conduits, and mid-term follow up demonstrates good haemodynamic results and appears promising.

STENTING OF THE NATIVE RIGHT VENTRICULAR OUTFLOW TRACT IN THE SYMPTOMATIC INFANTS WITH TETRALOGY OF FALLOT (TOF)

Fernando Ballesteros / Alejandro Rodriguez Ogando / Jose Luis Zunzunegui Martinez
Gregorio Maranon General University Hospital, Madrid, Spain

OBJECTIVE

To assess feasibility, safety and effectiveness of right ventricular outflow tract (RVOT) stenting in symptomatic young infants with TOF.

METHODS

Retrospective case notes and procedure review of patients undergoing stenting of the RVOT over a 5 year period.

RESULTS

Between 2010 and 2015, 9 patients underwent stent implantation; median age was 48 (range 1–364) days, and median weight was 3.7 (2.2–7) kg. Median procedure time was 54 (30–233) min and fluoroscopy time 20 (12.6–77) min. There was one procedural emergency surgery. Two patients required ECMO support during the procedure. The pulmonary valve was deemed unsalvageable in all patients but one (median valve diameter 5 mm (range 4–8), median Z-score -3 (range -5 to -0.5). Saturations increased from 77% (50–85%) to 95% (85–98%) ($p < 0.005$). Two further catheter interventions were undertaken (balloon in 1, stent in 1). 7 patients underwent delayed surgery (complete repair in all of them) at a median of 140 (111–200) days post-stenting. No surgery was compromised by the presence of stents in the RVOT. There were no perioperative deaths. Median Nakata index increased from 80 mm²/m² (50–200) to 126 mm²/m² (100–251) ($p < 0.05$) before surgical repair.

CONCLUSIONS

In symptomatic young infants with TOF, stenting of the RVOT provides a safe and effective management strategy, improving arterial oxygen saturation and encouraging pulmonary artery growth.

ONE COIL AND THREE COLLATERALS

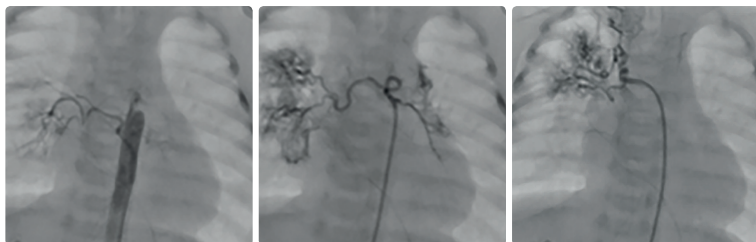Sherien AbdelSalam / Hassan Kamel
Aswan Heart Centre, Aswan, Egypt

HISTORY AND PHYSICAL

An 8-day-old, 23 kg, preterm baby boy with d-TGA, intact IVS S/P balloon atrial septostomy was referred to our centre for pre-assessment. He underwent successful arterial switch operation with no intra-operative events. There was no evidence of increased venous return during surgery. Attempts to wean the baby from mechanical ventilation were unsuccessful and he had repeated airway infections. Echocardiography showed good cardiac repair with dilated left side and increased venous return to LA. Supra-sternal views of the aorta showed at least two collaterals of moderate size. His X-rays showed progressive plethora.

IMAGING

Due to his stormy course in ICU, patient was restudied in cathlab and he was found to have 3 collaterals arising from upper and lower descending aorta. Cineangiogram in PAs showed dilated branches which supply all lung lobes. The 1st collateral came off the anterolateral aspect of the proximal descending aorta and was about 3 mm in diameter. It supplied the right upper lung lobe. The 2nd one was slightly lower in origin and showed a convoluted beginning, then it bifurcated to right and left branches; the right branch supplied the middle and lower right lung lobes, the left branch was smaller and supplied mid-lung segments. The third collateral was the smallest and it came off the lower descending aorta. It supplied lower right lung.



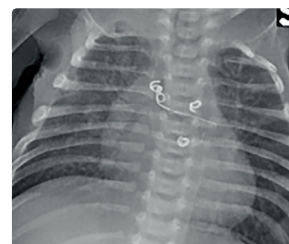INDICATION FOR INTERVENTION

Inability to wean the baby off mechanical ventilation. Increased pulmonary flow and dilated left side.

INTERVENTION

Using a RJ 4 Fr catheter and Terumo and BMW wires, each collateral was engaged. There was only one coil available on shelf: A PFM 4×5 coil, so it was cut into 3 pieces. Each piece was introduced into the catheter and pushed by the stiff end of the wire. The same procedure was done for the three collaterals. There was

some residual flow in the upper right collateral so another piece of a wire was used to plug the vessel proximal to the first coil. There was complete occlusion of the collaterals with no encroachment of the aorta. Patient was transferred to ICU where he had 2 days of stability and dry lungs on X-rays. Echo showed mildly dilated left ventricle with good function. Baby was successfully extubated a day later, a smooth in-hospital stay afterwards and was discharged home.



LEARNING POINTS OF THE PROCEDURE

Major aorto-pulmonary collaterals or enlarged bronchial vessels are not uncommon in cases of d-TGA-IVS after arterial switch operation.

MAPCAs should always be ruled out whenever an apparently smooth postoperative course after a successful TGA-IVS repair becomes unexpectedly complicated by cardiac or respiratory failure.

Percutaneous closure can be done before or after surgery with excellent results.

ISOLATED BRANCH PULMONARY STENOSIS AND UNILATERAL PULMONARY HYPERTENSION: RELATIONSHIP AND OUTCOME

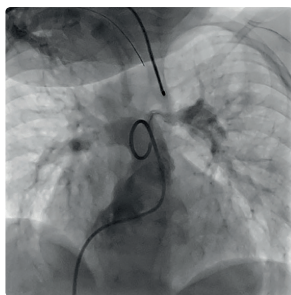
Sherien AbdelSalam / Hassan Kamel
Aswan Heart Centre, Aswan, Egypt

HISTORY AND PHYSICAL

A 2-year-old girl presented to us with progressive dyspnoea on exertion. On examination there was a left parasternal heave and a pan-systolic murmur over the tricuspid area and an ejection systolic murmur in the inter-scapular area, liver was enlarged (2 fingers below costal margin).

IMAGING

Echo showed a dilated hypertrophied RV with fair systolic function, moderate TR with an ERVSP of 80 mmHg and a very tight LPA stenosis. The child was scheduled for invasive hemodynamic study and pulmonary angiography.



INDICATION FOR INTERVENTION

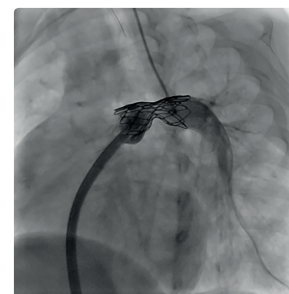
Severe LPA origin stenosis, contralateral pulmonary hypertension, impaired RV function.

INTERVENTION

The invasive hemodynamic study and pulmonary angiography showed a dilated right pulmonary artery with tight hypoplastic origin of the left pulmonary artery and normal distal left pulmonary arterial tree. The right pulmonary artery systolic pressure was 70 mmHg, the left pulmonary artery systolic pressure distal to the hypoplastic segment was 25 mmHg and the right ventricular systolic pressure was 80 mmHg. Attempt to dilate the hypoplastic origin of the LPA was done using a 10 and 12 F Z med high pressure balloons resulted in improvement of the diameter of the hypoplastic segment. Repeated measurements of the pulmonary pressure after balloon dilatation showed drop of the right pulmonary artery pressure to 50 mmHg and increase of the left pulmonary artery pressure to 35 mmHg with drop of the pressure gradient across the origin of the left pulmonary artery from 55 mmHg to 15 mmHg. The child was discharged on oral frusemide diuretics and phosphodiesterase inhibitor to relieve the remaining high

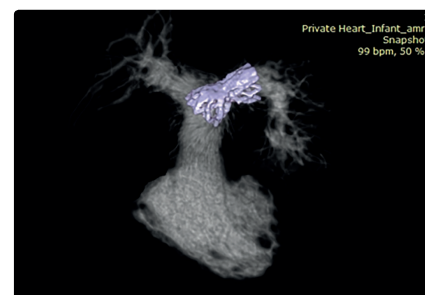
right ventricular pressure and was scheduled for follow up trans-thoracic echocardiogram on a monthly bases. The immediate follow up echocardiogram 1 month later showed persistent RV dilatation with fair functions and RVSP 55 mmHg. Three months later there was progressive RV dilatation with impaired RV function and estimated RVSP 90 mmHg with evident turbulent flow across the origin of the LPA.

In view of the immediate improvement of the pulmonary artery pressure after balloon dilatation and the short term relapse and progressive RV dilatation and progressive increase in RVSP, the decision was made to establish persistent patency of the LPA by percutaneous stenting. An exchange Amplatz stiff wire 0.035×260 was parked in the terminal LPA branches. A 12 F Mullin sheath was advanced over the stiff, then a 34 mm CP stent was mounted over a Zmed Balloon (12×40 mm) and was properly positioned across the stenotic segment in the LPA and was redilated using Zmed Balloon (16×30 mm). Post stent deployment angiography showed good flow across the LPA with PG across the stent of 20 mmHg and resulted in improvement of the diameter of the hypoplastic segment. Repeated measurements of the pulmonary pressure after balloon dilatation showed drop of the right pulmonary artery pressure to 50 mmHg and increase of the left pulmonary artery pressure to 35 mmHg with drop of the pressure gradient across the origin of the left pulmonary artery from 60 mmHg to 15 mmHg.



LEARNING POINTS OF THE PROCEDURE

Isolated origin branch pulmonary stenosis or unilateral pulmonary artery agenesis (UAPA) may present quite early. Contralateral pulmonary hypertension usually develops with RV progressive function impairment. Pulmonary hypertension declines after relieving the stenosis (either surgically or as in this case percutaneously).



DEVICE CLOSURE IN ADULTS WITH ATRIAL SEPTAL DEFECT: A SINGLE CENTER STUDY

Vida Razazikhales / Mohammad / Ali Ostovan / Javad Kojuri / Pooyan Dehghani
Shiraz University of Medical Sciences, Shiraz, Iran

BACKGROUND

Atrial septal defect (ASD) has a prevalence of 6–10% in congenital heart diseases. Successful closure of ASD improves patients' functional class and exercise capacity with usually normalization of intracardiac pressures and reduction in right heart chamber size with better preservation of right ventricular function. The aim of this study is to evaluate the safety and feasibility of percutaneous device closure of ASDs in 256 patients.

OBJECTIVES

The aim of this study is to evaluate the results of device closure in adults with atrial septal defect.

METHODS

256 consecutive patients with final echocardiographic diagnosis of ASD with Qp/Qs ratio of more than 1.5 and/or enlarged right ventricle who were suitable for device closure according to our criteria were enrolled in our study. The patients were treated using nitinol wire mesh transcatheter devices. Short and mid-term complications of the procedure were followed and recorded for a mean period of 3.2 years.

RESULTS

There was a success rate of 98.4% with just 3 unsuccessful cases and mean hospital stay was 1.007 ± 0.0004 days. Complication rate was 7.42%. Size of the right ventricle (RV) annulus was significantly decreased 24 hours after intervention. (Before intervention: 12.8 ± 2.1 mm, after intervention 9.5 ± 2.2 mm, $P=0.005$)

CONCLUSION

The present report demonstrates that transcatheter closure of ASD is safe and effective.

LONG-TERM OUTCOMES OF TREAT AND REPAIR STRATEGY FOR ATRIAL SEPTAL DEFECT WITH PULMONARY ARTERIAL HYPERTENSION

Yoichi Takaya / Teiji Akagi / Yasufumi Kijima / Koji Nakagawa
Okayama University Hospital, Okayama, Japan

BACKGROUND

Therapeutic strategies for atrial septal defect (ASD) with pulmonary arterial hypertension (PAH) are controversial. Long-term effects of the treat and repair strategy remain unknown.

OBJECTIVES

This study aimed to evaluate long-term outcomes of PAH specific medications and subsequent transcatheter closure (ie, the treat and repair strategy) in patients with ASD complicated with PAH.

METHODS

A total of 616 patients, who underwent transcatheter ASD closure, were divided into three groups: PAH/specific medications ($n=13$), PAH/no-specific medications ($n=42$), no-PAH ($n=562$). PAH was defined as mean pulmonary arterial pressure (PAP) ≥ 25 mmHg at cardiac catheterization. The endpoint was defined as cardiovascular death and hospitalization for heart failure or exacerbation of PAH.

RESULTS

The mean PAP before the treat and repair strategy was 56 ± 21 mmHg in patients with PAH/specific medications, which was significantly higher than the other groups. During a median follow up of 24 months (1–110 months), one of the patients with PAH/specific medications was hospitalized due to heart failure. No deaths occurred in these patients. The event-free survival rate was worse in patients with PAH/specific medications (log-rank test, $p < 0.001$), however this was not different from that in patients with PAH/no-specific medications ($p=0.864$). Most patients with PAH/specific medications had no cardiac events. Further improvements in PAP occurred after transcatheter ASD closure. Some patients had a reduction of PAH specific medications after the procedure.

CONCLUSION

Our findings suggest that the treat and repair strategy can be considered a valuable therapeutic option in patients with ASD complicated with PAH.

INCIDENCE OF PARADOXICAL EMBOLISM MEDIATED BY PATENT FORAMEN OVALE AT ACUTE-CARE HOSPITAL

Shinobu Hosokawa / Akiho Seno / Tstuo Yasuoka / Tomoko Minami / Riyo Ogura
Tokushima Red Cross Hospital, Tokushima, Japan

BACKGROUND

Previous report described incidence of paradoxical embolism is 5% of all strokes.

57

OBJECTIVES

To evaluate the incidence of paradoxical embolism at acute-care hospital.

METHODS

From 2013 June to 2015 January, 1105 transesophageal echocardiography were examined. 183 pts were screened for source of embolic stroke. Patients with atrial fibrillation and movable aortic plaque > 4 mm were excluded. Transesophageal echocardiography was conducted with bubble test and valsalva maneuver: shunt grading (grade 0 = none, grade 1 = 1 to 5 bubbles, grade 2 = 6 to 20 bubbles, grade 3 > 20 bubbles). 63 were considered positive (\geq grade 2). They were divided into two groups (spontaneous shunt: group S {n=20} and no shunt group NS {n=43}). The form of PFO and clinical characteristics were compared between two groups.

RESULTS

Mean age was lower in the group S than in the group NS (61.4 vs 69.8, $p=0.02$). Compared with group NS, group S presented with tunnel formation and a higher membrane mobility ($P=0.03$). The prevalence of positive bubble test \geq grade 2 was significantly higher ($P=0.003$) in group S as opposed to group NS. Incidence of continuous shunt or positive bubble test \geq grade 2 was 14.8%.

CONCLUSION

Incidence of paradoxical embolism may be underestimated at acute-care hospital. Stroke patients of continuous right to left shunt and positive bubble test have a strong association with paradoxical embolism. These patients should be considered for percutaneous closure.

FEASIBILITY AND SAFETY OF TRANSCATHETER CLOSURE OF ATRIAL SEPTAL DEFECT IN SMALL CHILDREN WEIGHING 10 KG OR LESS

Se Yong Jung / Nam Kyun Kim / Lucy Eun / Jo Won Jung / Jae Young Choi
Severance Cardiovascular Hospital, Yonsei University College of Medicine, Seoul, Korea

BACKGROUND

Transcatheter closure of atrial septal defect (ASD) has been accepted as a standard treatment for patients with hemodynamic significant ASD in children and adults. Little is known about very small children and infants with poor weight gain and symptoms with congestive heart failure.

58

MATERIALS AND METHODS

From April 2004 to October 2015, 1101 patients underwent transcatheter closure of ASD using Amplatzer septal occluder® (ASO, Golden Valley, MN) in our institute. Among them 121 patients were weighing 10 kg or below. The indication of early treatment in each group was symptoms of congestive heart failure with volume overload of right side heart. We analyzed the demographic data, clinical characteristic and outcome of the patients.

RESULTS

There were 44 males and 77 females. Median age was 15 months (7–24 months) and average weight was 8.9 kg (5.7 kg to 10 kg). Median ASD size was 15 mm (10 mm to 24 mm). Four patients were sent to surgery because of the encroaching mitral valve by LA disk after device placement. The procedure was successful in the rest of the patients. There was no mortality or major complication in any patients. Complete closure rates (except patients with multiple defects) at discharge and 3 month f/u were 91.9% and 98.9%, respectively. Only one minor complication was transient atrial arrhythmia during procedure. The mean hospital stay was 4.7 days (4–5 days).

CONCLUSIONS

Transcatheter closure of secundum ASD with the ASO is technically feasible, safe and effective even in very small children and infants less than 10 kg. Meticulous patient selection is of critical importance to avoid undue invasive procedures in this unique group of patients.

SEVEN NIT-OCCLUD LE-VSD DEVICES FOR THE TRANSCATHETER CLOSURE OF MULTIPLE VSDS – A CASE REPORT

Robert Sabiniewicz¹ / Piotr Werynski² / Jacek Kuzma³ / Andrzej Rudzinski³

¹ Medical University of Gdansk, Gdansk, Poland

² Uniwersytecki Szpital Dzieciocy, Krakow, Poland

³ Jagiellonian University, Krakow, Poland

HISTORY AND PHYSICAL EXAMINATION

A patient with multiple VSD, symptoms of heart failure, and increased pulmonary artery pressure was referred for pulmonary artery banding at the age of 5 weeks. His condition improved, and he grew up properly. At the age of 33 months, the procedure of “de-banding” was performed.

IMAGING AND INDICATION FOR INTERVENTION

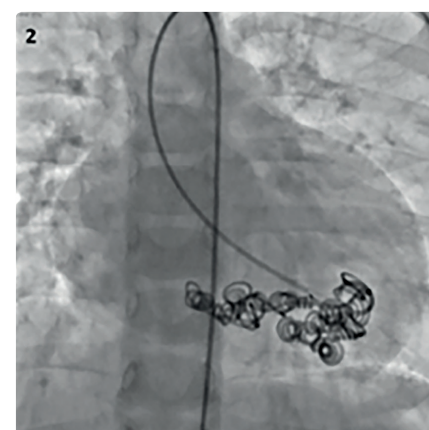
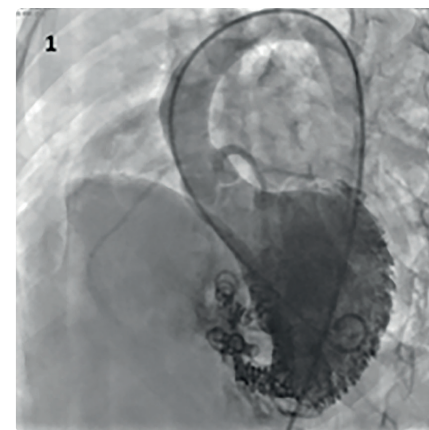
Echocardiography revealed a hemodynamically significant shunt through multiple VSDs. The patient presented symptoms of heart failure again. Cardiac catheterization parameters were as follows: QP:QS 2:1, PAP 48/16/29 mmHg. The diameter of the biggest VSD was 5.3 mm, and the other defects were 2.2 mm, 2.1 mm, and 1.7 mm in diameter.

INTERVENTION

The biggest VSD was closed with a Nit-Occlud Le-VSD device (10×6 mm). The other VSDs were closed with 8×6 mm devices. Mean PA pressure decreased to 19 mmHg, and QP:QS to 1.7:1. A new leak through VSD was observed, and 2 months later the next two Nit-Occlud Le-VSD devices (10×6 mm, 8x6 mm) were implanted. 10 months later the residual shunt was still significant, and the next three Nit-Occlud Le-VSD devices (10x6 mm) were implanted. Finally, during three cardiac catheterization sessions, a total of seven Nit-Occlud Le-VSD devices were implanted (Figures 1 and 2). After 6 months of follow up there is one insignificant shunt (<1,5 mm), with QP:Q 1,1:1 and a good LV function (EF 58%).

LEARNING POINTS OF THE PROCEDURE

Muscular, and especially multiple VSDs are a serious clinical problem. Surgical closure of such defects is very difficult and sometimes impossible. The “Swiss cheese” type VSD is the most difficult type of VSD. Transcatheter device closure was first reported as a therapeutic option for muscular VSD by Lock et al. in 1988. Different types of devices and implantation techniques are used. New devices give new possibilities and lower rates of complications. The Nit-Occlud Le-VSD device (PFM) is a pre-mounted coil system, dedicated for VSD closure. PFM Le-VSD coil system is effective, especially in closing atypical multiple VSDs. The implant adapts to the anatomy of the VSD and septum. The implant’s plasticity prevents any significant distortion of the interventricular septum. This may constitute a treatment option for the “Swiss cheese” type of VSD.



EMBOLIZATIONS/DISLOCATIONS OF ATRIAL SEPTAL DEFECT AND PATENT DUCTUS ARTERIOSUS OCCLUDERS; SINGLE CENTER EXPERIENCE

Ahmet Celebi / Ilker Kemal Yucel / Orhan Bulut / Sevket Balli / Gokmen Akgun / Mehmet Kucuek / Evic Zeynep Basar
Dr. Siyami Ersek Hospital, Istanbul, Turkey

INTRODUCTION

In this paper, we aimed to present the results and treatment methods of device embolizations seen after transcatheter ASD and PDA device closures.

METHOD

Between 2004 and 2016 transcatheter device closures of secundum ASD and PDA was performed in 884 cases and 312 cases respectively in our clinic. The patients were retrospectively analyzed regarding the device dislocation and embolization. 553 patients, in whom a detachable or a Gianturco coil were used for PDA closure, were excluded from the study.

RESULTS

Amongst the patients in whom a device closure of ASD was performed, device embolization and dislocation was encountered in ten and one, respectively. The median age of the patients was 19.5 (5–52) years. The interatrial septum was aneurysmatic in 2 patients while the rims of the defect were either deficient or thin and mobile in 5. The median 2D diameter of the defects was 20.5 mm (11.2–30), median color flow diameter was 24 mm (13–34), and median sizing balloon stretched diameter was 26 mm (13–34) (an indentation did not occur with 34 mm sizing balloon in two cases). The median size of the embolized devices was 25 mm (13–36). Migration occurred due to spontaneous disconnection of the devices during repeated implantation attempts in three cases. Embolization occurred right after the release of the device in 6 patients and 24 hours after the procedure in one patient. The device embolized into pulmonary artery in 5 cases, into the left ventricle in 2 cases, into the ascending aorta in one, into the right atrium in one and onto the mitral valve in one patient. The devices were retrieved with the use of a biptome and a snare in 6 patients and the defect was closed percutaneously with a larger device in 5 of these patients. 5 patients were referred for surgery in a hemodynamically stable condition. One patient was also referred for surgery due to dislocation of the device at the aortic site causing significant left to right shunt. Migration or dislocation of a device was encountered in 8 patients after the device closure of a PDA. Device migration was observed in 5 patients and dislocation of the device into the descending aorta was seen in 3. The median age of the patients was 2.5 years (1 month to 8 years), and the

median weight was 9.5 kg (3.3–24 kg). In 6 cases PDA was conical in shape and tubular in 2 cases. The median diameter of the PDA was 8.6 mm (3.7–11.7 mm) on angiogram. Except for one patient, pulmonary hypertension equal to systemic pressure was present in all. Amongst 5 cases with migration, four devices embolized into the PA and into the descending aorta in one patient. 3 cases were referred for surgery. The devices were retrieved with the use of a snare from PA and descending aorta in 2 patients. In one of these patients, PDA was occluded with a larger device. In the remaining, it could not be achieved even with a larger device.

In 3 cases dislocation of the device into the descending aorta led to a coarctation of the aorta. All of these patients had severe pulmonary hypertension. Two of these devices were repositioned successfully with the use of a biptome, antegradely. In the other patient, the device was retrieved with a snare and the PDA was closed with a muscular VSD device.

CONCLUSION

The risk factors for embolization of the devices after ASD closure are found to be the presence of a large defect, the use of large devices, the presence of a deficient rim, septum dilation during balloon sizing, mismeasurement of the diameter of the defect and the presence of an aneurysmatic septum. The first objective should be to bring the device to a safe position. While using a snare for retrieval, a biptome may be used to stabilize the device. During this process, special attention should be paid to the mitral and tricuspid valve damage. The most important risk factor for embolization of the devices after the PDA closure are found to be the presence of severe pulmonary hypertension and large defects. The retrieval rate is lower after PDA device closure than that after ASD device closure. Especially, after the occlusion of PDA in a patient with severe pulmonary hypertension, a close follow up should be considered regarding embolization.

TRANSCATHETER CLOSURE OF PERIMEMBRANOUS VENTRICULAR SEPTAL DEFECT BY NIT-OCCLUD COIL – A SINGLE CENTER EXPERIENCE

Moshe Dotan^{1,2} / Yakir Or² / Avraham Lorber^{1,2}

¹ Meyer Children's Hospital, Rambam Health Care Campus, Haifa, Israel

² B. Rappaport – Faculty of Medicine, Technion – Israel Institute of Technology, Haifa, Israel

BACKGROUND

Surgical closure is still considered as the most common treatment for hemodynamically significant perimembranous ventricular septal defect. Even though the mortality and morbidity rates have become lower than ever in the past few decades with the advance of the cardio-thoracic surgical techniques, this approach still carries the risks and complications of open thoracotomy, bypass time and cardiac ischemia. The transcatheter approach has overcome the need for open heart procedures with lower morbidity, mortality and complication rates.

METHODS

A total of 29 patients (mean age 12 years, range 3–36 years) who underwent transcatheter coil closure of perimembranous ventricular septal defects between May 2009 and November 2011 were reviewed. Nit-Occlud® VSD coils (pfm medical ag Koeln, Germany) were applied in all subjects. Success rate, adverse reactions, short and long term complication were documented.

RESULTS

There was a 96.5% procedure success rate (28/29 patients). There were 5 (17%) minor immediate and short term complications including: transient device hemolysis, local intravascular thrombus formation, transient 2nd degree AV and bundle branch blocks, and short intra-procedural asystole. Two patients had major long term complications which required late surgical intervention. There were no cases of high degree AV block.

DISCUSSION

An overall success rate of 96.5% was accomplished by the transcatheter approach in our study. When comparing to surgical closure there is a significant reduction of procedural time, hospitalization duration and cost, median intensive care unit stay, median hospitalization cost and blood products usage.

CONCLUSION

Transcatheter coil closure may provide an effective approach for closure of perimembranous ventricular septal defects.

CLOSING PERIMEMBRANOUS TYPE VENTRICULAR SEPTAL DEFECTS BY AMPLATZER DUCT OCCLUDER II

Ming-Chih Lin / Yun-Ching Fu / Sheng-Ling Jan

Taichung Veterans General Hospital, Taichung City, Taiwan

BACKGROUND

Various devices have been reported to be applied for closing ventricular septal defects (VSD). However, Amplatzer Duct Occluder II (ADO II) has been seldomly reported.

OBJECTIVE

To review the feasibility and effectiveness of using ADO II to close VSD from a case series from a single institution.

METHODS

From August 2013 to January 2016, 22 consecutive patients with perimembranous type VSD underwent transcatheter closure of VSD by ADO II. Of them, there were 10 males and 12 females. After establishing arterial and venous routes from groin, left ventricular angiography was performed. The AV loop was established mostly by a 0.032 inch 260 cm glide wire (Terumo Medical Co. Japan). Passing the VSD from LV was aided by a Jukins right catheter or cut-headed pig-tail catheter. Then the low profile delivery system (St. Jude Medical, St. Paul, MN) was advanced to descending aorta from femoral vein along the AV loop. The left disc and wait was then deployed in ascending aorta. Then the device was pulled back to the septum and the right disc was then deployed in the right ventricular side while keeping tension of the delivery cable. VSD size and device selection was mainly according to angiography. Transthoracic echocardiography was used to check device position and valves during the procedure. Patients were followed up by echocardiography, EKG and Holter 1, 3, 6 and 12 months after the procedure.

RESULTS

The ages of those patient ranged from 1 to 61 years with a median of 7 years old. The body weight ranged from 9 to 82 kg with a median of 25 kg. No patients demonstrated any kind of heart block. Only one patient developed transient sinus bradycardia relieved by atropine injection. Two patients had transient trivial aortic regurgitation immediately after the procedure. Six of the 22 patients (27%) had tiny residual shunts. However, no patients had events of hemolysis. No major complications of thromboembolism, device embolization, life threatening events had been ever recorded. The average procedure and screen time is 80 and 23.7 minutes.

CONCLUSION

Closing VSD by ADO II might be a feasible and effective alternate therapeutic option for patients of perimembranous type VSD.

HIGH INCIDENCE OF RIGHT TO LEFT SHUNT IN ADULT PATIENTS WITH ATRIAL SEPTAL DEFECT

Koji Nakagawa¹ / Teiji Akagi² / Yoichi Takaya¹ / Hiroki Oe¹ / Nobuhiro Nishii¹ / Kazufumi Nakamura¹ / Hiroshi Morita¹ / Hiroshi Itoh¹

¹ Okayama University Hospital, Okayama, Japan

² Okayama University Graduate School of Medicine, Okayama, Japan

BACKGROUND

Hemodynamic feature of atrial septal defect (ASD) has been recognized as the degree of LR shunt. On the other hand, ASD patients have a relevant risk for paradoxical embolism due to RL shunt.

OBJECTIVE

The purpose of this study was to define the incidence of RL shunt in adult patients with ASD, and to evaluate the factors associated with this phenomenon.

METHOD

We performed a bubble study in 85 adult ASD patients (mean age; 54±21 years, mean ASD diameter; 15.3±7.4 mm) before transcatheter closure in our hospital and we assessed the incidence of RL shunt and the relationship between degree of RL shunt and clinical factors.

RESULT

Significant RL shunt was observed in 68 (80%) and 82 patients (96%) of all patients at rest and under the valsalva maneuver, respectively. The presence of floppy rim located in the inferior or posterior portion of the defect was highly associated with the degree of RL shunt ($P < 0.001$). Furthermore, the presence of a previous history of systemic thromboembolism was significantly associated with the degree of RL shunt under the valsalava maneuver ($P < 0.05$). On the other hand, neither maximum ASD diameter nor QpQs were associated with the presence and degree of RL shunt.

CONCLUSION

RL shunt can be confirmed in the majority of adult patients with ASD having significant LR shunt. Our results suggest that there may be a risk for development of paradoxical embolism even in hemodynamically insignificant ASD.

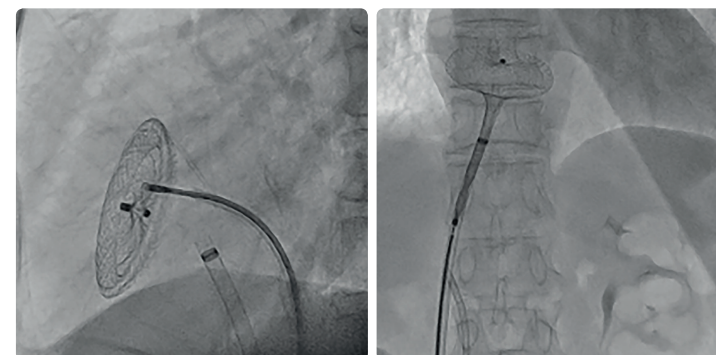
A SUCCESSFUL FAILURE

Ming-Chih Lin

Taichung Veterans General Hospital, Taichung, China

HISTORY AND PHYSICAL

A 68-year-old man had a chief complaint of exercise intolerance. Grade 3 of 6 systolic murmur was heard at his left upper sternal border with a fixed split second heart sound. Atrial septal defect was noted by echocardiography. Then he underwent transcatheter closure of atrial septal defect. Both transthoracic and intracardiac echocardiography showed a defect size of more than 3 cm. So, we attempted to close the defect by a 40 mm Amplatzer septal occlude. The device looked good initially. However, after release, it embolized to right ventricle. After fixing the device by biopsy forceps through a Mullin sheath, the screw head of the device was snared in the right atrium. Then the device was retrieved into the 12 Fr Torg Vue ASD long sheath. Unfortunately, the snare was lost due to the resistance of the large device. Then the delivery cable was screwed back to the device within the long sheath. Finally, the device was retrieved successfully.



INDICATION FOR INTERVENTION

Large ASD with right side heart failure.

INTERVENTION

Transcatheter closure of ASD. Retrieving of a 40 mm ASD after embolization to the right ventricle.

LEARNING POINTS OF THE PROCEDURE

1. Always consider inferior rim
2. Don't panic when losing a device
3. 2F larger long sheath available

IMPLANTATION OF ANDRASTENTS XL/XXL FOR DILATION OF DIFFERENT VESSELS

Bialkowski Jacek / Szkutnik Malgorzata / Fiszer Roland
Medical University of Silesia, Zabrze, Poland

PURPOSE

To present our experience with application of new cobalt – chromium stents (namely Andrastents XL/XXL).

METHODS

There were 91 patients treated with 93 Andrastents – 53 (aged 8–65 years) with native CoA or ReCoA, 16 (aged 6–64 y) with left or right or left PS closely to the bifurcation (native or postsurgical). In 19 pts (aged 11–40 y) the stent was implanted before Melody valve implantation (in calcified pulmonary homograft or native RVOT). In 3 patients Andrastents were implanted in different places to dilate stenosis of: superior vena cava (in 7.5y old child), Fontan tunnel (in 17y old boy), and PFO (interatrial septum in complex heart defect in 19y old boy). Mean follow up was 3.4 (0.2–5.4) years.

RESULTS

Procedures were finished successfully in all but two patients without any complications with good clinical improvement. Two migration of stents occurred – one in RVOT and another in LPA (without clinical consequences). In all cases successful dilation of stenosed place with significant gradient reduction occurred. In 2 cases of native CoA (23 and 34 y old men) in early follow up (6 and 8 months after the procedure) in angio CT small aneurysm formations were observed. Both patients were treated successfully with covered stents. In follow up no fracture of the stent nor any other complications were observed.

CONCLUSIONS

Implantation of Andrastents XL and XXL is a good therapeutical option for the treatment of stenosed great vessels.

ONE CENTER COMPARATIVE STUDY OF SIX DIFFERENT NITINOL WIRE MESH OCCLUDERS IN TRANSCATHETER CLOSURE OF ATRIAL SEPTAL DEFECT

Malgorzata Szkutnik / Roland Fiszer / Jacek Bialkowski
Medical University of Silesia Zabrze, Katowice, Poland

PURPOSE

To evaluate the safety and efficacy of 6 different nitinol wire mesh occluders in transcatheter closure of secundum atrial septal defect (ASD)

MATERIAL AND METHODS

Between 1997 and 2016 percutaneous closure of ASD was performed in 1281 patients (pts). Their age ranged from 0.5 to 79 years. Generally all devices were similar to Amplatzer Atrial Septal Occluder (ASO).

RESULTS

There were 1077 single ASDs and 204 double/multiple ASDs. 1013 pts received ASO, 87 Figulla occluders, 62 Cardio-O-Fix occluders, 27 Cera occluders, 31 HeartR occluders and 61 Hyperion occluders. Applied implant size was similar in all subgroups, fluoroscopy time was longer in ASO group (5.0 min) compared to others groups. There were 8 early embolizations – 7 ASO and 1 Figulla – mainly in the early years of its usage. In the ASO group the age and weight of pts were lower and follow up longer. No serious complications (such as wall erosion, fracture of the device or thrombus formation) were observed in any pt, but one. In one pt after Figulla application in early postprocedural period small ischemic stroke occurred. In late observations 2pts developed complete a-v block with the need of peacemaker implantation and 1 developed endocarditis due to incomplete endothelialization (all treated with ASO).

CONCLUSIONS

The application of all types of nitinol wire mesh occluders for ASD closure mentioned above is safe and they have similar effectiveness. The advantage of the smallest sheath makes Amplatzers the optimal device in the closure of ASD in small children.

DEVICE SIZING FOR ATRIAL FLOW REGULATION IN HFPEF: A COMPUTER SIMULATION MODEL

Joseph J. Vettukattil¹ / Harikrishnan K. N. Kurup¹ / Bennett P. Samuel¹ / Michael Broome^{2,3,4}

¹ Helen DeVos Children's Hospital of Spectrum Health, Grand Rapids, USA

² Karolinska University Hospital, Solna, Sweden

³ Karolinska Institutet, Solna, Sweden

⁴ KTH Royal Institute of Technology, Stockholm, Sweden

OBJECTIVES

Heart failure with preserved ejection fraction (HFpEF) is a condition leading to progressive abnormality in diastolic distensibility, filling, or relaxation of the left ventricle (LV). Creating an atrial fenestration in HFpEF is a potentially therapeutic intervention as it can decompress the left atrium (LA), improve filling pressures, decrease the pulmonary venous pressure and systemic congestion, and increase cardiac output. As the degree of atrial decompression will depend on the severity of HFpEF and atrial pressures, atrial fenestration of varying sizes may be required. We present a computer simulated hemodynamic model (Aplysia Cardiovascular Lab, Aplysia Medical AB, Sweden) for atrial fenestration sizing in HFpEF.

METHODS

The Aplysia Cardiovascular Lab provides an overview of the complex real-time interactions between myocardial, valvular and vascular function in the human cardiovascular system. The left atrial pressure (LAP) was increased in the model to simulate varying degrees of HFpEF. Atrial septal communication with varying diameters from 4 to 10 mm was simulated. The hemodynamics was documented after the proposed intervention.

RESULTS

The atrial fenestration size was selected to achieve post-intervention targets of a 5 mm reduction in LAP and Qp:Qp of < 1.5. An atrial communication of 8 mm was found to be effective for LA decompression when LAP was >20 mmHg. A 10 mm fenestration would be ideal for LAP ranging from 15–20 mmHg. There were no differences in the hemodynamics related to the thickness of the atrial communication.

CONCLUSIONS

Increasing the fenestration size beyond 10 mm can cause severe rise in RAP and Qp:Qs, especially in more severe degrees of LA hypertension. The pre-determination of the hemodynamics by means of a computer simulation model may be useful for effective LA decompression and prevent complications of increased pulmonary blood flow.

RETROGRADE TRANSCATHETER CLOSURE OF VENTRICULAR SEPTAL DEFECTS

Ib Vijayalakshmi

Sri Jayadeva Institute of Cardiovascular Sciences and Research, Karnatak, India

BACKGROUND

Amplatzer Duct Occluder II (ADO II) is designed for closing long ducts in infants. There are few reports of "off-label" use of ADO II in non-ductal positions.

PURPOSE

To evaluate the advantages and disadvantages of retrograde transcatheter closure of ventricular septal defects (VSD) with ADO II.

RESULTS

102 cases of VSDs closed by retrograde transcatheter method with ADO II, formed the material for the prospective study. Age: 8 months to 23 years (mean 9.1 years). 74 perimembraneous VSDs, 14 muscular VSDs, 13 Gerbode defects, one midmuscular VSD with dextrocardia, were closed. The shortest fluoroscopic time was 4.2 min, mean was 8.4 ± 4.1 min. In six cases there was initially a small residual shunt which had closed on three months follow up. Only in one case the device embolized to left pulmonary artery and it was retrieved. Eleven cases developed transient complete heart block which resolved and only one of them needed temporary pacing.

DISCUSSION

ADO II has a very low profile, can be easily delivered through a 5F guiding catheter and needs very short fluoroscopic time as artero-venous (AV) loop is not needed. The cost is 1/3 of the cost of regular ventricular septal occluder. However, it is not useful in VSDs measuring more than 6 mm and in those with insufficient aortic rim.

CONCLUSION

ADO II is an excellent device in ventricular septal defects. The procedure time and the cost are significantly less than regular devices. The success rate is very high and complication rate is very low.

TRANSCATHETER MANAGEMENT OF PERIMEMBRANOUS VENTRICULAR SEPTAL DEFECT AND SUBAORTIC RIDGE WITH OR WITHOUT AR

Hussein Abdulwahab M. Abdullah / Hussein A. Alsalkhi
Ibn-Albitar Center for Cardiac Surgery, Baghdad, Iraq

BACKGROUND

Subaortic ridge (SAR) is almost always a progressive disease and recurrence after surgery may occur in nearly one third of patients.

PURPOSE

To evaluate the safety and efficacy of management of PM VSD and SAR with or without AR using ADO type I.

METHODS

During the period from 1/2/2014 to 18/1/2016, 18 of 216 patients with PM VSD were found to have SAR. The same protocol for catheter closure of PM VSD under TTE was done. The aortic disc of the device was pulled toward the defect capturing and/or compressing the ridge against the ventricular septum.

RESULT

The median age and weight were 3 years and 16 kg respectively. Obstructive SAR was found in 8 patients with mean LVOT PG of 25 mmHg. Mild-moderate AR was found in 5 patients whose TTE follow up revealed improvement in the severity of the AR. Successful VSD closure with capturing and/or compressing the SAR was achieved in 15 patients (83.3%). Three patients underwent failed trial due to technical problem in one and deficient rims in the other two patients.

CONCLUSION

Transcatheter closure of PM VSD with SAR using ADO type I is safe and effective.

ARE AMPLATZER DUCT OCCLUDER II ADDITIONAL SIZES DEVICES DEDICATED ONLY FOR SMALLER CHILDREN?

Fiszer Roland¹ / Chojnicki Maciej² / Szkutnik Malgorzata¹ / Haponiuk Ireneusz² / Bialkowski Jacek¹

¹ Medical University of Silesia Zabrze, Katowice, Poland

² Hospital "Copernicus", Gdansk, Poland

PURPOSE

To present our experience with Amplatzer Duct Occluder type II Additional Sizes (ADOIIAS) for closure of different types of patent ductus arteriosus (PDA) in patients with distinct age compartments.

METHODS AND RESULTS

A group of 103 patients were analyzed, in whom PDA (diameter below 3.5 mm) was closed with ADO II AS. The median age of treated patients was 3.0y (from 0.1 till 24 yo) – 55 pts (53.4%) were older than 3 years. Ductal anatomy defined by angiography showed Type A in 42 pts (40.8%), type C in 6 (5.8%), type D in 21 (20.5%), type E in 34 pts (33%). Embolization of the device occurred in two patients shortly after implantation.

Both occluders were retrieved percutaneously. One death occurred in neonate 4 days after ADO II AS implantation not related to the procedure (cause multiorgan failure). In all patients total occlusion of PDA was confirmed the day after the procedure. No protrusion of the device to aorta nor pulmonary artery was seen in any patient in follow up.

CONCLUSIONS

Application of Amplatzer Duct Occluder type II Additional Sizes is a good therapeutic option to treat adequate PDA. The implant may successfully substitute coil implantation in all age groups.

RESIDUAL POSTSURGERY PERIMEMBRANOUS VSD CLOSURE

Jorge Gomez

Hospital Nacional Alejandro Posadas, Buenos Aires, Argentina

HISTORY AND CLINICAL EXAMINATION

Female patient, five years old with a history of pm VSD and subaortic fibromembranous stenosis. She underwent surgery at the age of 9 months (VSD closure, subaortic membrane resection and myomectomy). Seven days later TTE reported residual VSD of 2 to 4 mm with left to right shunt. Patient was periodically examined until the age of 4 years. During this period, she always presented an holosystolic murmur 2–3/6 EKG reported Sinus rhythm 100 beats per minute PR0, 14" Qtc 0,41" with complete right bundle block (RBB). Holter reported only RBB as relevant information. TTE showed a gradually increasing 4 to 6 mm sub aortic residual pmVSD due to patch dehiscence, with closure mechanism. The defect was somehow difficult to delimitate. Aliasing of colour doppler was visualized over the free wall of right ventricle (RV) LA/Ao ratio 1.3. Left end diastolic and left end systolic diameters were within normal limits. In four chamber view, LA and LV areas were predominant (Fig.1) and increased pulmonary vein flow were considered indirect signs of elevated pulmonary flow due the left to right shunt across the residual defect. Diuretic treatment was prescribed and there was a slope in gaining weight. We considered the possibility of percutaneous closure to avoid another surgery.

INDICATION FOR INTERVENTION

Residual defect, volume overload, risk of endocarditis

INTERVENTION

Catheterization was performed under general anesthesia, elective intubation and trans-esophageal echocardiography (TEE) guidance. Remaining VSD on LV side measured 5 to 6 mm. Another small VSD was visualized more proximal to the aortic valve. Extension through posterior annulus of the tricuspid valve and colour aliasing were also observed under the anterior leaflet of the tricuspid valve next to the free wall of the right ventricle (Fig. 2). Dehiscent patch was visualized in the short axis view.

The pulmonary artery pressure measured 27/10 (16) mmHg while the systemic pressure was 80/45 (65). The ratio of pulmonary to systemic flow (Qp:Qs) was 1.68:1 on room air. The LV angiogram was obtained in 20° left anterior oblique (LAO) view and 60° cranial. The image obtained in this angiogram revealed the defect was more complex than just a residual leak from a patch dehiscence. There were two connections, one superior of 2 mm and the other inferior. This last one measured 6 mm from the left ventricle (Fig.4) These two VSD or more likely openings from the LV, connected to a tunnel excavated under the annulus of the tricuspid valve. Through the trabeculae; shunt passed to the RV next to the free wall rather than next to the septum; as a common VSD or patch dehiscence.

We first attempted to close this defect using a Nit Occlud Le- VSD device. With a Judkins Right catheter we passed through the defect, advanced a Terumo guidewire to the left pulmonary artery and then snared this to establish an arteriovenous loop. We intended to advance the introducer catheter of Nit Occlud device. Despite the well-established arteriovenous loop of the guidewire, the introducer catheter never could advance to the RV. After several attempts and even repeating new arteriovenous loop, we concluded that this impossibility was due to morphological aspects of the defect excavated through trabeculae of RV and we would never be able to close this defect through venous approach. After analyzing echo and angiographic images for better interpretation, we decided to recatheterize and close defect through arterial access with other device. This time we selected a PDA II AS device. We positioned a Torq Vue catheter 4fr and tried to deploy the device in the middle part of the defect in order to close both defects or opening but the device jumped from this position to the superior opening next to the aortic valve. The device was well positioned and released without complications. A second device PDA II was positioned through the inferior defect, and released without complications. No changing on EKG were reported immediately and or later after the procedure, there was no enlargement of QRS more than the described RBB. Patient was extubated Echocardiogram performed within 24 hours showed devices in proximity to aorta. No obstruction to left outflow tract, mild aortic regurgitation which was present before procedure. No left to right shunt was detected and colour aliasing next to RV free wall under tricuspid valve disappeared. Patient left the hospital uneventfully. Aspirin was indicated 5 mg/kg per day for six months.

FOLLOW-UP

She remained clinically stable. Diuretic medications were discontinued. ETE reported no shunt. Holter reports RBB, which was present before the procedure.

LEARNING POINTS

First attempts to close pm VSD encountered a relatively high rate of early and late third degree atrioventricular block. Other complications reported in the literature were embolization, hemolysis, and transient rhythm disorders. Despite the major complication described above; which probably discouraged many interventionists to consider percutaneous closure of pm VSD; reports of this procedure with good results have steadily increased over the past ten years. This is probably a result of the combination of two conditions: the use of devices specifically designed for this defect or off label use of other devices such as PDA closure devices with softer material and no stenting purposes of the defect; and a better selection of cases, for example, pm VSD with closure mechanism. Although venous arterial loop is the most standard technic, arterial access may be the only approach possible. The need for more than one device should also be considered. Using off label devices should probably clear the path for better

designs. These must avoid in order of importance, third degree block, conduction disturbance, hemolysis and residual leaks. Hemolysis could be managed with medication, or a second intervention. Small residual leaks without hemodynamic compromise or hemolysis should be clinically followed because these may close by endothelium growth covering the implanted device.

Figure 1

Left atrium enlargement

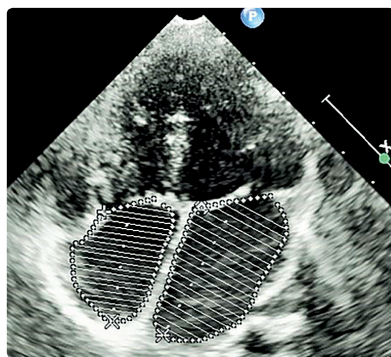
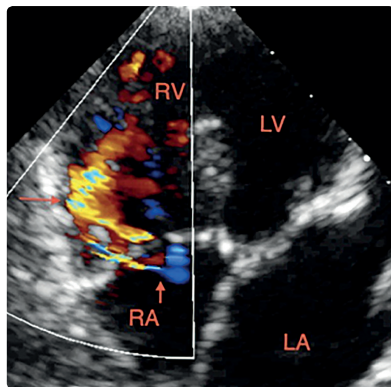


Figure 2

Color aliasing over right ventricle free wall



SURVEY INTO CURRENT PERCEPTIONS AND PRACTICE OF DEVICE CLOSURE OF PATENT FORAMEN OVALE FOR CRYPTOGENIC STROKE IN THE UNITED KINGDOM

Katherine von Klemperer¹ / Aleksander Kempny¹ / Edward Nicol² / Anselm Uebing²

¹ St Bartholomews Hospital, London, UK

² The Royal Brompton Hospital, London, UK

BACKGROUND

Patent foramen ovale (PFO) closure for cryptogenic stroke (CS) remains controversial due to a lack of conclusive randomized control data. Many experts feel that PFO closure is indicated in select cases, however international guideline recommendations are not uniform.

OBJECTIVE

We conducted a survey of UK cardiologists and stroke physicians/neurologists to determine specialist interpretation of the evidence and gain insight into current UK Practice.

METHODS

The British Cardiac Society and British Society of Stroke physicians distributed our survey using an online platform (www.surveymonkey.com) in January 2015.

RESULTS

120 physicians (70 stroke physicians, 23 neurologists, 27 cardiologists) completed the survey. Most (89%) felt PFO closure should be considered in selected patients. Atrial fibrillation (86.6%), significant carotid stenosis (86.6%), diabetes (38.4%), hypertension (36.6%) were considered exclusion criteria for CS diagnosis. Only 37% cardiologists vs 70% non-cardiologists ($p=0.001$) used an age cutoff for implicating PFO in CS. Features believed to support the case for PFO closure were aneurysmal septum (89.6% of respondents), shunt size (73.6%), prominent Eustachian valve (16%). 60% discuss their patients in a multidisciplinary meeting forum prior to decision regarding PFO closure (77% of cardiologists vs 55% non-cardiologists $P=0.045$). After PFO closure patients are managed with Clopidogrel (by 72.3%), Aspirin (50%) or anticoagulants (17%). 63.2% of respondents continue therapy in patients for a limited period after PFO closure, 34% prefer life-long therapy (14.8% cardiologists vs. 40.5% non-cardiologists $P=0.021$).

CONCLUSION

Whilst experts do support selective PFO closure in CS current practice remains variable with significant differences in perceptions of cardiologists and neurologists.

TRANSCATHETER CLOSURE OF CORONARY CAMERAL FISTULA

Anwar Khan
Global Hospital, Jalandhar, India

HISTORY

A 35-year-old man had presented with palpitation and breathlessness on exertional activities. There was no angina.

PHYSICAL EXAMINATION

Revealed no musculoskeletal abnormality, no cyanosis and no clubbing. His pulse was of normal volume, 80 per minute and blood pressure was 130/70 of mm of Hg. Cardiovascular examination revealed LV apical impulse, normal heart sounds and continuous murmur at LV apex.

ECG

Showed sinus rhythm and no chamber enlargement and no sign of ischemia.

ECHOCARDIOGRAPHY

Showed normal LV and RV size and coronary to RV fistula with continuous Doppler signals.

CORONARY ANGIOGRAM

It revealed dilated and tortuous large type3 left anterior descending artery and a large fistula from distal LAD to right ventricle.

PROCEDURE

Left coronary artery was hooked with JL4-6F guiding catheter and LAD fistula was crossed with floppy Terumo. 035 wire and it was retrieved from RA to right internal jugular vein to make arteriovenous loop. Then a JR4-6F guiding catheter was passed over retrieved Terumo wire from right IJV and was positioned in LAD from RV side as a delivery catheter. Then a 4 mm muscular VSD Amplatzer device was pushed into guiding catheter from RV side and opened its distal disc in LAD and pulled back at fistula site. After confirming its position with left coronary angiogram, a 3.5×20 mm coronary balloon was inflated in LAD to have optimal position and profile of distal disc in LAD and then it was deployed. Final angiogram showed complete closure of fistula and good distal run-off in distal LAD.

He was put on Clopidogril and Aspirin. He showed marked symptomatic improvement, and repeat coronary angiogram after three months showed device in situ, no residual shunt and good flow in LAD with no evidence of stenosis or thrombosis in LAD.

LEARNING POINT

Varieties of coronary cameral fistulas require different treatment according to their size and site. Most of the fistulas are closed with coil embolizations. But in present case it was a significant size of fistula and a large size LAD which required myocardial preservation too, beside closing the shunt. A successful closure of coronary cameral fistula was done with muscular VSD device and was followed up with good outcome with dual antiplatelet therapy. I have not come across any previous report where coronary cameral fistula was closed with VSD device.

INITIAL EXPERIENCE OF COCOON SEPTAL OCCLUDER IN CHINESE PATIENTS IN HONG KONG

Gary Cheung
Prince of Wales Hospital, Hong Kong, China

BACKGROUND

Percutaneous transcatheter closure with double disc occluder is the preferred method for the majority of patients with secundum atrial septal defect (ASD) currently. Despite high closure rate and few major complications, the current device has been rarely associated with life-threatening aortic erosions and severe allergic reactions due to nickel leakage into blood stream. Compared to non-coated nickel containing occluders, the important properties of Cocoon Septal Occluder (CSO) are the nanoplatinum coating and its softness resulting predominantly from the removal of the oxide of Nitinol during its preparation process.

OBJECTIVES

The aim of this study was to examine the initial experience and results of usage of CSO in Chinese patients.

METHODS

We conducted a retrospective review of 10 consecutive patients that had ASD closure by CSO from August 2015 to March 2016 in Hong Kong.

RESULTS

Ten Chinese patients (7 female, 3 male) received CSO for ASD closure with intra-cardiac echographic guidance, with median age 46.6 years (range 26–59 years). 9 of them just had a single defect, and one was fenestrated ASD with three defects. Indication for closure in all cases was right heart volume overload. All of them had right heart catheterization before closure, and the shunt ratio before procedure was 2.78 (range 1.6–3.9 mmHg). Mean ASD diameter was 14.3 mm (range 8–24 mm), while the mean device diameter was 19.4 mm (range 12–30 mm). The fenestrated case received two 16 mm devices, while all others had one device only. All devices were successfully implanted without the need to change to different device size. Echocardiographic examination immediately after the procedure and at the one-month follow up showed complete closure of the defect in all patients. No complications, adverse allergy reactions or mortality were observed during the procedure or at short term follow up, mean 4 months (range 1–7 months).

CONCLUSION

This initial experience of CSO in Hong Kong indicated that this device is a reasonable and safe choice for percutaneous transcatheter closure of ASDs in Chinese patients. Moreover, CSO could also be used in fenestrated ASD closure. Further studies with longer follow up period in a larger patient size are necessary to show its efficacy and safety.

TRANSCATHETER SEPTATION OF A SINUS VENOSUS ASD WITH PARTIAL ANOMALOUS PULMONARY VENOUS DRAINAGE

Eric Rosenthal / Shakeel A. Qureshi / Tarique Hussain
Evelina London Children's Hospital, London, UK

A 60-year-old man with asthma had chest discomfort during golf. CT angiography showed minor coronary artery disease and a dilated right ventricle. MRI scanning showed a Sinus Venosus ASD (SVASD) with the right upper pulmonary vein (RUPV) draining into the low SVC. Using a 3-D printed model of the heart it was possible to demonstrate that a covered stent in the lower SVC would both close the SVASD and divert the RUPV into the left atrium. Using measurements from the model with an inflated balloon under fluoroscopy as well as the MRI images, the likely stent size was estimated. A custom-made 6 cm long, 10 zig covered CP stent was obtained together with 6 cm long BIB balloons of 24, 26 and 28 mm in diameter. A guidewire circuit was established from the RFV to the RIJ and a 34 mm sizing balloon used to test occlude the SVASD and size the SVC. A diagnostic catheter passed from the RFA/LV/LA to the anomalous RUPV allowed angiography during balloon occlusion demonstrating wide patency of the RUPV – also confirmed by transoesophageal echocardiography (TOE). The 6 cm stent mounted on the 28 mm BIB was positioned, using the guidewire circuit for stability, through an 18F sheath in the RFV and deployed without difficulty. The stent was flared in the proximal SVC. The TOE confirmed occlusion of the SVASD and unobstructed flow from the RUPV. Catheter withdrawal from the RUPV to LA did not reveal a gradient. He was discharged on aspirin and clopidogrel for 6 months.

IS ONLY A PATENT FORAMEN OVALE RESPONSIBLE FOR PARADOXICAL BRAIN EMBOLISM IN A YOUNG MAN? A CASE WITH COEXISTING PULMONARY ARTERIOVENOUS MALFORMATION

Lidia Wozniak / Maksymilian Mielczarek / Robert Sabiniewicz
Medical University of Gdansk, Gdansk, Poland

HISTORY AND PHYSICAL EXAMINATION

A 15-year-old man with no previous medical history experienced two episodes of transient ischemic attacks (TIA) within a year, which manifested in sudden dysarthria and paresis of the right upper and lower limb. He was admitted to the department of neurology where his general and neurological examination was normal. Brain magnetic resonance imaging (MRI) revealed multifocal cerebral infarctions. There was no history of atherosclerosis risk factors such as smoking, diabetes or hyperlipidemia and family history was unremarkable. His complete coagulation work-up and carotid ultrasound did not reveal any abnormalities. Therefore, paradoxical embolism was suspected. Doppler ultrasound did not reveal any potential source of embolism in deep veins of the lower limbs as well as in the iliac veins. However, transcranial Doppler (TCD) showed right-to-left shunting after saline contrast infusion. The patient was referred to the department of cardiology. On admission, he had normal physical examination, the oxygen saturation measured by pulse oximeter was 97%. Holter ecg monitoring did not reveal any arrhythmia.

IMAGING AND INDICATION FOR INTERVENTION

Transesophageal echocardiogram (TEE) showed a small shunt from the left to the right atrium across the patent foramen ovale (PFO) and right-to-left shunting with microbubbles after saline contrast infusion and Valsalva maneuver. The patient was qualified for a transcatheter closure of the PFO. A chest radiography performed prior to the procedure demonstrated a round shadow measuring 21×25 mm, located in the upper part of the left lung. Contrast enhanced chest computed tomography (CT) showed a polycyclic mass of uniform density, measuring 20×14 mm and surrounded by feeding vessels located in the central part of the upper lobe of the left lung. The image suggested vascular malformation. There was no thrombus within the PAVF and no evidence of pulmonary embolism.

INTERVENTION

Under general anesthesia we performed a selective left pulmonary arterial angiography, which revealed an arteriovenous fistula in the upper lobe of left lung (Fig. 1A). The diameter of the vessel supplying the malformation was 7 mm. Occlusion of the malformation was performed successfully by embolization using Amplatzer Vascular Plug 10 mm device (Fig. 1B). At the same time PFO closure was performed with Occlutech Figulla Flex II 23/25 mm device (Fig 2). The patient was discharged two days later. There was no recurrence of TIA at the 12 months follow up and there are no signs of right-to-left shunting in contrast TCD.

LEARNING POINTS OF THE PROCEDURE

Paradoxical embolism is considered the major cause of cerebral ischemic events in young patients. The most common cause of paradoxical embolism, which has been widely described, is right-to-left shunting at cardiac level through a PFO. An often unrecognized cause of paradoxical embolism is intrapulmonary right-to-left shunting (RLS) through a pulmonary arteriovenous fistula (PAVF). Herein, we present a case of a young man, who experienced TIA due to paradoxical embolism, in whom both abovementioned abnormalities coexisted. This coincidence is very rare (noted in only 1% of patients with cryptogenic stroke or TIA), but it highlights the importance of searching for extracardiac RLS in patients with cryptogenic stroke, even if a PFO has been detected.

PAVFs are rare pulmonary vascular malformations with direct communications between the branches of the pulmonary artery and pulmonary veins. The incidence of PAVFs is 2–3 per 100 000 population. More than 80% of PAVFs are congenital, and of these 47–80% are associated with Osler-Weber-Rendu disease. In contrast to systemic arteriovenous malformation, PAVFs do not affect cardiac hemodynamics and most patients are asymptomatic. Rarely, if RLS is large, PAVFs can cause desaturation and exertional dyspnea, cyanosis, clubbing and polycythemia. Their associated central nervous system complications include: migraine, TIA, stroke, abscess, and seizures. The reported incidence of neurological events in patients with PAVFs was 37% for TIA and 18% for stroke.

In patients with cryptogenic strokes PFOs are detected by contrast transesophageal echocardiography (c-TEE) and contrast transcranial Doppler (c-TCD). C-TEE with Valsalva maneuver is considered the „gold standard” for revealing PFOs. It is characterized by very high sensitivity and specificity. RLS can also be identified by the use of c-TCD. Recent studies demonstrate that TCD is as sensitive as TEE for revealing RLS, but it does not determine the level of RLS. To distinguish a PFO from PAVFs the timing of microembolic signals appearance in the cerebral circulation has been proposed.

In conclusion, our case highlights the importance of searching for extracardiac RLS in patients with cryptogenic stroke. The existence of PAVF should always be considered even if PFO has already been detected. For complete prevention of recurrent strokes or TIA caused by paradoxical embolism, it is necessary to not only close a PFO, but all existing shunts.

Figure 1A

Angiogram showing a single PAVF in the upper lobe of the right lung

Figure 1B

Angiogram showing complete occlusion of PAVF with 10 mm Amplatzer Vascular Plug device (arrow)

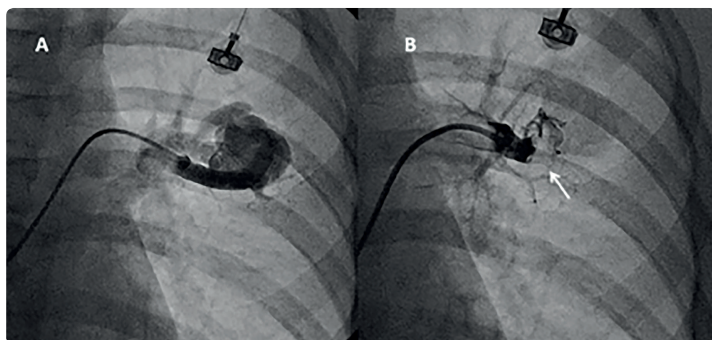
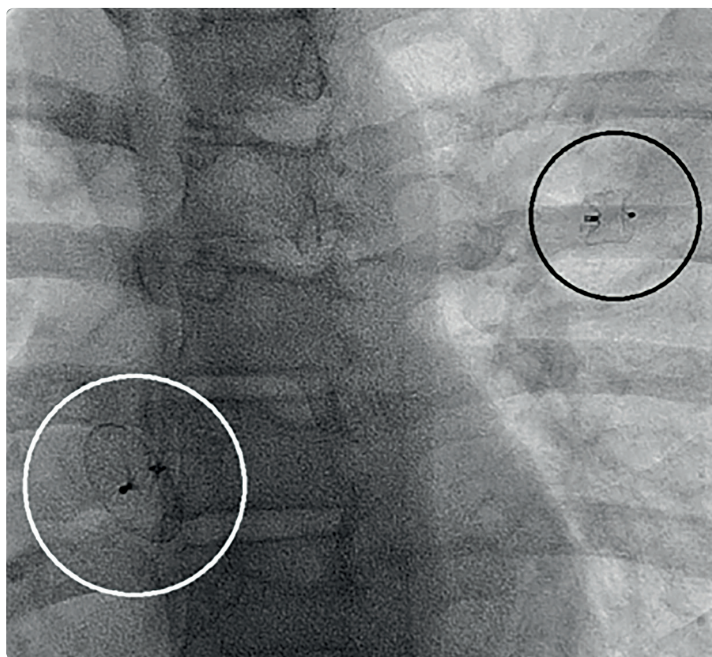


Figure 2

Chest radiograph showing two implanted devices: 10 mm Amplatzer Vascular Plug occluding PAVF (black circle) and Occlutech Figulla Flex II 23/25 mm occluding PFO (white circle)



APICAL POST INFARCT VENTRICULAR SEPTAL DEFECT TREATED WITH A GORE SEPTAL OCCLUDER

Eduardo Arias¹ / Amit Bhan¹ / Zhan Lim¹ / Guy Lloyd¹ / Michael J. Mullen²

¹ Barts Heart Centre, London, England

² The Heart Hospital, University College London Hospital, London, England

HISTORY AND PHYSICAL EXAMINATION

71 yo female patient referred to Barts Heart Centre for post MI VSD closure consideration.

PAST MEDICAL HISTORY:

- Osteoarthritis
- Hypercholesterolemia
- Ischemic heart disease:

Multivascular disease with severe mid LAD disease, circumflex artery with aberrant origin from the RCA, moderate proximal atheroma and severe discrete 90% mid-vessel stenosis. Dominant right coronary artery with a long proximal 60–70% stenosis.

She underwent elective PCI to the LAD 9 days before admission. Procedure complicated with mid LAD dissection associated with sudden onset of angina and anterior ST segment elevation. She was subsequently treated with three BMS stents to the LAD with a final TIMI 2 flow with improvement of ECG changes and symptoms. She was admitted to coronary care for observation and further medical management. Unfortunately, over the next few days she developed systemic venous congestion with progressive renal and liver failure. A new pansystolic murmur was auscultated. Clinical examination showed a raised JVP. Left parasternal pansystolic murmur. Right basal crepitations. Pulsatile hepatomegaly and lower limb pitting oedema.

IMAGING

Transthoracic echocardiogram: Left to right muscular VSD in apical septum with a peak velocity of 4.95 m/s. Moderately impaired LVSF. Moderate TR. Moderate to severe pulmonary hypertension (PASP 58–63 mmHg)

INDICATION FOR INTERVENTION

Multiorgan failure and requirement for IABP. After discussion in multidisciplinary meeting the patient was thought to be high risk for open heart surgery.

INTERVENTION

On the tenth day after failed PCI the patient underwent urgent percutaneous VSD closure under general anaesthesia with TOE guidance. Access was via right internal jugular vein and right femoral artery.

BASELINE CONDITIONS:

RA: 17/18/14 mmHg
 RV: 52/6/17 mmHg
 PA: 34/15/22 mmHg
 LV: 82/4/21 mmHg

6Fr JR4 catheter via RIJV with soft tip end of large J guidewire to PA. 6Fr Pigtail via RFA with soft tip end of large J guidewire to the LV. Ventriculogram showed apical VSD with severe left to right shunt. JR4 catheter via RFA to LV and then advanced across the VSD with a Terumo guidewire to the SVC. Terumo guidewire snared and externalised via the RIJV sheath to form an arteriovenous circuit. 30mm Gore Septal Occluder device positioned under TOE and fluoroscopy guidance and deployed successfully in good and stable position. Control angiogram and TOE showed small residual shunt with moderate TR. No complications.

POST CLOSURE CONDITIONS:

RA: 14/13/11 mmHg
 RV: 33/6/13 mmHg
 LV: 82/0/24 mmHg

LEARNING POINTS OF THE PROCEDURE

1. When considering percutaneous closure of a post MI VSD timing is crucial. The longer you can wait the better chance of success.
2. In this case, as the infarct time was less than two weeks old we assumed that the tissue was still friable and we decided to employ a device that was as soft as possible in order to minimize further septal trauma. In addition, as the defect was apical we hoped that a softer device might conform better to the anatomy.

SURVIVED A MYOCARDIAL INFARCTION AND PRESENTING WITH VENTRICULAR SEPTAL RUPTURE

Hesham Bahaeldin¹ / Ahmed Hassan¹ / Michel Nagy¹ / Sherien Abdelsalam Mohamed²

¹ Magdi Yacoub Foundation, Aswan Heart Centre, Aswan, Egypt

² Magdi Yacoub Hospital, Aswan Heart Centre, Aswan, Egypt

HISTORY AND PHYSICAL EXAMINATION

61-year-old female. She is diabetic on insulin for the past 18 years, and hypertensive on bisoprolol for 10 years.

She came to our centre complaining of shortness of breath on minimal exertion. The condition started 6 months before presentation, which was on more than ordinary effort. She remembers having an attack of severe burning chest pain that she took some antacids for and didn't seek medical advice. After this attack her symptoms began.

She had surgical history of cholecystectomy 8 years ago, and surgical debridement of a diabetic foot wound.

On examination her BP was 173/96 mmHg, HR 95/min, afebrile and with normal breathing rate.

PHYSICAL EXAMINATION:

- Congested neck veins with systolic expansion
- Fine basal crepitation bilaterally
- Lower limb pitting edema
- Peripheral pulsations couldn't be felt due to the edema of the foot
- Abdominal examination revealed tender hepatomegaly

CARDIAC EXAMINATION:

- Normal heart sounds, Pan systolic murmur could be heard over the apex and not radiating towards the axilla

IMAGING

Echo:

Concentric left ventricular hypertrophy, regional wall motion abnormality: markedly thinned out basal septum with a high muscular defect measuring 8mm with left to right shunt and a pressure gradient of 50 mmHg. Mild mitral regurgitation, moderate to severe tricuspid regurgitation, dilated right ventricle with impaired contractility.

MRI showed dilated ischemic cardiomyopathy, markedly thinned out basal septum with a high muscular ventricular septal defect. Transmural scar of the inferior septum (basal and mid) with late gadolinium enhancement.

INDICATION FOR INTERVENTION

Decompensated heart failure resistant to medical treatment.

Heart team discussion concluded that the characteristic of the defect would be feasible for transcatheter closure.

After explaining the risk of surgery to the patient, she chose the transcatheter closure approach with revascularization to the viable territory of the heart.

INTERVENTION

Under general anesthesia, arterial and venous access were obtained. 6F PT catheter in both LAO and LAO cranial view in LV showed that high muscular 8 mm VSD, using a teraumo 0.35×260 wire arteriovenous loop was done from the right femoral artery to aorta to LV, then across the VSD to the RV, then to LPA where the wire was snared to the the Rt femoral vein and then the VSD was closed using a 8.5mm muscular Amplatzer device.

PCI to LAD lesion was done after the closure of the VSD.

LEARNING POINTS OF THE PROCEDURE

- Atypical presentation of mechanically complicated missed inferior myocardial infarction
- VSD closure through the transcatheter technique is feasible and saves the patient many hazards of open-heart surgery
- Heart team discussion is a corner stone for successful combined procedures of structural and coronary interventions
- Good imaging for seizing of the defects before choosing the closure device size and type is paramount for the success of the intervention

RESTRICTIVE RIGHT VENTRICULAR PERFORMANCE ASSESSED BY CARDIAC MAGNETIC RESONANCE AFTER BALLOON VALVULOPLASTY OF CRITICAL PULMONARY VALVE STENOSIS

Ikram Massoud¹ / Nader Botros¹ / Atef Yahia¹ / Hassan Abd El Ghafoor¹ / Mohamed Donya² / Ahmed Samir³ / Elham Selim⁴ / Heba Tolba³

¹ National Heart Institute, Cairo, Egypt

² Cairo University, Cairo, Egypt

³ Ein Shams University, Cairo, Egypt

⁴ National Heart Institute, Cairo, Egypt

BACKGROUND

Little data are published about right ventricular diastolic performance in patients with critical pulmonary valve stenosis after balloon pulmonary valvuloplasty thus far.

METHODS

A total of 44 patients with isolated critical pulmonary valve stenosis who had undergone balloon valvuloplasty with haemodynamic recordings were enrolled in the study; 33 patients who came for follow up underwent further imaging by echocardiography after 6 months and their right ventricular functional parameters were compared with 33 control patients of the same age and sex. Out of 33 patients, 21 underwent cardiac MRI with late gadolinium enhancement to assess the presence of right ventricular fibrosis.

RESULTS

The right ventricular systolic pressure ($p<0.0001$) and right ventricular out flow tract gradient ($p<0.0001$) decreased acutely ($p<0.0001$) after balloon valvuloplasty. During follow up, M-mode left ventricular end diastolic dimension ($p<0.001$) and end systolic dimension increased ($p<0.001$), whereas right ventricular end diastolic dimension decreased ($p<0.001$). Compared with controls, patients ($n=33$) had significantly reduced tricuspid annular Ea and higher E/Ea ($p<0.001$). Right ventricular systolic dysfunction was also suggested by reduced tricuspid annular systolic velocity ($p<0.001$). Late gadolinium enhancement was demonstrated in 13 out of 21 patients with restrictive physiology, which involves the anterior right ventricular outflowtract, anterior wall, and inferior wall. The right ventricular late gadolinium enhancement score correlated positively with age ($r=0.7$, $p<0.001$) and right ventricular mass index ($r=0.52$, $p<0.001$).

CONCLUSION

The persistence of fibrosis is the most likely factor responsible for persistence of restrictive physiology as documented by late gadolinium enhancement.

VALVE IN VALVE TAVI IN A FAILING 29 MM SHELLHIGH CONDUIT USING A 27MM LOTUS VALVE

Zhan Yun Lim¹ / Eduardo Arias² / Amit Bhan¹ / Michael J. Mullen³

¹ Barts Heart Centre, London UK

² National Institute of Cardiology, Mexico City, Mexico

³ The Heart Hospital, London, UK

HISTORY AND PHYSICAL

78-year-old male who presented with refractory heart failure and a background of increasing breathlessness over the last 3 months. He remained on intravenous diuretics and was limited to his bed due to breathlessness.

His past surgical history includes 3 previous sternotomies for aortic valve surgery with the most recent being a shellhigh conduit 10 years ago after an episode of endocarditis.

His other past medical history includes chronic kidney disease with an eGFR 25.

IMAGING

Pre-procedural imaging demonstrated moderate left ventricular function impairment with a flail non coronary cusp and severe aortic insufficiency.

Cardiac CT imaging of the aortic valve revealed minimal calcification of the aortic root and annular sizing was difficult due to the tubular shape of the conduit and identifying the position of the aortic annulus.

INDICATION FOR INTERVENTION

He was turned down for conventional redo aortic valve surgery as he took a month to come off the ventilator from his last procedure and this would be his 4th sternotomy.

He was in refractory heart failure and the heart teams' consensus was to proceed with valve in valve TAVI urgently.

INTERVENTION

Pre-procedural planning: In view of the lack of calcification and fluoroscopic landmarks, the procedure was done under general anaesthesia to allow the use of intra procedural transoesophageal imaging to assist in positioning of the valve.

The internal diameter was measured to be 25mm on CT which would be compatible with the manufacturer's measurement. However, we could not be absolutely certain that the measurements were accurate due to the above mentioned difficulties.

A sizing balloon will be used during the procedure to confirm the annular diameter.

PROCEDURE

Bilateral femoral arterial access was established and the right internal jugular vein was cannulated.

A 4 french balloon flotation temporary pacing wire was placed in the right ventricular apex and a large Lotus introducer sheath was inserted in the right femoral artery.

A 30 mm sizing balloon was utilized and sized the annulus to 24.8mm. The aortic valve was crossed with a pigtail and exchanged for a SAFARI II wire. TOE guidance was utilized during the procedure to guide optimal implant depth along with the pigtail catheter in the right coronary cusp. A 27 mm Lotus valve was implanted in an excellent position.

Post procedure echocardiogram demonstrated a mean gradient of 3mmHg and no visible aortic regurgitation with mild improvement in the left ventricular systolic function.

LEARNING POINTS OF THE PROCEDURE

Treatment for failing aortic bioprosthesis needs to be timely to allow for good outcomes. Valve in valve TAVI in stentless prosthesis could benefit from adjunctive imaging including the role of sizing balloon, TOE guidance and the use of a fully repositionable system.

OFF PUMP MINIMALLY INVASIVE TREATMENT OF SEVERE DEGENERATIVE MITRAL VALVE DISEASE AND CONCOMITANT CORONARY ARTERY DISEASE: HYBRID APPROACH

Agne Drasutiene / Kestutis Rucinskas / Arturas Lipnevicius / Vilius Janusauskas / Diana Zakarkaite / Giedrius Davidavičius / Audrius Aidietis
Vilnius University, Vilnius, Lithuania

HISTORY AND PHYSICAL

Two patients were admitted to our hospital due to dyspnea (New York Heart Association functional class III despite optimal medical therapy) and reduced physical capacity.

1st patient: 79-year-old symptomatic male with severe mitral valve regurgitation and concomitant two coronary artery disease (Obtuse marginal branch – 90% and left anterior descending artery – 75%).

2nd patient: 86-year-old symptomatic male with severe mitral valve regurgitation and concomitant single vessel disease (LAD – 75%).

IMAGING

The pre-procedure transthoracic (TTE) and transesophageal echocardiography (TEE, 3D TEE) confirmed the degenerative mitral valve disease with presence of severe MR with isolated P2 prolapse (Figure 1 and 2). LV systolic function was normal with ejection fraction greater than 55%.

Preoperative coronary angiography revealed CAD amenable to PCI for both patients.

INDICATION FOR INTERVENTION

Both patients were discussed in multidisciplinary “heart team” meeting and single-stage approach of minimally invasive off-pump mitral valve repair with artificial chords implantation combined with PCI was selected as the treatment of choice.

INTERVENTION

Both patients have undergone coronary stenting. Standard antiaggregation treatment (325 mg of Aspirin and loading 600 mg dose of Clopidogrel) before stenting was administered. PCI followed by off pump transapical mitral valve repair using Neochord DS 1000 device. Surgery was done on beating heart, through a left anterolateral thoracotomy, under transesophageal echocardiographic guidance. 1st patient had 3 chords implanted to P2 segment. 2nd patient had 4 chords implanted to P2 segment. None of the patients had any serious adverse events. Both patients have improvement of symptoms (NYHA II), and had MR 1+ at one month follow up.

LEARNING POINTS OF THE PROCEDURE

Hybrid procedure (coronary artery stenting followed by off pump transapical implantation of artificial chordae) is an option for treating patients with severe mitral valve regurgitation and concomitant coronary artery disease.

Figure 1

First patient: (A, B, C) before the procedure and (C, D, F) – after the LAD and obtuse marginal branch PCI and Neochord implantation on P2 segment

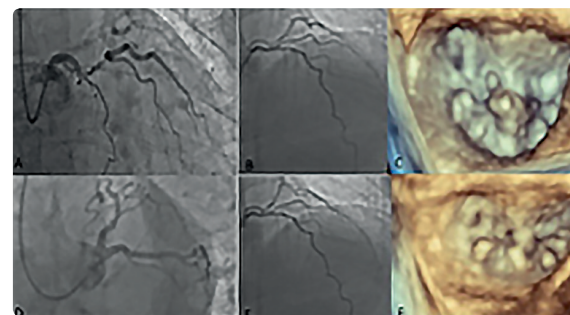
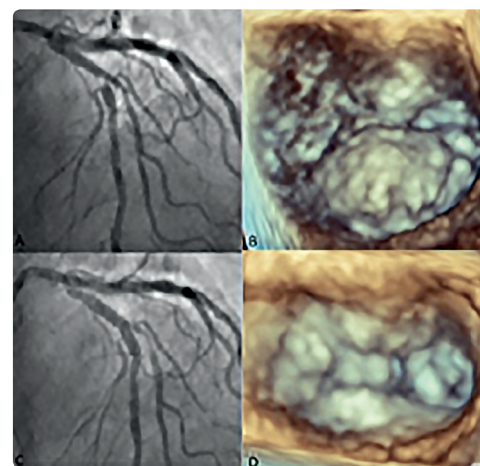


Figure 2

Second patient: (A, B) before and after (C, D) the LAD PCI and Neochord implantation on P2 segment



TAVI IN A LATE FAILING TAVI

Zhan Yun Lim¹ / Majid Akhtar¹ / Eduardo Arias² / Amit Bhan¹ / Roshan Weerackody¹ / Simon Kennon¹ / Anthony Mathur¹

¹ Barts Heart Centre, London UK

² National Institute of Cardiology, Mexico City, Mexico

HISTORY AND PHYSICAL

85-year-old male who presented with heart failure and 6 months of increasing breathlessness on exertion.

His background included transapical TAVI with a 26 mm Cribier-Edwards valve in 2009, porcelain aorta, hypertension, CKD, JAK2 positive thrombocytopenia and COPD.

He had an episode of strep sanguinis endocarditis with splenic infarcts in 2012 but treated medically and settled.

IMAGING

Pre-procedural transthoracic and transoesophageal imaging demonstrated a healed vegetation with severe transvalvular aortic regurgitation. There was good left ventricular systolic function.

Cardiac CT imaging confirmed a well sited TAVR prosthesis and an internal diameter of 24 mm. The femoral arteries were felt to be torturous and calcified but with a large luminal area.

INDICATION FOR INTERVENTION

He was an 85-year-old male with symptomatic severe aortic regurgitation. The patient was turned down for conventional surgery 6 years ago due to porcelain aorta. The heart teams' consensus was to offer him a valve in valve TAVI.

INTERVENTION

The right radial artery was cannulated for contralateral access and the left femoral artery was selected for the main access site. A surgical cut down approach was selected due to the heavy calcification of the femoral arteries.

The right femoral vein was cannulated and a 6 french temporary pacing placed at the right ventricular apex.

The Cribier-Sapien valve was crossed with a pigtail catheter and exchanged for an Amplatz superstiff wire.

A 26 mm S3 valve was chosen. The 20 mm frame height was felt to be suitable for the 16 mm frame height of the Cribier-Sapien valve. The plan was to deploy the valve in a more ventricular position to allow for the S3 skirt technology to work optimally.

Deployment of the 26 mm S3 valve was deliberate and slow with the center marker placed at the annular position. The valve was implanted successfully and the patient was discharged uneventfully after 3 days.

The patient remained well at his 1 year follow up with NYHA class I symptoms. His echocardiogram demonstrated a well seated TAVR with a peak gradient across the valve measuring 17 mmHg and a mean gradient of 8 mmHg with no paravalvular leak.

LEARNING POINTS OF THE PROCEDURE

A slow implant with valve in valve TAVI using balloon expandable devices is important as that allows minor adjustments to obtain the optimal results. TAVI in TAVI has been performed in emergency settings due to suboptimal result but this is a first TAVI in a failing TAVI prosthesis. Optimal implant position for TAVI in TAVI will require contribution from the rest of the TAVI community.

INNOVATIVE PERCUTANEOUS SOLUTION TO TREAT TRICUSPID VALVE DISEASE

Azeem Latib¹ / Paolo Denti¹ / Jean-Michel Juliard³ / Alec Vahanian³ / Francesco Maisano²

¹ San Raffaele University Hospital, Milan, Italy

² UniversitaetsSpital Zuerich, Zuerich, Switzerland

³ Hopital Bichat, Paris, France

A 77-year-old female patient, with severe functional TR was admitted in NYHA class III after several episodes of decompensated heart failure. Other comorbidities were moderate renal impairment (GFR 52 ml/min) and persistent atrial fibrillation. She had a clinical history of COPD and prior surgical treatment for cardiac tamponade due to AF-ATC. Due to her condition this patient was considered by the institutional heart-team a suitable candidate for the TriCinch procedure.

Transesophageal echocardiography confirmed grade 4+ TR (with septolateral dimension of 41 mm and TV area of 10.2 cm²) (Figure 1a), moderate right ventricular dysfunction, a normal functioning mitral valve and normal left ventricular ejection fraction.

After multidisciplinary heart team agreement on the transcatheter TV repair option (high-risk surgical candidate with a Logistic Euroscore of 23.95% and Euroscore II of 6.42%), it was decided to treat the patient with the TriCinch System (4Tech Cardio Ltd., Galway, Ireland). This is a percutaneous device designed for TV remodeling, by means of a transfemoral fixation of a stainless steel corkscrew into the anteroposterior TV annulus. The corkscrew is then connected through a Dacron band to a self-expanding Nitinol stent. By pulling the system towards the inferior vena cava (IVC), the anchoring corkscrew remodels the anteroposterior annulus, and the tension is maintained by fixation of the stent in the IVC. (Figure 2a). The procedural planning was based on the cardiac CT scan and predicted the safe anchoring area at the level of the anterior tricuspid annulus (between the right coronary artery and anterior leaflet's hinge) (Figure 2b). With an IVC mean diameter of 21 mm an adequate stent size was chosen to guarantee a 60% vessel oversizing.

The intervention was performed under general anesthesia, fluoroscopy, as well as intracardiac and transesophageal echocardiography guidance. A Gore Dryseal sheath was inserted in the right femoral vein for insertion of the steerable TriCinch delivery system into the right atrium. The tip of the delivery system was steered toward the target area on the tricuspid annulus and there the corkscrew was inserted. Any interference with the right coronary artery was ruled out by selective angiography. The system was tensioned under echo guidance until a reduction in septolateral dimension (from 41 mm to 31 mm) and in TR grade (from 4+ to 1+) (Figure 1b) was observed. The cinching of the tricuspid annulus was maintained

by implantation of a 43-mm self-expanding Nitinol stent in the IVC (Figure 2b). The procedure was completed uneventfully in 47 min, demonstrating the feasibility and safety of the percutaneous remodeling of the TV by implanting the TriCinch device, associated with reduction in annular dimensions and TR severity.

Figure 1

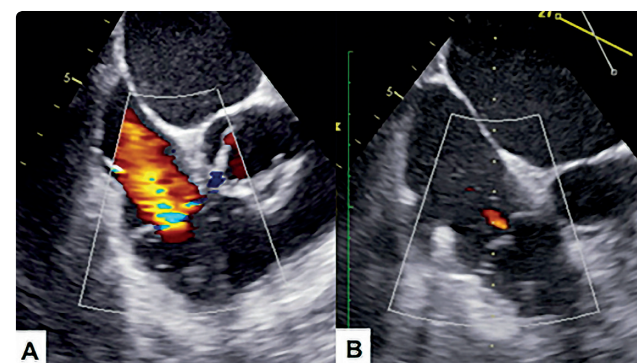
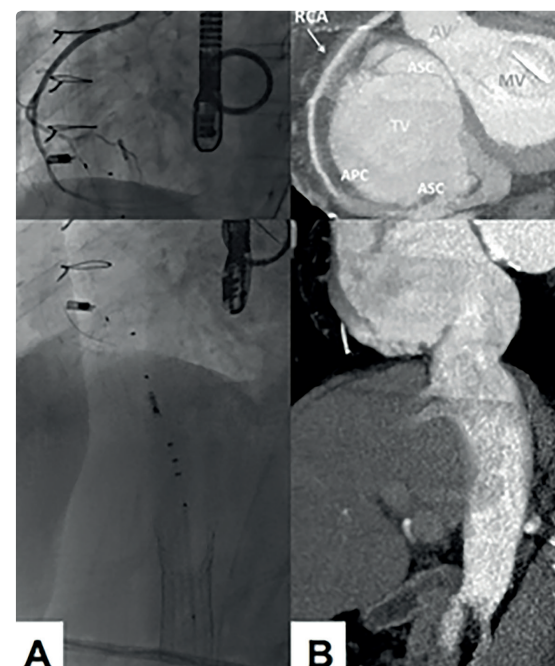


Figure 2



A SIMPLIFIED AND REPRODUCIBLE METHOD TO SIZE THE MITRAL ANNULUS; IMPLICATIONS FOR TRANSCATHETER MITRAL VALVE REPLACEMENT

Mohammad Abdelghani¹ / Ernest Spitzer² / Hiroki Tateishi³ / Rafael Cavalcante³ / Yohei Sotomi¹ / Erhan Tenekecioglu³ / Yoshinobu Onuma³ / Jan G Tijssen¹ / Robbert de Winter⁴ / Patrick W Serruys⁵

¹ University of Amsterdam, Amsterdam, The Netherlands

² Cardialysis Clinical Trials Management and Core Laboratories, Rotterdam, The Netherlands

³ Erasmus University, Rotterdam, The Netherlands

⁴ Academic Medical Center Amsterdam, Amsterdam, The Netherlands

⁵ Imperial College London, London, UK

BACKGROUND

Surgical correction remains the mainstay of therapy for mitral regurgitation (MR) but is deferred in many patients because of high surgical risk. Transcatheter mitral valve replacement (TMVR) provides definitive valve replacement through a minimally-invasive procedure. Multislice computed tomography (MSCT) provides complete evaluation of the mitral annulus (MA). In the setting of TMVR, it is unclear how relevant the differences between different MA diameters are.

OBJECTIVE

We sought to determine the best annular diameter to use for TMVR device size selection.

METHODS

Using contrast MSCT studies of 30 patients with functional MR, the 3D MA perimeter (P3D) was annotated. The method of the least squares was used to generate the projected MA area (Aproj) and perimeter (Pproj). The following MA diameters were measured: intercommissural (IC) and septo-lateral (SL) diameters, Dmean = (IC diameter + SL diameter)/2, area-derived diameter (DA = $2 \times \sqrt{A/\pi}$) and perimeter-derived diameter (DP = P/π). MA eccentricity, height and calcification (MAC) were also measured. All measurements were performed in mid-diastolic reconstructions to depict the largest MA size. All included studies were re-read by the same and by another observer to test intra- and inter-observer reproducibility.

RESULTS

Patients (age, 79.6 ± 12.1 years, 67% males) had a wide range of MR severity (none-trace in 9.5%, mild in 62%, moderate-severe in 28.5%), MA size (area: 5–15 cm²), eccentricity (3–52%) and height (3–11 mm). MAC was seen in one third of cases and its arc circumference occupied 21 ± 14% of the MA circumference.

DArea (34.94 ± 3.73 mm) and DPerimeter (36.26 ± 3.52 mm) correlated strongly (R2 = 0.96) and were not significantly different (p = 0.16). DPerimeter was larger than DArea in all patients. The average difference was +1.32 mm and the 95% limits of agreement were 2.77 and -0.12 mm. The difference increased with increasing annular eccentricity (r = 0.80, p < 0.001).

The IC (38.10 ± 4.04 mm) and the SL (30.47 ± 4.45 mm) diameters were significantly different from the DArea (p = 0.003 and < 0.001, respectively). Dmean (34.29 ± 3.76 mm), however, did not differ from DArea (p = 0.5). The correlation of DArea was stronger with Dmean (R2 = 0.95) than with IC and SL diameters (R2 = 0.69 and 0.79, respectively). Similarly, DPerimeter was more tightly correlated with Dmean (R2 = 0.91) than with IC (R2 = 0.78) and SL (R2 = 0.65) diameters.

DArea tended to be slightly larger than Dmean. The average difference between DArea and Dmean was +0.66 mm and the 95% limits of agreement were 2.33 and -1.03 mm. DPerimeter was larger than Dmean in all cases. The average difference was +1.98 mm and the 95% limits of agreement were 4.21 and -0.25 mm.

Overall reproducibility was good; the intraclass correlation coefficients were high (0.93–0.98), the average biases were small (0.37–1.1 mm), and the coefficients of variation were low (3–7%) for intra- and inter-observer comparisons of all diameters. Reproducibility was however slightly less and variability slightly more for SL and IC diameters than for Dmean, DArea and DPerimeter.

CONCLUSION

MSCT represents a versatile tool that yields a high feasibility and reproducibility of MA sizing. Dmean, rather than IC or SL diameters, should be used to infer the effective MA size.

PERATRIAL DEVICE CLOSURE OF DIFFERENT LOCATIONS OF MITRAL PARAVALVULAR LEAKS USING A PROBE-ASSISTED DELIVERY SYSTEM

Li Hongxin / Guo Wenbin / Hai-Zhou Zhang / Gang Zhang / Fei Liang
Shandong University, Jinan, China

HISTORY AND PHYSICAL

Prosthetic mitral paravalvular leak (MPVL) is a serious complication after surgical valve replacement. The transcatheter closure of MPVLs, including antegrade transseptal, retrograde transaortic and transapical approaches, is often a long, technically demanding procedure. Each of these techniques is only suitable for some specific anatomic locations of the MPVLs. The technical challenges that need to be overcome come from transseptal puncture, accessing the PVL site, deploying the appropriate occluders and the absence of dedicated delivery systems for percutaneous approach. In this study, we introduce a new minimally invasive technique of peratrial device closure of different locations of MPVLs using a probe-assisted delivery system under real-time three-dimensional transesophageal echocardiography (3D TEE).

Between March 2013 and November 2015, this technique was applied to 6 MPVL patients (four male, two female), aged 58, 47, 23, 49, 67 and 30 years, respectively. They presented with worsening exertional dyspnea (NYHA class II to IV) and palpitation. TEE showed moderate to severe MPVL through an oblong- or crescent-shaped hole that was located in different locations of the mitral prosthetic annulus. Five patients had previously undergone metallic (n=4) or tissue (n=1) mitral valve replacement 5 months to 9 years before. One patient had a history of combined mitral and aortic valve replacement with two mechanical prostheses 11 years before. Two patients had a hemolytic anemia (hemoglobin between 7.6–9.0 g/dL) requiring blood transfusions before admission.

IMAGING

After general anesthesia, the patients were placed in a supine position. The exact anatomic locations and spatial orientations of the PVLs were evaluated by real-time 3D TEE. The MPVL origin of these patients located respectively at 9 to 10, 5 to 6 and 2 to 3 o'clock of the mitral clock-face from the surgeon's view (Fig 1 A-D). The MPVL was an oblong-shaped hole in 3 patients and a crescent-shaped hole in 3 patients. The size of the MPVLs was measured as 7×5, 10×4, 6×5, 8×4, 8×5, and 5×4 mm, respectively.

INDICATION FOR INTERVENTION

Indication for this technique includes MPVLs at different locations without instability of the prosthetic mitral annulus.

INTERVENTION

A 4.0 cm parasternal incision was made in the fourth right interspaces. The projecting part of the pericardium in front of the right atrium was chosen and opened. A pursestring suture using 4–0 polypropylene was placed on the pericardium or the right atrium. Following intravenous administration of heparin (1mg/kg), an 8F dilating sheath loaded with a puncture needle was inserted into the right atrium. The sheath was short and perpendicular to the septum (Fig 2A). It was easy for the sheath to choose an appropriate location to puncture. The interatrial septum was punctured superiorly or/and posteriorly and dilated followed by a guidewire passing through the septum (Fig 2B). A specially designed J-shaped bendable hollow probe was advanced over the wire into the left atrium. Under TEE guidance, the steerable hollow probe was adjusted to point to or cross the MPVL and introduced an extra stiff guidewire across the leak into the left ventricle through the channel of the probe (Fig 2C). An 8F short delivery sheath was advanced over the stiff wire through the MPVL into the left ventricle (Fig 2D). A proper sized muscular septal occluder (6 to 12 mm in this series) with the waist 5 mm in length was then selected and deployed in the MPVLs. In two patients with crescent-shaped MPVL, residual regurgitation was still significant after the first device is deployed. The occluder was withdrawn while maintaining the delivery sheath in the left ventricle. Two guidewires were passed through the sheath to the left ventricle. After the 1st device was anchored, a 6F delivery sheath was advanced to the LV over the second wire alongside the 1st device (Fig 2E). Then the second device was implanted (Fig 2F). After ensuring proper stability with a standard push-pull test, the occluders were released. Once a satisfactory effect was proven, the sheath and cable were removed and the puncture site of the right atrium was closed with pursestring sutures. The pericardium was partially closed without placement of a drainage tube.

RESULTS AND LEARNING POINTS OF THE PROCEDURE

TEE revealed complete occlusion of the MPVL in 5 patients, with no residual leak and a good function of the prosthetic MV. They recovered uneventful and were discharged on postoperative day 4 to 7, with stable results after a follow up of 3 months to 2 years. Residual paravalvular regurgitation occurred in one patient with a crescent-shaped MPVL due to lack of experience of implanting double devices for closure. Although there was evident marked reduction in the degree of paravalvular regurgitation in this patient, decreased hemolysis and hemoglobinuria still existed at the 3-month follow up. All patients' symptoms of heart failure improved by at least 1 New York Heart Association functional class.

The probe-assisted delivery system can access and close the MPVLs at different locations through a right minithoracotomy-peratrial approach. This peratrial technique has the advantages of the perpendicular short entry route to the

septum which permits easy and precise transeptal puncture, easy manipulation and directional control of a short bendable hollow probe, no need to establish an arteriovenous guidewire rail, and no exposure to radiation.

Figure 1

Different locations of mitral paravalvular leaks (MPVL). Arrows = MPVL

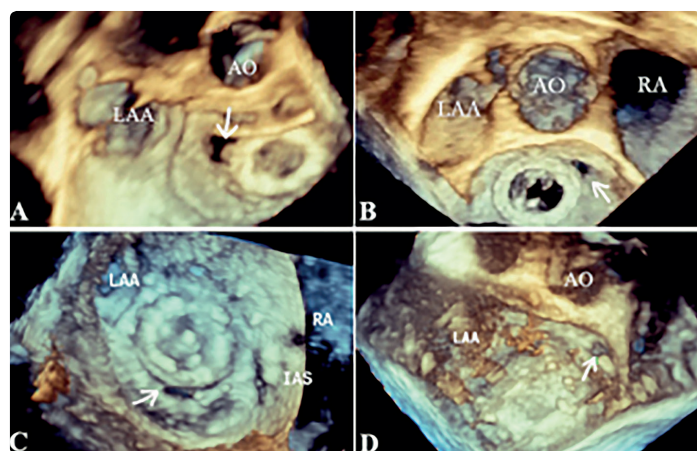
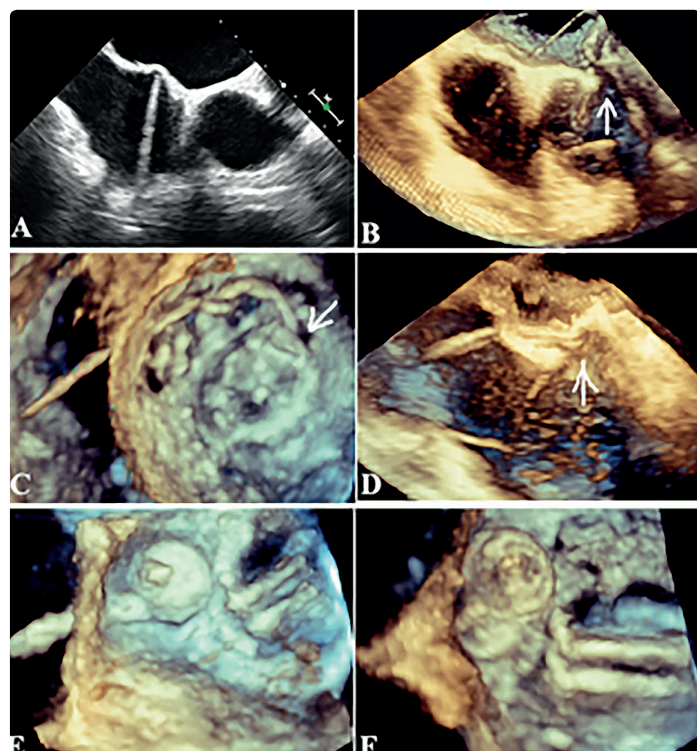


Figure 2

Steps of peratrial device closure of mitral paravalvular leak using a probe-assisted delivery system



CORRELATION OF COREVALVE IMPLANTATION 'TRUE COVER INDEX' WITH SHORT AND MID-TERM AORTIC REGURGITATION; IMPLANTATION DEPTH REALLY MATTERS

Manolis Vavuranakis / Konstantinos Kalogeras / Maria Lavda / Angelos Michail Kolokathis / Myrsini Stasinopoulou / Dimitrios Vrachatis / Maria Kariori / Carmen Moldovan / Evelina Bei / Sophia Vaina / Gerasimos Siasos / Euaggelos Oikonomou / Dimitrios Tousoulis
University of Athens, Athens, Greece

BACKGROUND

Aortic regurgitation (AR) after TAVI has been demonstrated to be related to impaired long-term prognosis. 'Cover index' has been proposed to appraise the congruence between the aortic annulus and the device, with the assumption of not taking into account the actual device implantation depth.

OBJECTIVE

We investigated whether the annulus-prosthesis mismatch, as expressed with the 'true cover index' according to actual implantation depth, is correlated with AR after TAVI.

METHODS

From June 2008 until June 2014, patients who had undergone TAVI with the self-expandable CoreValve device, were retrospectively studied. All available prosthesis sizes were scanned under a multislice CT and the precise diameter at 0.3 mm intervals along each device was measured. Implantation depth was measured utilizing the final aortography after device delivery. The 'true cover index' was evaluated, as a ratio of: $100 \times ((\text{prosthesis true diameter at implantation depth} - \text{annulus diameter}) / \text{prosthesis true diameter at implantation depth})$. AR was echocardiographically evaluated at discharge and at 30 days after TAVI and classified as impaired if moderate, or trivial if none or mild.

RESULTS

A total of 109 patients (mean age 80.7 ± 5.3 yrs, 58 males) were finally studied. At discharge, the 'true cover index' was statistically significantly lower among patients with impaired AR in comparison with trivial AR (9 ± 5.1 for trivial vs 5.4 ± 5.1 mm for impaired AR, $p=0.026$). Similarly, a significant difference was found for the 'true cover index' between AR classifications at one month post-TAVI (9.0 ± 5.1 for trivial vs 5.4 ± 5 mm for impaired AR, $p=0.023$), indicating increased AR for smaller index. Finally, after adjustment for age and impaired baseline EF, low 'true cover index' remained an independent predictor of one month impaired AR (OR: 0.850, CI: 0.730–0.990; $p=0.037$).

CONCLUSION

'True cover index', expressing the real congruence between the aortic annulus and the device, based on its precise implantation depth, is strongly and independently correlated with the short and mid-term AR after CoreValve implantation. Hence, appropriate annular measurements and prosthesis sizing are critical to minimize paravalvular AR.

ANGIOPLASTY FOR PARAVALVULAR LEAK CLOSURE

Jason Leung Kwai Chan
Queen Elizabeth Hospital, Hong Kong, China

CLINICAL HISTORY

- 65-year-old male
- Hypertension
- History of childhood rheumatic fever
- Symptomatic severe aortic stenosis and moderate to severe mitral regurgitation
- Aortic valve replacement (AVR) with Medtronic ATS AP360 #20 and Mitral valve replacement (MVR) with Medtronic ATS AP360 #28 performed on 4/12/2014

IMAGING

- Post operative trans-esophageal echocardiogram showed significant peri-prosthetic aortic regurgitation at left cusp region without evidence of infective endocarditis
- Repeated trans-esophageal echocardiogram 6 months later showed similar significant peri-prosthetic aortic regurgitation
- Patient suffered from persistent exertional shortness of breath, orthopnoea and decline in exercise tolerance
- No clinical evidence of haemolytic anaemia
- Offered re-do open heart surgery by cardiothoracic surgeon but was refused by patient
- Agreed for percutaneous para-valvular leak (PVL) closure

INDICATION FOR INTERVENTION

- Decreased exercise tolerance due to severe para-AVR leak
- Intervention: percutaneous para-AVR leak closure

1ST PVL CLOSURE 5/10/2015

- Retrograde approach
- Local anaesthesia
- Bilateral femoral arteries accesses
- AVR para-valvular leak was identified at left cusp on aortogram
- One AVP II plug 8 mm was deployed at left cusp uneventfully
- Repeated angiogram showed persistent significant aortic regurgitation but no significant leakage at left cusp
- leak from right cusp or trans-valvular leak
- Fluoroscopy showed no abnormal movement of valve leaflets
- No TEE available
- Trans-thoracic echo seemed another leak at right cusp

ECHO (TEE AND TTE) AFTER 1ST PVL CLOSURE

- No significant regurgitant flow at left cusp region
- However there was another peri-prosthetic regurgitation (vena contracta 3–3.5 mm) noted at right cusp with very eccentric jet directed posteriorly in the left ventricular cavity

2ND PVL CLOSURE 4 DAYS LATER

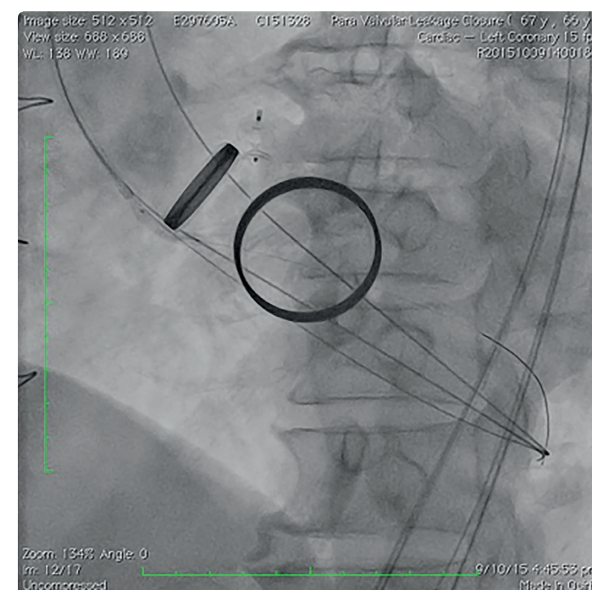- Retrograde approach
- Local anaesthesia
- Bilateral femoral arteries accesses
- 0.035 cm Terumo guidewire passed via the defect with the aid of 5 Fr AL1 guiding catheter
- However catheter failed to pass via defect with AL1 or 4 Fr MPA
- Angioplasty of the defect was decided

ANGIOPLASTY FOR PVL CLOSURE

- 0.014 coronary guidewire BHS and V18 were used as buddy guidewire to pass via the defect first
- Defect was serially sequentially dilated with semi-compliant 3.0×15 and non-compliant 5.0×8 coronary balloons
- 6 Fr MPA1 catheter finally crossed the defect
- 8 mm AVPII device was deployed at right cusp leak successfully
- Subsequent aortogram showed mild residual regurgitation only with significant improvement in leakage
- Trans-thoracic echocardiogram showed mild leakage as well
- Fluoroscopy showed satisfactory movement of mechanical discs

LEARNING POINTS OF THE PROCEDURE

- Paravalvular leak closure can be performed with percutaneous approach
- In difficult case, angioplasty of the defect with coronary interventional technique can be considered to facilitate the procedure
- Sometimes, leak may not come from only one site



DEALING WITH DUCTAL ANEURYSM – INTERVENTIONAL SOLUTIONS

Jae Young Choi / Se Yong Jung / Lucy Youngmin Eun / Nam Kyun Kim
Yonsei University Health System, Seoul, South Korea

HISTORY AND PHYSICAL EXAMINATION

CASE 1

A 72-year-old male patient was transferred to our hospital with the chief complaint of recently developed hoarseness. He had a history of transcatheter closure of patent ductus arteriosus (PDA) using an Amplatzer Duct Occluder (ADO; St. Jude Medical, St. Paul, Minnesota) 8 years prior to the presentation of current symptom. He was lost to follow up after PDA closure and he had been well, except for the recently developed symptom.

CASE 2

A 45-year-old gentleman was referred to our hospital for the treatment for PDA with a large ductal aneurysm which was incidentally found during the workup for atypical chest pain. Low grade continuous murmur was auscultated over the left upper sternal border. Various treatment options have been discussed, including surgery and catheter intervention.

IMAGING

CASE 1

Chest CT scan from the referring hospital revealed a large thrombus-occupied ductal aneurysm (Fig. 1, marked as asterisk) originating from the inferior surface of the aortic ampulla which was not covered by ADO at the time of PDA closure. Transthoracic echocardiography showed mild to moderate regurgitation of mitral and aortic valves, which were thought to be degenerative valve diseases.

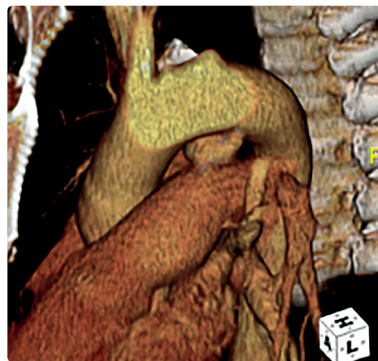
CASE 2

CT scan, which was taken in another hospital, showed a large ductal aneurysm with connections to aorta and pulmonary artery in a twisted angulation (Fig. 2). Transthoracic echocardiography revealed mild enlargement of left atrium and ventricle.

Figure 1

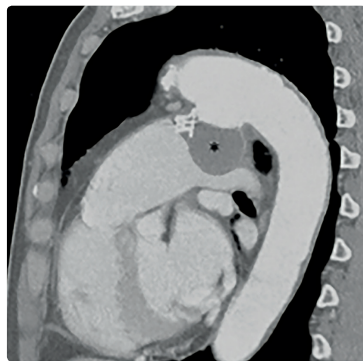

Figure 2



INDICATION FOR INTERVENTION

Ductal aneurysm associated with symptom, progressive enlargement of the aneurysm or risk of aneurysm rupture.

INTERVENTION

CASE 1

The patient refused surgery after an extensive discussion with the multi-disciplinary team and his family. He underwent stent graft (Zenith TX2, 42/38–158 mm, COOK Medical Inc., Bloomington, IN) implantation, distal to the origin of left subclavian artery covering the ductal ampulla and the aneurysm.

CASE 2

We closed the PDA and ductal aneurysm by both antegrade and retrograde approach to ensure the safety of the procedure. We made an arterio-venous loop with an exchange-length guide wire and delivered a 6×6 mm Amplatzer Duct Occluder II (St. Jude Medical, St. Paul, Minnesota) first by the retrograde route from the femoral artery with in situ guide wire loop (over-the-wire technique). Then we delivered an 18 mm Amplatzer vascular plug II (St. Jude Medical, St. Paul, Minnesota) to the ductal aneurysm through the antegrade approach with the same technique, which achieved an immediate occlusion of the arterial duct as well as the ductal aneurysm.

LEARNING POINTS OF THE PROCEDURE

A ductal aneurysm may occur spontaneously or develop as a long-term adverse event after PDA closure, and is difficult to treat surgically. Use of novel devices and techniques may enable a more efficacious and safer treatment for these complex lesions.

THE FORGOTTEN EUSTACHIAN VALVE

Hala Mounir Agha¹ / Ziyad Hijazi² / Ibrahim Abou Farag³

¹ Cairo University Specialized, Cairo, Egypt

² Sidra Cardiovascular Center of Excellence, Doha, Qatar

³ El Azhar University, Cairo, Egypt

HISTORY AND PHYSICAL

A patent eustachian valve (EV) is not only a possible pitfall in echocardiography but also for the cardiac surgeon closing an atrial septum defect.

There are several reports of the EV being mistaken for the lower rim of the ASD, thus causing inadvertent diversion of the IVC blood flow into the left atrium. In February 2016, a 10-year-old boy presented to the Catheterization Laboratory of Cairo University Specialized Pediatric Hospital, Egypt with a mild degree of cyanosis.

The mother mentioned that a previous surgical repair of partial anomalous pulmonary venous drainage and ASD closure was performed since 8 years.

IMAGING

Multislices CT angiogram 6 months ago was done and misinterpreted the findings as an IVC that was draining into the left atrium and overriding the inferior posterior segment of the interatrial septum with a residual defect related to the IVC.

TEE was performed and the bicaval view (110 degree) demonstrated a prominent thickened eustachian valve (EV) aggravated by the presence of sutures lines with blood turbulence at its tip inside RA. An obligatory right to left flow was detected through a small (4 mm) low ASD secundum (Figure 1).

Diagnostic catheterization was done and IVC injection confirmed the TEE findings and angiographic stenosis of EV entrance into RA and small ASD (Figure 2).

INDICATION FOR INTERVENTION

Mild cyanosis, Sao2 on room air was ranging from 86 to 90%.

INTERVENTION

An angioplasty was performed at the site of stenosis by Z-med balloon 12 mm by 3 cm without significant changes of the hemodynamic or the angiographic findings. Then, a 7.5 mm Occlutech Figulla Flex II ASD occluder device was successfully implanted followed by 16mm by 4cm Z-med balloon dilatation. This procedure ended by a significant drop of IVC pressure from 17 mmHg to 7mmHg as well as the disappearance of the angiographic narrowing. On follow up 1 week after the intervention Sao2 on room air was 96%.

LEARNING POINTS

- A large eustachian valve might be a pitfall during surgical closure of an ASD.
- This mistaken large structure aggravated by the presence of suture lines induces obstruction to flow entering from the IVC and directs the blood flow through a residual atrial communication leading to cyanosis.
- Percutaneous closure of the ASD and balloon dilatation of the site of stenosis by a forgotten large eustachian valve are feasible and successful in relieving the cyanosis.

Figure 1

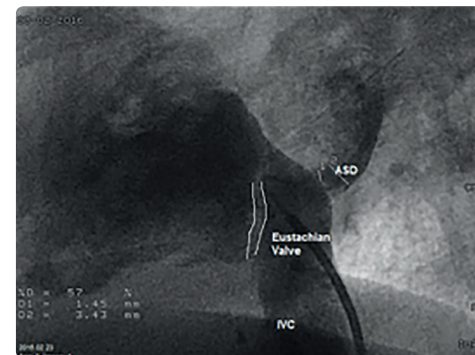
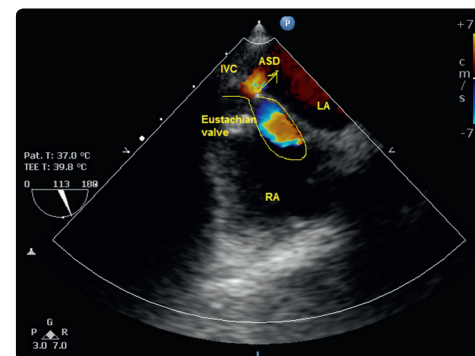


Figure 2



FIRST CASE OF PERCUTANEOUS CLOSURE OF A TRICUSPID PARAVALVULAR LEAK IN SRI LANKA

Charitha Herath¹ / Sepalika Mendis¹ / Zahid Amin² / Nadeeja Seneviratne¹ / Ambiga Kathirgamanathan¹

¹ National Hospital of Sri Lanka, Colombo, Sri Lanka

² Children's Hospital of Georgia, Augusta, USA

Paravalvular leak is a well-known complication of valve replacement – it affects 5 to 17% of post-surgical patients¹. This may happen immediately after the procedure or after several years of surgery. Most cases of paravalvular leaks are small with little clinical significance². However large paravalvular leaks may present with symptoms of heart failure, hemolysis and infective endocarditis³.

Paravalvular leaks are most often found in association with mitral valve prostheses, less often with aortic and rarely after tricuspid valve (TV) prostheses placement⁴. Echocardiographic imaging with trans-thoracic (TTE) and real time 3D trans-esophageal echocardiography (TEE) are key for diagnosis as well as evaluating the defect size, shape and the surrounding tissue³.

Surgical repair has been the standard treatment in most cases⁵, but re-do surgery is associated with high morbidity and mortality and may not be successful because of underlying tissue friability, inflammation and annular calcification. Operations are associated with increased risk of paravalvularleaks. Therefore, in most cases, the less invasive approach of initial percutaneous closure is preferred, with surgical repair reserved for patients in whom percutaneous repair cannot be performed or is contraindicated such as active endocarditis, significant dehiscence.

We describe a case of large tricuspid paravalvular leak that was successfully occluded using a transcatheter approach. We believe this is the first successful tricuspid paravalvular leak closure in Sri Lanka.

HISTORY AND PHYSICAL

A 35-year-old female with Ebstein anomaly underwent total correction with tricuspid valve replacement with Edwards's bio prosthetic (Edwards Lifesciences, USA) valve twelve years earlier. She was admitted with symptoms of right heart failure since 2011. Symptoms were worsening over the years and she required recurrent admission with intense medical therapy.

IMAGING

Trans-thoracic and trans-esophageal echocardiography revealed grossly dilated right cardiac chambers with significant paravalvular leak.

INDICATION FOR INTERVENTION

The patient was symptomatic with limited daily activities; Re-operation was deemed to be very high risk, hence it was decided to do the procedure using trans-catheter techniques.

INTERVENTION

The procedure was performed under general anesthesia with the fluoroscopic and trans-esophageal echocardiographic guidance. A 6F multipurpose diagnostic catheter was passed into the right ventricle through bio prosthetic TV and right ventricle ventriculogram was done, which showed the large paravalvular leak in the antero posterior position.

Sizing of paravalvular leak was made by using 2D and 3D TEE and the right ventriculogram, which revealed the final size of 19.5mm defect. A 0.035 inch straight tipped Terumo wire was advanced into the right ventricle through paravalvular leak and 6F multipurpose catheter was advanced through the defect. Subsequently Terumo wire was exchanged with a 0.035 inch super stiff Amplatzer guide wire.

The size of the para-valvular leak was difficult to ascertain, therefore, we decide to balloon size the leak. An Amplatzer (SJM, Golden Valley, MN, USA) compliant sizing balloon was advanced over the wire and placed across the leak. It was gently inflated til color flow through the paravalvular leak ceased by echocardiography. The size measured about 18mm.

The 9F Amplatzer delivery system was placed into the right ventricle over this stiff wire. 20mm post-infarct muscular VSD device (PIVSD) was placed across the paravalvular leak. The device was released across the defect after confirmation of the position by trans-esophageal echocardiography and fluoroscopy.

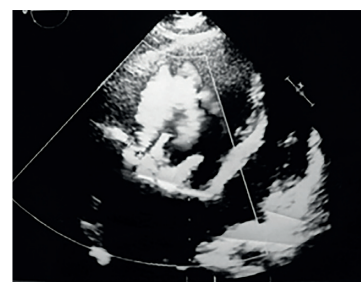
Closure of the defect was checked with TEE and repeat right ventriculogram was also performed. There was impingement of the device edges on the valve leaflets. There were no complications.

LEARNING POINTS OF THE PROCEDURE

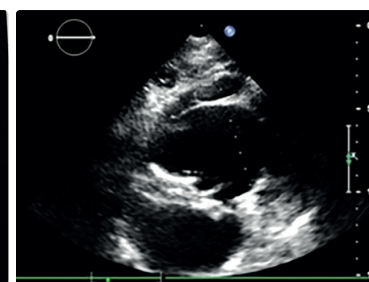
This patient had refractory right heart failure due to significant tricuspid paravalvular leak and had excellent results following closure.

The choice of PI VSD was based upon the very large size of the defect and that face that the tricuspid valve ring was not well formed in this patient. We wanted to ensure that the device will astride the prosthetic valve ring and the tricuspid valve annulus. This was accomplished with PIVSD device as the discs are 10mm larger than the waist. This patient's symptoms were completely settled and her exercise tolerance showed marked improvement in the three month follow up. We believe that in selective cases, transcatheter closure of paravalvular leaks can be accomplished with excellent results. The procedure, however, remains challenging with relatively high failure rate.

TV Paravalvular leak



Post procedure TTE image showing the device



PACEMAKER AND LIMA GRAFT ARE NOT CONTRAINDICATIONS FOR TRANSCUTANEOUS AORTIC VALVE REPLACEMENT THROUGH LEFT AXILLARY ARTERIAL ACCESS

Babu Ezhumalai / Vijay Kumar / Vshal Rastogi / Ashok Seth
Fortis Escorts Heart Institute, New Delhi, India

HISTORY AND PHYSICAL

86-year-old male, hypertensive, dyslipidemic, hypothyroid, non-diabetic, post PTCA with stent to LCX –1989, post PTCA with stent to LAD in 2007, post PPI (DDDR) in 2008, calcific aortic stenosis, post BAV in 2011, patient suffered again from worsening breathlessness due to restenosis of AV.

IMAGING

ECHO

Aortic valve gradient – peak 102 mmHg & mean 66 mmHg, normal LV function

CT ANGIOGRAPHY

Left subclavian artery 7.4 mm, severe tortuous iliac arteries

INDICATION FOR INTERVENTION

Severe calcific aortic stenosis in elderly patient with co-morbidities. In view of bilateral tortuous iliac arteries, subclavian arterial access was selected for TAVR in this patient in spite of him having dual chamber pacemaker leads placed through left subclavian vein.

INTERVENTION

- Left axillary arterial access obtained by surgical cut down
- 6F pigtail catheter placed into non-coronary sinus, through right femoral arterial access 7F sheath
- 5F TPI lead placed in RV apex through right femoral venous access 7F sheath
- Balloon dilatation of native aortic valve done with Z-Med balloon 22×4 mm
- Device negotiated through subclavian sheath and placed across AV
- TAVR performed with 29 mm CoreValve through left subclavian arterial access in a patient with dual chamber pacemaker

LEARNING POINTS OF THE PROCEDURE

- Axillary arterial access is a feasible route for TAVR
- This route is especially important in elderly patients who have tortuous aorta and peripheral artery disease wherein it is difficult to negotiate the bulky devices of TAVR
- Presence of LIMA graft to LAD (as per literature) or Pacemaker leads placed through left subclavian vein are not contraindications for performing TAVR through left axillary arterial access

Figure 1

Left axillary arterial access obtained by surgical cut down for TAVR in a patient with dual chamber pacemaker

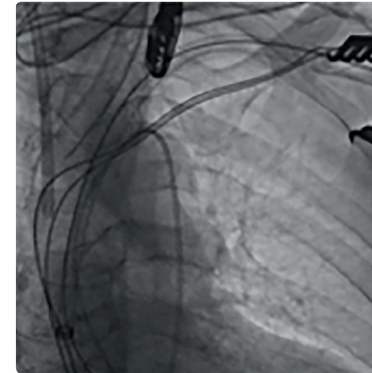
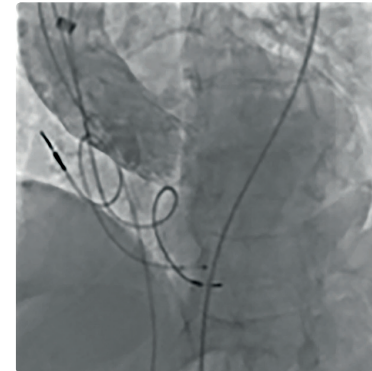


Figure 2

TAVR performed with 29 mm CoreValve through left axillary arterial access in a patient with dual chamber pacemaker



TRANSAPICAL MITRAL VALVE IMPLANT FOR THE TREATMENT OF DEGENERATED BIOPROSTHESIS

Ben Cole / Reuben Jeganathan / Ali Abdelnour / Ganesh Manoharan / Mark Dougherty / Mark Spence
Victoria Hospital, Belfast, UK

Bioprosthetic heart valves are increasingly used in current surgical practice. As outcomes continue to improve there has been a growing need for valve reinterventions in patients at high risk for traditional surgical intervention. Transcatheter valve-in-valve therapies have been evolving as a treatment for these patients with increasing experience reported especially for the aortic position. Mitral valve-in-valve or valve-in-ring transcatheter intervention while less well studied has been shown to be feasible with a recently presented retrospective case series from multiple centres worldwide of 349 patients demonstrating a 30-day mortality of 7.7%.¹

We report the case of an 80-year-old female with rheumatic heart disease. Her history included surgical mitral valve replacement in 2002 for the treatment of mitral stenosis (Size 25 Medtronic Mosaic). She had transcatheter aortic valve implantation (TAVI) in 2012 with a 29 mm Medtronic Corevalve for aortic stenosis after being deemed to be too high risk for conventional surgical valve replacement. She had made good progress after TAVI, with resolution of dyspnoea on exertion and improvements in her 6-minute walk test (6MWT).

In 2015 she attended for routine review at the outpatient clinic where she reported worsening exertional dyspnoea and peripheral oedema along with five-pillow orthopnoea. Cardiac auscultation evidenced a grade 2 mid-diastolic murmur in the mitral area. Pulmonary auscultation revealed crepitations at both lung bases. She was subsequently admitted for further investigation and optimisation of her cardiac status. Transthoracic echocardiogram (TTE) showed degeneration of the mitral bioprosthesis resulting in severe stenosis (Peak gradient 34 mmHg, mean gradient 22 mmHg). Her aortic bioprosthesis functioned well, however there was mild to moderate paravalvular regurgitation. There was severe tricuspid regurgitation with right ventricular systolic pressure (RVSP) estimated at 94 mmHg. Both atria were severely dilated. The left ventricle was not dilated with normal systolic function; however the right ventricle was moderately dilated with mild impairment of systolic function. Subsequent transoesophageal echocardiogram (TOE) confirmed the findings of TTE, with severe stenosis of the mitral bioprosthesis with mild paravalvular regurgitation.

She responded to treatment with intravenous diuretics and proceeded to right and left cardiac catheterisation, which revealed elevated right heart pressures (mean RA pressure 11 mmHg, RV 61/2 mmHg, RVEDP 7 mmHg, PA pressure 68/25 mmHg, mean 42 mmHg). Mean pulmonary capillary wedge pressure was also elevated at 29 mmHg, with a transpulmonary gradient of 11 mmHg. Pulmonary vascular resistance was 2.75 Wood units. Mean transmitral gradient was 21 mmHg.

Cardiac output was 4.0 L/min, with cardiac index 2.19 L/min/m². There was no obstructive coronary disease. Gated cardiac computed tomography (CT) was performed.

The heart team considered her case and were of the opinion that surgical mitral valve replacement carried excessive risk. She was considered suitable for transapical transcatheter mitral valve-in-valve implantation for the failed bioprosthesis.

When deciding on the valve to choose prior to the procedure, the manufacturer specifications for the Medtronic Mosaic 25 mm valve were consulted. The manufacturer states that the internal diameter of a Mosaic 25 mm valve is 22.5 mm. The overall height of the Mosaic valve is 18 mm with a stated aortic protrusion of 13.5 mm. Analysis of cardiac gated CT gave an even smaller internal diameter in the degenerated bioprosthesis of 18.2 mm. We selected a 23 mm Sapien 3, which is the smallest Sapien 3 valve available in our region and is designed to treat native aortic stenosis with annulus dimension 18–22 mm. This device has a height of 18 mm when deployed which matched the mosaic valve height identically.

The case was performed in a hybrid operating room, under general anaesthesia with transoesophageal echocardiographic support. By use of a left lateral minithoracotomy over the fifth intercostal space, the cardiac apex was exposed. Purse string suture was performed with prolene reinforced with pledgets. The apex was punctured and a guidewire was advanced with the aid of a JR catheter across the mitral valve to the right superior pulmonary vein under fluoroscopy. An 18-F Edwards Certitude delivery system was introduced through the apex over the guidewire.

Following preoperative calculations regarding the internal diameter of the mitral bioprosthesis as discussed earlier a 23 mm Edwards Sapien 3 balloon expandable bioprosthesis was introduced through the 18-F sheath and advanced within the degenerated prosthesis by simultaneous use of fluoroscopy and transoesophageal echocardiography. The Edwards Certitude delivery system allowed the valve to be positioned within the degenerated mitral bioprosthesis before unsheathing, reducing disruption to the degenerated valve. With the aid of rapid pacing, the balloon was expanded and the valve deployed. There was instant improvement in catheter-derived gradients across the valve. Transoesophageal echocardiogram performed immediately after implantation revealed a normally functioning bioprosthesis with neither paravalvular nor valvular leak; peak and mean diastolic gradients of 16 and 5 mmHg, respectively; and an effective valvular area of 2.3 cm². The delivery sheath, catheters and guidewire, were removed, and the apex closed. The patient was transferred to the intensive care unit and

PARAVALVULAR LEAK DEVICE CLOSURE – CATCH ME IF YOU CAN

Babu Ezhumalai¹ / Balachander Jayaraman²

¹ Fortis Escorts Heart Institute, New Delhi, India

² Jawaharlal Institute of Postgraduate Medical Education and Research, Puducherry, India

HISTORY AND PHYSICAL

52 years male, RHD, post mitral valve replacement (mechanical valve) 3 years back, Patient presented with c/o worsening breathlessness and palpitation

IMAGING

TRANSTHORACIC ECHOCARDIOGRAPHY

Prosthetic mitral valve functioning well. Mean pressure gradient – 5 mmHg, mitral (moderate) paravalvular leak seen, normal LV function, PA pressure 38/12 mmHg

TRANSESOPHAGEAL ECHOCARDIOGRAPHY

Prosthetic valve functioning well in mitral position, severe paravalvular leak present 7mm defect

INDICATION FOR INTERVENTION

Severe paravalvular leak

INTERVENTION

- Right femoral vein and arterial access obtained with – 5F sheath each
- Transeptal puncture performed with Brockenbrough needle
- Using 5F JR and 0.035" Terumo glidewire, mitral paravalvular leak crossed from left atrial side
- This was exchanged over Amplatz 0.035" superstiff wire and then 7F long sheath parked in left atrium
- Amplatz muscular VSD occluder 10mm device was deployed at the paravalvular leak site
- Immediately post deployment the device embolised into left atrium and started swirling in the left atrium
- Various attempts were made to capture and retrieve the device including using snare but in vain
- So patient was sent for surgery, device was retrieved successfully and paravalvular leak closed

LEARNING POINTS OF THE PROCEDURE

- Be prepared for retrieving the device with snare
- Surgical backup must always be available while performing paravalvular leak device closure

IMAGES

Figure 1

Amplatz 0.035" superstiff wire passed through 5F JR diagnostic catheter which has crossed the mitral paravalvular leak

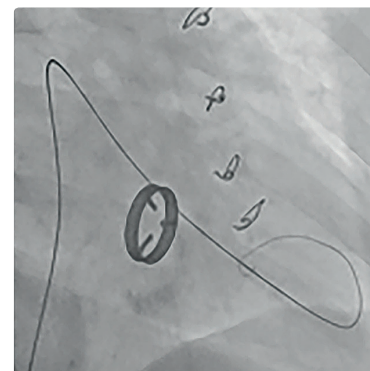
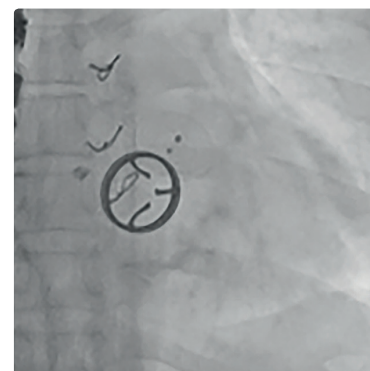


Figure 2

Embolised device swirling in the left atrium



DOES PATIENT FRAILITY INFLUENCE THE USE OF REGIONAL OR GENERAL ANESTHESIA FOR TRANS-FEMORAL TRANS-CATHETER AORTIC VALVE REPLACEMENT?

Akhlaque Uddin / Ashan Gunarathne / Amerjeet Banning / Derek Chin / David Adlam / Elved Roberts / Jan Kovac
Glenfield Hospital, Leicester, UK

BACKGROUND

Transcatheter aortic valve replacement (TAVR) has dramatically impacted on the management of symptomatic severe aortic stenosis in those high surgical risk patients. Regional anaesthesia for TAVR has been used to further reduce the risks associated with general anaesthesia.

OBJECTIVE

The aim of the study was to compare characteristics of patients undergoing regional anaesthesia and general anaesthesia and the role of frailty.

METHODS

107 high risk patients with severe aortic stenosis referred for TAVR to the heart MDT were studied. Transfemoral approach with either general anaesthesia (GA) or local anaesthesia (LA) (prilocaine) with optional sedation were included. All LA patients received IV paracetamol 1g, and additional IV morphine ± diazepam, if required. Frailty was assessed using the CSHA (Canadian Study of Health and Ageing) Clinical frailty scale (1 = very fit to 9 = terminally ill).

RESULTS

Both groups were matched for age, sex, parameters of aortic stenosis, LV function, BMI and vascular risk factors. The LA group had a significantly lower frailty score than GA group (2 (2–3) vs. 3 (2–3) $p=0.019$). The duration of procedure was not statistically different. LA group had one major vascular complication by VARC criteria. There was a higher percentage of procedure pacemaker implantation in the LA group ($n=18$) vs. GA group ($n=9$) ($p=0.02$). Median length of stay was, LA = 3.6 (2.6–8.0) days, vs. GA = 5.8 (3.0–8.6) days ($p=0.19$). The 30 day mortality was zero.

CONCLUSION

Local anaesthesia is suitable for TAVR for patients with low frailty grade with minimal adverse complication. Higher pacemaker implantation may be related to predominant use of the balloon expandable device.

PERCUTANEOUS PULMONARY VALVE IMPLANTATION WITH EDWARDS SAPIEN XT IN PATIENTS WITH NATIVE AND LARGE RIGHT VENTRICULAR OUTFLOW TRACT; EARLY RESULTS

Ahmet Celebi / Ilker Kemal Yucel / Orhan Bulut / Sevket Balli / Mehmet Kucuek
Dr Siyami Ersek Hospital, Istanbul, Turkey

BACKGROUND

Percutaneous pulmonary valve implantation (PPVI) has been used mainly for conduit dysfunction in right ventricular outflow tract (RVOT). Until recently, native RVOT without stenosis used to be considered a relative contraindication to transcatheter valvulation.

OBJECTIVE

We present early results of PPVI with Edwards-Sapien XT (ES-XT) in repaired tetralogy of Fallot (TOF) patients with native-large RVOTs.

METHODS

36 s/p repaired TOF patients who had native RVOT with free pulmonary regurgitation and right ventricular dilatation without significant stenosis. Balloon sizing was performed with compliant (34mm Amplatzer sizing) and semi-compliant balloons for interrogation. The size of the Z-Med balloons and BIB catheters that the Andra Stents XXL would be mounted on was decided according to the indentation diameter that occurred during interrogation; as at least 1mm larger than the indentation diameter.

RESULTS

Mean age and weight of the patients were 17.9 ± 9 (7–50) years and 48 ± 15 (22–84) kg, respectively. Before pretesting, pressure gradient between right ventricle and pulmonary artery was 5.7 ± 4.2 (0–14) mmHg. Indentation diameter with balloon interrogation was 26 ± 2.1 (22–32) mm. Pretesting was successful in all. Balloon size used for pretesting was 27.9 ± 2.2 (24–30) mm. Successful valve implantation was achieved in all patients; 29mm in 29 and 26 mm in seven. Valvulation was performed in same session in five, and 3–12 weeks after pretesting in 31. Valve function was good in all immediate after and at the last follow up; a median of 5 months (1–18 months). Mild paravalvular leakage was observed only in two. Stent fracture has not been observed and no reintervention required yet.

CONCLUSION

PPVI with ES-XT valve, which has larger sizes at 26 and 29mm, is feasible and safe in patients larger native RVOT without stenosis in adolescents and adults. Newer delivery system (Novaflex), which is used through 14–20 Fr smaller sheaths, also gives us an opportunity of early transcatheter valvulation in smaller patients with native RVOT. Pretesting for providing a secure landing zone is the most important part of the procedure. Only Andra XXL stents, which have an expansion capacity of up to 32mm, can be used for this purpose, currently.

REDO TRANSAPICAL OFF-PUMP NEOCHORD IMPLANTATION TO TREAT SEVERE DEGENERATIVE MITRAL REGURGITATION

Agne Drasutiene / Kestutis Rucinskas / Ieva Kazukauskienė / Vilius Janusauskas / Diana Zakarkaite / Arturas Lipnevicius / Audrius Aidietis
Vilnius University, Vilnius, Lithuania

HISTORY AND PHYSICAL

A 54-year-old man was referred to cardiologist due to systolic murmur in the mitral valve area. The patient had no dyspnea or any other heart failure symptoms. There were no other comorbidities.

IMAGING

Transthoracic echocardiography (TTE) was performed and revealed the presence of severe mitral regurgitation (MR) due to posterior MV leaflet P2 segment prolapse and chordal rupture. Transesophageal 3D echocardiography (TEE) confirmed degenerative lesion of posterior leaflet medial segment (P2) with chordal rupture and eccentric significant MR jet.

INDICATION FOR INTERVENTION

The patient refused any surgical conventional procedure and was scheduled for transapical off-pump beating heart MV repair with Neochord DS1000 device.

INTERVENTION

A standard left lateral mini-thoracotomy was performed in the fifth intercostal space to access the left ventricular (LV) apex. The device was introduced through a standard purse-string apical ventriculotomy. The procedure was performed under 2-/3-dimensional TEE guidance. 5 neochords were implanted in different points of flailing P2 segment and then retracted outside the heart. Under echocardiographic guidance, every neochord was properly tensioned, achieving a correct MV function. Echocardiography confirmed good result of MV repair with no residual MR. The patient made uncomplicated further recovery and was discharged 7 days after surgery.

Unfortunately, after 4 months of follow up, the patient presented with recurrence of severe MR due to chordal rupture of anterior leaflet medial segment (A2) (Figure 1). There was no prolapse of P2 segment of posterior leaflet, all 5 neochords were visualized in this segment properly tensioned.

Again, patient refused conventional mitral repair and was scheduled for redo transapical off-pump Neochord implantation. Prior the procedure, accurate evaluation of neochords and native chords was performed. LV chamber was evaluated in transgastric TEE short and long axis views, which demonstrated no crossing of neochords with native chords.

This time through transapical access prolapsing segment of the anterior leaflet was grasped using the NeoChord device and 2 neochords were implanted in different points of A2 segment and then retracted outside the heart. No residual MR and perfect anatomical result of MV repair was achieved. Transgastric 3D TEE confirmed correct position of both previously and recently implanted neochords on both mitral valve leaflets (Figure 2).

The perioperative and recovery period were uneventful and the patient was discharged 4 days after surgery.

LEARNING POINTS OF THE PROCEDURE

This case demonstrates the technical feasibility of the implantation of neochordae on both mitral leaflets using the Neochord DS1000 device and possibility of redo procedure.

Figure 1
(A, B) – severe MR due to chordal rupture of anterior leaflet medial segment; (C, D) – final result after transapical neochord implantation.

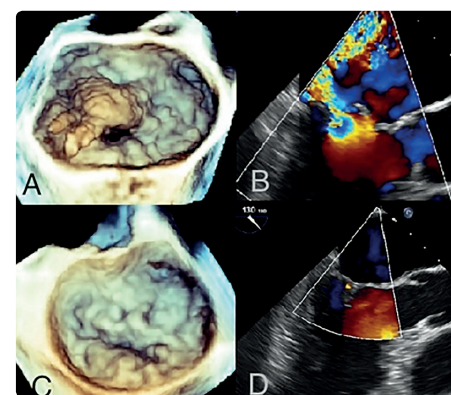
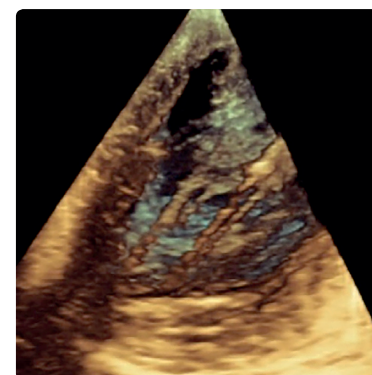


Figure 2
Transgastric view of neochordae on posterior and anterior leaflet.



THE ALLIANCE OF STRUCTURAL AND CORONARY EQUIPMENT AND TECHNIQUES TO FACILITATE CLOSURE OF PARAVALVULAR LEAKS

Andrew Mcneice / Mark Spence / Colum Owens
Royal Victoria Hospital, Belfast, UK

HISTORY AND PHYSICAL

- 61-year-old male
- Acute decline in exercise tolerance
- Cardiac Surgery 3 months prior to presentation
 - Bioprosthetic AVR-23mm Perimount magna ease
 - Double vessel CABG-LIMA-LAD/SVG-LCx
- Complicated post-operative period, slow wean off ventilator due to chest sepsis
- Elevated NT Pro-BNP
- No evidence of infection: Apyrexia, normal inflammatory markers
- No clinical or biochemical evidence of haemolysis
- Trans-thoracic echocardiography showed a broad aortic paravalvular regurgitant jet with preserved LV systolic function
- Past medical History
 - Splenectomy following motor vehicle accident
 - Paroxysmal atrial fibrillation

IMAGING

Trans-oesophageal echocardiography showed the cavity to be crescentic in shape and located posteriorly (non-coronary cusp), the most common site for an aortic PVL.

Cardiac gated computed tomography with 3D reconstruction defined the size and shape of the cavity further. Like most paravalvular cavities it was serpiginous with multiple lobulations. It measured 31.8 × 11.6 mm.

Indication for intervention:

- Symptomatic patient with severe aortic paravalvular regurgitation
- Elevated NT Pro BNP
- No evidence of infection
- Comprehensive preparatory imaging to define the problem
 - 2D/3D Trans-Oesophageal Echocardiography
 - Cardiac Gated Computed Tomography
- Heart team discussion
 - Discussed with cardiac surgeon who performed index procedure
 - Unfavourable characteristics for redo surgery
 - Decision made to proceed with transcatheter device closure
 - Planned dual wire access into LV through single femoral artery puncture
 - Allows potential for two Amplatzer Vascular Plug (AVP) occlusion devices to be deployed

INTERVENTION

Approach

- General anaesthetic
- Femoral artery -7F sheath
- TOE and fluoroscopy guidance
- A combination of structural and coronary artery equipment used
- AL1 7F guide
- Straight hydrophilic wire 0.035" 260 cm (Terumo)
- Guideliner V3 (Vascular Solutions) 7F
- X 2 0.035" 260 cm Emerald wires (Cordis)- dual access in LV through single puncture to facilitate 2 occlusion devices

STEP 1

Crossing cavity safely with 2 wires via single skin puncture

- Solution- 7F guide with guideliner as guide catheter extension

STEP 2

Positioning of first device -AVP II 10 mm

- Device deployed with safety (2nd) wire in left ventricle
- Intra-procedural TOE-Residual leak; confirmed strategy of second device requirement

STEP 3

Aim was to deliver second AVP II device- Lost position during attempted placement

- No safety wire in LV

Options

- Abandon procedure as will be challenging to re- cross small cavity
- Risk of disruption to first device
- Utilise percutaneous coronary equipment to cross cavity
- Telescoping technique using balanced heavyweight coronary guidewire (Abbott Vascular); corsair microcatheter (Asahi Intecc); 4F JR4 catheter

STEP 4

Re-crossing cavity with coronary equipment to regain LV access

- Telescoping technique using balanced heavyweight coronary guidewire (Abbott Vascular); corsair microcatheter (Asahi Intecc); 4F JR4 catheter

A 0.014 balanced heavyweight coronary wire (BHW) along with a microcatheter was used to cross the cavity to avoid disruption of the first AVP.

The microcatheter passed easily over the BHW, confirming that the 0.014 wire

hadn't passed through the first device apparatus and adding additional support to allow delivery of the 4F coronary diagnostic catheter into the LV over the wire and microcatheter in a telescoping fashion.

The BHW and microcatheter were exchanged for a 0.035" 260cm Emerald wires (Cordis) and a 5F destination long sheath was used to deliver the second closure device, in this case an 8mm Amplatzer Vascular Plug II.

Final fluoroscopy and TOE views showed no regurgitation with two closure devices positioned across the paravalvular cavity.

The patient was discharged home the following day.

LEARNING POINTS

- Challenge identifying the appropriate patient for percutaneous closure
 - Symptomatic
 - Absence of infection
 - Objective evidence significant AR
 - Some unfavourable features for re-do surgery
 - Suitable anatomy/device choice- dependent on imaging
- Ability to use coronary equipment for crossing small cavities
 - 0.014" heavyweight coronary guidewire- safe method of crossing small cavities
 - Microcatheters- low profile, add support, act as a rail for catheters to cross small cavities, easily trackable, use in telescoping fashion with guidewire and catheter
 - Guideliner- Atraumatic tip, hydrophilic coating, flexible, 7F allows dual access into LV through single skin puncture

The purpose of this case was to highlight the potential use of coronary equipment in percutaneous structural intervention.

Firstly, the use of a guideliner to cross paravalvular cavities has proven itself to be safe and effective. This is because of its properties such as its soft atraumatic tip, hydrophilic coating and stainless steel braiding for flexibility and support. 7 French facilitated delivery of x2 0.035" wires allowing dual access through single skin puncture.

Secondly, use of coronary guidewires, in this case a 0.014 heavyweight coronary guidewire with a low tip load are ideal to cross residual small cavities due to their low profile and atraumatic tip. Using a microcatheter facilitates safe crossing of the cavity by adding support and confirming position outside of the device.

Thirdly, the microcatheter also provided additional support acting as a rail to deliver the catheter into the LV in a telescoping fashion.

From this point, access to the LV is re-established and the procedure can be completed with wire and guide exchange.

This was the first case of PVL closure we are aware of that overlapped structural and coronary catheter based techniques and equipment to successfully complete the procedure.

A successful outcome requires meticulous planning with heart team discussion, detailed imaging to define the anatomy and skill in complex structural/coronary interventional catheter- based techniques.

Image 1

Pre-procedural imaging (Gated CT and TOE), Steps and equipment used to close PVL

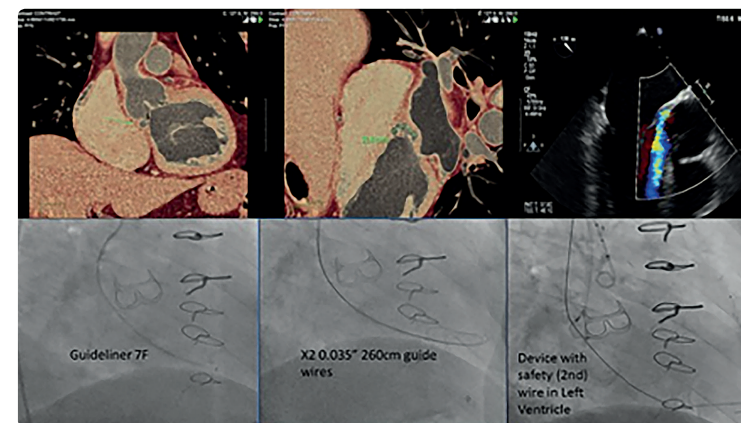
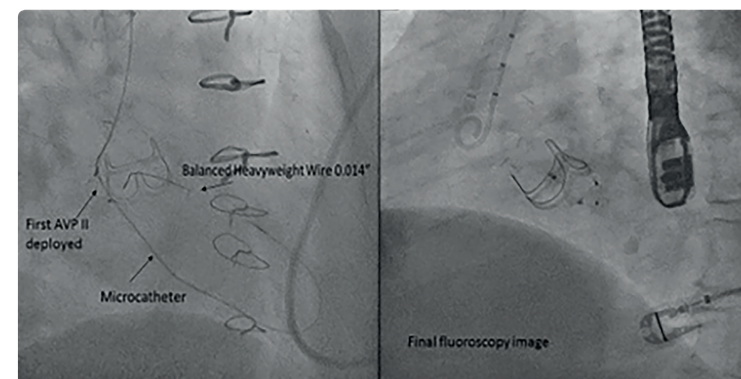


Image 2

Coronary equipment involved to re-establish LV access, Final image



A NOVEL CLIPPING STRATEGY IN DEGENERATIVE MITRAL REGURGITATION – TARGETING AN INDENTATION BETWEEN SEGMENTS P1 AND P2

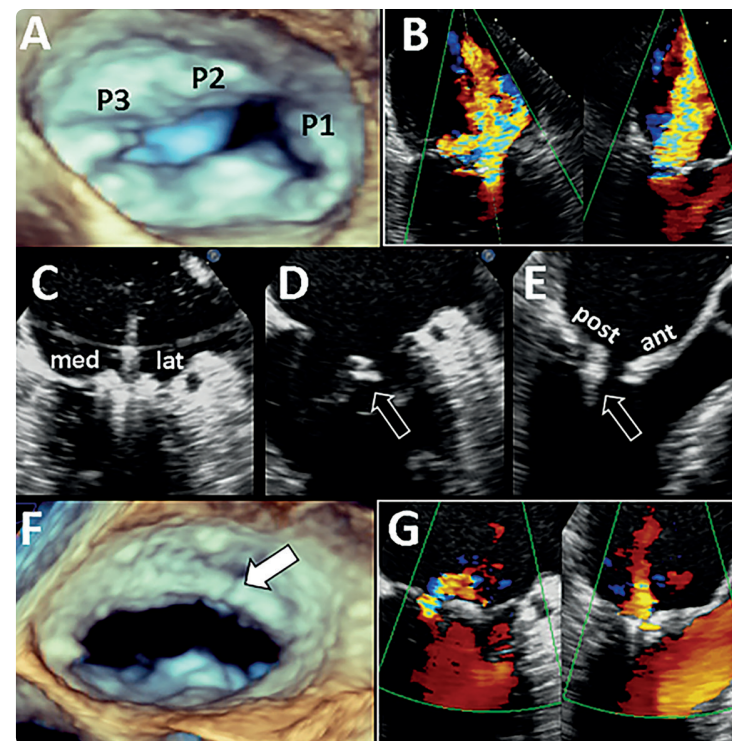
C. Schach / C. Birner / S. Buchner
University Hospital Regensburg, Regensburg, Germany

An 80-year-old male patient was scheduled for percutaneous valve repair due to recurrent heart failure NYHA III-IV and comorbidities (Euroscore II 24.4%) in October 2015. Besides his coronary heart disease, for which he received coronary artery bypass surgery in 1991 and PCI with drug eluting stenting in 2000, 2007 and 2015 (CABG-Rm, LAD and LM/CX, respectively) he received a DDD-pacemaker because of sick-sinus-syndrome in 2013. Because of paroxysmal atrial fibrillation he takes a vitamin-K antagonist. Extracardiac morbidity include a partially thrombosed infrarenal aortic aneurysm, peripheral arterial disease (PCI A. iliaca ext. 2013), COPD and renal insufficiency (GFR of 33 mL/min). His diabetes mellitus type 2 is controlled by diet and arterial hypertension by a quadruple combination.

Transesophageal echocardiography revealed a severe mitral regurgitation (MR) with a broad jet taking its origin in a significant indentation between segments P1 and P2 (Panels A, B) and thereby reducing the coaptation of the adjacent segments to produce a 3D vena contracta area of 0.86 cm². A moderate to severe tricuspid regurgitation is known, the systolic pulmonary artery pressure above central venous pressure was measured at 84 mmHg by transthoracic echocardiography, normal systolic left ventricular function. Chest X-ray showed moderate pulmonary venous congestion and excluded pleural effusion as well as infiltrates. With optimized heart rate, normal ejection fraction and sufficient myocardial perfusion we accused the severe mitral regurgitation for recurrent episodes of worsening heart failure with congestion. Heart team consensus favoured the percutaneous strategy based on high perioperative risk.

Our primary strategy was to clip the P1/A1 segments. Various grasps failed to reduce the MR significantly, so we went ahead with grasping the P2/A2 segments which showed dissatisfying results, too. We therefore focused on the specific pathology and decided to mediate the underlying problem by clipping the P1 and P2 segments (Panels C–E, arrows mark clip). This resulted in a distinct reduction of the MR with a nice integration of the clip into the posterior leaflet, and interestingly a physiological appearing valve anatomy (Panels F, G, arrow marks clip). Invasive measurements of v-wave and mean left atrial pressure revealed a considerable reduction of 16 mmHg (to 32) and 6 mmHg (to 21), respectively, and 3D vena contracta was reduced to 0.21 cm². The procedure was completed uneventfully. After six weeks, the patient was able to raise his 6-minute-walk distance by 32% up to 354 m, NYHA class was reduced to II.

This case highlights a novel clipping strategy based on this specific anatomy. Therefore we recommend consideration of alternative clipping targets in selected patients after a careful examination of the MR-pathology.



INNOVATIVE SOLUTION TO TREAT TRICUSPID DISEASE

Azeem Latib¹ / Alberto Pozzoli¹ / Jean-Michel Juliard² / Eric Brochet² / Phalla Ou² / Paolo Denti¹ / Eustachio Agricola³ / Pietro Spagnolo³ / Maurizio Taramasso⁴ / Ottavio Alfieri¹ / Antonio Colombo¹ / Alec Vahanian² / Francesco Maisano⁴

¹ San Raffaele University Hospital, Milan, Italy

² Hopital Bichat, Paris, France

³ San Raffaele Scientific Institute, Milan, Italy

⁴ University Hospital of Zuerich, Zuerich, Switzerland

BACKGROUND

Tricuspid regurgitation is usually functional and a challenging issue is the development of significant tricuspid regurgitation late after left-sided valve surgery.

OBJECTIVE

To evaluate the transcatheter procedure on the tricuspid valve with the TriCinch System as an option for patients deemed high-risk surgical candidates.

METHODS

A stainless steel corkscrew is implanted transfemorally into the anterior TV annulus; system tensioned by pulling under beating heart conditions; remodeling is maintained by deploying self-expanding nitinol stent connected to the corkscrew in inferior vena cava. The percutaneous treatment of tricuspid valve regurgitation with TriCinch System; NCT02098200 is a single-arm, non-randomized, prospective trial enrolling 24 patients in 6 sites in Europe, to assess safety and efficacy of the TriCinch System.

RESULTS

The learning curve was completed with the first patients, with echocardiographic and computed tomography scan protocols acquired and corrective actions adopted. Six patients with severe functional tricuspid regurgitation successfully implanted to date (mean age 69.8 years, logistic EuroScore 12.3%). Primary safety and performance endpoints at 30 days were achieved for 5 of 6 patients. One patient's corkscrew dehiscid at day 2 post-procedure. The annulus was remodelled for all patients (mean septolateral annular reduction: 18.7% and tricuspid regurgitation reduction ≥ 1 in 4 of 6 patients) and their clinical condition improved. For the 3 patients at their 6-month follow up, the TriCinch System was stable in position with improvement in quality of life in all patients.

CONCLUSION

The TriCinch System™ is the first dedicated TV repair device for humans. Initial experience demonstrates the feasibility and safety of implantation.

CLINICAL PRESENTATION, MANAGEMENT AND OUTCOMES OF PATIENTS WHO DEVELOPED POST TRANSCATHETER AORTIC VALVE REPLACEMENT THROMBOSIS: GLOBAL CASE SERIES

Mohammad M. Ansari / Daniel Garcia

Michigan State University, East Lansing, USA

BACKGROUND

Current prevalence of thrombus formation after transcatheter aortic valve replacement (TAVR) is small (1–3%). This complication can lead to poor clinical outcomes including re-do procedure and cardiac death. Currently there are no established diagnostic or treatment guidelines. We aimed to report the clinical presentation, diagnosis, treatment and outcomes of all cases described in literature for post-TAVR thrombosis.

METHODS

We systematically search Pub Med, Embase and Cochrane database through December 2015 for all cases described for post-TAVR thrombosis. We report patient's age, sex, type and size of valve used, type of anti-platelet regimen post TAVR, time since TAVR implantation, clinical presentation upon diagnosis, mean peak gradient, treatment used and clinical outcomes.

RESULTS

A total of 13 studies reported a total of 25 cases of post-TAVR thrombosis. Mean age was 79 ± 7 years, 52% were men, mean time since TAVR was 7.2 ± 6.6 months. Most pts were discharged on dual anti-platelet therapy (52%). Majority of them presented with NYHA class III (52%) upon diagnosis. Diagnostic echocardiogram disclosed mean peak gradient of 43 ± 16.6 mmHg. The majority of them were treated with oral-anti-coagulant (56%). There were 6 deaths reported (24%) (Table 1).

CONCLUSION

Post-TAVR thrombosis is an uncommon complication that can be initially underdiagnosed. Majority of these patients present symptomatic with increased mean peak gradient. There seems to be a high mortality rate. Further studies for diagnosis and treatment should be pursued.

PROCEDURAL OUTCOMES OF PERCUTANEOUS TRANSCATHETER PARAVALVULAR LEAK CLOSURE

Mohammad M. Ansari / Daniel Garcia
Michigan State University, East Lansing, USA

BACKGROUND

Paravalvular leakage occurs in up to 18% of all patients who underwent valve replacement. Surgery might be the best treatment option although recently percutaneous valvular leakage (PVL) treatment has surged as a feasible option. There is a lack of comparative data between two modalities and there are only few studies of outcomes of percutaneous PVL closure. We sought to evaluate the procedural outcomes for percutaneous PVL closure.

METHODS

We systematically searched Pub Med, Embase and Cochrane database until December 2015 for all cases-studies for percutaneous PVL closure. We reported type and location of prosthesis, total number of leakages, procedural success, technical success, total number and type of devices used, and access approach. In terms of clinical outcomes we reported cardiac death, stroke, AMI, bleeding, vascular complications and NYHA class post procedure.

RESULTS

A total of 15 authors reported a total of 416 patients and 463 procedures. Procedural and technical success rates were 83% and 86% respectively. Mitral valve prosthesis represented the majority (71.6%) as well as mechanical prosthesis (54%). Total devices implanted were 424 and most of them were AVP III followed by ADO. 10% of these patients had to have a second device placed. Antegrade approach was the most commonly used (38%). Clinical outcomes disclosed NYHA class I/II in 72% patients, death (5%), no AMI, stroke (2%), bleeding (3.8%) and vascular complications (1.2%).

CONCLUSION

In patients with excessively high surgical risk, percutaneous closure of PVLs may be considered an alternative treatment. It carries good procedural and clinical outcomes. Further randomized trials should be pursued.

MULTIVESSEL VERSUS CULPRIT-ONLY REVASCULARIZATION FOR PATIENTS WITH ST-SEGMENT ELEVATION MYOCARDIAL INFARCTION AND MULTIVESSEL DISEASE UNDERGOING PRIMARY PERCUTANEOUS CORONARY INTERVENTION

Wen Zheng
Beijing Anzhen Hospital, Capital Medical University, Beijing, China

BACKGROUND

In acute ST-segment elevation myocardial infarction (STEMI), the use of primary percutaneous coronary intervention (PCI) to treat the artery responsible for the infarct related artery (IRA) improves prognosis, while the value and timing of PCI in Non-IRA with major stenosis is unknown.

OBJECTIVE

The purpose of this study was to examine the differences in long-term outcomes for STEMI patients with multivessel disease as a function of whether and when they should undergo only-IRA PCI or complete PCI including Non-IRA.

METHODS

1,033 STEMI patients with multivessel disease undergoing primary PCIs in Beijing Anzhen Hospital between January 1, 2005 and January 1, 2015, were divided into those who underwent only-IRA PCI (57 patients) and those who underwent complete PCI during the index procedure (immediate PCI, 427 patients) or staged within 90 days of the index-procedure (staged PCI, 555 patients). The primary outcome was a composite of cardiac death, myocardial re-infarction, ischemic stroke or repeat revascularization.

RESULTS

During a mean follow up of 47 months (at least 1 year), the primary outcome occurred in 146 patients assigned to only-IRA PCI and in 102 patients assigned to complete PCI respectively (hazard ratio in complete PCI group, 0.633; 95% confidence interval [CI], 0.445 to 0.900; $P=0.011$). While, of the patients with complete PCI, patients undergoing staged PCI had no significant difference in primary outcomes compared with those undergoing immediate PCI (HR, 3.910; 95%CI, 0.852–17.949; $P=0.079$), staged time interval was associated with risk-adjusted outcomes (HR 0.886; 95%CI, 0.797–0.984; $P=0.024$) and treatment for Non-IRA assigned over 10 days after index-procedure could significantly reduce the endpoint events (HR, 0.213; 95%CI, 0.063–0.717; $P=0.013$).

CONCLUSION

In patients with STEMI and multivessel coronary artery disease undergoing primary PCI, complete PCI in Non-IRA with major stenosis significantly reduced the risk of adverse cardiovascular events, as compared with PCI limited to the infarct artery. The optimal time for treating Non-IRA could be assigned over 10 days after the index-procedure.

CHARACTERISTICS AND CORRELATIONS OF ANATOMICAL AND FUNCTIONAL PARAMETERS OF LEFT ATRIAL APPENDAGE IN PATIENTS WITH OR WITHOUT ATRIAL FIBRILLATION: A THREE-DIMENSIONAL TRANSESOPHAGEAL ECHOCARDIOGRAPHY STUDY

Yuki Matsumoto / Yoshihiro Morino
Iwate Medical University, Morioka, Japan

BACKGROUND

Recently, left atrial appendage (LAA) closure devices have been widely applied for the prevention of cardiogenic stroke in patient with atrial fibrillation (Af). However, detailed and structured assessment of LAA remains limited.

OBJECTIVE

To investigate functional and anatomical parameters of LAA among patients with chronic Af (CAf), paroxysmal Af (PAf) and normal sinus rhythm (NSR).

METHODS

The study population consisted of 194 consecutive patients (>50 years old), hospitalized due to ischemic embolic stroke who underwent transesophageal echocardiography (TEE) (CAf: n=53, PAf: n=26, NSR: n=115). Anatomical and functional parameters of LAA assessed by 3-dimensional TEE were compared between these three groups. Simple linear regression analyses were performed between the LAA parameters.

RESULTS

Comparison of anatomical and functional LAA parameters between the three groups was summarized in the table. A positive correlation was observed between LAAEF and flow velocity ($r=0.36$, $p<0.001$). Depth, orifice area, and diastolic volume of LAA inversely correlated with LAA flow velocity ($r=-0.26$, $p=0.002$, $r=-0.29$, $p=0.016$, and $r=-0.23$, $p<0.001$, respectively).

CONCLUSIONS

Significant as well as explainable differences were observed in anatomical and functional parameters of LAA among patients with CAf/PAf/NSR. Negative correlations were confirmed between size/volume and flow velocity of LAA, which reasonably account for mechanisms of thrombus formation in this blind sac space.

ENDOVASCULAR REPAIR OF PETROUS PART OF INTERNAL CAROTID ARTERY IN TWO CASES

Vida Razazikholes / Mohammad Ali Ostovan
Shiraz University, Shiraz, Iran

HISTORY AND PHYSICAL EXAMINATION

CASE1

A 52-year-old lady presented with sudden onset severe neck pain and headache 2 months ago with 2 episodes of right sided transient hemiparesis during the past 10 days. MRA showed severe distal LICA stenosis and low flow.

CASE 2

A 49-year-old man presented with jaw pain and headache 1 month ago and right sided hemiparesis and aphasia which partially recovered. CT angiography showed severe stenosis in distal LICA with dissection flap.

IMAGING

CASE 1

MRA showed severe distal LICA stenosis and low flow.

CASE 2

CT angiography showed severe stenosis in distal LICA. Carotid angiography revealed dissection flap with severe stenosis in both cases.

INDICATION FOR INTERVENTION

For both cases dual antiplatelet therapy was started but in case 1 the patient developed right sided transient ischemic attack for second time despite medical therapy. In case 2 the patient had right sided aphasia despite dual antiplatelet therapy after presentation of jaw pain and headache, so it was decided to treat both of them by stenting.

INTERVENTION

There was dissection causing significant stenosis in both cases in distal petrous part of internal carotid artery. This segment is tortuous and there was no room to accommodate distal protection filters, because of superimposed stenosis and possibility of thrombus we have to use proximal protection device (MOMA). Both cases stented with wallstent 7×30, and in case 2 because of extreme tortuosity, stent delivery was possible only after buddy wire technique with a BHW guide wire. The procedure was done uneventfully, and both cases were discharged with no complication and event free survival till 1 year follow up.

LEARNING POINTS OF THE PROCEDURE

Spontaneous dissection of carotid artery can safely be stented even in tortuous segments with proximal protection devices.

PATIENT SELECTION FOR A PERCUTANEOUS VENTRICULAR PARTITIONING DEVICE IMPLANTATION AFTER ANTERO-APICAL MYOCARDIAL INFARCTION WITH LEFT VENTRICULAR SYSTOLIC DYSFUNCTION: A SINGLE CENTER EXPERIENCE

Alfonso Ielasi / Chiara Todaro / Giulietta Grigis / Alberto Repossini / Pasquale Scopelliti / Maurizio Tespili
Bolognini Hospital Seriate, Seriate, Italy

BACKGROUND

Parachute® (Cardiokinetix, Inc., Menlo Park, California) is a novel percutaneous ventricular partitioning device recently proposed for treatment of patients with ischemic heart failure (IHF) due to a prior transmural antero-apical myocardial infarction (MI) associated with regional wall motion abnormalities (WMA). However selection of patients who may benefit from this procedure remains a major challenge.

OBJECTIVE

In our study we sought to describe the selection protocol adopted by our center to identify potential candidates to Parachute implantation.

METHODS

From December 2013 to January 2015, 45 consecutive patients with IHF due to an anterior MI that occurred at least three months before clinical evaluation, were referred to our center for Parachute implantation screening. Each patient underwent a three-phase selection process including initial clinical evaluation (NYHA class \geq II) and a secondary screening step based on echocardiographic functional (Left Ventricular End-diastolic Diameter LVEDD \leq 40 \geq 15%, apical/anterior akinesia/dyskinesia) and anatomical parameters (LVEDD \geq 42 mm and \leq 67 mm measured respectively at 3.5 cm and 4.5 cm from LV apex). Finally patients meeting the echocardiographic criteria, were selected for 3D cardiac computed tomography (CT) for systematic evaluation of LV geometry and device size estimation. Patients with cardiac masses, apical thrombus, ventricular septal defect, apical pseudoaneurysm, more than mild valvular heart diseases (VHD), apical trabeculation and calcification in anchor and/or apical region were deemed not suitable for Parachute implantation, whereas patients fulfilling clinical and instrumental criteria were scheduled for the procedure.

RESULTS

From a total of 45 patients (mean age 69 ± 10 years) with previous anterior MI referred to our center, 20 patients presented with NYHA \geq II and were screened according to echocardiographic criteria. Seventeen patients met the echo inclusion criteria and were considered eligible for cardiac CT scan, 3 patients were excluded: 1 patient for more than mild VHD, 2 patients for WMA not limited to apical region; however, only 13 patients underwent cardiac CT imaging (3 patients refused further examination, 1 patient recovered with medical therapy). According to CT imaging criteria, 6 patients were considered suitable for Parachute implantation. Causes for exclusion were apical chordae in 2 patients, LV thrombus detection

in 2 patients; excessive apical trabeculations in 1 patient and too large LV in 2 patients. The device was successfully implanted only in 3 patients, since the other suitable 3 patients refused to undergo the procedure for psychological reasons. Clinical follow up of treated patients showed a significant improvement of quality of life and NYHA class.

CONCLUSION

Although, feasibility and efficacy of Parachute implantation have already been demonstrated in clinical trials, the use of this device in real world is still hampered by the complex selection of suitable patients. Moreover from our experience, it emerges that beside a good selection protocol, motivation and compliance of patients is crucial for a successful implantation program.

UNDERSTANDING THE ROLE OF 3D TEE IN PARAVALVULAR LEAK CLOSURE

Sushma Rekhraj¹ / Duncan McNab² / Stephen Hoole² / Cameron Densem² / Karen Parker² / James Boyd² / Leonard Shapiro² / Bushra Rana²

¹ Nottingham University Hospital Trust, Nottingham, UK

² Papworth Hospital NHS Trust, Cambridge, UK

BACKGROUND

Paravalvular leak (PVL) closure is an alternative to high-risk redo surgery. Procedure failure often results from poorly understood defect morphology. 3D transoesophageal echocardiography (TEE) clearly delineates defect anatomy, and may assist in device selection and procedural success.

OBJECTIVE

The aim of this study was to assess the use of 3D TEE to facilitate PR in our institution.

METHODS

PVL patients underwent percutaneous repair (PR) at our institution between May 2010–December 2015 using fluoroscopy and 3D TEE guidance. Live 3D colour datasets and Xplane TEE imaging were used to locate, define and measure PVL defects.

RESULTS

52 patients (mean age 70 years, logistic Euroscore 21%) underwent 62 PR procedures. 75% aortic; 25% mitral position. 32 patients had >1 defect. PVL anatomy varied from discrete open defects to irregular serpiginous tracts; mean defect size 7×8 mm, range 3–24 mm. Devices implanted included AVP III (n=44), Muscular VSD (n=5), Occlutech (n=2) and ASO device (n=1). 9 patients needed 2 devices whilst 6 patients had unsuccessful device deployment; 5 due to irregular serpiginous tracts, 1 due to instability of sewing ring. Procedure and fluoroscopy median (IQR) times were 120 (90–150) mins and 22 (11–49) mins respectively.

Follow up data available on 43 patients (average 15 months). Successful PVL closure achieved in 32 patients with an improvement in haemolysis (6 patients); symptoms (NYHA class ≥1 grade, 24 patients) and HF (25 patients). Five patients required redo surgery.

CONCLUSION

3D TEE aids successful PVL closure through improved patient selection. Accurate depiction of defect morphology, sizing and location may reduce procedure times and increase success; helping define potentially unsuitable anatomy. This information may help in the development of new occluder designs.

COMPLICATION DURING TRANSCATHETER AORTIC VALVE-IN-RING IMPLANTATION IN A FAILED MITRAL VALVE REPAIR

Bushra Rana¹ / Mateusz Orzalkiewicz¹ / Sushma Rekhraj² / Guillermo Martinez¹ / Yasir Abuomar¹ / Cameron Densem¹ / Steven Tsui¹

¹ Papworth Hospital NHS Trust, Cambridge, UK

² Nottingham University Hospital Trust, Nottingham, UK

HISTORY AND PHYSICAL EXAMINATION

An 86-year-old female presented in NYHA III heart failure. She had a previous mitral valve (MV) repair (complete 29 mm St Jude Tailor Ring with P2, P3 chordal reconstruction). Clinically she was in heart failure with a loud pan systolic murmur.

IMAGING

TTE and TEE imaging demonstrated a failed mitral valve repair with severe transvalvular MR secondary to leaflet thickening and prolapse. She had good biventricular function and no other significant valvular abnormalities.

INDICATION FOR INTERVENTION

Patient had recurrent admissions with heart failure and severe mitral regurgitation. She was deemed high risk for redo surgery (logistic Euro score 43%).

INTERVENTION

She underwent implantation of a transcatheter aortic valve into the MV annuloplasty ring, via a transapical approach. Using three-dimensional transoesophageal echocardiography (TEE) the MV ring diameter measured 23mm; 15% oversizing calculated an annulus diameter of 26.5 mm for prosthesis sizing. A 29 mm Edwards Sapien XT™ valve was deployed within the annuloplasty ring using a 2mls overinflated valve-balloon. Blood pressure (BP) was slow to recover after cessation of high rate ventricular pacing (HRVP). The valve gradually migrated spontaneously into the left atrium and threatened to embolize at which point BP recovered. The valve was recaptured with a 4mls overinflated valve-balloon and pulled back to its initial position under HRVP. The patient acutely deteriorated again with persistent hypotension. TEE showed the anterior MV leaflet (AMVL) had been pulled across the left ventricular outflow tract (LVOT), causing severe obstruction (invasive peak gradient 80 mmHg). Femoro-femoral cardiopulmonary bypass was established. Median sternotomy and transaortic excision of the AMVL was undertaken. TEE confirmed no LVOT obstruction (LVOTO) (peak gradient <10 mmHg). The patient's condition stabilized and she made a steady recovery.

LEARNING POINTS OF THE PROCEDURE

The experience with "valve-in-ring" procedure is limited. The complication of life-threatening LVOTO has not been described to date. In our case a thickened fibrotic AMVL and an acute angle between the planes of the aorta, LVOT and mitral valve annuloplasty ring resulted in acute LVOTO.

EMERGENCY PERCUTANEOUS THROMBUS FRAGMENTATION IN A NEONATE WITH BRACHIAL ARTERY THROMBUS

Anja Lehner / Sarah Ulrich / Florian Schettler / Marcus Fischer / Beatrice Heineking / Robert Dalla Pozza / Nikolaus A. Haas

Ludwig-Maximilians University of Munich, Munich, Germany

HISTORY AND PHYSICAL EXAMINATION

We report a 3190 g female neonate who presented 5 hours after uneventful vaginal delivery with pallor of the left upper extremity, capillary return > 8 secs, absent SaO₂ pulse and loss of distal pulses.

IMAGING

Echocardiography showed a structurally normal heart with persistent foramen ovale and a small open duct. The aortic arch and branching vessels were normal and well perfused. However, Colour Doppler examination of both brachial arteries showed unimpaired flow on the right side but complete interrupted flow at the proximal brachial artery on the left side with no significant collateral perfusion. In addition Doppler wave was damped on this side.

INDICATION FOR INTERVENTION

Lysis was contraindicated and heparinization for 24 hrs did not resolve the obstruction. With suspected arterial occlusion the patient was brought to cath lab for further investigation and acute intervention.

INTERVENTION

Angiography of the left subclavian artery showed a 12×2.4 mm thrombus completely occluding the proximal brachial artery (Fig. A). Balloon dilation (3.0×20 mm PTCA-Balloon) and subsequent thrombus fragmentation was performed. Angiography after intervention showed a well perfused upper extremity with no further thrombosis or re-stenosis (Fig. B). Clinically the affected hand and forearm showed prompt capillary return and palpable distal pulses as well as adequate SaO₂ pulse.

Figure A

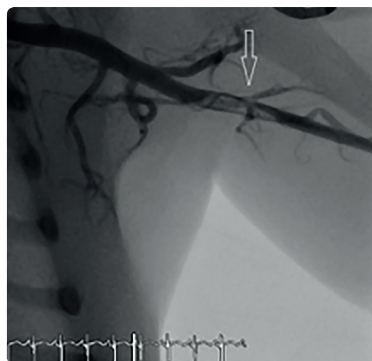
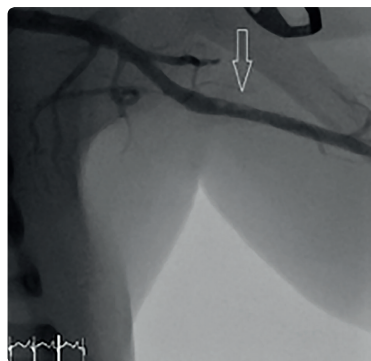

Figure B



After intervention the child received iv heparin with 400 IE/kg/d for 48 hours and ASS 3 mg/kg/d p.o. for additional 3 months. Diagnostic work-up included a thrombophilia screening with unremarkable results. Three days after admission the patient was discharged in good condition with no signs of restenosis. Sonography 4 weeks post intervention showed a well perfused brachial artery on the left with similar Doppler results on both sides. The patient showed no signs of impaired limb function.

LEARNING POINTS OF THE PROCEDURE

Current therapeutic options for neonatal arterial thrombosis include heparinization, fibrinolysis and surgical thrombectomy. Heparinization and fibrinolysis can be too slow to prevent further tissue damage and may be contraindicated due to the risk of especially intracerebral haemorrhage. Surgery comes with anaesthesia and can be difficult in smaller infants. An interventional approach with balloon dilation can be performed safely in low weight neonates with immediate clinical results. Prompt intervention to restore blood flow is crucial for limb salvage and normal functionality.

HEPATIC VEIN TO ATRIAL FISTULA – RARE CAUSE OF CYANOSIS IN A POST OPERATIVE CASE OF FONTAN SURGERY

Gaurav Garg / Himanshu Tyagi / Gaurav Agrawal / Joseph J. Vettukattil / Anil Sivadasan Radha
Apollo Health City, Hyderabad, India

CASE REPORT

This is regarding a 10-year-old boy with a diagnosis of common atrium, single ventricle, common atrio ventricular (AV) canal, severe pulmonary stenosis, no AV valve regurgitation, good biventricular function. He underwent bidirectional Glenn shunt with MPA ligation at age of 1 year in 2005. In July 2011, extra cardiac fenestrated Fontan operation was done. His saturation after surgery was 92% on room air and child was doing well after 3 months follow up. He did not come for follow up for 2 years. After 2 years, he came to us with dyspnoea on exertion and room air saturation of 70%. After detailed evaluation we found that his lungs were fairly normal with good sized branch pulmonary arteries (PA), cardiac function was good, there was no AV valve regurgitation and there were no signs of Fontan failure. Confused about the cause of cyanosis, we took the patient for cardiac catheterization. We found that Fontan circuit (fig 1) was flowing well with no decompressing veins. Mean PA pressure was 12 mmHg. We decided to balloon occlude the fenestration (fig 2) but there was only 2% increase in saturation with no effect on PA pressures. So, it was concluded that fenestration was not the cause of this severe cyanosis.

Hand injection was done in infra hepatic portion of inferior vena cava (IVC) which showed a huge fistula from left hepatic vein to atrium (fig 3). It was tapering distally with 14 mm near origin and 9 mm at distal end. We decided to balloon occlude the fistula. It was occluded with 14 mm × 4 cm Tyshak II balloon (fig 4). After occlusion, his saturation came up to 94% and mean PA pressure was 14 mmHg. Decision was taken to close the fistula with atrial septal defect (ASD) occluder. Fistula was successfully closed with help of 16 mm Lifetech ASD device (fig 5). Post device angiogram showed no residual flow through the fistula, room air saturation of 94% and mean PA pressure of 14 mmHg. He was discharged next day and is doing well on a follow up period of 6 months.

DISCUSSION

After excluding most of the causes of cyanosis in this patient, we incidentally found a huge fistula from left hepatic vein to atrium during cardiac catheterization which was beyond our suspicion. We could not find any cause of development of such kind of connection after Fontan surgery. This is a very rare defect which should always be kept in mind in a post operative case of single ventricle physiology who presents with cyanosis.

ADVANCED CARDIOVASCULAR ASSESSMENT OF VENTRICULAR FUNCTION WITH TISSUE MOTION ANNULAR DISPLACEMENT

Harikrishnan K N Kurup¹ / Benjamin Miller² / Bennett P Samuel¹ / Joseph J Vettukattil¹

¹ Helen DeVos Children's Hospital of Spectrum Health, Grand Rapids, USA

² Spectrum Health Offices of Research Administration, Grand Rapids, USA

OBJECTIVES

Tissue Motion Annular Displacement (TMAD), an advanced assessment technique based on atrioventricular valve annular motion tracking, provides rapid estimate of longitudinal function. Longitudinal function mainly depends on the displacement of the atrioventricular junction during the cardiac cycle and constitutes an important component of global function of the heart, especially in children. We evaluated TMAD as a measure of ventricular function in comparison with the currently used echocardiographic measures and speckle tracking echocardiography (STE).

METHODS

We assessed ventricular function in 122 children and adults using STE. Post-processing was performed on Philips Qlab and TomTec. TMAD was calculated from an average of 2 independent measurements from the apical four chamber views. Simple linear regression analysis was performed to correlate TMAD with STE parameters using SAS software Version 9.4.

RESULTS

The intraobserver variability was excellent (ICC=0.891) with adequate interobserver variability (ICC=0.697) for TMAD. Of the 122 echocardiograms (54 with Congenital heart disease), 2DSTE was performed on 114 and 3DSTE on 48 participants. Among 2DSTE variables, there was moderate correlation between Longitudinal Strain Rate (LSR, $r=0.29$, $p=0.009$) and Global Longitudinal Strain (GLS, $r=0.39$, $p<0.001$) with TMAD. Global Radial Strain (GRS, $r=0.42$, $p=0.003$) and GLS ($r=0.44$, $p=0.001$) measured by 3DSTE had moderate correlation with TMAD.

CONCLUSION

TMAD is a reliable and reproducible parameter and correlated well with commonly used measurements for assessment of ventricular function. TMAD correlated better with GLS than strain rate and with 3D GLS better than GRS. TMAD has previously been shown to correlate with cardiac magnetic resonance (CMR). In view of the ease of use of TMAD measurements and its strong correlation with CMR and STE parameters, it should replace the current echocardiographic measures of ventricular function.

PERCUTANEOUS RECANALIZATION OF A COMPLETELY OCCLUDED RIGHT PULMONARY ARTERY 3 MONTHS AFTER THROMBOEMBOLISM

Anja Lehner / Sarah Ulrich / Robert Dalla Pozza / Marcus Fischer / Florian Schettler / Ingram Schulze-Nick / Nikolaus A. Haas
Ludwig-Maximilians University of Munich, Munich, Germany

HISTORY AND PHYSICAL EXAMINATION

A 16-year-old girl was transferred to our clinic with a history of recurrent pulmonary embolism following deep vein thrombosis 3 month ago. Check up for prothrombotic risk factors revealed heterozygotic Factor V Leiden deficiency and prothrombin mutation as well as an additional intake of oral contraceptives. Heparinization was performed at the acute event, lysis however was deemed contraindicated. Clinically the patient presented now with persistent shortness of breath and reduced exercise capacity, NYHA class II–III.

IMAGING

CT scan showed vast chronic embolism in all parts of the lung and especially a large filling defect of the right pulmonary artery, most likely due to a massive proximal thrombus. Consequently pulmonary perfusion of the right middle and lower lobe was almost inexistent. Cardiac images held additional signs of right heart insufficiency with right ventricular dilation and prominent liver veins.

INDICATION FOR INTERVENTION

According to the patient's clinical impairment and extensive CT scan findings, hemodynamic evaluation for signs of pulmonary hypertension and possible transcatheter relief of thrombotic material was indicated.

INTERVENTION

The patient was referred to cath lab for further evaluation. Hemodynamic measurements showed normal right ventricular (RV) and pulmonary (PA, PCW) pressures (RV 18/0 mmHg, PA mean 10 mmHg, PCW 2 mmHg; PVRI 1.7 Wood units). However, selective angiography of the right pulmonary artery showed a completely blocked perfusion of the right main pulmonary artery (Fig. A). A guidewire was advanced across the embolus along the presumed continuity of the artery followed by PTCA balloon dilation using catheters in sizes up to 6 mm. Finally a high pressure balloon catheter with a diameter of 10 mm (Cordis Power-Flex®) was applied for repetitive dilation and thrombus fragmentation. Herewith satisfactory recanalization of the occluded pulmonary artery branches could be achieved. Angiography after intervention showed a well perfused right pulmonary artery and branching lower arteries with no signs for extravasation (Fig. B). The patient was stable throughout the whole intervention. Afterwards the patient was set on iv Heparin for 24 hours and long-term oral anticoagulation with warfarin was initiated.

One month later the patient presented in excellent clinical condition with considerable improved exercise capacity in NYHA I. Control angiography showed a well perfused right middle and lower lobe, no restenosis.

Figure A

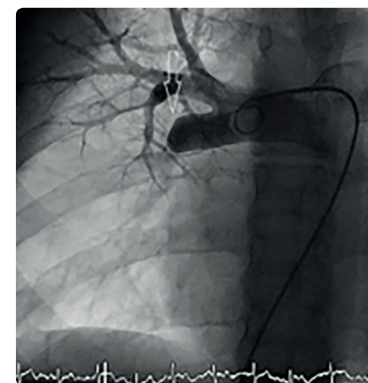
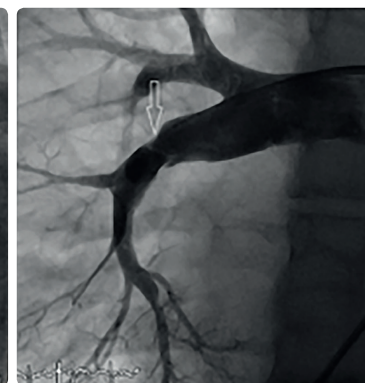
Figure B



LEARNING POINTS OF THE PROCEDURE

Like heparinization and fibrinolysis, percutaneous thrombectomy is thought to be less effective if the thrombus is organized and best results may be obtained in acute occlusions not wall-adherent and of less than two weeks duration. We present a case with successful percutaneous recanalization 3 month after pulmonary embolism with excellent clinical outcome. Percutaneous thrombectomy can be performed safely and with good clinical results even in subacute pulmonary thrombosis. This illustrates a valid option to surgical procedures to achieve rapid clot dissolution and improvement of a patient's right heart function and overall life quality.

MULTICENTER EXPERIENCE OF IMPELLA DEVICES IN FONTAN PATIENTS WITH SYSTEMIC VENTRICULAR DYSFUNCTION

Brian Morray¹ / Vivian Dimas² / Henri Justino³ / Doff Mcelhinney⁴

¹ Seattle Children's Hospital, Seattle, USA

² University of Texas Southwestern Medical Center, Dallas, USA

³ Texas Children's Hospital, Houston, USA

⁴ Lucille Packard Children's Hospital at Stanford, Palo Alto, USA

BACKGROUND

There are limited mechanical circulatory support options for patients with single ventricle (SV) anatomy. This is a multicenter, retrospective study of Impella devices to support the systemic ventricle in a cohort of SV patients with Fontan circulation.

OBJECTIVE

The aim of this study is to evaluate the procedural and short term outcomes using the Impella pump to support the failing systemic ventricle in SV patients with Fontan circulation.

METHODS

Patients with SV anatomy supported with Impella from 2012 to 2015 were included. Demographic information, indication for support, adverse events and short term outcome data were collected.

RESULTS

Ten patients were included. The median age and weight at implant were 26 years (4–38 years) and 64 kg (15–102 kg). Indications for support were systemic ventricular failure with cardiogenic shock or high risk electrophysiology (EP) procedure. The median duration of support was 49 hours (2.7–264 hours). Support was discontinued for ventricular recovery in 5 patients, transition to another device in 2 patients, completion of EP procedure in 2 patients and death in 1 patient. Survival to hospital discharge was 80%. Adverse events occurred in 4 patients. Hemolysis in 2 patients required transition to ECMO in 1 patient and device explant in another. One patient experienced an increase in aortic valve insufficiency from mild to moderate following explant. An additional patient developed a thrombus at the access site that did not require intervention. There were no bleeding or thromboembolic events.

CONCLUSIONS

Impella devices can provide temporary support for the systemic ventricle in SV patients as a bridge to recovery or additional device. Procedural survival and adverse event profiles are favorable.

TUNNELED DIALYSIS CATHETER EXCHANGE RATES: ANALYSIS AFTER A DEPARTMENTAL SWITCH TO THE BARD GLIDEPATH

Fareed Riyaz

Medical College of Virginia, Richmond, USA

BACKGROUND

Prior to November 2013, our department used a variety of tunneled dialysis catheter types for permacath placement. A department-wide switch to the Bard Glidepath was made that month with the hope that this would result in fewer permacath complications.

OBJECTIVE

This study was done to examine whether exchange rates of the Glidepath were statistically lower than those of other catheter types.

METHODS

An IRB-approved retrospective review was performed evaluating 1098 tunneled dialysis catheters placed from 10/17/2012 to 2/9/2015. Days to exchange were logged for all exchanged catheters. Indications for exchange were binned as such where possible: poor flow; infection; or malpositioning. Placements were excluded if a patient was lost to followup in ≤ 60 days (86 total) or if the indication was catheter damage (10 total), leaving 1002 total catheters. Exchange rates were analyzed at both ≤ 30 and ≤ 60 day samplings using pairwise X^2 statistical analyses.

RESULTS

507 non-Glidepath catheters (50.6%) were placed from 10/17/2012 to 10/31/2013, with the following breakdown: 16 Equistream, 9 Hemosplit, 364 Hemostar, and 118 Palindrome. 495 Glidepath catheters (49.4%) were placed from 11/1/2013 to 2/9/2015. The following comparisons were statistically significant at both 30 and 60 days:

- Glidepaths vs. all non-Glidepaths: less likely to be exchanged when binning all indications (ORs 0.44 and 0.39, at 30 and 60 days, respectively)
- Glidepaths vs. all non-Glidepaths: less likely to be exchanged for poor flow (ORs 0.32 and 0.52, at 30 and 60 days, respectively). Subgroup analysis found that this was due to high exchange rates of the Palindrome catheters for poor flow. Glidepaths vs. all non-Palindromes exchanged for poor flow did not meet significance (ORs 0.72 and 0.76, at 30 and 60 days, respectively)
- Palindromes vs. all other non-Glidepaths: less likely to be exchanged for infection (ORs 0.16 and 0.38, at 30 and 60 days, respectively)

CONCLUSIONS

The exchange rate for tunneled dialysis catheters is statistically lower since the switch to the Glidepath, driven by the high exchange rate of the Palindrome catheters for poor flow. Interestingly, the Palindrome has a lower exchange rate for infection, which may be related to differences in the Dacron cuff and will be further studied.

PERCUTANEOUS LEFT ATRIAL APPENDAGE OCCLUSION UNDER MONITORED ANESTHETIC CARE: SINGLE CENTRE ONE-YEAR EXPERIENCE IN HONG KONG

Gary Cheung / Anna Kin-yin Chan / Adrian Yue-yan Cheong / Kevin Ka-ho Kam / Alex Pui-wai Lee / Sylvia Au / Simon Chan
Prince of Wales Hospital, Hong Kong, China

BACKGROUND

Percutaneous left atrial appendage occlusion (LAAO) for stroke prevention in patients with atrial fibrillation (AF) is usually performed under general anaesthesia in many centres due to prolonged intubation of trans-esophageal echocardiographic (TEE) probe. With the support from the anaesthetists, our percutaneous LAAO program was run regularly under the monitored anaesthetic care (MAC) without the need of endotracheal intubation.

OBJECTIVE

The aim of this study was to share our experience and to evaluate the performance of the LAAO program.

METHODS

In this study, we shared our experience and evaluated the performance of the LAAO program between January and December 2015 in Prince of Wales Hospital in Hong Kong.

RESULTS

44 patients (28 males and 16 females) received percutaneous LAAO under MAC session. The average age was 73.9 years old (range 60–84), and the mean CHA₂DS₂-VASc and HAS-BLED scores were 4.1 and 3.1 respectively. 25 (57%) Watchman and 19 (43%) Amulet LAAO devices were implanted with mean procedural time of 66.9 minutes and fluoroscopic time of 15.3 minutes. There were two (4.5%) minor complications: vascular access site hematoma, which were managed conservatively. There were two (4.5%) major complications: cardiac tamponade requiring urgent open heart repair, and both patients were discharged home after 10 days and 30 days hospitalization. After excluding those two patients, the average length of hospital stay was 3.6 days (range 2–7 days). There was no device embolization, stroke, systemic embolism, air embolism, aspiration pneumonia, or procedural related death.

CONCLUSION

Percutaneous LAAO under MAC is feasible and safe. Major complication is uncommon, and could be managed promptly even under MAC. LAAO under MAC might be a good alternative in patients for AF stroke prophylaxis.

INTENTIONAL STENT FRACTURES IN CHILDREN: INTERMEDIATE TERM FOLLOW-UP

Hitesh Agrawal / Athar M. Qureshi / Henri Justino
Texas Children's Hospital, Houston, USA

BACKGROUND

Use of small diameter stents in young children and/or jailing of side branches pose significant challenges due to somatic growth.

OBJECTIVE

We sought to assess the capacity to induce longitudinal fractures in undersized stents to increase vessel diameter, and side cell fractures to enlarge stenotic jailed branches.

METHODS

Retrospective review of patients (pts) who underwent attempted intentional stent fractures (ISF) from 01/06–12/15.

RESULTS

21 pts (19 male), median age 4.7 (1.1–47.8) yrs, weighing 14.9 (6.9–102) kg underwent attempted ISF in 27 vessels. All but 3 ISF attempts were performed by a single operator. Initial stent implant occurred at a median age of 1.3 (0.1–34.1) yrs, at the following sites: pulmonary arteries (8), pulmonary veins (8), RV-PA conduit (4), systemic veins (6), and aorta (1). Types of stents were "coronary" (13), premounted Genesis (5), Genesis XD (n=2), Mega LD (2), Palmaz 4 series (2), and Palmaz 8 series (2), with initial stent diameters of 3.5–16 mm. Four patients had 2 completely overlapping stents, 1 had 3 overlapping stents and 4 had partial overlap at the stented segment. Using noncompliant balloons [Dorado (n=7), Atlas (10), Conquest (9) and Mustang (1)], longitudinal ISF was achieved in 17 and side cell expansion with strut fracture in 7 (diameter 5–20 mm, and pressure 12 to >30 atm). Three longitudinal ISF attempts were unsuccessful. Two pts had balloon rupture with no consequence.

Side cell ISF permitted immediate stenting of stenotic jailed side branches in 2 pts. Re-stenting was immediate in 4 longitudinal ISF; 2 had bare metal stents and 2 developed pseudoaneurysms requiring covered stents (1 pulmonary artery, 1 conduit). At a median follow up of 3 yrs (1 wk–9.3 yrs), 6 pts had 9 additional interventions for restenosis at site of longitudinal ISF: angioplasty (2), stenting (5), surgical stent flaring (1), conduit revision (1). There were no other late sequelae at ISF sites.

CONCLUSIONS

ISF can be induced safely using high-pressure balloons both longitudinally to expand undersized stents or through side cells to expand stenotic jailed branches. Longitudinal ISF may require covered stents due to immediate pseudoaneurysm formation and/or re-stenting due to late restenosis.

PERCUTANEOUS CIRCULATORY SUPPORT WITH IMPELLA DEVICES IN PEDIATRIC PATIENTS: A MULTICENTER STUDY

Vivian Dimas¹ / Brian Morray² / Doff Mcelhinney³ / Dennis Kim⁴ / Lynn Peng⁵ / Christopher S Almond⁵ / Shabana Shahnavaz⁶ / Sebastian Tume⁷ / Sonya Bhavsar⁸ / Noam Josephy⁹ / Henri Justino⁷

¹ University of Texas Southwestern Medical Center, Dallas, USA

² Seattle Children's Hospital, Seattle, USA

³ Lucile Packard Children's Hospital at Stanford, Palo Alto, USA

⁴ Children's Healthcare of Atlanta/Emory University, Atlanta, USA

⁵ Stanford University Medical Center, Stanford, USA

⁶ Washington University School of Medicine, Washington, USA

⁷ Texas Children's Hospital, Houston, USA

⁸ Abiomed Inc, Danvers, USA

⁹ Massachusetts Institute of Technology, Cambridge, USA

BACKGROUND

Options for minimally invasive circulatory support in children are few, and published data are limited to case reports and small single center series.

OBJECTIVE

to review use of Impella devices (Abiomed Inc, Danvers, MA) for temporary circulatory support in pediatric patients (age < 21 yrs).

METHODS

Retrospective multicenter review of pediatric implants performed from 2009–15 using a dedicated case report form.

RESULTS

34 patients from 12 centers were included. Median age and weight were 16 yrs (4–20.9 yrs) and 61 kg (15–134 kg). Indication for implant was cardiogenic shock (INTERMACS Profile I) in 25 patients (74%). Heart transplant rejection, myocarditis, or cardiomyopathy were the underlying diagnosis in 20 patients (59%); 9 others had congenital heart disease (5 biventricular, 4 univentricular). Median duration of support was 56 hrs (0.5 hrs–18 days) for ventricular recovery or transplant in 15 patients, transition to another device in 8, death in 5, and other in 6. Survival was 82% at 7 days and 67% at 30 days. Adverse events (INTERMACS definitions) occurred in 16 patients: hemolysis in 9 (major 3, minor 6, 2 of which were also on ECMO), device malfunction in 3 (major 1, minor 2), stroke in 2 (unrelated to Impella), sepsis in 1, critical leg ischemia in 1, with no major bleeding events.

CONCLUSION

Temporary circulatory support with Impella devices is feasible in pediatric patients, with a favorable risk profile compared to other modalities of support and compared to previously published adult studies.

CHALLENGES OF TRANSCATHETER INTERVENTIONS FOR CONGENITAL HEART DISEASES IN DEXTROCARDIA

Ib Vijayalakshmi

Sri Jayadeva Institute of Cardiovascular Sciences and Research, Bengaluru, India

BACKGROUND

Several challenges are faced by interventionalists while performing various percutaneous interventions for congenital heart disease (CHD) in patients with dextrocardia. The anatomical alterations in dextrocardia especially the lie of the interventricular septum (IVS) can cause impediment for device closure of ventricular septal defect (VSD) and lie of interatrial septum (IAS) for puncture.

PURPOSE

The aim of our study is to evaluate the challenges, feasibility and efficacy of transcatheter interventions in children with CHD in dextrocardia.

MATERIALS AND RESULTS

Out of 60 patients of CHD with dextrocardia catheterized, only 9 patients (15%) underwent transcatheter interventions. The age range was 4 months to 16 years (mean 5.4 years) and weight range was 4.1 to 40 kgs (mean 8.4 kgs). 3 cases underwent successful device closure for patent ductus arteriosus (PDA). 2 cases of midmuscular VSD (MVSD) were closed. One had to be closed with Amplatzer ventricular septal occluder through the jugular approach and the other with Amplatzer duct occluder II (ADO II). There was a difficulty in puncturing IAS during balloon valvuloplasty for mitral stenosis in a case of right-sided May Thurner Syndrome (MTS). Balloon valvuloplasty was done in one infant with severe pulmonary stenosis by flipping the cine image. One very sick patient with inferior vena cava web died after cavoplasty and stenting.

CONCLUSION

Catheter interventions in CHD with dextrocardia though difficult are feasible. The device closure of PDA and MVSD is not difficult especially with ADO II. The balloon mitral and aortic valvuloplasty in the complex cardiac anatomy of situs inversus totalis is feasible and safe. Rarely right-sided MTS may cause problems for right femoral access during transcatheter procedure.

CHALLENGES OF INTERVENTIONS FOR ASSOCIATED LESIONS IN CASES OF APICAL NON-COMPACTION

Ib Vijayalakshmi

Sri Jayadeva Institute of Cardiovascular Sciences and Research, Bengaluru, India

BACKGROUND

Isolated left ventricular non-compaction is reported extensively. But apical non-compaction (ANC) of both ventricles and septum is not reported much in literature. For the first time in the world, we are reporting the challenges of various interventions for different associated lesions in ANC.

PURPOSE

To know the challenges and feasibility of transcatheter interventions for the associated lesions in cases of ANC to reduce the pump failure.

MATERIAL AND RESULTS

Out of 100 consecutive patients diagnosed as ANC by transthoracic echocardiography (TTE), 30 cases underwent various transcatheter interventions and formed the material for this study. Age ranged from 3 days to 17 years (mean 8 years). The device closure was done for PDA in 2, VSD in 15, ASD in 1, ARVT in 1, ARAT in 1, ABV in 4, PBV in 2, aortoplasty in 1, PTMC in 2, pericardiocentesis in 3. 5 patients underwent two procedures in the same sitting. They were ABV and PBV, ABV and PTMC, ABV and PDA device closure, ASD and VSD device closure and PDA and VSD device closure. 3 cases of VSD were post-operative residual and one was closed with multiple devices. One 8-months-old infant had apical VSD closed with ADO II. Another 2-year-old child underwent hybrid surgery for closure of VSD with 14 mm device. Mirror image dextrocardia and midmuscular VSD was closed with device in one child. In one case procedure was abandoned as 18 mm VSD device slipped.

DISCUSSION

Procedures in ANC is risky in presence of LV/or RV dysfunction with or without thrombosis. Positioning the device in apical VSD in ANC cases is very challenging as the device gets caught in trabeculae in RV and if more tug is given the device slips through spongy myocardium. The results of interventions are very gratifying as the superadded pump failure due to pressure or volume overload caused by associated lesions improves significantly. One patient with severe AS and mitral stenosis had reverse May Thurner syndrome (obstruction of right common iliac vein by right common iliac artery), hence procedure was done through left femoral puncture.

CONCLUSION

Associated lesions in ANC worsen the pump failure. Transcatheter interventions, though challenging, are feasible, safe, effective and lifesaving. Transcatheter interventions certainly reduce the morbidity and mortality in ANC patients who are at high risk for surgery or redo surgery.

NOVEL TRANSCATHETER INTERVENTION IN COR TRIARIATUM DEXTER

Ib Vijayalakshmi

Sri Jayadeva Institute of Cardiovascular Sciences and Research, Bengaluru, India

BACKGROUND

Cor triatriatum dexter is an extremely rare congenital anomaly (0.025%), in which the right atrium is divided into two chambers by a septum, diagnosed on autopsy in the past. We describe antemortem diagnosis, by 2D transthoracic echocardiography with agitated saline contrast echocardiography and inferior venacava or superior venacaval venography. To the best of our knowledge, for the first time in world, we report a novel method of transcatheter balloon disruption of membrane in five cases, along with the balloon dilatation of rheumatic mitral stenosis in two cases and device closure of atrial septal defect in one case, to prevent morbidity and mortality.

OBJECTIVE

To describe the importance of transthoracic echocardiography with agitated saline contrast echocardiography and assess the feasibility and efficacy of transcatheter intervention.

MATERIAL AND RESULTS

Out of fifteen consecutive patients of cor triatriatum dexter, diagnosed with transthoracic echocardiography with agitated saline contrast echocardiography, five patients who underwent transcatheter balloon disruption of membrane and other interventions formed the material for this study. Three patients were boys and two were girls, age ranged between 3 to 17 years, median age was 10 years. Three patients presented with exertional dyspnea and two were asymptomatic. Two who had rheumatic heart disease with mitral stenosis underwent balloon mitral valvuloplasty and one case with atrial septal defect without pulmonary artery hypertension underwent device closure.

CONCLUSION

The cor triatriatum dexter is not benign as mortality occurs due to pulmonary embolism. Timely diagnosis with transthoracic echocardiography with simple agitated saline contrast echo followed by balloon disruption can prevent cyanosis, pulmonary artery hypertension, morbidity and mortality.

DEVICE CLOSURE IN RUPTURED SINUS VALSALVA

Haritha Pns

Government General Hospital Guntur, Guntur, India

HISTORY AND PHYSICAL EXAMINATION

A 38-year-old female pt. presented with sudden onset of chest pain, retrosternal, radiating to rt arm.

- Breathlessness class III with PND episodes
- PR: 110/min, B.P: 90/60 mmHg
- CVS: S1 loud, S2 P2 loud, continuous murmur present at right sternal border
- Lungs: Bilateral minimal creptations present

ECG AND ECHOCARDIOGRAM

- ECG showed sinus tachycardia with RV strain pattern
- Echo: Dilated right atrium and right ventricle, mild LV dysfunction
- Dilated non-coronary sinus, communication between non-coronary sinus and RA
- Mild to moderate tricuspid regurgitation.
- Severe PAH

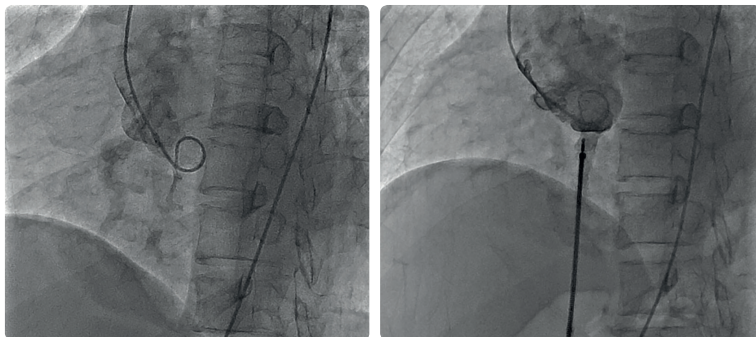
TEE

- RSOV with aortic side 8 mm diameter and exit 6 mm
- Length of the sac is 10 mm
- Away from the coronaries and near to the tricuspid valve
- Aortogram showed RSOV to RA draining just above the tricuspid valve
- Indications for closure
- To prevent failure and complications

Device closure done with 10/8 mm ADO I device. RSOV to RA can be closed easily by device closure.

Entry and exit sizing with TEE is very much useful for device size.

The shape of the defect suits ADO I device and the defect is far away from coronaries. So, device closure is safe and easy way of closing the unstable pt. without complications.



STENTING ARTERIAL SHUNTS FOR ADULT CONGENITAL PATIENTS WITH SINGLE VENTRICLE PHYSIOLOGY

Mohamed Kasem / James Bentham / John Thomson

Leeds General Infirmary, Leeds, UK

BACKGROUND

Adult patients with single ventricle physiology and pulmonary blood flow dependant on a surgically placed arterial shunt who did not progress to venous palliation are extremely challenging to manage. Progressive cyanosis secondary to narrowing of the shunt has a marked impact on exercise tolerance and results in intolerable symptoms for these patients. Stenting arterial shunts in adult patients are one method which can help improve pulmonary blood flow. There are no published studies in the literature about this subject.

OBJECTIVES

We present our experience in stenting arterial shunts in ACHD patients between 2008–2016 with the following aims: assess the clinical and haemodynamic changes after stenting the arterial shunts; present the technical challenges in stenting different types of arterial shunts; present the medium term follow up outcome for those patients.

METHODS

The institutional database was searched for Blalock-Taussig shunt (BTS) stenting in ACHD patients. 5 cases were identified during the studied period. The age range was between 17–45 years (mean 30.6 years) with two cases of central shunts, one case of left and right modified BTS, one case of bilateral classical BTS and one case of a left classical BTS to left lung and patent ductus arteriosus (PDA) to right lung. The oxygen saturations, NYHA status, haemoglobin level, atrioventricular valve regurgitation on echocardiography and left atrial volume were all compared pre and after the procedure (6–12 months after the procedure).

RESULTS

There was a short term improvement in oxygen saturations (pre procedure 70–85% [mean 75.8%]; post 78–87% [mean 83%]), P value: 0.04. Haemoglobin level fell from a pre procedure mean of 22.06 g/l to 20.28 g/l (range 18.1–24.4 g/l to 13–23.3 g/l), P value: 0.44. NYHA class fell from a mean of 3.2 to 2.2 post procedure. Left atrial volume for four cases did not change (22.6–76.6 mls [mean 48.37 mls] to 29.6–72.9 mls [mean 52.02 mls], P value: 0.83. Only one case showed an increase in AVVR from trivial to moderate (Vena contracta 0.4 mm) with the other cases showing no change.

CONCLUSIONS

Although stenting BTS has been reported in paediatric patients, repeated stenting and intervention on classical and modified BTS as a method of palliation has not been described. From our experience we feel that arterial shunt stenting is a challenging, but a potentially useful intervention in ACHD patients. The procedure can be done to improve the clinical and haemodynamical status of the patients or to prepare further surgical palliation.

TRANSCATHETER INTERVENTIONS AFTER GLENN ANASTOMOSIS AND FONTAN OPERATION IN PATIENTS WITH UNIVENTRICULAR HEART

Ahmet Celebi / Ilker Kemal Yucel / Orhan Bulut / Sevket Balli / Evic Zeynep Basar / Mehmet Kuecuk
Dr Siyami Ersek Hospital, Istanbul, Turkey

INTRODUCTION

In this paper, we aimed to present transcatheter treatment of patients with a single ventricle physiology, experiencing low cardiac output or severe systemic desaturation after a Glenn or a Fontan operation.

METHODS

We retrospectively evaluated 28 patients in whom a transcatheter intervention was attempted due to the presence of signs and symptoms low cardiac output and/or severe systemic desaturation after a Glenn or a Fontan surgery between 2007 and 2016.

RESULTS

The mean age was 7.6 years (6 months–21 years) and the weight was 25.2 kg (6–54). 29 attempts were made in 28 patients. The procedures were performed after a Kawashima, Glenn and Fontan surgery in 3, 12 and 13 patients, respectively. A severe systemic desaturation was encountered in 15 patients. Amongst these patients, closure of a Fontan fenestration was performed in 7. We occluded a decompressing vein in 5 and a pulmonary arteriovenous fistula closure in one. Closure of a residual right SVC-atrium connection was performed in one and stent implantation to reroute the hepatic blood flow to the right lung in one, after a Kawashima operation. The mean oxygen saturation of $79.3 \pm 8.1\%$ (65% to 90%) increased to $92.2 \pm 5.6\%$ (85% to 100%) and the mean PA pressure increased from 11.9 ± 2.2 mmHg (8–16) to 13.5 ± 2.1 mmHg (10–17). Signs and symptoms of low cardiac output and/or increased pulmonary artery pressure was detected in the remaining 13. Attempts had to be made at an early stage after the Fontan surgery in 4. One patient was on an ECMO support. Amongst these 13 patients, an antegrade pulmonary flow was occluded using a number of devices in 7, antegrade flow was closed with the use of a covered stent, resolving an associated left PA stenosis at the same time in one. Among 3 patients suffering from branch PA stenosis, 2 received stent implantation while the remaining was treated via cutting balloon angioplasty. Two separate stents were needed to treat branch PA and extracardiac conduit stenosis in one. In the patient on ECMO support, Fontan fenestration was dilated with a balloon to ensure cardiac output at the expense of systemic desaturation. In patients with low cardiac output, the preprocedural PA pressure decreased from 20.6 mmHg (15–27) to 14.9 ± 1.8 mmHg (11–18). There was no procedural mortality. Circulatory failure regressed in all cases except one. Protein losing enteropathy (PLE) was encountered after the device closure of Fontan fenestration in one and PLE was resolved with medical treatment and did not recur during follow up.

CONCLUSION

A thorough pulmonary artery reconstruction is of utmost importance in staged palliation of patients with a single ventricle. To avoid reopening of the antegrade flow, surgeons should not only ligate but divide the PAs from the corresponding ventricle. In the presence of circulatory failure/high PA pressure or systemic desaturation, urgent catheterization should be considered to assess hemodynamic and anatomic condition. Appreciated significant PA stenosis should be treated even if there exists no pressure gradient throughout the circulation.

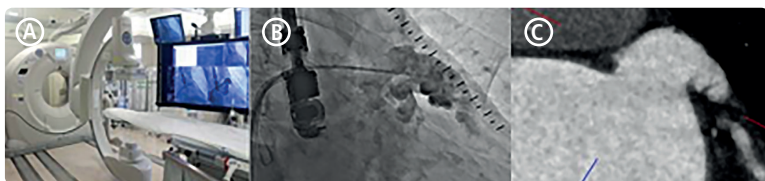THE NOVEL APPLICATION OF INTRAPROCEDURAL CARDIAC COMPUTED TOMOGRAPHY FOR LEFT ATRIAL APPENDAGE OCCLUSION

Jung-Sun Kim
Yonsei University, Seoul, South Korea

HISTORY AND PHYSICAL EXAMINATION

A 67-year-old woman with persistent atrial fibrillation (CHA₂DS₂-VASc: 6 and HAS BLED: 4), recurrent stroke and intracranial bleeding on Apixaban was considered for left atrial appendage (LAA) occlusion with Amplatzer Cardiac Plug (ACP). An angiography shared multi-detector computed tomography system (MDCT) was applicable in this procedure (Panel A). Before the procedure, transesophageal echocardiography (TEE) and MDCT were performed to evaluate the LA and LAA. The dimensions of landing zone were 18–21 mm in TEE, 19–21 mm in angiography and 20–22 mm in MDCT (Panel B and C).

IMAGES



INDICATION FOR INTERVENTION

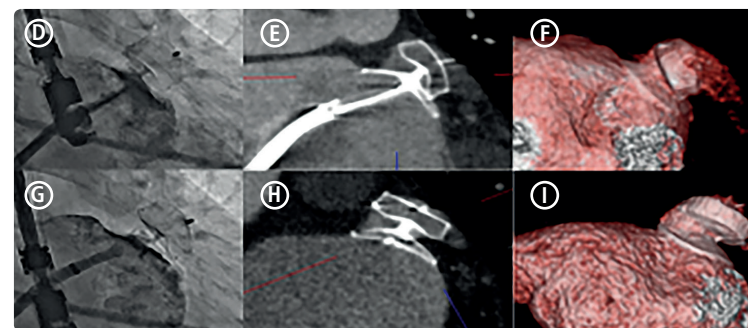
Non-valvular atrial fibrillation with high stroke risk and bleeding risk can be a recommended indication for LAA occlusion.

INTERVENTION

24 mm ACP was selected and deployed without complication. Before releasing the device, conformational change, position and anchoring of device could be assessed with angiography shared MDCT applying 640 channel double-slice technology (Aquilion ONE™; Toshiba Medical) which allows a CT scan to be evaluated during procedure on the same table. Although angiography and TEE showed an appropriately seated device in LAA (Panel D, Supplementary material online S1 and S2), MDCT clearly demonstrated the configuration of device and complete closure of LAA (Panel E and F). Then, device was safely detached from the delivery cable (Panel G). 2 days after procedure, MDCT was performed to check the position of device and communication between LA and LAA (Panel H and I).

LEARNING POINTS OF THE PROCEDURE

1. One of the serious complications is a device embolization, with difficulties to identify the risk with angiography, 2 dimensional (2D) or 3D TEE.
2. Possible role of intraprocedural role of MD CT during LAA occlusion.



SUCCESSFUL PERCUTANEOUS REPAIR OF AN ACQUIRED GERBODE DEFECT

Kully Sandhu / Paul Ridley / Najeeb Azam / Rob Butler / Adrian Large
Royal Stoke University Hospital, Stoke-on-Trent, UK

HISTORY AND PHYSICAL EXAMINATION

3 weeks after redo surgical replacement of her mitral and aortic valves to treat severe prosthetic aortic regurgitation and an aorto-right ventricular fistula, a 57-year-old Caucasian female's recovery was complicated by breathlessness on minimal exertion and complete heart block without major hemodynamic upset otherwise. A pan-systolic murmur and systemic congestion were noted. Echocardiography demonstrated a communication between the left ventricle and the right atrium (acquired Gerbode defect).

6-years earlier the patient had suffered septic, superior mesenteric artery embolism and bowel necrosis complicating staphylococcal aortic endocarditis. These were treated with extensive bowel resection, aortic valve replacement with a bioprosthesis (Epic supra 21mm) and an extended course of intravenous antibiotics. Soon thereafter short bowel syndrome demanded instigation of long-term, intravenous nutrition via a tunnelled, right subclavian, venous catheter. The patient represented in the spring of 2015 with progressive dyspnoea. Severe transvalvar aortic regurgitation and an aorto-right ventricular fistula were demonstrated echocardiographically. Coronary arteriography revealed no stenoses. Redo surgery was undertaken wherein a degenerated aortic prosthesis was replaced by a 21mm Magna Ease bioprosthetic valve and the aorto-ventricular fistula was repaired. In addition, a defect was noted in the base of the anterior leaflet of the mitral valve. An attempt at repairing this with a pericardial patch was unsuccessful and ultimately complete replacement of the mitral valve with a 27mm Perimount bioprosthesis was required.

IMAGING

Figure 1a
TOE image of acquired Gerbode defect before intervention.

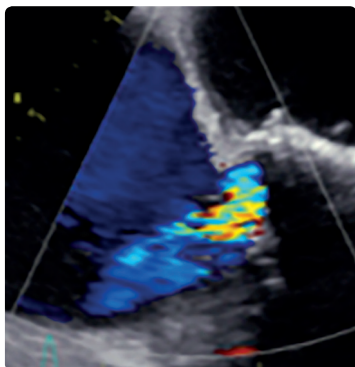


Figure 1b
TOE image of the site of the defect after intervention.

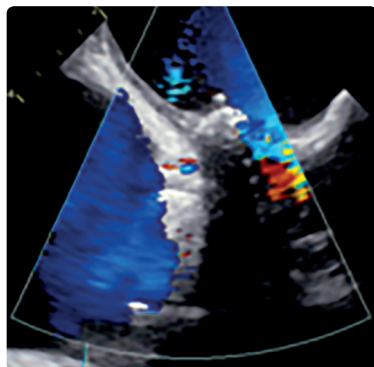
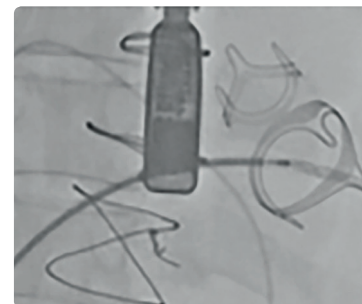

Figure 2

Fluoroscopic image acquired during the deployment of an Amplatzer muscular VSD occluder in the defect.



INDICATION FOR INTERVENTION

A joint cardiology-cardiac surgery conference unanimously recommended an attempt at percutaneous closure of the acquired Gerbode defect with a view to relieving heart failure and reducing the risks of recurrent endocarditis and mortality.

INTERVENTION

The patient was anaesthetised. Transvenous, temporary, right ventricular pacing was established via a 6F sheath in the right femoral vein. Under fluoroscopic and transoesophageal echocardiographic guidance and using a telescoping catheter system composed of a 5F JR4.0 diagnostic coronary catheter inside an Agilis NxT steerable introducer sheath (St Jude Medical), the tip of a hydrophilic 0.035 guidewire (Terumo Corp.) was steered across the defect from right atrium to left ventricle. The coronary catheter was then advanced to the left ventricle and the hydrophilic wire was replaced with a 300 cm, 0.035, pre-shaped TAVR guidewire (Safari, Boston Scientific). Next, the telescoping catheter assembly was exchanged for an 8F flexible guiding sheath (Flexor Shuttle, Cook Medical). The guidewire was removed and a 12 mm Amplatzer muscular VSD occluder (St Jude) was deployed across the communication. Further echocardiographic assessment demonstrated a stable device position with complete occlusion of the defect and cessation of left to right shunting of blood without atrioventricular or aortic valve impingement. The device was set free and there were no procedural complications. A few days later a permanent pacemaker system (left ventricular free wall epicardial lead) was implanted via a small left thoracotomy and the patient was subsequently discharged from hospital in good condition having been fully mobile without cardiorespiratory symptoms.

LEARNING POINTS OF THE PROCEDURE

1. The case exemplifies the assertion that percutaneous repair of acquired cardiac and great vessel defects is commonly feasible, safe and effective.
2. The use of a highly steerable, supportive but low profile introducer sheath may facilitate complex structural cardiac interventions and reduce procedure complexity and duration.
3. Good clinical outcomes in complex, multiple co-morbid patients with advanced heart diseases are often the result of synergistic efforts by a team of experts from differing clinical backgrounds.

PATIENT RADIATION EXPOSURE DURING INTERVENTIONAL PROCEDURES IN CHILDREN AND ADULTS WITH CONGENITAL HEART DISEASES – A SINGLE CENTER EXPERIENCE

Lidia Wozniak / Paulina Glowacka / Aleksandra Skrzypka / Klaudia Spaczynska / Dominika Sabiniewicz / Jaroslaw Meyer-Szary / Robert Sabiniewicz
Medical University of Gdansk, Gdansk, Poland

BACKGROUND

Cardiac catheterization (CC) is an important diagnostic and therapeutic tool in children and adults with congenital heart diseases (CHD). In the last decade CC is increasingly performed, however, the long-term effects connected with radiation exposure haven't been studied yet. These potential risks require particular concern in children with complex congenital heart diseases who undergo plenty of such procedures during lifetime.

OBJECTIVE

To determine patient radiation exposure levels during diagnostic and interventional CC in children and adults with CHD.

METHODS

We retrospectively reviewed data of all patients who underwent diagnostic or interventional CC at the Department of Pediatric Cardiology and Congenital Heart Diseases from January 2010 to October 2015. Electrophysiological procedures were excluded. Demographics, procedural data and patient radiation exposure levels were collected and analyzed. Radiation dose was quantified as fluoroscopy time (FT), air Kerma dose (K) and dose area product (DAP). Data is presented as median (minimum–maximum) values or proportions.

RESULTS

A total of 828 patients (576 children) underwent 870 procedures (159 diagnostic and 711 interventional). The median age was 7.1 years, ranging from 1 day to 85 years and the median weight was 22 kg (range 2.1–125). There were 60 children under 5 kg. The most common procedures were atrial septal defect (ASD) closure and persistent ductus arteriosus (PDA) closure: 26.1% and 20% respectively. The median FT was 3.4 min (range 0.3–87.7), the median K was 21 mGy (range 0.2–8100) and the median DAP was 108.8 uGy*m² (range 1.6–17046). The longest FT were noted during a coronary artery fistula closure – the median FT was 28.2 min (range 17.1–87.7), during a balloon angioplasty of distally narrowed pulmonary arteries – the median FT was 19.55 min (range 17.3–21.8) and during a ventricular septal defect closure – the median FT was 19.3 min (range 11.0–54.0). The shortest FT have been associated with PFO closure – the median FT was 2.3 min (range 0.9–42.6), ASD closure – the median FT was 2.7 min (range 1–36) and PDA closure – the median FT was 2.7 min (range 1.2–31.2).

CONCLUSION

Findings of the present study urge to pay special attention while performing coronary artery fistula closure and balloon angioplasty of distally narrowed pulmonary arteries to maintain radiation exposure at lowest possible levels. It is particularly important with the latter condition as it frequently recurs and repeated procedures are warranted.

PERCUTANEOUS CLOSURE OF A POST-SURGICAL PSEUDOANEURYSM OF THE ASCENDING AORTA

Miroslava Stolcova / Francesco Meucci / Giovanni Squillantini / Gennaro Santoro
Careggi Hospital, Firenze, Italy

HISTORY AND PHYSICAL

We present a case of an 82-year-old lady, referred to our team after radiological documentation of a pseudoaneurysm of the ascending aorta. She had aorto-coronary bypass surgery 20 years ago and a re-do sternotomy for a severe mitral regurgitation due to anterior mitral leaflet prolapse treated with mitral valve replacement two months ago. Her post-operative course was complicated by a long-lasting sternal wound dehiscence and infection treated with antibiotic therapy and surgical debridement. She eventually underwent a CT scan in order to evaluate the presence mediastinal involvement in the infectious process of the sternum. The contrast-enhanced CT scan showed a 18×43 mm pseudoaneurysm anteriorly to the ascending aorta, very close to the posterior sternal surface. Osteomyelitis of the sternum was also present.

IMAGING

Imaging techniques used were CT scan and fluoroscopy. The pseudoaneurysm was spheric, with an entry port of a diameter of approximately 4 mm, the nearest by-pass graft anastomosis was 9 mm far away.

INDICATION FOR INTERVENTION

Indication for percutaneous intervention were the very high surgical risk for a re-do sternotomy and a bypass-graft running very close to the sternal midline.

INTERVENTION

A diagnostic aortography through right femoral artery access was performed confirming the presence of a pseudoaneurysm of the ascending aorta. The cavity was easily engaged by a 6F diagnostic Amplatz Right 1 catheter. A stiff INNOWI 2cm TAVI wire (Symbrix, Oberhaching, Germany) was then placed inside the cavity to allow advancement of a 6F long PDA-occluder sheath (St Jude, St Paul, MN). Subsequently a 6mm Amplatzer Septal Occluder (St Jude, St Paul, MN) was implanted and released after angiographic confirmation of a complete occlusion of the entry port of the pseudoaneurysm. A control CT scan showed absence of residual leak inside the cavity.

LEARNING POINTS OF THE PROCEDURE

The main learning point of the procedure is the possibility of percutaneous closure of a post-surgical perforation of a native ascending aorta causing pseudoaneurysm.

TWO CENTER EXPERIENCE WITH NOVEL IMAGE FUSION SOFTWARE FOR 3D GUIDANCE OF COMPLEX CARDIAC CATHETERIZATIONS

Goreczny S.¹ / Dryzek P.¹ / Lukaszewski M.¹ / Moll J. A.¹ / Moszura T.¹ / Kuhne T.² / Berger F.² / Schubert S.²

¹ Polish Mother's Memorial Hospital, Research Institute, Lodz, Poland

² German Heart Center, Berlin, Germany

INTRODUCTION

Recent improvements in the development of fusion imaging software have led to the introduction of a 3D roadmap based on preregistered Computed Tomography (CT) or Magnetic Resonance (MR) datasets for live guidance of trans-catheter interventions.

METHODS

We performed a retrospective review of all cardiac catheterizations guided with novel image fusion software VesselNavigator (Philips), at two reference centres. Patient characteristics and catheterization data were reviewed with focus on fusion of pre-intervention imaging and intervention guidance.

RESULTS

Between 11/2015 and 03/2016, VesselNavigator was applied in 23 patients for planning (n=5) and live guidance (n=18) of cardiac catheterization. The median age was 13.1 years (2 weeks–64 years) and median weight was 36.4 kg (3.5–116 kg). Fifteen patients underwent trans-catheter interventions: pulmonary valve placement (n=6), stent implantation in pulmonary artery (n=4), aortic coarctation (n=3), arterial duct (n=1) and pulmonary artery balloon dilation (n=2). In the remaining 3 patients diagnostic catheterization was performed. A 3D roadmap was created from existing CT (n=12) or MR (n=6) datasets. For registration and fusion of the overlay, fluoroscopy images were acquired in 2 projections with spine and vertebrae (n=11), test angiography (n=7), calcifications (n=5), previously placed devices (n=2) serving as reference points for orientation of the 3D roadmap against live fluoroscopy. Accurate overlay was achieved in 15 patients (83%) with 3 patients requiring intra-procedural angiography to gain proper alignment.

CONCLUSIONS

VesselNavigator proved to be useful in guidance of versatile complex diagnostic and interventional cardiac catheterizations. Intuitive segmentation and easy fusion with live fluoroscopy allowed shortening of the diagnostic phase of the procedure and reliable 3D roadmap facilitated interventional treatment.

RETROGRADE CATHETER OCCLUSION OF RECURRENT LARGE SYSTEMIC VENOUS FISTULAE AFTER CP SHUNT

Oliver Stumper

Birmingham Children's Hospital, Birmingham, UK

BACKGROUND

Systemic venous fistulae (SVF) to the IVC frequently develop after creation of a superior cavopulmonary (CP) shunt in patients with borderline haemodynamics. Recurrence rate is high after standard embolization. Conversion to high-risk Fontan circulation addresses the problem – but mortality in these is high. If Fontan completion is not acceptable patients will suffer from severe progressive desaturation.

OBJECTIVE

Develop a new catheter approach for occlusion of recurrent large SVF after CP shunt.

PATIENTS AND METHODS

Five patients (mean age 12 (5.4–16.1) yrs) had severe recurrent SVF in the setting of unsuitable Fontan haemodynamics, morphology or co-morbidities.

RESULTS

All 5 patients had numerous feeding vessels to the vertebral and paravertebral plexus which then drained from posteriorly to the left renal vein or the IVC. Follow-through angio or balloon occlusion angiography was employed to identify the drainage site and to enter these large venous collaterals from the IVC. Retrograde intubation was achieved in all. Either SJM vascular plugs or duct occluders were placed in both the right and/or left paravertebral venous systems at the level of the diaphragm. Oxygen saturations increased from 74 (71–78)% to 84 (81–86)% [$p < 0.05$]. No further re-intervention was required for 24 (12–108) months.

CONCLUSION

Severe recurrent systemic venous fistulae after superior cavopulmonary shunt can be addressed effectively by retrograde catheter occlusion in patients with unsuitable Fontan haemodynamics. The use of suitable angiographic and catheter techniques is essential for success.

TRANSCATHETER OCCLUSION OF A LARGE PULMONARY AV FISTULA DRAINING INTO THE SCIMITAR VEIN IN A YOUNG INFANT

Raghavannair Suresh Kumar / Salim Al Maskar / Borris Dimitri / Eapen Thomas / Abdulla Al Farquani
National Heart Centre, The Royal Hospital, Muscat, Oman

BACKGROUND

Pulmonary AV Fistula (AVF) is uncommon in infancy and its occurrence in association with Scimitar syndrome has been reported only in an adult. This is the first report of this unusual condition in early infancy and its successful trans-catheter management.

HISTORY AND PHYSICAL EXAMINATION

A term baby presented with severe congestive heart failure in the third week of life. Weight 3.7 kg. The baby was tachypneic with SPO₂ of 88%. The heart was dextroposed. S₁ was normal, S₂ single and loud. There was grade 2/6 systolic murmur over right sternal border and right lung fields.

IMAGING

Chest Xray showed dextroposed heart, cardiomegaly and increased lung vascularity. 2D echo showed dextroposition, Situs solitus and AV and VA concordance. There was a small secundum ASD with bidirectional shunt, no other intracardiac lesion. RA/RV were dilated with moderate TR and systemic RV pressure. Rt lower lobe pulmonary vein drained into the IVC, without any obstruction. There was a large collateral to left lower lobe from lower descending aorta. CT angiogram confirmed the findings and showed a tracheal bronchus to right upper lobe.

INTERVENTION 1

With a diagnosis of Scimitar syndrome, the baby underwent catheter occlusion of collateral artery from femoral arterial access, deploying ADO2 4/4 device achieving complete occlusion.

PROBLEM

Despite successful collateral occlusion, the baby had severe PAH by echo and could not be extubated after 3 weeks. This period was complicated by recurrent lung collapse and septicemia. As these issues settled, it was decided to restudy the baby.

INTERVENTION 2

PA pressures were systemic. Descending aortogram showed complete occlusion of the aberrant vessel; there was no additional collateral.

RPA lower lobe branch angiogram showed a feeder vessel measuring 3 mm leading to a long tortuous vessel connecting with the pulmonary vein draining into IVC – the “Scimitar vein”. This was entered with a 4F RCA catheter and an Amplatzer extrastiff 0.035”×260cm wire was parked in the LPA lower lobe

branch. 6F Mullins sheath was introduced over the wire. Attempt to deliver a 6/4 ADO1 device did not succeed as the device would not track. Hence 5/4 ADO2 device was introduced through the same sheath. This tracked easily and was successfully deployed. The fistula was completely closed. PA pressures dropped to 60% systemic value immediately. Baby was extubated in 2 days and the post procedure echo showed normal RV pressures. He had a longer hospital stay due to recurrent lung collapse.

LEARNING POINTS OF THE PROCEDURE

This is the first report of Pulmonary AV Fistula involving the Scimitar vein in a young infant and causing severe PAH. When a Scimitar baby fails to improve after conventional collateral occlusion and has heart failure/PAH, this rare, but curable possibility also merits consideration.

STENTING THE LEFT PULMONARY ARTERY AFTER NORWOOD – PERFECTION IS THE ENEMY OF GOOD!

Oliver Stumper

Birmingham Children's Hospital, Birmingham, UK

HISTORY

17-year-old male patient after staged Norwood/Fontan palliation for hypoplastic left heart syndrome. Required epicardial DDD pacing with extracardiac Fontan completion at 4 years of life. Underwent fenestration closure at 5.2 years for severe persistent cyanosis and poor exercise tolerance. At 8.3 years of life was diagnosed with protein losing enteropathy (PLE) and underwent stent fenestration, stenting of left pulmonary artery (LPA) and balloon RPA, together with intensified medical management. Recovered and underwent reduction of stent fenestration and upsizing of LPA stent at 11.5 and 14 years of age.

IMAGING

Elective cath to upsize stent in LPA to adult size, echo fine.

INDICATION FOR INTERVENTION

Decision to electively enlarge stent in LPA at 17 years of age before transferring care to grown up congenital heart service

INTERVENTION

Initial LAO angio documented long segment narrowing/compression of the left pulmonary artery. Decision to implant a 10×30 mm Cook Formula stent across the whole length – right up to the left upper branch PA. Further dilated to 14 mm with Crystal balloon – balloon fractured. Probably retrieved completely with various attempts and manoeuvres. Clinically initially well. After 3 months reduced exercise tolerance, tired and puffy. Possible chest infection. After 5 months: peripheral oedema and recurrence of PLE with albumin of 21 and Hb of 7.8. Started on iron and folate and blood transfusion. And booked for early recath.

Initial angio 5 months post re-stenting showed huge filling defect within LPA stent. Discussed with surgeons regarding reop: high risk and not keen. Thus, interventional attempts at recanalization – with some success.

A number of hours later (and some further stents) looked ok.

Kept on therapeutic Heparin and control CT 5 days later – complete occlusion of LPA.

Thus repeat cath – no flow to LPA – insertion of central line towards LPA and infusion of rTPA.

No improvement.

Decided that he is not a surgical or transplant candidate.

Referral to Freeman Hospital – Mr Hassan.

Prepared to attempt extensive thromboembolectomy.

Intraoperative findings of a tear in the posterior aorta and that the stents had denuded the aorta – Aorta was replaced with a Dacron graft, the LPA was replaced with a 16 mm Contegra and the TV was replaced with a 29 mm Carbomedic.

Balloon fragment was found and retrieved.

OUTCOME

Patient is alive and doing reasonably well – currently not a transplant candidate.

LEARNING POINTS OF THE PROCEDURE

- Perfection is the enemy of good!
- When overdilating closed cell stents – struts may fracture and penetrate into surrounding vessels
- Haemolytic anaemia suggests high pressure fistula
- Shall we use covered stents to overdilate/crack & burst existing stents?
- Never leave small balloon segments behind in Fontan/CP shunt circulation.

TRANSCATHETER RIGHT VENTRICLE OUTFLOW TRACT STENTING AFTER INTRACARDIAC REPAIR OF TETRALOGY OF FALLOT

Sanjiban Ghosh / Anuradha Sridhar / Neville Solomon / Muthukumaran Chinnasamy Sivaprakasam
Apollo Children's Hospital, Chennai, India

BACKGROUND

The incidence of re-intervention after surgical repair for tetralogy of Fallot (TOF) has been increasing. Significant right ventricular outflow tract obstruction (RVOTO) is one of the most common causes of re-intervention after TOF surgery. Though surgical management in the form of resection and reconstruction is the standard approach, that is not free of risk and sometimes difficult because of previous surgery. Transcatheter technique for RVOT reconstruction has been well described as a mode of palliation for TOF, however, the experience of transcatheter intervention as definitive repair of RVOTO by percutaneous stent implantation is very limited. We report our experience of safety and feasibility of transcatheter right ventricular outflow tract stent implantation in two children with RVOT stenosis after surgical repair of TOF.

HISTORY AND PHYSICAL EXAMINATION

PATIENT 1

6-year-old male child presented with mild effort intolerance. At the age of 2 years 6 months he underwent successful repair of TOF with RV-Pulmonary artery conduit using 16 mm Contegra valved conduit placement for TOF with absent pulmonary valve. On examination ejection systolic murmur was noticed over pulmonary area.

PATIENT 2

3-year-old boy presented with progressive exertional dyspnoea and features of RV failure for last 6 months. He underwent intracardiac repair at 7 month of age. Hepatomegaly with pedal oedema was noted. JVP was found to be elevated. Ejection systolic murmur was noted over pulmonary area and pansystolic murmur of tricuspid regurgitation was noticed over left 5th intercostal place.

IMAGING

Echocardiography was done for both the patients. For the first patient good flow was seen across the RV-PA conduit with mild conduit regurgitation. But there was severe subvalvar pulmonary stenosis noticed in echocardiography. Severe residual subvalvar pulmonary stenosis with severe high pressure tricuspid regurgitation were noticed in the echocardiography for the second patient along with moderate RV systolic dysfunction. Diagnostic cardiac catheterization was done for both of them and RV pressure was found to be suprasystemic for both of them. RV angiography showed severe infundibular pulmonary stenosis.

INDICATION FOR INTERVENTION

As RV pressure was found to be suprasystemic and stenosis was noted at the infundibular level, it was decided to perform RVOT stenting for both the children.

INTERVENTION

RVOT stenting has been done for both of them using CP stent which is redilatable. For the second child, the stent has been positioned 2mm proximal to native pulmonary valve to preserve the valve function. Post procedure RV pressure was found to be less than 50% of LV pressure for both of them. Post procedure echocardiography showed no significant increase in PR/Conduit regurgitation. Both of them were clinically asymptomatic at post procedure follow up after 9 months. Echocardiography showed good stent position without any displacement, distortion and stent fracture. Mild residual supra-valvar stenosis was noted for the first patient while mild gradient was noted across the stent for the second patient.

LEARNING POINTS

Transcatheter infundibular stent implantation is a safe and effective alternative to surgical reconstruction for residual RVOTO after TOF surgery. It is preferable to use sturdy stents to maximize the radial strength of the deployed stent and to allow for redilatation if required to compensate for growing RVOT dimension. Longer term follow up is required to draw the final conclusion.

Figure 1
Pre Intervention Echocardiography showed severe infundibular stenosis

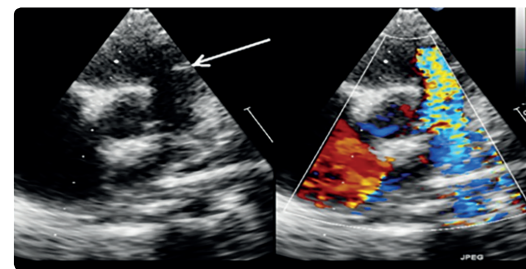
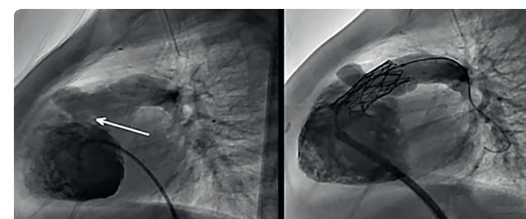


Figure 2
Pre Intervention RV angiogram showed severe infundibular stenosis (left side) and post Intervention RV angiogram showed good position of RVOT stent and good flow across the stent



A CASE OF CONGENITALLY CORRECTED TRANSPOSITION OF GREAT ARTERIES: AN INFREQUENT HAPPENSTANCE

Prakash Ajmera / Vikas M.

Malla Reddy Narayana Multispeciality Hospital, Hyderabad, India

HISTORY AND PHYSICAL EXAMINATION

A 42-year-old male, occasional drinker, presented to neurosurgery department with complaint of dizziness, seizures and loss of consciousness since 20 days. He was afebrile, non hypertensive and non diabetic. His hematological, serological and biochemical investigations were found normal, except for raised SGPT (ALT) enzyme (62 IU/L). Thereby, further investigations were performed.

IMAGING

Magnetic Resonance Imaging was done, which showed morphological left ventricle (LV) on right side and small in caliber; morphological right ventricle (RV) on left side with myocardial hypertrophy; aorta rising from RV and mildly dilated pulmonary artery rising from LV suggestive of pulmonary arterial hypertension. Findings of MRI were of concern for echocardiography.

2D-Echocardiography established the presence of congenitally corrected transposition of great arteries (CCTGA). Findings of echocardiography correlated with MRI.

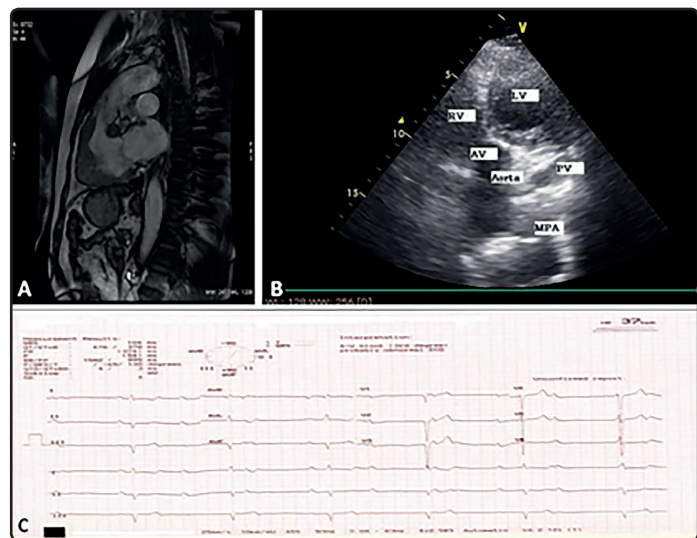
Moreover, grade -1 left ventricular diastolic dysfunction, mild pulmonary regurgitation, mild tricuspid regurgitation, mild mitral regurgitation and bradycardia were noted during echocardiography. Ejection fraction was 64 %.

Electrocardiography depicted third degree atrioventricular block (AV block) and heart rate of 37 beats per minute.

Figure A – Shows cardio thoracic MRI

Figure B – Demonstrates echocardiography image with transposed ventricles

Figure C – Depicts ECG interpreting AV block and bradycardia



INDICATION FOR INTERVENTION

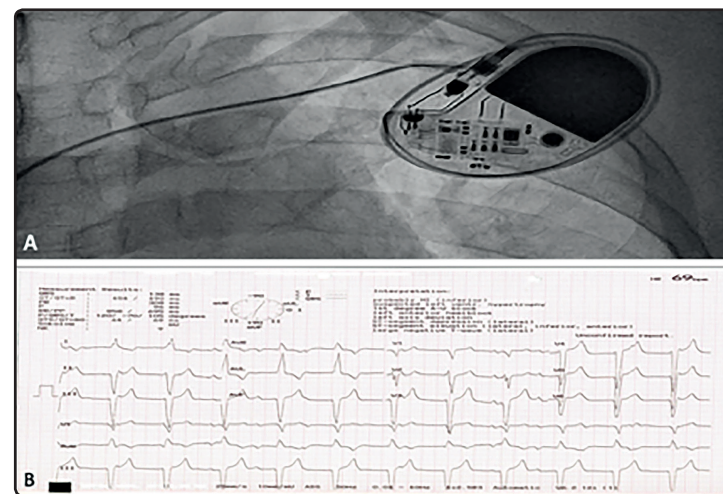
Congenitally corrected transposition of great arteries (CCTGA) with third degree AV block, right ventricular hypertrophy and bradycardia indicated implantation of permanent pacemaker into the patient.

INTERVENTION

Permanent pacemaker implantation – VVI mode was done from left subclavian approach under local anesthesia. Extra thoracic subclavian vein puncture was done. A 58–1888 screw-in lead was placed in the left ventricular apex. A pulse generator was connected. Lead parameters were acceptable. The incision was closed in layers after checking the lead position. Procedure was uneventful and well tolerated by patient.

Figure A – Image of implanted permanent pacemaker

Figure B – Post-implantation ECG



LEARNING POINTS OF THE PROCEDURE

This was a rare case presentation as the patient remained asymptomatic for a long time (42 years) though with CCTGA and moreover it was an accidental diagnosis of CCTGA accompanied with AV block. The placement of pacemaker reverted normal heart rate and post-implantation ECG depicted first degree AV block.

We placed a screw-in lead as the anatomical right ventricle is left ventricle and the cavity is smooth. In most cases inferior vena cava interruption occurs, so we need to prepare for hemiazygos route.

COMPARISON OF DEVICE SELECTION FOR LEFT ATRIAL APPENDAGE OCCLUSION USING THREE-DIMENSIONAL PRINTING AND CONVENTIONAL MULTI-SLICE COMPUTED TOMOGRAPHY

Rodney De Palma¹ / Claudio Capelli² / Bo Sahgren¹ / Magnus Settergren¹

¹ Karolinska Institute and University Hospital, Stockholm, Sweden

² University College London & Great Ormond Street Hospital, London, UK

PURPOSE

Comparison of device selection for left atrial appendage occlusion using three-dimensional printing and conventional multi-slice computed tomography.

METHODS

Retrospective analysis using three-dimensional (3D) printed models and pre-procedure multi-slice computed tomographic (CT) scans from ten consecutive patients who underwent left atrial appendage occlusion (LAAO) with the St Jude AMPLATZER™ AMULET™ device (Minnesota, USA). 3D models of left and right atria of each patient were reconstructed by post-processing CT images. The models were then manufactured using a flexible, rubber-like, translucent material (TangoPlus FLX930).

Two operators trained in LAAO, blind to the actual final device selected, took measurements from the CT and used visual and tactile feedback following test insertion of devices within the 3D models to predict the correct size of device required. Bland-Altman analyses were performed to evaluate the difference in device choices between both methods and between each method and the actual final device selected.

RESULTS

The bias between 3D-guided and actual device choice was +2.4 mm (limits of agreement -2.0 to 7.0); for CT +0.68 mm (limits of agreement -7.0 to 8.4); and between 3D and CT was -1.7 mm (limits of agreement -11.8 to 8.2). There was consistent variation of size selection compared to the sizes actually implanted. However, there was more inter-operator variation in sizes selected using CT guidance than with the 3D models (-2.7 vs -2.1).

CONCLUSIONS

In this preliminary study 3D printed models of patient-specific left atria leads to LAAO device size selection, using the AMULET™, one size greater than when guided by CT.

OPTICAL COHERENCE TOMOGRAPHY IN CHILDREN OFFERS NEW IMAGING POSSIBILITIES: 2 CASES OF HEART TRANSPLANT RECIPIENTS

Robert Dalla Pozza / Sarah Ulrich / Anja Lehner / Beatrice Heineking / Julinda Mehilli / Nikolaus A Haas

Ludwig-Maximilians-University of Munich, Munich, Germany

BACKGROUND

Optical Coherence Tomography (OCT) allows for high-resolution intracoronary visualization of intimal hyperplasia, coronary vasculopathy and plaque formation. Thus, in heart transplant recipients, cardiac allograft vasculopathy (CAV) may be detected at an early stage.

OBJECTIVE

We present two patients in whom coronary angiography revealed similar findings with diffuse narrowing of the left anterior descending (LAD). However, OCT revealed different anatomic results leading to different medical management.

METHODS

Comparison of two transplanted patients with similar angiographic, but different OCT results. Pt. 1 presented 21 y after neonatal heart transplantation (HTX) for hypoplastic left heart syndrome (HLHS) in good clinical condition without signs of ischemia during stress testing. Pt. 2 presented 17 y after neonatal HTX for dilated cardiomyopathy, also in good clinical condition with negative stress testing.

RESULTS

Pt. 1 showed diffuse narrowing of the LAD in angiography. OCT-result: intimal hyperplasia to 0.5 mm = CAV grade 3 according to the Stanford classification, 1 small plaque (pictures will be provided). Pt. 2 showed similar findings in angiography, but only mild intimal hyperplasia in OCT: 0.2 mm = CAV grade 1–2 Stanford class pictures will be given). In Pt. 1, according to the finding of the OCT, aggressive medical treatment of atherogenic risk factors was initiated together with the introduction of Everolimus to delay the progression of CAV over time. In Pt. 2, a less aggressive approach was chosen including optimization of atherogenic risk factors.

CONCLUSION

Introducing OCT in the follow up of heart transplant recipients allows for differentiation between coronary stenosis or narrowing due to vessel hypoplasia, and intimal hyperplasia or plaque formation secondary to CAV. This advantage is even more appreciated as CAV represents one of the most important risk factors for graft survival in the long term follow up after HTX. Lacking specific therapeutic strategies for the primary prevention of CAV, at least early diagnosis should be the aim. After that, rigorous treatment of atherogenic risk factors is recommended. Also, some authors report on a positive effect of changing immunosuppression to calcineurin-inhibitor-free medication (i.e. Everolimus). Finally, also follow up visits may be scheduled differently in Pts. with and without CAV.

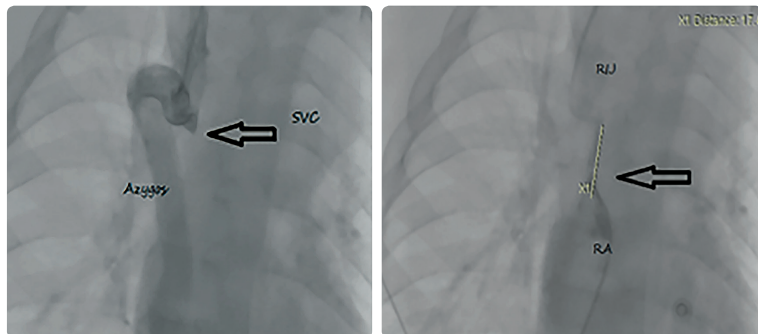
STENTING OF TOTALLY OCCLUDED SVC

Sherien Abdelsalam Mohamed / Hassan Mohamed Kamel
Magdi Yacoub Hospital, Aswan, Egypt

BACKGROUND

A 5-year-old boy was presented with: SVC obstruction syndrome with dilated veins on chest wall. The patient had a history of ventriculoperitoneal shunt at the age of 1 m old which included central line in the right jugular vein. The symptoms of the SVC obstruction were of 3 years duration. CT was done pre-procedure and showed total occluded SVC for 2 cm distance with dilated azygos vein and multiple collaterals.

Figure 1a and 1b:



OBJECTIVE

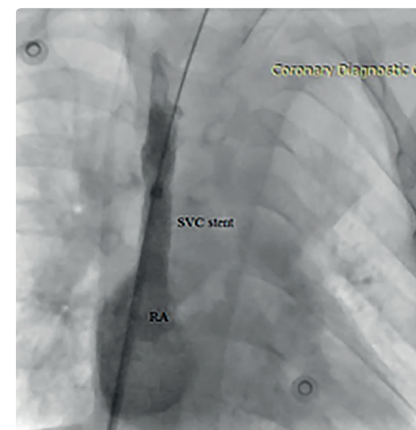
SVC DILATATION AND STENTING

METHODS

The procedure was done under general anaesthesia. Vascular access: 6F right femoral vein, 6F right internal jugular vein. Angiography in the RT internal jugular vein showed totally occluded SVC and no connection with the RA. Angiography from the RA showed that there was no connection between the RA and the SVC about 17 mm length. Using a 4 MP and a 0.014F PT 2 MS wire the obstruction was probed till a track was found. Wire was passed till LT subclavian vein where it was snared from the LT subclavian to the innominate vein to the RT internal jugular. Multiple pre-dilatations using 1.5×20mm balloons were done, then 3×20mm. The 6Fr RFV was exchanged for a 7Fr long sheath. A pre-mounted stent (GENESIS 29×8) was introduced to the stenotic area and position was confirmed by angiography.

Stent was deployed successfully. Continuation between SVC and RA was established with no pressure difference.

Figure 2: Stent in the SVC



RESULTS

Successful stenting of a totally occluded SVC is a feasible but difficult procedure.

CONCLUSION

- Good planning of the procedure with the imaging team can be helpful.
- Patience in such a difficult procedure can give a chance of good change in the patient life.

THROMBUS IN THE AORTA – A LATE COMPLICATION OF PERCUTANEOUS CLOSURE OF A RUPTURED ANEURYSM OF THE SINUS OF VALSALVA

Robert Sabiniewicz / Jaroslaw Meyer-Szary / Magdalena Kolaczowska / Piotr Siondalski / Lidia Wozniak / Rafal Galaska
Medical University of Gdansk, Gdansk, Poland

HISTORY AND PHYSICAL

A 35-year-old woman with no prior medical record presented with a history of progressive fatigue for the preceding 6 months. Diagnostic echocardiography revealed an aneurysm of the noncoronary sinus of Valsalva, 7mm in diameter, ruptured into the right atrium, with hemodynamic significance (Figure 1A). Percutaneous closure of the aneurysm was performed uneventfully, using the femoral access and the self-expandable Amplatzer Duct Occluder ADO 9-PDA-004 device (Figure 1B). Echocardiographic follow up at 1, 3, 6 and 12 months confirmed the correct position of the implant, without any residual shunt or thrombosis. Nearly 2 years later, the patient underwent popliteal endarterectomy due to an acute thromboembolic event.

IMAGING AND INDICATION FOR INTERVENTION

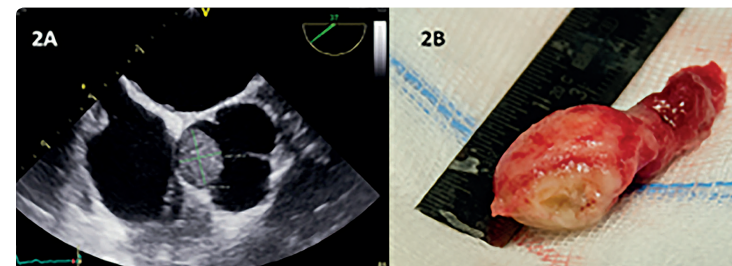
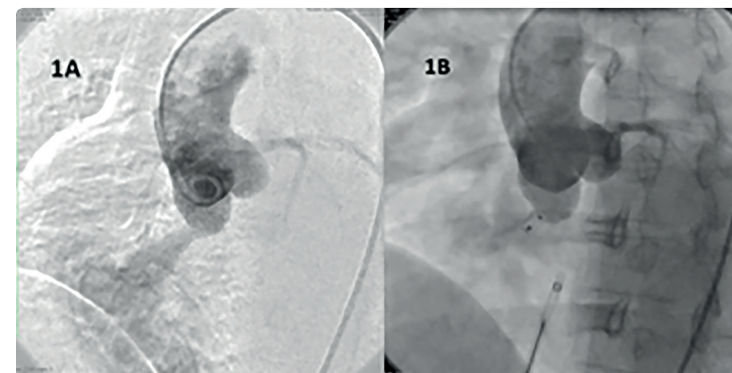
Subsequently the patient was referred to cardiologist. Echocardiography revealed a massive thrombus (13×16×37mm), originating from the noncoronary sinus of Valsalva (Figure 2A).

INTERVENTION

The thrombus and the device were surgically extracted, and the noncoronary sinus of Valsalva was reconstructed uneventfully, with no residual shunt or aortic valve dysfunction (Figure 2B). Pathological evaluation of the extracted specimen revealed appropriate endothelialization of the device on the right-atrial side, and a thrombus with a well-organized fibrous nucleus originating from the aortic disc of the implant.

LEARNING POINTS OF THE PROCEDURE

This is the case of a very late thrombus formation on the Amplatzer Duct Occluder implanted in an atypical position – the ruptured sinus of Valsalva.



PERCUTANEOUS TRANSLUMINAL ANGIOPLASTY OF TOTALLY OCCLUDED LEFT INNOMINATE VEIN PERCEIVED DURING PACEMAKER LEAD INSERTION – A NEEDLE IN THE HAYSTACK

Raghava Sarma Polavarapu / Sravanthi Byrapaneni / Anurag Polavarapu / Naren Polavarapu / Vijaya Pamidimukkala
Lalitha Super Speciality Hospital, Guntur, India

HISTORY AND PHYSICAL

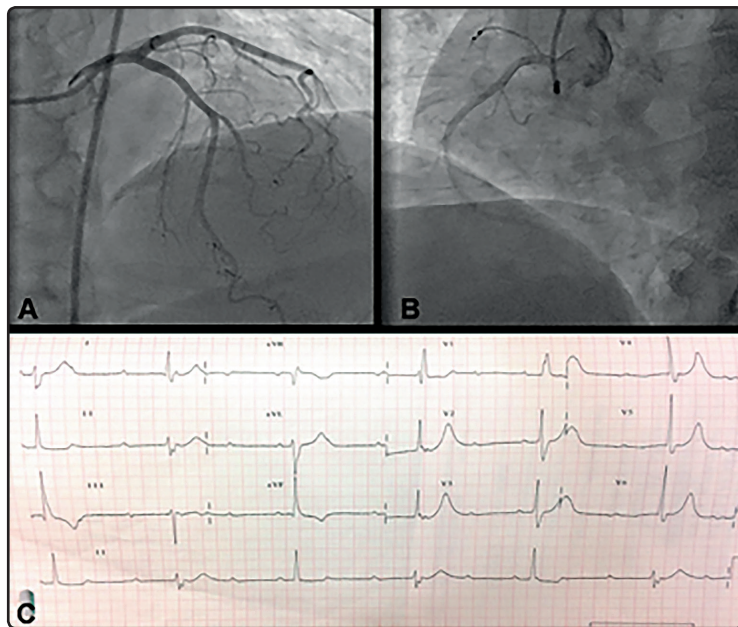
A 62-year-old male presented to us with recurrent syncopal attacks. He was non hypertensive, non diabetic, non smoker, and did not have previous history of any major illness. He was referred for further investigation.

IMAGING

Angiography demonstrated normal coronary arteries. Electrocardiography depicted third degree heart block. Echocardiography established normal left ventricular functioning.

Figure A & B – demonstrate normal coronary arteries' angiogram

Figure C – shows ECG showing complete heart block



INDICATION FOR INTERVENTION

With regards to presence of complete heart block, the patient was posted for permanent pacemaker implantation through left subclavian approach. After puncturing the left subclavian vein, it was noticed that the guidewire was not able to pass through it. Therefore, a check venography was performed. It showed total occlusion

of left innominate vein, reforming through collaterals. Percutaneous transluminal angioplasty of left innominate vein was performed to facilitate pacing lead passage.

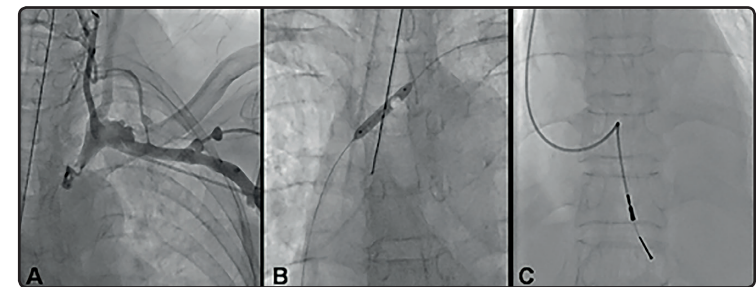
INTERVENTION

Percutaneous transluminal angioplasty to innominate vein was done using standard procedure with 4×24mm semi compliant balloon which resulted in partial recanalisation of the vein. Subsequently, lead insertion and permanent pacemaker implantation – VVI mode was done as per standard protocol. Procedure was uneventful and well tolerated by patient.

Figure A – Image of totally occluded left innominate vein

Figure B – Image showing balloon angioplasty to left innominate artery

Figure C – Image of successful insertion of pacemaker lead into the ventricle



LEARNING POINTS OF THE PROCEDURE

Subclavian or innominate vein occlusion can occur secondary to previous pacemaker lead insertions or mediastinal fibrosis. Occlusion of these veins without any previous underlying cause have never been reported before. When this is encountered balloon angioplasty can be performed safely to pass the lead and there is no need to shift to the opposite side for implanting pacemaker.

IMAGING OF INTIMA-MEDIA-STRUCTURE OF THE CAROTID ARTERY IN CHILDHOOD: NORMATIVE DATA FROM A COHORT OF 631 CHILDREN

Robert Dalla Pozza¹ / Sarah Ulrich¹ / Raphael Pirzer¹ / Heidi Weber² / Renate Oberhoffer² / Heinrich Netz¹ / Nikolaus A Haas¹

¹ Ludwig-Maximilians-University of Munich, Munich, Germany

² Institute for Preventive Pediatrics, Technical University of Munich, Munich, Germany

BACKGROUND

Carotid artery intima media thickness (IMT) measurements and their interpretation in the pediatric age group represent a special challenge. On the other hand, this surrogate marker for atherosclerosis deserves special attention in counselling patients at risk for vascular complications as early as possible. Previously calculated reference values differed between studies. So, in the light of different reference data from different ultrasound systems and algorithms we are missing robust and easily applicable preventive parameters.

OBJECTIVE

Calculation of normative data for comparison of age- and sex-specific values in a healthy cohort of school children.

METHODS

We calculated "average" IMT from sonographic studies of the carotid artery in 709 school children from 8–18 y. The algorithm included both end diastolic and end systolic IMT during a minimum of 3 heart cycles eliminating errors of manual tracing or indefinite measurement points. Moreover, IMT-"roughness" as a function of difference from the mean and as a surrogate for IMT irregularity was calculated as well. From these parameters, we calculated age- and sex-specific percentiles using the LMS-method.

RESULTS

After eliminating studies from obese and hypertensive children, a total of 631 subjects were included (s. Table).

AGE (YEARS)		1 (8.0–10.9)	2 (11.0–13.9)	3 (14.0–17.9)
n	w	111	134	59
	m	124	177	26
IMT	w	0.48 ± 0.04	0.49 ± 0.03	0.50 ± 0.04
	(mm)	0.49 ± 0.03	0.49 ± 0.03	0.49 ± 0.04
IMR	w	0.037 ± 0.012	0.035 ± 0.010	0.036 ± 0.010
	(mm)	0.035 ± 0.011	0.033 ± 0.010	0.038 ± 0.011

CONCLUSION

Given the differences of actual IMT-normative values, we propose a more sophisticated calculation of IMT including diameters at end systole and end diastole. As these diameters are detected with an automated contour edge detection system and calculated from several measurements at different time points, they may represent more comparable surrogate markers for the "real" intima media thickness of the carotid artery. IMT-"roughness" may add valuable informations about the structure of the inner layer of the endothelium. Also, by using z-scores of both average-IMT and IMT-roughness, measurement results from different ultrasound systems and from different IMT measurement algorithms should be comparable throughout different studies.