

# Resolution of Migraine After Transcatheter Closure of Atrial Communication

## Migraine and Atrial Communication Closure

Yoichi Takaya, MD<sup>1</sup>, Teiji Akagi, MD<sup>2\*</sup>, Yasufumi Kijima, MD<sup>1</sup>, Koji Nakagawa, MD<sup>1</sup>, Syoichiro Kono, MD<sup>3</sup>, Kentaro Deguchi, MD<sup>3</sup>, Shunji Sano, MD<sup>4</sup>, Hiroshi Ito, MD<sup>1</sup>

<sup>1</sup> Department of Cardiovascular Medicine, Okayama University Graduate School of Medicine, Dentistry, and Pharmaceutical Science, Okayama, Japan

<sup>2</sup> Cardiac Intensive Care Unit, Okayama University Graduate School of Medicine, Dentistry, and Pharmaceutical Science, Okayama, Japan

<sup>3</sup> Department of Neurology, Okayama University Graduate School of Medicine, Dentistry, and Pharmaceutical Science, Okayama, Japan

<sup>4</sup> Department of Cardiovascular Surgery, Okayama University Graduate School of Medicine, Dentistry, and Pharmaceutical Science, Okayama, Japan

### Abstract

**Background:** Limited information is available regarding migraine in patients with atrial septal defect (ASD), and the clinical effects of transcatheter closure are controversial. We aimed to demonstrate the clinical features of migraine in patients with ASD compared with those in patients with patent foramen ovale (PFO) and evaluate the impact of transcatheter closure.

**Methods:** We investigated the prevalence of migraine in 68 patients with ASD and 27 patients with PFO who underwent transcatheter closure. Migraine prevalence, frequency, and severity were evaluated before and after the procedure.

**Results:** Twenty patients (29%) with ASD and 15 patients (56%) with PFO suffered from migraine. Characteristics such as migraine frequency and severity and incidence of aura were not different between the ASD and PFO patients. Among the 20 ASD patients, migraine disappeared in 10 (50%) and improved in 7 (35%) patients after a mean follow-up of 20 ± 8 months. Among the 15 PFO patients, migraine disappeared in 11 (73%) and improved in 3 (20%) patients.

**Conclusions:** Approximately 30% of patients with ASD experience migraine. The improvement in migraine

after transcatheter closure is observed in the majority of those with ASD, similar to the rate of patients with PFO with improvement. These findings suggest that transcatheter closure may be beneficial for migraine in patients with atrial communication.

Copyright © 2016 Science International Corp.

### Key Words

Atrial septal defect • Migraine • Patent foramen ovale • Transcatheter closure

### Introduction

Migraine is a common, recurrent, and potentially disabling headache. The prevalence of migraine in the overall population is 10–12%, 6% in males and 15–18% in females [1]. Although the pathophysiology of migraine is not fully understood, a causal relationship between migraine and right-to-left communication has been proposed. In particular, patent foramen ovale (PFO) has been associated with an increase in the prevalence of migraine [2-4]. Transcatheter PFO



closure seems to be associated with the improvements in migraine prevalence and severity [2, 3, 5-7].

Atrial septal defect (ASD) is characterized by a predominant left-to-right communication, but the occurrence of right-to-left communication is detected during a Valsalva maneuver or exercise [8]. Therefore, some patients with ASD may suffer from migraine, and transcatheter closure may contribute to migraine improvement. However, limited information is available regarding migraine in patients with ASD [9-11]. This study aimed to evaluate the prevalence of migraine and the effect of transcatheter closure on migraine in patients with ASD, compared with those in patients with PFO.

## Methods

### Study Population

We investigated 68 consecutive patients with ASD who underwent transcatheter closure between December 2012 and November 2014; specifically, we assessed the prevalence rates of migraine before and after the procedure. Twenty-seven consecutive patients with PFO who underwent transcatheter closure for the secondary prevention of cerebral ischemia between March 2007 and November 2014 were also included. Transcatheter ASD closure was performed for a significant left-to-right communication and/or clinical symptoms of heart failure or cerebral ischemia. All patients gave written informed consent for the procedure. The study was approved by our institution's ethical committee.

### Echocardiographic Assessment

Atrial communication was diagnosed by transesophageal echocardiography. For PFO detection, agitated saline contrast injection (aerated saline solution) was administered via the antecubital vein with and without the Valsalva maneuver. PFO was defined as a flap-like opening in the atrial septum secundum, with the septum primum serving as a one-way valve allowing for permanent or transient right-to-left communication. PFO diameter was obtained by measuring the maximum opening of the PFO in the end-diastolic frames. Atrial septal aneurysm was defined as an aneurysm with a base diameter  $\geq 15$  mm and an excursion of the septum  $\geq 10$  mm [12].

### Transcatheter Closure of Atrial Communication

Transcatheter closure of atrial communication was performed as described previously under the guidance of transesophageal echocardiography and/or intracardiac echocardiography [13, 14]. The Amplatzer Septal Occluder, Amplatzer Cribriform, and Amplatzer PFO Occluder (St. Jude Medical, St. Paul, MN, USA) were used. All patients received

100 mg/day aspirin 48 h before the procedure, which was continued for 6 months after the procedure. Clopidogrel was administered at a dose of 75 mg/day for 1 month after the procedure.

### Migraine Evaluation

Migraine was diagnosed by independent neurologists according to the criteria of the International Headache Society [15]. Migraine prevalence, frequency, severity, and medications were evaluated at baseline, 3 months, and  $>6$  months after the procedure. Severity was estimated according to three-grade scale: none-mild (not interfering with usual activity), moderate (interfering with usual activity), or severe (confined to bed). Follow-up comprised a combined cardiologic and neurologic visit or a telephone interview. Postprocedural changes in migraine were classified into four groups according to migraine frequency and severity of migraines: disappeared (complete disappearance), improved ( $\geq 50\%$  decrease in frequency and  $\geq 1$ -grade decrease in severity), no change ( $<50\%$  change in frequency or no change in severity), or worsening ( $\geq 50\%$  increase in frequency and  $\geq 1$ -grade increase in severity).

### Statistical Analysis

Data are presented as mean  $\pm$  standard deviation for continuous variables and as number and percentage for categorical variables. Significant differences between two groups were analyzed using the *t* test or Mann-Whitney *U* test for continuous variables and the  $\chi^2$  test for categorical variables. Differences between baseline and follow-up in each group were analyzed by the paired *t* test and Wilcoxon signed-rank test. Statistical analysis was performed with JMP version 8.0 (SAS Institute Inc., Cary, NC, USA), and significance was defined as  $p < 0.05$ .

## Results

### Characteristics

Characteristics in patients with ASD and PFO are shown in Table 1. Patients with ASD were older than those with PFO. The frequency of atrial septal aneurysm was higher in patients with PFO than those with ASD. There were no significant differences in comorbidities between the two groups except for cerebral ischemia. Transcatheter closure of ASD or PFO was successfully performed in all patients without procedural complications. Among the patients with ASD, the Amplatzer Septal Occluder was used in 66 patients and the Amplatzer Cribriform in 2 patients. Among the patients with PFO, the Amplatzer PFO Occluder,

Cribriform, and Septal Occluder were used in 10, 5, and 12 patients, respectively.

### Migraine Prevalence

Twenty (29%) of 68 patients with ASD suffered from migraine, including 12 patients with migraine with aura. Fifteen (56%) of 27 patients with PFO suffered from migraine, including 8 patients with migraine with aura. The prevalence of migraine was lower in

patients with ASD than in those with PFO (Table 1). Migraine characteristics such as the frequency, severity, incidence of aura, and the need for medications were not different between the 20 patients with ASD and the 15 patients with PFO (Table 2).

### Short-Term Effect of Transcatheter Closure on Migraine

Among the 20 patients with ASD, migraine had disappeared in 10 (50%) patients and improved in 8 (40%) patients 3 months after the procedure. Among the 15 patients with PFO, migraine disappeared in 9 (60%) patients and improved in 5 (33%) patients (Figure 1).

### Mid-Term Effect of Transcatheter Closure on Migraine

Among the 20 patients with ASD, migraine disappeared in 9 (45%) patients and improved in 7 (35%) patients at a mean follow-up of  $20 \pm 8$  months after the procedure. Among the 15 patients with PFO, migraine disappeared in 11 (73%) patients and improved in 3 (20%) patients at a mean follow-up of  $44 \pm 29$  months (Figure 2). No patients with ASD or PFO experienced worsening of migraine after the procedure. New-onset migraine was not observed in patients without migraine.

The frequency of migraine decreased significantly at the last follow-up in patients with ASD ( $2.8 \pm 3.3$  to  $0.6 \pm 0.8$  times/month,  $p = 0.008$ ) and

**Table 1:** Characteristics in patients with ASD and PSO

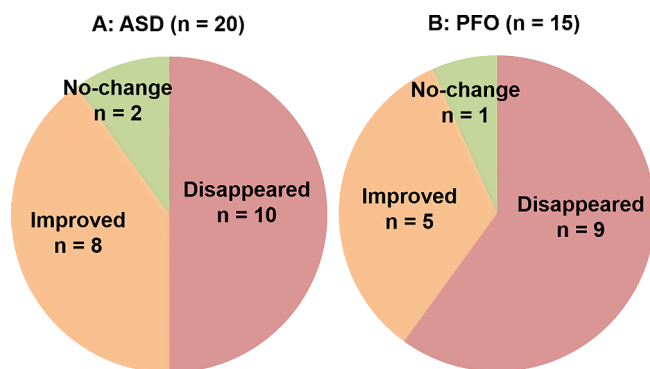
	ASD (n = 68)	PFO (n = 27)	p
Age at procedure, years	51 ± 19	43 ± 12	0.034
Female	41 (60%)	15 (56%)	0.676
Hypertension	16 (24%)	6 (22%)	0.893
Dyslipidemia	16 (24%)	3 (11%)	0.176
Diabetes mellitus	6 (9%)	1 (4%)	0.394
Smoking	6 (9%)	1 (4%)	0.394
Cerebral ischemia	11 (16%)	27 (100%)	<0.001
Defect diameter, mm	18 ± 8	3 ± 2	<0.001
Atrial septal aneurysm	11 (16%)	10 (37%)	0.027
Eustachian valve	7 (10%)	5 (19%)	0.281
Migraine	20 (29%)	15 (56%)	0.017

Data are presented as mean ± standard deviation or n (%).  
ASD = atrial septal defect; PFO = patent foramen ovale.

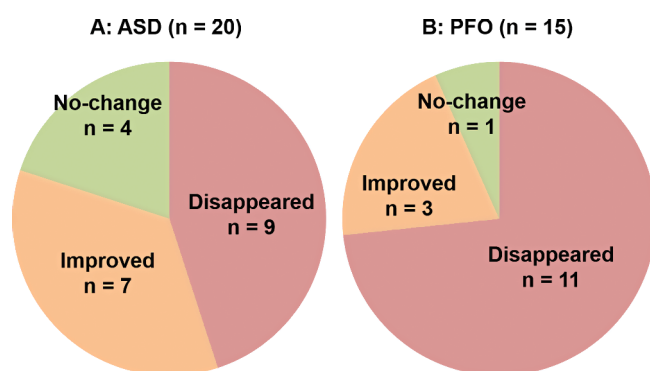
**Table 2:** Migraine in patients with ASD and PFO

	ASD with Migraine (n = 20)	PFO with Migraine (n = 15)	p
Age at migraine onset, years	23 ± 12	24 ± 11	0.786
Frequency of migraine, times/month	2.8 ± 3.3	4.1 ± 4.7	0.324
Severity of migraine			
None-mild (not interfering with usual activity)	8 (40%)	3 (20%)	0.219
Moderate (interfering with usual activity)	10 (50%)	9 (60%)	0.570
Severe (confined to bed)	2 (10%)	3 (20%)	0.418
Incidence of aura	12 (60%)	8 (53%)	0.704
Migraine medications	12 (60%)	8 (53%)	0.704

Data are presented as mean ± standard deviation or n (%).  
ASD = atrial septal defect; PFO = patent foramen ovale.



**Figure 1.** Short-term effect of transcatheter closure on migraine in patients with ASD (Panel A) and PFO (Panel B). ASD = atrial septal defect; PFO = patent foramen ovale.



**Figure 2.** Mid-term effect of transcatheter closure on migraine in patients with ASD (Panel A) and PFO (Panel B). ASD = atrial septal defect; PFO = patent foramen ovale.

those with PFO ( $4.1 \pm 4.7$  to  $0.2 \pm 0.6$  times/month,  $p = 0.004$ ) (Figure 3). Migraine severity decreased at last follow-up in 11 (92%) of 12 patients with ASD and 11 (92%) of 12 patients with PFO who had moderate or severe migraine at baseline (Figure 4). Among those who used medications for migraine at baseline, they were not required in 8 (67%) of the 12 patients with ASD and 7 (88%) of the 8 patients with PFO.

## Discussion

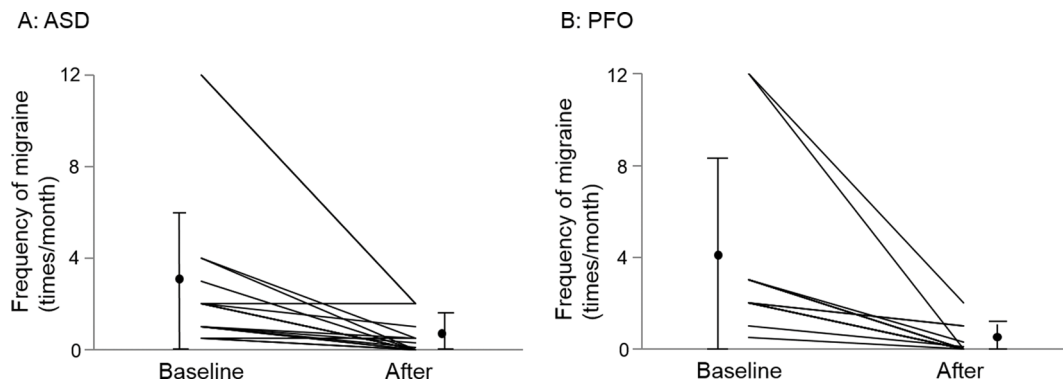
The major findings of the present study are as follows: 1) the prevalence of migraine was lower in patients with ASD than those with PFO but still affected approximately 30% of ASD patients; 2) migraine characteristics were similar in the ASD

and PFO groups; and 3) improvement in migraine after transcatheter closure was observed in the majority of patients with ASD, similar to those with PFO.

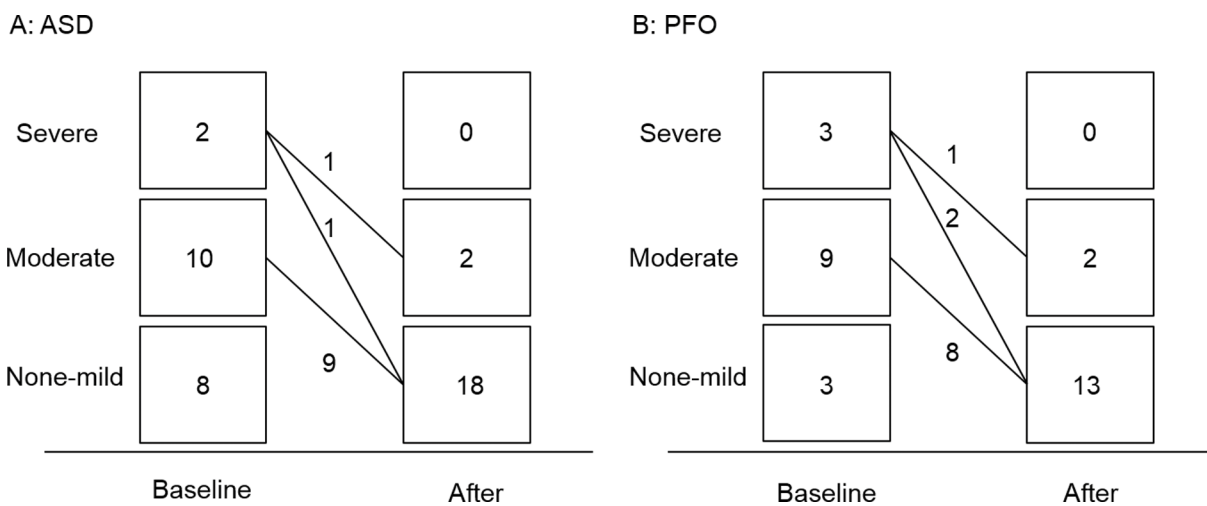
Although the pathophysiology of migraine is unclear, the presence of PFO is thought to be a potent trigger of migraine. Normally, trigger substances in the venous circulation will be filtered in the lungs. However, PFO may allow vasoactive chemicals or microemboli to bypass the lungs through right-to-left communication and reach the cerebral circulation, leading to migraine [16, 17]. This hypothesis is enforced by improvements in migraine prevalence and severity after PFO closure [2, 3, 5-7]. In contrast with PFO, ASD is mainly characterized by a left-to-right communication. However, during a Valsalva maneuver or exercise, a right-to-left communication can be detected with contrast echocardiography in patients with ASD [8]. Because this communication permits bypass of the lung filter, ASD may be also associated with migraine; however, little is known about migraine in this population [9-11, 18].

In the present study, the prevalence of migraine was lower in patients with ASD compared to those with PFO, but approximately 30% experienced migraine. This improved after transcatheter closure in 16 (80%) of the 20 patients with ASD, including 9 patients with complete disappearance. The benefit of transcatheter closure on migraine was similar in patients with ASD and PFO. Our findings suggest that ASD is associated with migraine and that transcatheter closure may be beneficial for migraine in patients with atrial communication.

There are some limitations in the present study. First, we included a small number of patients, and the follow-up period was short. Larger trials are required to confirm our findings. Second, we did not include a control group. Migraine is known to have a placebo response rate of 20–30%. However, the improvement rate of migraine in the present study was higher than the accepted placebo response rate [19]. Third, antiplatelet therapy might modify migraine prevalence, frequency, and severity [20]. However, aspirin was administered for 6 months and clopidogrel for 1 month. The improvement in migraine was eval-



**Figure 3.** Changes in migraine frequency after transcatheter closure in patients with ASD (Panel A) and PFO (Panel B).  $p = 0.008$  and  $0.004$ , respectively. ASD = atrial septal defect; PFO = patent foramen ovale.



**Figure 4.** Changes in migraine severity after transcatheter closure in patients with ASD (Panel A) and PFO (Panel B). ASD = atrial septal defect; PFO = patent foramen ovale.

uated when these medications were not given. Fourth, the timing of transcatheter closure and the follow-up period differed between the ASD and PFO group. Finally, there was a selection bias as we only included patients who underwent transcatheter closure.

**Conclusions**

Approximately 30% of patients with ASD experience migraine, the characteristics of which are similar in ASD and PFO. An improvement in headache after transcatheter closure was observed in the majority of patients with ASD, similar to those with PFO. These findings suggest that PFO and ASD are both associ-

ated with migraine, and transcatheter closure may be beneficial for migraine in patients with atrial communication.

**Conflict of Interest**

Dr. Akagi is a consultant for St. Jude Medical, Inc. The other authors have no conflict of interest relevant to this publication.

[Comment on this Article or Ask a Question](#)

## References

1. Stewart WF, Shechter A, Rasmussen BK. Migraine prevalence. A review of population-based studies. *Neurology*. 1994;44:S17-S23. PMID: 8008222
2. Post MC, Thijs V, Herroelen L, Budts W. Closure of a patent foramen ovale is associated with a decrease in prevalence of migraine. *Neurology*. 2004;62:1439-1440. DOI: 10.1212/01.WNL.0000120756.25236.37
3. Reisman M, Christofferson RD, Jesurum J, Olsen JV, Spencer MP, Krabill KA, et al. Migraine headache relief after transcatheter closure of patent ovale. *J Am Coll Cardiol*. 2005;45:493-495. DOI: 10.1016/j.jacc.2004.10.055
4. Schwedt TJ, Demaerschalk BM, Dodick DW. Patent foramen ovale and migraine: a quantitative systematic review. *Cephalalgia*. 2008;28:531-540. DOI: 10.1111/j.1468-2982.2008.01554.x
5. Wilmshurst PT, Nightingale S, Walsh KP, Morrison WL. Effect on migraine of closure of cardiac right-to-left shunts to prevent recurrence of decompression illness or stroke or for haemodynamic reasons. *Lancet*. 2000;356:1648-1651. DOI: 10.1016/S0140-6736(00)03160-3
6. Trabattoni D, Fabbiochi F, Montorsi P, Galli S, Teruzzi G, Grancini L, et al. Sustained long-term benefit of patent foramen ovale closure on migraine. *Catheter Cardiovasc Interv*. 2011;77:570-574. DOI: 10.1002/ccd.22826
7. Rigatelli G, Dell'Avvocata F, Ronco F, Cardaioli P, Giordan M, Braggion G, et al. Primary transcatheter patent foramen ovale closure is effective in improving migraine in patients with high-risk anatomic and functional characteristics for paradoxical embolism. *JACC Cardiovasc Interv*. 2010;3:282-287. DOI: 10.1016/j.jcin.2009.11.019
8. Kai H, Koyanagi S, Hirooka Y, Sugimachi M, Sadoshima J, Suzuki S, et al. Right-to-left shunt across atrial septal defect related to tricuspid regurgitation: Assessment by transesophageal Doppler echocardiography. *Am Heart J*. 1994;127:578-584. DOI: 10.1016/0002-8703(94)90666-1
9. Mortelmans K, Post M, Thijs V, Herroelen L, Budts W. The influence of percutaneous atrial septal defect closure on the occurrence of migraine. *Eur Heart J*. 2005;26:1533-1537. DOI: 10.1093/eurheartj/ehi170
10. Luermans JG, Post MC, Temmerman F, Thijs V, Schonewille WJ, Plokker HW, et al. Is a predominant left-to-right shunt associated with migraine? A prospective atrial septal defect closure study. *Catheter Cardiovasc Interv*. 2009;74:1078-1084. DOI: 10.1002/ccd.22226
11. Azarbal B, Tobis J, Suh W, Chan V, Dao C, Gaster R. Association of interatrial shunts and migraine headaches: impact of transcatheter closure. *J Am Coll Cardiol*. 2005;45:489-492. DOI: 10.1016/j.jacc.2004.09.075
12. Mügge A, Daniel WG, Angermann C, Spes C, Khandheria BK, Kronzon I, et al. Atrial septal aneurysm in adult patients. A multicenter study using transthoracic and transesophageal echocardiography. *Circulation*. 1995;91:2785-2792. DOI: 10.1161/01.CIR.91.11.2785
13. Thanopoulos BD, Laskari CV, Tsaousis GS, Zarayelyan A, Vekiou A, Papadopoulos GS. Closure of atrial septal defects with the Amplatzer occlusion device: preliminary results. *J Am Coll Cardiol*. 1998;31:1110-1116. DOI: 10.1016/S0735-1097(98)00039-4
14. Kijima Y, Akagi T, Nakagawa K, Taniguchi M, Ueoka A, Deguchi K, et al. Catheter closure of patent foramen ovale in patients with cryptogenic cerebrovascular accidents: initial experiences in Japan. *Cardiovasc Interv Ther*. 2014;29:11-17. DOI: 10.1007/s12928-013-0193-9
15. Headache Classification Subcommittee of the International Headache Society. The International Classification of Headache Disorders: 2nd edition. *Cephalalgia*. 2004;24:9-160. PMID: 14979299
16. Wilmshurst P, Nightingale S. Relationship between migraine and cardiac and pulmonary right-to-left shunts. *Clin Sci (Lond)*. 2001;100:215-220. DOI: 10.1042/cs1000215
17. Kurth T, Tzourio C, Bousser MG. Migraine: a matter of the heart? *Circulation*. 2008;118:1405-1407. DOI: 10.1161/CIRCULATIONAHA.108.807198
18. Truong T, Slavov L, Kashani R, Higgins J, Puri A, Chowdhry M, et al. Prevalence of migraine headaches in patients with congenital heart disease. *Am J Cardiol*. 2008;101:396-400. DOI: 10.1016/j.amjcard.2007.08.047
19. van der Kuy PH, Lohman JJ. A quantification of the placebo response in migraine prophylaxis. *Cephalalgia*. 2002;22:265-270. DOI: 10.1046/j.1468-2982.2002.00363.x
20. Wilmshurst PT, Nightingale S, Walsh KP, Morrison WL. Clopidogrel reduces migraine with aura after transcatheter closure of persistent foramen ovale and atrial septal defects. *Heart*. 2005;91:1173-1175. DOI: 10.1136/hrt.2004.047746

**Cite this article as:** Takaya Y, Akagi T, Kijima Y, Nakagawa K, Kono S, Deguchi K, Sano S, Ito H. Resolution of Migraine After Transcatheter Closure of Atrial Communication. *Structural Heart Disease*. 2016;2(4):102-107. DOI: <http://dx.doi.org/10.12945/j.jshd.2016.010.15>