

Worsening of Functional Mitral Regurgitation from Septal Dyssynchrony Induced by Ventricular Pacing in Ebstein's Anomaly Undergoing Percutaneous Mitral Valve Repair

Heajung L. Nguyen, MD^{1*}, Marcella A. Calfon Press, MD, PhD², Jamil A. Aboulhosn, MD³, Jeannette P. Lin, MD³, Peyman Benharash, MD⁴, Eric H. Yang, MD²

¹ Department of Medicine, University of California at Los Angeles, Los Angeles, California, USA

² Division of Cardiology, Department of Medicine, University of California at Los Angeles, Los Angeles, California, USA

³ Department of Medicine, Ahmanson-UCLA Adult Congenital Heart Disease Center, Los Angeles, California, USA

⁴ Division of Cardiothoracic Surgery, Department of Surgery, University of California at Los Angeles, Los Angeles, California, USA

Abstract

A 67-year-old male with Ebstein's anomaly and a dual-chamber pacemaker due to sick sinus syndrome was admitted to our hospital with cardiogenic shock. Echocardiography revealed severe functional mitral valve regurgitation with preserved ejection fraction. He was referred for percutaneous mitral valve repair (PMVR) for refractory shock in the setting of prohibitive surgical risk. Invasive hemodynamics obtained during PMVR revealed worsening mitral regurgitation due to septal dyssynchrony induced by the patient's permanent pacing. He underwent successful PMVR with subsequent clinical recovery. Dyssynchrony from right ventricular apical pacing may exacerbate mitral regurgitation and heart failure. PMVR with MitraClip may be a safe and effective therapeutic option in patients with refractory cardiogenic shock and severe mitral regurgitation.

Copyright © 2017 Science International Corp.

Key Words

Mitral valve regurgitation • Dyssynchrony • Ventricular pacing • Percutaneous mitral valve repair • Ebstein's anomaly

Introduction

Percutaneous edge-to-edge mitral valve repair (PMVR) using the MitraClip (Abbott, Menlo Park, CA, USA) system is a novel method of reducing severe symptomatic degenerative mitral valve regurgitation (MR) in high-risk or inoperable patients. Although randomized trials for its use in functional MR and end-stage heart failure are currently underway, there are a few reported cases of its use as a rescue therapy in critically ill patients with refractory cardiogenic shock [1, 2]. Here, we present a case of cardiogenic shock in a patient with Ebstein's anomaly secondary to severe functional MR who underwent successful PMVR.

Case Presentation

A 67-year-old male with Ebstein's anomaly, history of bioprosthetic tricuspid valve replacement for tricuspid regurgitation, and dual-chamber pacemaker due to sick sinus syndrome presented to the emergency department with progressive dyspnea on exertion, abdominal distension, a 7-kg weight gain, and severe orthopnea. In the preceding 5 years, he had re-



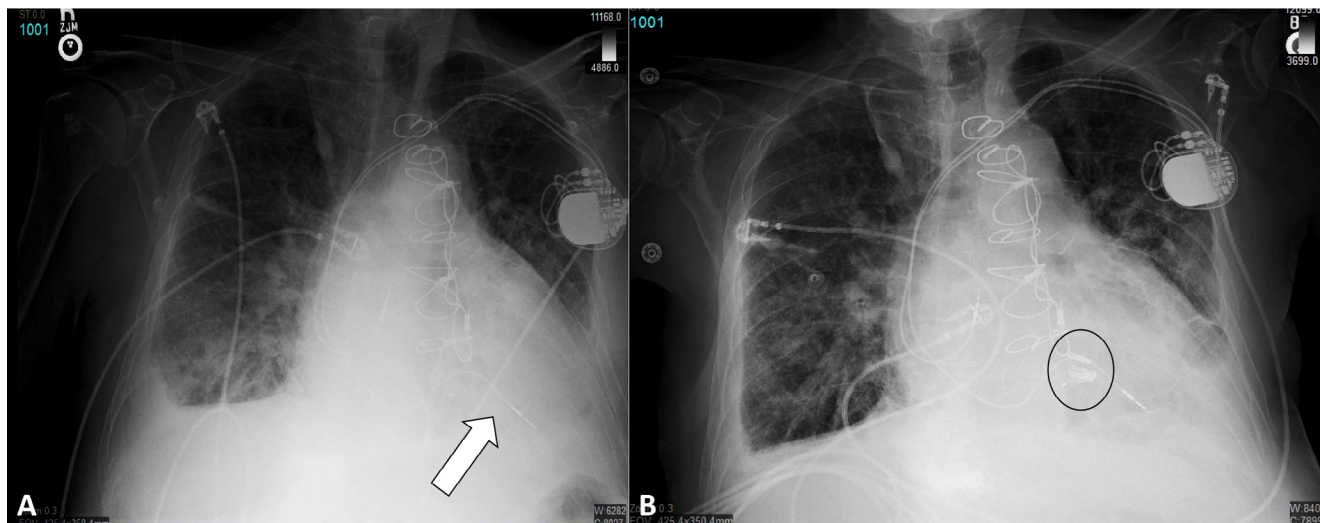


Figure 1. Portable chest radiographs throughout hospitalization. *Panel A.* Portable chest radiograph on admission demonstrating cardiomegaly with a dual-chamber pacemaker with the ventricular lead running on the outside of the bioprosthetic tricuspid valve (**arrow**), vascular congestion, pulmonary edema, and bilateral pleural effusions. *Panel B.* Portable chest radiograph on hospital day 12 (post-mitral valve repair day 6) showing stable placement of three MitraClips (**circle**) and improving pulmonary edema.

quired multiple hospitalizations for dyspnea, weight gain, and abdominal distension despite escalating doses of diuretics.

On physical examination, he was severely dyspneic with an oxygen saturation of 95% on non-invasive bi-level positive pressure ventilation. His blood pressure was 96/67 mmHg with an atrioventricular paced

heart rate of 80 beats per minute. His physical examination was notable for significant jugular venous distension, a grade II/VI holosystolic murmur heard loudest at the apex, bibasilar crackles, abdominal distension, and 1+ bilateral lower extremity edema. Serum brain natriuretic peptide was elevated at 364 pg/mL, and chest radiography showed enlargement of the cardiac silhouette, vascular congestion, pulmonary edema, and bilateral pleural effusions (**Figure 1A**).

Transthoracic and transesophageal echocardiography revealed severe MR, severe biatrial enlargement, and preserved left ventricular ejection fraction with left ventricular end-diastolic and end-systolic dimensions of 52 mm and 40 mm, respectively (**Figure 2A and 2B, Video 1 and 2**). Tenting of the mitral leaflets with poor coaptation of anterior and posterior leaflets was noted, consistent with functional MR. The bioprosthetic tricuspid valve appeared to function normally. Within 24 h of admission, he quickly progressed to cardiogenic shock requiring dobutamine and dopamine, and progressive anuric renal failure requiring continuous renal replacement therapy. He was evaluated for PMVR with via MitraClip given prohibitive surgical risk with 30-day Society of Thoracic Surgeons predictive operative mortality risk scores of 43% and 36% for mitral valve replacement and repair, respectively.

Table 1. Invasive hemodynamics immediately before and after percutaneous mitral valve repair. Note all hemodynamics were measured on the same dosages of dopamine, dobutamine, and epinephrine.

	Pre-Mitral Valve Repair	Post-Mitral Valve Repair
Mean Right Atrial Pressure (mmHg)	23	17
Pulmonary Artery Pressure (mmHg)	67/30	60/27
Pulmonary Capillary Wedge Pressure (mmHg)	27	18
Left Atrial Pressure, a/v waves (mmHg)	18/65	14/30
Cardiac Output (L/min; via thermodilution)	6.1	7.1
Cardiac Index (L/min/m ² ; via thermodilution)	3.2	3.8

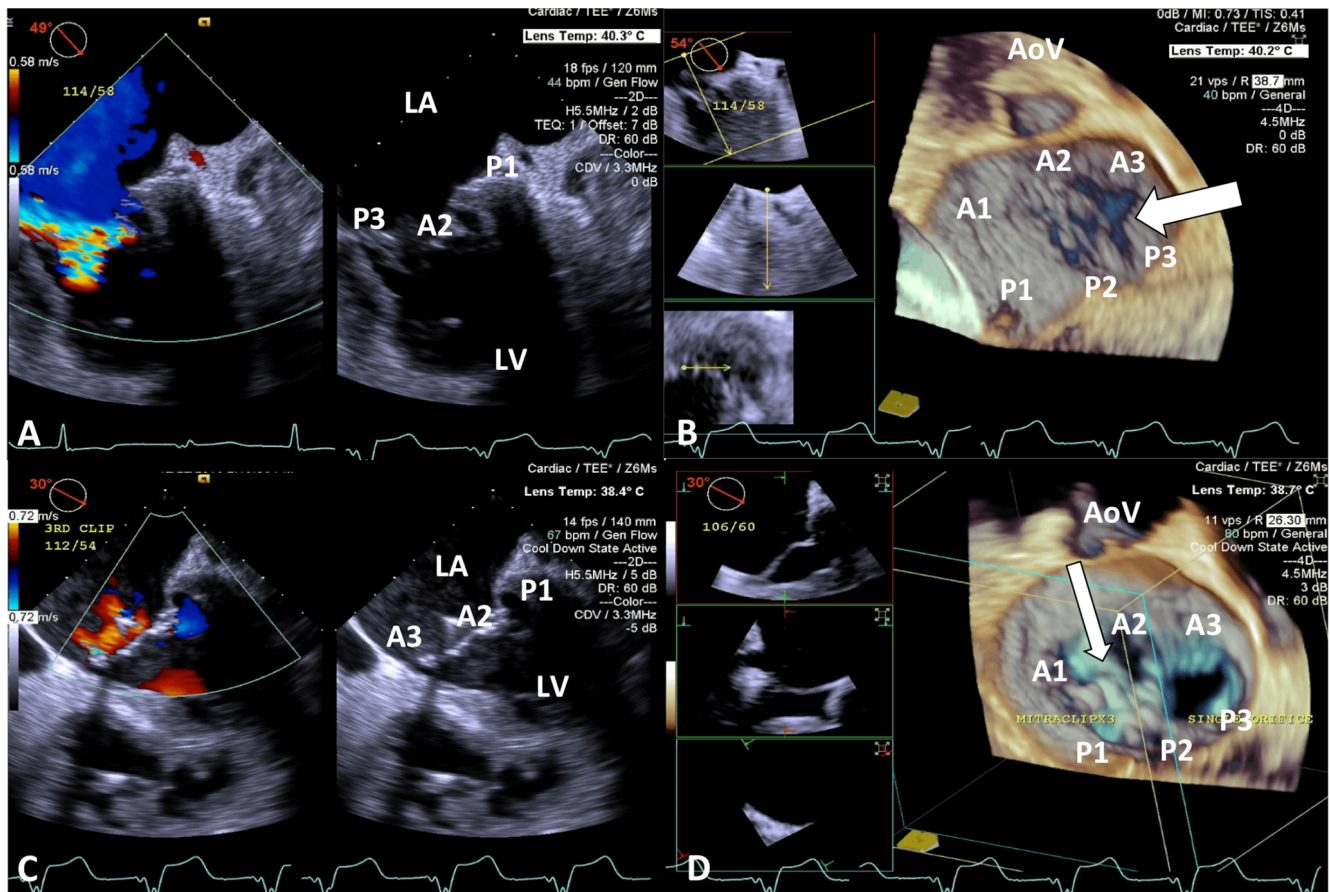
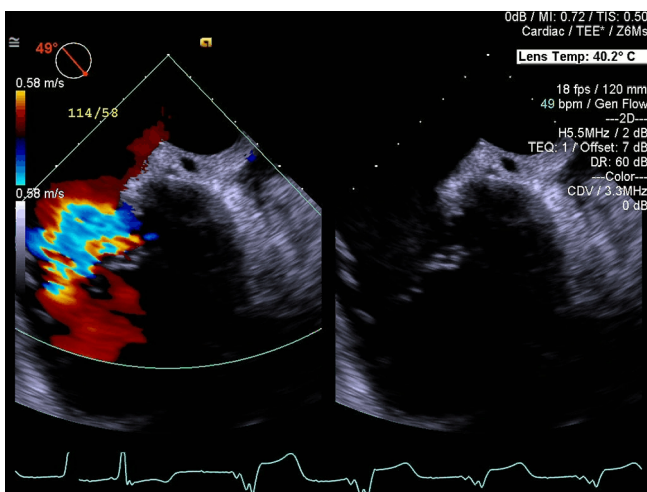
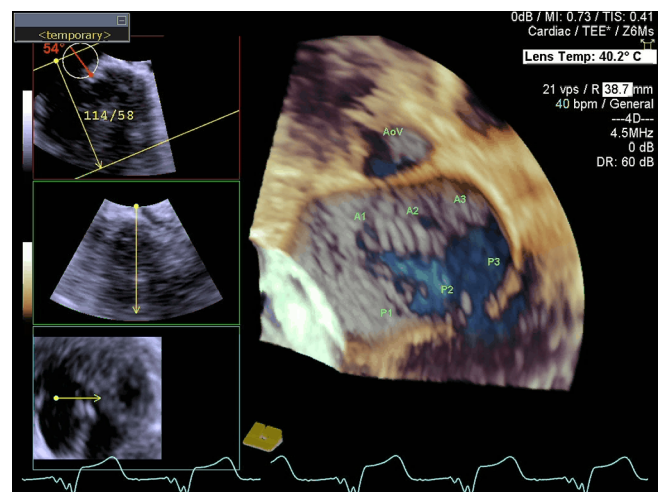


Figure 2. Transesophageal echocardiography before and after percutaneous mitral valve repair. *Panel A.* Two-dimensional mid-esophageal 50° view of the mitral valve with color doppler (**left panel**) showing an approximate commissural view of the P3, A2, and P1 scallops. Severe MR is noted, with a broad base due to leaflet malcoaptation resulting in a functional etiology from atrial dilation. *Panel B.* Three-dimensional live visualization of the mitral valve from the view of the left atrium. Three-dimensional imaging allows



Video 1. Two-dimensional transesophageal echocardiography of the mitral valve as seen in Figure 2A before percutaneous mitral valve repair. View supplemental video at <https://doi.org/10.12945/jshd.2017.033.17.vid.01>.



Video 2. Three-dimensional transesophageal echocardiography of the mitral valve as seen in Figure 2B before percutaneous mitral valve repair. View supplemental video at <https://doi.org/10.12945/jshd.2017.033.17.vid.02>.

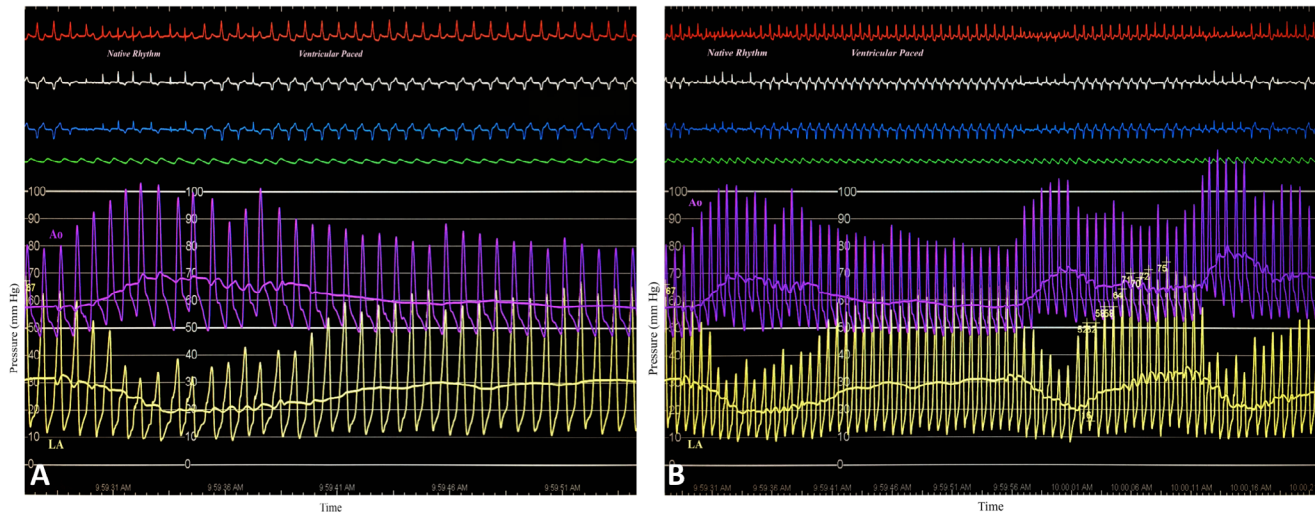


Figure 3. Invasive cardiac hemodynamics measuring simultaneous aortic (**purple**) and left atrial (**yellow**) waveforms before mitral valve repair. When the patient was in a ventricular paced rhythm, increased left atrial pressures with a mean of 30 mmHg with prominent V waves of up to 75 mmHg were noted. Simultaneous central aortic pressures decreased with ventricular pacing (mean 58 mmHg). Native ventricular conduction was associated with decreased left atrial pressures (mean 20 mmHg) with smaller V waves and enhanced arterial pressures (mean 68 mmHg). Ao = aortic pressures; LA = left atrial pressure.

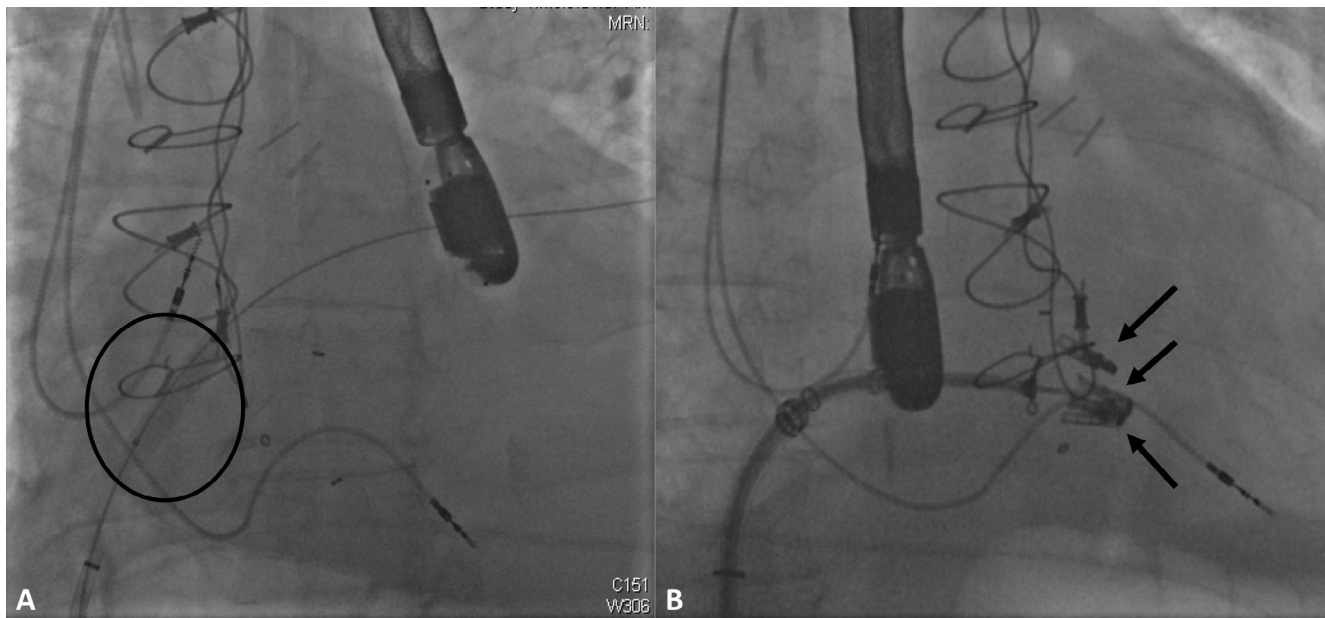


Figure 4. Intraoperative fluoroscopy, anteroposterior view, during MitraClip procedure. *Panel A.* Fluoroscopy performed after transseptal puncture. Balloon dilation (**circle**) of the interatrial septum was performed to allow for passage of the MitraClip delivery catheter. *Panel B.* Fluoroscopy visualizing the placement of three MitraClips (**arrows**).

Intraoperative pre-repair hemodynamics revealed two distinct left atrial and arterial waveforms depending on the patient's cardiac rhythm, illustrating its electromechanical influence on MR (Figure 3). Where-

as the patient was predominantly atrioventricular (AV) paced, a drop in V waves and concurrent rise in aortic waveforms was observed when the patient had native AV conduction. In comparison, resumption of

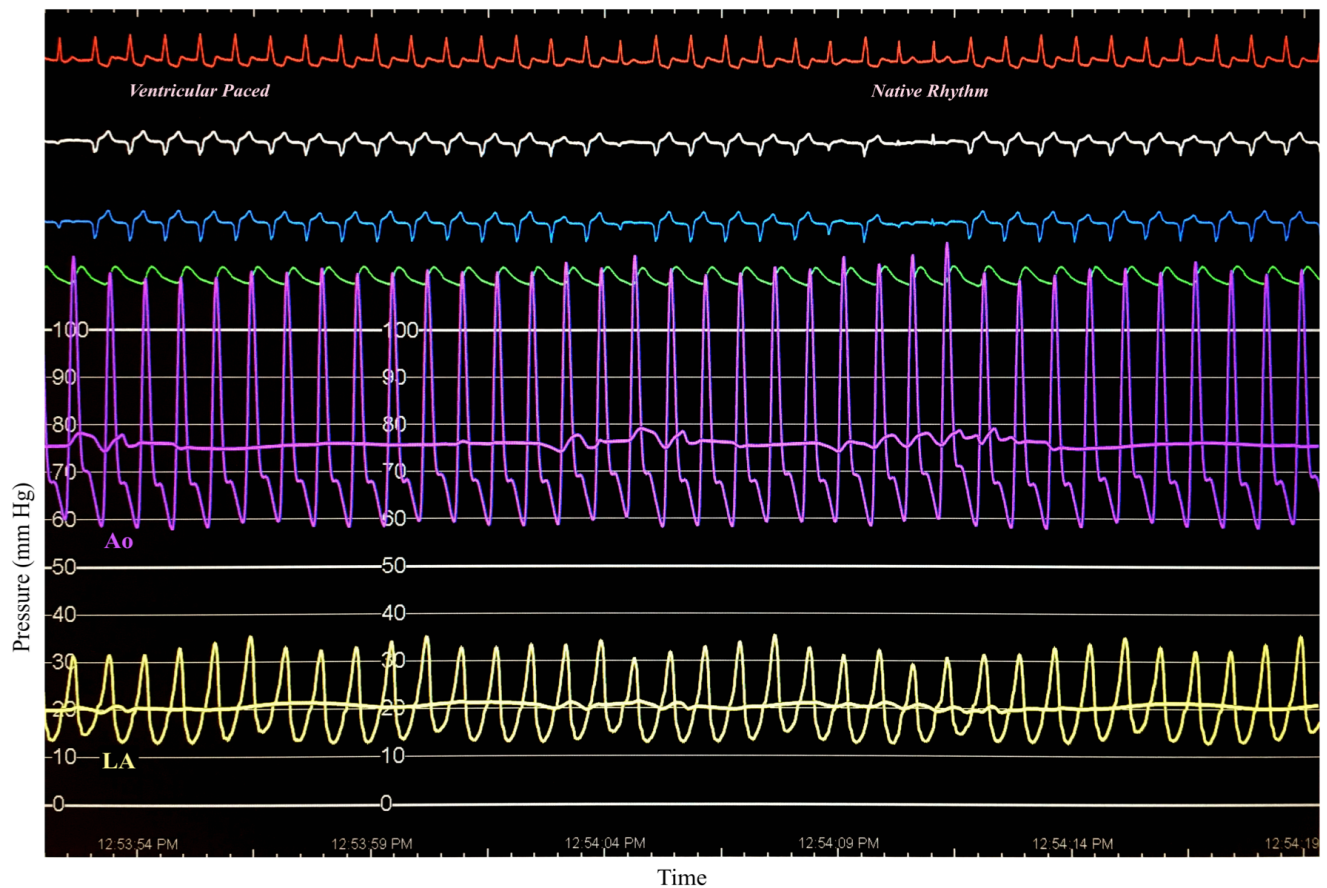


Figure 5. Cardiac invasive hemodynamics after mitral valve repair with measurement of aortic (purple) and left atrial (yellow) pressures. After MitraClip placement, overall improved left atrial pressures (mean 20 mm Hg with V waves up to 33 mm Hg) and arterial pressures (mean 76 mm Hg) are seen with no significant pressure changes during ventricular paced or native conducted rhythms. Of note, minimal pressure variations did not correlate with the patient's ventilatory changes.

right ventricular (RV) pacing resulted in a marked elevation of V waves (up to 67 mmHg) and decrease in aortic pressures, demonstrating worsening of MR.

The patient underwent successful PMVR with deployment of three MitraClips along the A1-2/P1-2 interface, with reduction of MR from severe to mild and a mean transmitral gradient of 3 mmHg (three-dimensional planimetry valve orifice area of 3.6 cm²) (Figure 2B, 2C, and 4, Video 3 and 4). Post-MitraClip hemodynamics confirmed dramatic improvement in left atrial pressures throughout both paced and native rhythms (Figure 5, Table 1). Transthoracic echocardiography on postoperative day 1 showed a mild decrease in left ventricular size and modest drop in left ventricular ejection fraction from 60–65% to 45–50% but with sustained mild residual MR.

Postoperatively, the patient was rapidly weaned off vasopressor support with recovery of renal function (Figure 1B). He was discharged 10 days after the procedure, with plans for pacemaker upgrade to cardiac resynchronization therapy. One month post-procedure, he was doing well, with New York Heart Association class II symptoms and maintenance of a stable weight on an oral diuretic regimen with brain natriuretic peptide of 126 pg/mL. Follow-up echocardiography confirmed no significant changes, with stable mild residual MR.

Discussion

Cardiac pacing is an established and effective treatment for a variety of bradyarrhythmias. Although the

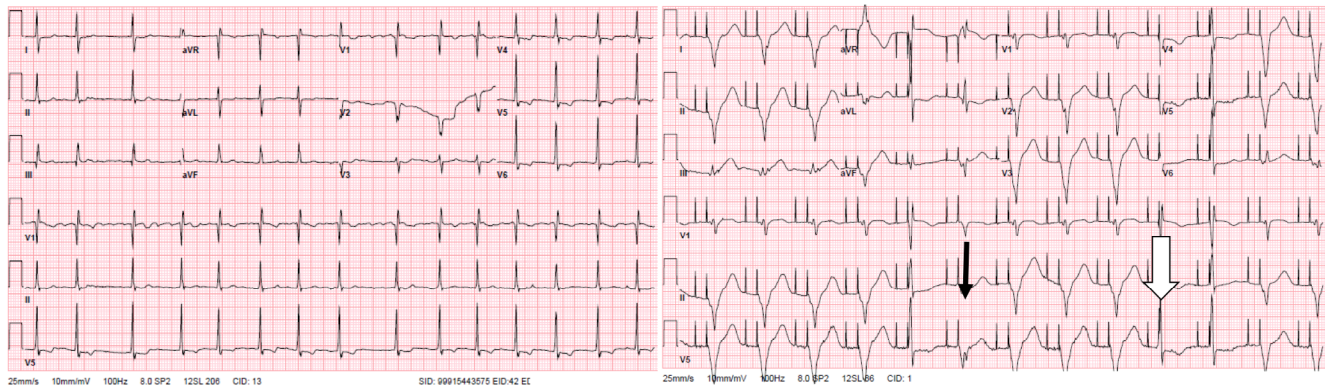
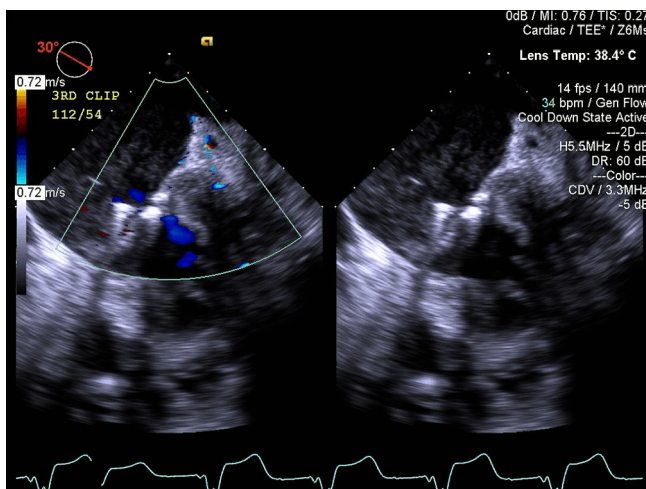
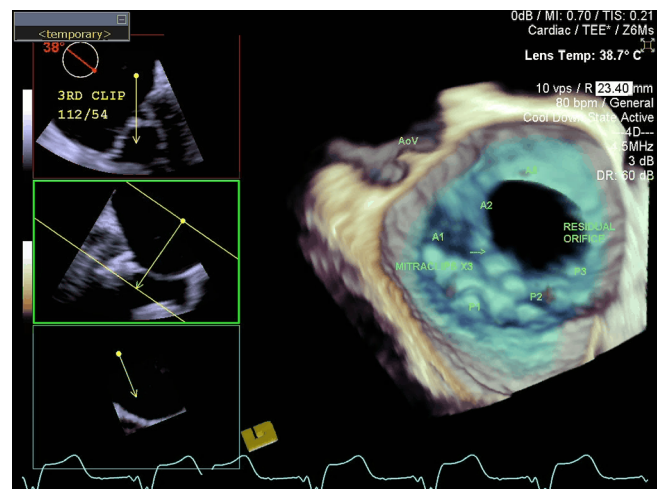


Figure 6. Twelve-lead electrocardiograms. *Panel A.* Electrocardiogram prior to pacemaker placement, demonstrating atrial fibrillation with an incomplete right bundle branch block pattern, with normal axis and nonspecific ST-T segment abnormalities seen inferolaterally. *Panel B.* Electrocardiogram after dual-chamber pacemaker placement, demonstrating an atrioventricular paced rhythm and a paced ventricular morphology with an indeterminate axis and atypical left bundle branch morphology (no broad R waves noted in lateral leads). Pseudofusion (**thick arrow**) was intermittently noted, revealing the patient's native QRS morphology and fusion (**thin arrow**).



Video 3. Two-dimensional transesophageal echocardiography of the mitral valve as seen in Figure 2C after percutaneous mitral valve repair. View supplemental video at <https://doi.org/10.12945/jjshd.2017.033.17.vid.03>.



Video 4. Three-dimensional transesophageal echocardiography of the mitral valve as seen in Figure 2D after percutaneous mitral valve repair. View supplemental video at <https://doi.org/10.12945/jjshd.2017.033.17.vid.04>.

right ventricular apex is the standard pacing site for dual-chamber pacemakers, several studies report detrimental effects of electrical dyssynchrony from RV pacing, including exacerbation of valvular dysfunction and heart failure [3, 4].

In this case, invasive hemodynamics obtained during PMVR demonstrated worsening of functional MR from septal dyssynchrony induced by RV apical pacing. The association between MR and right ventricular apical pacing has been described in many

clinical scenarios ranging from acute severe MR immediately following pacemaker implantation to slow progression of MR in the setting of chronic right ventricular apical pacing [4-6].

The mechanism of MR with RV pacing is derived from intraventricular dyssynchrony. Pacing from the right ventricular apex induces an iatrogenic form of left bundle branch block as depolarization spreads from the apex to the base, as demonstrated by the patient's electrocardiograms before and after du-

al-chamber pacemaker placement (Figure 6). This abnormal left ventricular activation sequence causes delayed reduction of both the mitral annular size and regurgitant orifice size, leading to abnormal leaflet coaptation and enhanced MR [7].

Moreover, a hallmark of Ebstein's anomaly is dyssynchrony of the basal septum at the attachment site of the septal leaflet [8]. Although the patient had previously undergone surgical tricuspid valve replacement, residual septal dyskinesia may have also further contributed to worsened MR.

This case highlights the hemodynamic effects of right ventricular pacing in MR and demonstrates the potential utility of the MitraClip system as a feasible

and effective salvage therapy option in refractory cardiogenic shock. Further experience and research is needed to clarify which patients can be hemodynamically significantly affected by right ventricular pacing.

Conflict of Interest

The authors have no conflict of interest relevant to this publication.

[Comment on this Article or Ask a Question](#)

References

- Zuern CS, Schreieck J, Weig HJ, Gawaz M, May AE. Percutaneous mitral valve repair using the MitraClip in acute cardiogenic shock. *Clin Res Cardiol.* 2011;100:719-721. DOI: [10.1007/s00392-011-0324-1](https://doi.org/10.1007/s00392-011-0324-1)
- Pleger ST, Chorianopoulos E, Krumsdorf U, Katus HA, Bekerredjian R. Percutaneous edge-to-edge repair of mitral regurgitation as a bail-out strategy in critically ill patients. *J Invasive Cardiol.* 2013;25:69-72. PMID: [23388223](https://pubmed.ncbi.nlm.nih.gov/23388223/)
- Cannan CR, Higano ST, Holmes DR Jr. Pacemaker induced mitral regurgitation: an alternative form of pacemaker syndrome. *Pacing Clin Electrophysiol.* 1997;20:735-738. PMID: [09080503](https://pubmed.ncbi.nlm.nih.gov/09080503/)
- Wong DT, Leong DP, Khurana S, Puri R, Tayeb H, Sanders P. Severe mitral regurgitation due to right ventricular apical pacing. *BMJ Case Reports.* 2010;pii:bcr1220092524. DOI: [10.1136/bcr.12.2009.2524](https://doi.org/10.1136/bcr.12.2009.2524)
- Miranda R, Almeida S, Brandão L, Alvarenga C, Ribeiro L, Almeida AR, et al. Acute severe mitral regurgitation as an early complication of pacemaker implantation. *Europace.* 2010;12:1791-1792. DOI: [10.1093/europace/euq191](https://doi.org/10.1093/europace/euq191)
- Alizadeh A, Sanati HR, Haji-Karimi M, Yazdi AH, Rad MA, Haghjoo M, et al. Induction and aggravation of atrioventricular valve regurgitation in the course of chronic right ventricular apical pacing. *Europace.* 2011;13:1587-1590. DOI: [10.1093/europace/eur198](https://doi.org/10.1093/europace/eur198)
- Ebrille E, DeSimone CV, Vaidya VR, Chahal AA, Nkomo VT, Asirvatham SJ. Ventricular pacing – Electromechanical consequences and valvular function. *Indian Pacing Electrophysiol J.* 2016;16:19-30. DOI: [10.1016/j.ipej.2016.02.013](https://doi.org/10.1016/j.ipej.2016.02.013)
- Méndez C, Soler R, Rodriguez E, López M, Alvarez L, Fernández N, et al. Magnetic resonance imaging of abnormal ventricular septal motion in heart diseases: A pictorial review. *Insights Imaging.* 2011;2:483-492. DOI: <https://doi.org/10.1007/s13244-011-0093-4>

Cite this article as: Nguyen HL, Calfon Press MA, Aboulhosn JA, Lin JP, Benharash P, Yang EH. Worsening of Functional Mitral Regurgitation from Septal Dyssynchrony Induced by Ventricular Pacing in Ebstein's Anomaly Undergoing Percutaneous Mitral Valve Repair. *Structural Heart Disease.* 2017;3(6):192-198. DOI: <https://doi.org/10.12945/j.jshd.2017.033.17>