

# The Pediatric and Adult Interventional Cardiac Symposium (PICS/AICS) 21st Annual Meeting

Las Vegas, Nevada, September 5-8, 2018

## 1. TRANSCATHETER CLOSURE OF PATENT DUCTUS ARTERIOSUS IN INTERRUPTED LEFT-SIDED IVC WITH HEMIAZYGOS CONTINUATION: SUBCLAVIAN VENOUS APPROACH

*Balasubramani Nallaperumal, Dr Swapan Se, Dr Soumya Patra*

Apollo Gleneagles hospitals, Kolkata, India

**Introduction:** A 15-years old girl presented with the history of recurrent chest infection, poor weight gain and clinically with bounding pulse, LV enlargement, continuous murmur at left infra-clavicular area. Chest X-ray showed cardiomegaly with prominent pulmonary conus and lung plethora. Echocardiogram revealed a moderate sized (6 mm) Patent ductus arteriosus (PDA), dilated left ventricle and left atrium with pulmonary artery pressure of 40 mm Hg.

**Objective:** The plan was to close the PDA with an Amplatzer duct occluder-I by conventional antegrade femoral vein approach in the cath lab.

**Procedure:** The descending aortogram in left lateral view confirmed of a moderate sized PDA filling pulmonary artery. A 5 French Multipurpose catheter was inserted into the femoral vein to cross the PDA. As soon as the catheter crossed renal level, the anomalous course of inferior vena cava (IVC) took everyone by surprise. It was a rare anomaly of Interrupted left-sided IVC with hemiazygos continuation. Though the PDA could be crossed with wire and catheters, the device delivery system with the length of 80cm was not long enough to be across PDA. So the procedure was to be continued with an alternate approach. The alternate approaches were;

1. Right internal jugular vein
2. Retrograde transarterial: Amplatzer duct occluder-II

- preferred
3. Subclavian vein: rarely tried

We chose subclavian vein approach and a 5 French multi-purpose catheter was used to cross the PDA. Though the course was tortuous the 0.035X260cm Amplatzer super stiff wire made the tough task of tracking of 7 French delivery system smooth across PDA. A Amplatzer duct occluder size of 8 mm/6 mm positioned across the duct and confirmed by aortogram before deployment. Final angiogram showed no residual flow across the PDA.

**Conclusion:** Congenital interruption of IVC is a rare developmental variation (0.6–2.0%). The prevalence of left sided IVC is even rare (0.2%–0.5%) and usually continues as hemiazygos or accessory hemiazygos vein. Interruption of IVC make transcatheter closure of PDA a challenging procedure. Echocardiographic assessment of systemic venous drainage is essential. Subclavian vein approach is an alternative of femoral vein or IJV in a case with interrupted IVC.

## 2. BALLOON ANGIOPLASTY OF CRITIC COARCTATION OF THE AORTA IN NEWBORNS AND INFANTS - FIRST LINE DEFENCE

*Imanov Elnur<sup>1</sup>, Lazoryshynets Vasil<sup>2</sup>, Abdullayev Fuad<sup>1</sup>, Hasanov Elnur<sup>1</sup>, Jahangirov Tofik<sup>3</sup>*

<sup>1</sup>Topchibashev Research Centre of Surgery, Baku, Azerbaijan

<sup>2</sup>Amosov National Institute of Cardiovascular Surgery, Kiev, Ukraine

<sup>3</sup>Abdullayev Research Institution of Cardiology, Baku, Azerbaijan

**Background:** Endovascular intervention in newborns and infants with critic coarctation of the aorta (CoA) is choice of option vs. surgical intervention especially in Ductus dependent patients.



**Objective:** To analyze first experience of balloon angioplasty of CoA in newborns and infants.

**Material:** Enrolled 60 patients with CoA, of them: 41 (68.3%) - underwent surgery; 19 (31.7%) - endovascular intervention. Males to female ratio = 2.74. Age of patients = 1 to 360 days (98.9±10.8). In 34 (57.6%) patients diagnosis was done prenatal.

Patients underwent a routine exam including neurosonography. 9 (15%) patients underwent MDCT. In 22 (36.6%) patients, CoA combined with concomitant congenital heart diseases: VSD in 9 (40.9%) ASD -in 3(13.6%), bicuspid aortic valve in 5 (22.7%), TGA in 3 (13.6%), complete endocardial cushion defect in 2 (1%). All 60 patients were in NYHA class IV. 41(68.3%) patients underwent surgery; 19(31.7%) - balloon angioplasty.

**Results:** Mean pressure gradient prior intervention comprised 58±1.7mm Hg; mean LVEF - 51±12%. In surgical group mean pressure gradient comprised 57±16mm Hg; mean LVEF - 58±7%. In endovascular group mean pressure gradient prior angioplasty was 59±18 mm Hg; mean LVEF 41±9%.

After surgical treatment, mean pressure gradient decreased to 18±6 mm Hg; mean LVEF increased to 67±8%. After balloon dilatation mean pressure gradient decreased to 19±7 mm Hg; mean LVEF increased to 63±7%.

In-hospital complications of surgery presented in 4 (9.7%) patients: 2 patients, after repair of arched hypoplasia, faced with chylothorax; one patient - paresis of the left dome of diaphragm. Wound infection observed in one patient. Neurological complications were absent. Endovascular group made an uneventful recovery. 13 (68.4%) patients need surgery for re - CoA on 3 - 6 months after dilatation.

**Conclusion:** In critic newborns and infants with CoA balloon intervention should be preferred with good in-hospital results. However, endovascular angioplasty of CoA in newborns and infants with isolated CoA remains controversial through a high rate of re-coarctation and necessity for re - interventions.

### 3. EFFICACY AND SAFETY OF CATHETER CLOSURE OF ATRIAL SEPTAL DEFECTS USING THE AMPLATZER VERSUS THE COCOON SEPTAL OCCLUDER. A MULTICENTER RANDOMIZED STUDY

*Basil (Vasileios) Thanopoulos<sup>1,2</sup>, Petros Dardas<sup>1</sup>, Vlassis Ninios<sup>1</sup>, George Giannakoulas<sup>3</sup>, Dan Deleanou<sup>4</sup>, Silvia Lancovici<sup>4</sup>*

<sup>1</sup> Agios Loukas Clinic, Thessaloniki, Greece

<sup>2</sup> Iatrikon Medical Center, Athens, Greece

<sup>3</sup> Ahepa University Hospital, Thessaloniki, Greece

<sup>4</sup> Ares Cardiology Center, Bucharest, Romania

**Introduction:** Transcatheter closure of atrial septal defect (ASD) using the Amplatzer Septal occluder (ASO) has become the procedure of choice in most cardiac centers. However, despite its technical simplicity the procedure is still associated with complications which, although very rare, are potentially life-threatening. The Cocoon septal occluder (CSO) is an improved ASO with certain design features (Nanoplatinum coating, softness) that may potentially reduce the risk of device related erosions and nickel allergic reactions. We design a randomized controlled study to prospectively compare the efficacy and safety of these two devices

**Methods:** 718 patients (median age 14.5 years) from 4 major centers in Greece and Romania were randomly assigned in a 1:1 ratio to catheter ASD closure using the ASO (group 1) and CSO (group 2), respectively. The procedure was guided by fluoroscopy and 2D and 3D transechocardiography.

**Results:** Mean echocardiographic ASD diameter was 21±7mm (range 14-35 mm); 22 ± 6 mm (range 12-34 mm) in group 1 and group 2, respectively. Mean device diameter was 24±9 mm (range 17-40 mm) and 22 ± 8mm (range 14 - 38 mm in group 1 and group 2, respectively. The device was permanently implanted in 353 (98.3 %) and 352 (98%) patients of the group 1 and group 2, respectively. Follow-up (FU) ranged from 6- 48 months. Complete ASD occlusion at 1 month FU was 99%) in both groups of patients. One device erosion (surgical removal) and severe skin allergic reaction (AR) that required chronic treatment with cortisone were observed in one (0.3%) and 2 (0.6%) patients, respectively, of group 1. No device erosions or ARs were observed in group 2. Device embolization was observed in 2 (0.6 %) and 3 (0.85%) patients of group 1 and group 2, respectively. Thrombus formation on the device was observed in 1 patient in both groups.

**Conclusions:** The ASO is a safe and effective in the great majority of cases. The CSO is a safe and effective device that adds to our armamentarium for as much safer catheter ASD closure. Further studies with a larger patient population are needed to confirm our results.

#### 4. HYBRID STENTING IN TREATMENT OF THE OBSTRUCTIVE PATHOLOGY OF THE AORTIC ARCH IN LOW-WEIGHT CHILDREN AFTER SURGICAL CORRECTION OF COMPLEX CHD

*Manolis Pursanov, Konstantin Shatalov, Mikhail Chiaurelli, Andrey Sobolev, David Berishvilli, Alexey Kim, Andrey Svobodov, Irina Arnautova, Ashot Baveyan*

A.N. Bakoulev Scientific Center for Cardiovascular Surgery, Moscow, Russian Federation

**Aim:** to demonstrate possibility of hybrid management of the obstructive aortic arch pathology in low weight children after surgical correction of complex congenital heart disease (CHD).

**Materials and methods:** hybrid interventions were carried out in 3 patients with various CHD. Patients was 8, 22, 27 month and weight 5,7; 8,0; 11,9 kg. In first patient we performed hybrid stenting using Valeo stent 7x18 mm through descending aorta after primary surgical repair of the common arterial trunk (CAT) type 1 with aortic arch restenosis. In second patient with HLHS after Norwood procedure we performed simultaneous stenting of stenotic segments of the obstructive arch of the neo aorta and pulmonary artery (PA). Neoarotic arch was stented using intrastent LD Max 26 mm on a 14 mm balloon through the ascending aorta, next we performed stenting of the left using Valeo stent 6x18 through the right PA with the following BT-shunt reformation. In third patient with Williams syndrome, after surgical management of the supravalvular aortic stenosis using Doty technique an acute dissection of the ascending aorta and aortic arch was registered. We performed intraoperative hybrid stenting of the ascending aorta and aortic arch using 2 Valeo stents 8x18 and 8x26 mm.

**Results:** no complications were registered during hybrid procedure. All patients were discharged from the hospital with good clinical results. After aortic arch stenting in first two patients no systolic pressure gradient (SPG) were registered (86 and 66 mmHg respectively before operation). In third patient with Williams syndrome stent implantation allowed to manage acute aortic dissection and to reduce SPG from initial 177 mmHg to 15 mmHg after operation.

**Conclusion:** Intraoperative hybrid stenting is effective and safe method of treatment of the obstructive pathology of the aortic arch in low-weight children. Stents designed for further dilatation in a follow-up period can provide a good long-term prognosis.

#### 5. HYBRID STENTING OF HYPOPLASTIC PULMONARY ARTERIES IN SURGICAL REPAIR OF COMPLEX CHD

*Manolis Pursanov, Konstantin Shatalov, Mikhail Chiaurelli, David Berishvilli, Alexey Kim, Andrey Sobolev, Irina Arnautova, Ashot Baveyan*

A.N. Bakoulev Scientific Center for Cardiovascular Surgery, Moscow, Russian Federation

**Objective:** to determine results and efficiency of hybrid stenting of the pulmonary artery in patients with various CHD with the obstructive pathology of the pulmonary artery (PA).

**Methods:** hybrid stenting of the PA was performed in 26 patients (28 lesions) with various CHD. Patient age was from 10 month to 19 years (median 4,5+4,7) and weight from 5,3 to 77 kg (median 18,7+18,8). Hybrid stenting was performed in 14 patients (53,9 %) under 3 years old (y.o.), in 5 (19,2%) – from 3 to 6 y.o. and in 7 (26,9%) – older than 6 y.o. Hybrid stenting was performed in operation suit using mobile angiographic C-arm GE 9900. In 9 (34,6%) patients PA stenting was performed during hemodynamic correction of CHD, in 5 (19,2%) – during primal surgical repair of CHD, in 6 (23,1%) – in patients with complications after surgical repair of CHD and in 6 (23,1%) – in patients with hypoplastic left heart syndrome. In general 7 operations were performed as an emergency procedure and in 19 – as a scheduled surgery. Stenting of left PA was performed in 18 cases, of right PA – in 9 cases and in 1 case we performed a stenting of the pulmonary trunk.

**Results:** in 25 (96,2%) of 26 patients hybrid stenting was effective. In 1 case (3,8%) after balloon expansion, stent migrated to the proximal part of the left LA which resulted in surgical removal and repair of the left PA ostium. After stent implantation in all cases, we achieved a complete management of the PA obstruction. One patient (after primal repair of the PA atresia) died due to increasing polyorganic insufficiency in short follow-up period, remaining 25 patients were discharged from a hospital with significant improvement.

**Conclusion:** intraoperative hybrid stenting is effective and save procedure. Vascular access should be determined individually, according to patient anatomy and morphological specifics of CHD. Hybrid procedure allows more effective and safe hemodynamic and primal surgical repair. In cases of complications, they can be managed with direct surgical intervention.

## 6. HYPOTENSION AFTER DEVICE CLOSURE OF ASD

*Kalyanasundaram Muthusamy*

GKNM Hospital, Coimbatore, India

4 years old male child with history of recurrent respiratory tract infection and poor weight gain was evaluated and showed large ostium secundum atrial septal defect of 22 mm in size with adequate rims for the device closure. Under general anesthesia 24 mm Amplatzer septal occluder was deployed under fluoroscopic and transesophageal echocardiogram (TEE) guidance. Before releasing the device TEE showed device was well in position, no residual shunt, normal AV valve flows and both systemic and pulmonary venous blood flows were normal. Hemodynamics and electrocardiogram were normal. 10 minutes after the device was released and just before the femoral sheath was removed, ECG showed significant ST segment elevation, tachycardia of 180 per minute and blood pressure dropped from 100 to 30 mm Hg. Recheck echocardiogram showed device was in position, no AV valve or aortic compression, normal systemic and pulmonary venous flows. Since we could not identify the cause of the haemodynamic instability and we decided to retrieve the device. While we were retrieving the device using 20 mm Goose neck snare and the device was partially retrieved, we noticed the ECG became sinus rhythm and blood pressure became normal. During the process of the retrieving the device the device got loosened off from the snare and it went back to normal position. But ECG again showed elevation of ST segment and blood pressure dropped to 30 mmHg. Meanwhile one of our colleague did coronary artery angiogram while device was still in situ. It showed abnormal origin of left coronary artery from right coronary and it was compressed by the device. Since we identified the cause of ECG changes and hypotension, we retrieved the device using snare with much difficulties and it took about 45 minutes to retrieve the device. It was our luck on that day that we could retrieve the device in the cath lab itself otherwise child could not have survived since there was no time to shift the child to operation room for surgical retrieval.

## 7. ACUTE KIDNEY INJURY AFTER CORONARY ARTERY BYPASS GRAFTING IN PATIENTS RECEIVING PREOPERATIVE INTRA-AORTIC BALLOON PUMP

*Hussain Aboud, Olanrewaju Olaoye, Amir Kazory*

University of Florida, Gainesville, USA

**Introduction:** Placement of preoperative prophylactic intra-aortic balloon pump (IABP) has been suggested to provide improved outcomes in high-risk patients

undergoing coronary artery bypass grafting (CABG). Postoperative acute kidney injury (AKI) is an established predictor of adverse outcomes in cardiac surgery. The aim of this study was to examine the impact of preoperative prophylactic IABP on the incidence of postoperative AKI in high-risk patients undergoing CABG.

**Methods:** Articles cited in PubMed database from Inception to February 2018 using keywords "intra-aortic balloon pump" and "coronary artery bypass grafting" were searched. Clinical trials evaluating pre-operative IABP in high-risk patients undergoing CABG were reviewed. Clinical trials that contained data on renal parameters were selected. Pertinent data including baseline renal function, definition of AKI, and incidence of AKI were extracted and recorded.

**Results:** A total of 104 citations were reviewed and after exclusion of duplicate articles, 17 clinical studies (including 6 randomized controlled trials) with 4481 participants were included. The mean age was 64.7 years, and 74.7% were men. Between 2.6 and 23% of the study population were reported to have preoperative chronic kidney disease (mean  $9.1\% \pm 6.3$ ). Substantial variation existed across studies in the definition of AKI and the time to primary endpoint assessment. The incidence of AKI was between 0 and 22% in the IABP group (median  $4.1\% \pm 6.1$ ) and between 0.5 and 20.4% (median  $8.7\% \pm 8.9$ ) in those who did not receive IABP.

**Conclusion:** We found that preoperative CKD and postoperative AKI are common in high-risk patients undergoing CABG. Moreover, the incidence of AKI seems to be lower in those patients receiving prophylactic preoperative IABP likely due to hemodynamic stabilization by IABP. Future studies are needed to identify the population at risk for renal complications, and to explore management strategies aiming at preservation of renal function in these patients.

## 8. CATHETER CLOSURE OF PATENT DUCTUS ARTERIOSUS IN ADULT PATENTS USING AN OUTPATIENT PROTOCOL. A RANDOMIZED MULTICENTRE STUDY

*Basil (Vasileios) Thanopoulos<sup>1,2</sup>, Petros Dardas<sup>1</sup>, Vlassis Ninios<sup>1</sup>, George Giannakoulas<sup>3</sup>, Dan Deleanou<sup>4</sup>, Silvia Lancovici<sup>4</sup>*

<sup>1</sup> Agios Loukas Clinic, Thessaloniki, Greece

<sup>2</sup> Iatrikon Medical Center, Athens, Greece

<sup>3</sup> Ahepa University Hospital, Thessaloniki, Greece

<sup>4</sup> Ares Cardiology Center, Bucharest, Romania

**Introduction:** Transcatheter closure is the treatment of choice for the majority of patients with a patent ductus arteriosus (PDA). However, the standard technique of this procedure uses an arterial access and requires immobilization of the patients for 24 hours and may be associated with arterial complications. The aim of this study was to report experience with catheter closure of PDA in 104 consecutive adult patients with the Cocoon PDA occluder on outpatient basis using an exclusive venous approach.

**Methods:** The age of the patients ranged from 16-72 years (median 36 years. In group 2 the procedure was guided using hand injections of contrast media through the delivery sheath and 2D and color Doppler echocardiography from suprasternal and parasternal long and short axis, respectively.

**Results:** Group 1: The PDA diameter range from 3 to 10 mm. The device diameter ranged from 4 to 12 mm. The PDA occluders were permanently implanted in all patients. Two and 4 patients had absent and reduced arterial pulses, respectively, that were restored with intravenous infusion of heparin and rtPA, were the main complications of the procedure. The hospital stay of the patients ranged from 24-48 hours. Group 2. The mean PDA diameter ranged from 2 – 9 mm. The device diameter ranged from 4 – 10 mm. The PDA occluders were permanently implanted in all but 2 patients. There were no arterial complications. The hospital stay of the patients ranged from 6 -8 hours. There was a reduced cost that ranged from 300- 500 €. Complete echocardiographic closure of the ductus at 1-month follow-up was observed in all 102 patients (100%).

**Conclusions:** Exclusive transvenous PDA occlusion using combined angiographic and echocardiographic guidance is an effective and safe method that prevents the arterial complications of the standard approach. In addition, in adult patients, this technique, may be used on outpatient basis resulting in early patient mobilization and reduce hospital cost.

#### **9. AMPLATZER VASCULAR PLUG II (AVP II) IS AN ALTERNATE TO AMPLATZER DUCT OCCLUDER (ADO I OR ADO II) FOR UNSUITABLE PDA ANATOMY**

*Kalyanasundaram Muthusamy*

GKNM Hospital, Coimbatore, India

Every patent ductus arteriosus (PDA) has different morphological anatomy. There will be a problem in closing the PDA with ADO I or II device when it is large and long with no adequate ampulla, like Type C PDA (by Krichenko et al classification), especially in neonates. Similarly any type of

PDA with mild Coarctation of aorta where closure of PDA with ADO I or II might increase coarctation gradient. Such types of PDAs can be closed with AVP II. We had six cases of PDA in the last two months with anatomy not suitable for device closure with ADO I or II. Four children with ages between 2 to 4 months had large and long PDAs with no adequate ampulla (almost like Type C PDA). Two patients had moderate to large sized PDA with mild Coarctation (CoA gradient of 10 to 15 mmHg). All these patients underwent successful device closure of PDA with AVP II with no residual shunt on table. Post procedure angiogram showed no aortic encroachment or blocking of branch pulmonary arteries by the device. Patients who had coarctation of aorta showed reduction of gradient to 5 mmHg in one case and nil gradient in the other case. Device sizes used were from 6 mm to 12 mm. The size of the device selection was 1 ½ to 2 times of the duct size on the pulmonary artery end. Two neonates had hemodynamic instability while delivery sheath was negotiated from right atrium to PDA. Sheaths used were Amplatzer delivery system, Cooks mullein sheath and Jugkins right guiding catheter. We conclude that device closure of PDA where anatomy is not suitable for device closure with ADO I or ADO II may be a candidate for AVP II device.

#### **10. FEASIBILITY OF DEVICE CLOSURE OF SUB PULMONIC VENTRICULAR SEPTAL DEFECT (VSD)**

*Kalyanasundaram Muthusamy*

GKNM Hospital, Coimbatore, India

There are enough literatures available to prove beyond doubt that device closure of muscular VSDs and perimembranous VSDs are feasible with acceptable safety. But there are not much published datas available about device closure of sub pulmonic VSDs. The closure of sub pulmonic VSD is necessary even if it is small because they present frequently with complication of aortic regurgitation. Conventionally sub pulmonic VSDs are closed by surgery. But sub pulmonic VSD was not considered earlier for device closure because of its proximity to both semilunar valves and the fear of interference with their function including development of aortic regurgitation. We report 32 cases of sub pulmonic VSDs who underwent successful device closure. Out of 306 cases who underwent successful device closure of VSDs from 2008 to 2017, 32 were sub pulmonic VSDs. Rest of them were perimembranous (230), muscular (29) postsurgical residual VSDs (9) and post MI VSD (2). Demographic features of sub pulmonic VSD cases were age (1 year to 27 years), male (18 no), female (14 no) and weight (9 to 57 kg). The size of the VSD ranges from 3 mm to 12 mm and device sizes used were 4 mm to 14 mm.

We used 21 muscular VSDs, 9 ADO II and 2 ADO I occluders. We had 7 unsuccessful implantation due to failure to cross the VSD and development AR. All these unsuccessful cases were attempted in the initial period of our learning curve. Since the sub pulmonic VSD is located anteriorly and the chance of heart block is less likely. We had two cases of trivial AR before deployment but they did not increase after the device was deployed. Out of 32 cases 30 cases were deployed through retrograde technique (from LV side) and the remaining two cases, where we used ADO I, were deployed through antegrade technique (from RV side). We did not see any complications in the follow up period of 10 years. We conclude that device closure of sub pulmonic VSD through retrograde technique using muscular or ADO II devices is feasible, safe, easy and fast.

### 11. OUTCOMES OF BALLOON ANGIOPLASTY IN NEONATAL TYPE COARCTATION OF AORTA IN SULAIMANI CARDIAC CENTER/ KURDISTAN/ IRAQ

Aso Salih<sup>1</sup>, Shaymaa Mohammed<sup>2</sup>

<sup>1</sup>Sulaimani University/College of Medicine, Sulaymanyah, Iraq.

<sup>2</sup>Sulaimany Pediatric Hospital, Sulaymanyah, Iraq

**Background and Objectives:** Coarctation of aorta is the fourth most prevalent heart disease in infants requiring catheterization and surgery during the first year of life. Balloon angioplasty treatment introduced as an alternative therapy for CoA in the 1980s. The aim of the study is to assess the immediate and intermediate outcome of balloon angioplasty in neonatal type COA.

**Patients and methods:** A case series study of 13 young infants with neonatal coarctation of aorta their ages between 10 days to 18 months. Admitted to intensive care unit of pediatric teaching hospital and Shar hospital neonatal care unit in Sulaimani. Balloon angioplasty were done for them in Sulaimani cardiac center between Feb 2014 to Oct 2017.

**Results:** The patients ages between 10 days to 18 months with mean age at diagnosis in days (mean  $\pm$  SD) was  $90.92 \pm 141.767$ , balloon angioplasty done for them with good result in 10/13 cases without any complication. The mean pressure gradient before and after procedure was  $48 \pm 18.57$  and  $28.15 \pm 16.12$  mmHg, respectively (p 0.2). The complications of balloon angioplasty were divided in to immediate complication within 24h post angioplastic procedure include peripheral cyanosis 1 case (7.7%), with small coarct aneurysm formation 1 case (7.7%), and intermediate complication within 6 month of the angioplasty show

repeated angioplasty in 1 case (7.7%) with stent implantation at 4 month of age, while 10 cases (76.9%) were completely cured without any complications.

**Conclusions:** Balloon angioplasty is more effective in severely ill infants compared to surgery and has many advantages in addition in cases in which none of the treatment modalities is definitely superior it appears that transcatheter technique is preferable. It has been concluded that balloon angioplasty is more effective in severely ill infants compared to surgery and has many advantages in addition to cases in which none of the treatment modalities is definitely superior it appears that transcatheter technique is preferable.

### 12. SUCCESSFUL, DEFINITIVE PERCUTANEOUS CLOSURE OF SEVERE MITRAL REGURGITATION RESULTING FROM IATROGENIC PERFORATION OF ANTERIOR MITRAL LEAFLET DURING AORTIC VALVE REPLACEMENT

Aditya Goud, Steven Deutsch, Suneel Kumar, Amish Patel, Prashant Patel, Ashish Mukherjee, Prabhdeep Sethi, Ramdas Pai, Mohammed Kanakriyeh

University Of California, Riverside, USA

**Case:** A 79-year-old Hispanic female who had redo aortic valve replacement, coronary artery bypass surgery and aortic pseudoaneurysm repair 3 months earlier presented with intractable heart failure. A transesophageal echocardiogram showed a 10 mm sized perforation at the very base of the anterior mitral leaflet causing wide open mitral regurgitation along with a dissection flap into adjoining left atrial wall. The LV systolic and bioprosthetic aortic valve function were normal. The pulmonary artery systolic pressure was 90 mmHg. The etiology was felt to be iatrogenic during aortic valve resection. There were no features of prior or ongoing endocarditis.

**Decision making:** The heart team felt that she was too high risk for a third re-do surgery because of age, heart failure and adhesions seen during the prior surgery. Expectant management was not acceptable because of severe symptoms. Percutaneous closure of the defect was contemplated and various devices were considered to fit the anatomy (various AV plugs, ASD and VSD closure devices). The closure was performed under TEE guidance. Transseptal approach was unsuccessful because of the trajectory of the defect. Aortic retrograde approach was successful in crossing the defect. The defect was closed with a 14 mm AVP II. To provide better support to withstand LV systolic pressure, initially, 2 of the 3 lobes of the device were placed

on the LV side of the defect. But, this produced severe LV outflow flow obstruction. Then, we placed 2 lobes on the left atrial side. This not provided complete elimination of mitral regurgitation, a stable position and lack of LV outflow tract gradient. Patient had a dramatic improvement and remains free from heart failure at 2 month follow up.

**Discussion:** We describe off label use of a vascular plug to seal off a large iatrogenic perforation of the anterior mitral leaflet. We explored various devices to match the device to the defect and providing stability on a mobile leaflet without obstructing LV outflow tract or impeding prosthetic aortic valve function. To our knowledge, this is the first report of a definitive percutaneous closure of such a defect.

#### 14. PERCUTANEOUS OCLUSION OF INTER ATRIAL SEPTAL DEFECTS IN SMALL INFANT WEIGHING UNDER 5 KG WITH IMPORTANT COMORBIDITIES.

Fabio Bergman<sup>1</sup>, Luis A Christiani<sup>1,2</sup>, Alan E. da Silva<sup>1</sup>, Rafael F. Agostinho<sup>1</sup>, João C. Tress<sup>3</sup>

<sup>1</sup>Babycor Pediatric and Fetal Cardiology, Rio de Janeiro, Brazil

<sup>2</sup>UERJ, Rio de Janeiro, Brazil

<sup>3</sup>Complexo Hospitalar de Niteroi, Rio de Janeiro, Brazil

**Introduction:** percutaneous occlusion of inter atrial septal defects in small infants are not easily indicated. Functionally major defects, with huge pulmonary flow, pulmonary disease or persistent ventilation, right ventricular enlargement and pure weight gain should be present and enforce the decision to treat. Safety and efficacy have been published, but are still an issue.

**Case Report:** 6 month age male, 4,9 kg, long term hospitalization ( ICU ), repeated pulmonary infections and low weight gain. A 10 mm inter atrial septal defect and a very small inter ventricular septal defect associated. Right ventricle overload. The x ray show augmented cardiac index and pulmonary congestion. The procedure was performed under general anesthesia with transthoracic echocardiogram, right femoral vein was punctured, for the procedure, left femoral artery was also punctured. The patient was fully heparinized and prophylactic antibiotic therapy was performed. Regular study was performed, ballon assessment of the defect was avoided. A super stiff guide wire, was positioned in the left upper pulmonary vein, 6 french long sheath Amplatzer for PDA closure (AGA Medical, Golden Valley, MN) was used to deliver a 10 mm Amplatzer septal occluder (AGA Medical, Golden Valley, MN). Transthoracic echocardiography demonstrated the

device appropriately seated with atrial septal tissue captured between the left and right atrial parts of the device, only then released. No hemodynamic changes, vascular injury or bleeding at the end of the procedure. A 15 minutes compression of the puncture was enough to stop the bleeding. The patient was taken back to ICU. Despite the uneventful procedure, correct indication and execution and evident signs of immediate improvement, in short-term follow up, the patient presented a new episode of lung infection, did not went well and died 4 weeks after the procedure.

**Conclusion:** We do not recommend the routine closure of an atrial septal defect before 3 years or 12 kg, but in certain small patients with lung disease and others comorbidities would benefit from closure of their defect.

#### 15. USE OF INSTITUTIONAL CRITERIA FOR TRANSCATHETER DEVICE CLOSURE OF FONTAN FENESTRATION – MIDTERM OUTCOMES

Nikhil Thatte<sup>1</sup>, Vivian Dimas<sup>2</sup>, Alan Nugent<sup>2</sup>, Thomas Zellers<sup>2</sup>, Joseph Forbess<sup>3</sup>, Luis Zabala<sup>2</sup>, Surendranath Veeram Reddy<sup>2</sup>

<sup>1</sup>Boston Children's Hospital, Boston, USA

<sup>2</sup>UT Southwestern, Dallas, USA

<sup>3</sup>Lurie Children's Hospital, Chicago, USA

**Background:** There are no established catheter based criteria to decide ideal candidacy for device closure of patent Fontan fenestration. Our institution broadly follows a set of catheter based parameters to decide a patient's candidacy for Fontan fenestration device closure. The criteria are: an unobstructed Fontan pathway with no significant decompressing venous collaterals, baseline Fontan pressures  $\leq 15$  mm Hg, baseline cardiac index  $\geq 2$  L/min/m<sup>2</sup>, and a decrease in cardiac index not more than 20% from baseline with test occlusion of the Fontan fenestration. The objectives of this study were to review mid-term patient outcomes following device closure of Fontan fenestration using our institutional criteria.

**Methods:** A retrospective chart review of all patients who underwent a fenestrated Fontan procedure at our institution between May 2005 and January 2015 was performed.

**Results:** Of the 203 patients who underwent fenestrated Fontan palliation during the study period, 51 patients were referred to the catheterization laboratory for fenestration closure. 42 of 51 (82.4%) patients met the institutional criteria and underwent successful fenestration device closure (Group A). Fenestration closure was deferred (Group B) in the remaining 9 (17.6%) as they were deemed high risk. Demographics, clinical, and pre- and post- test occlusion

hemodynamics for Groups A, B and a Control group C (patients not referred for closure) were compared. The percentage fall in cardiac index with test occlusion was  $18.12 \pm 15.68\%$  in Group A and  $33.75 \pm 14.98\%$  in Group B ( $p = 0.019$ ). There was no significant difference in the rates of plastic bronchitis, PLE, stroke and need for subsequent heart transplantation between the patients in the 3 groups.

**Conclusions:** Using our institutional criteria, transcatheter device closure of Fontan fenestration was followed by significant increase in the oxygen saturations and no significant difference in morbidity or mortality between the closure and non-closure groups. Further prospective randomized studies are needed to identify the patients who will benefit from device closure of patent Fontan fenestrations.

### 17. TRANCATHETER CLOSURE OF ATRIAL SEPTAL DEFECT WITH THE FIGULLA ASD OCCLUDER. A COMPARATIVE STUDY WITH THE AMPLATZER SEPTAL OCCLUDER: A SINGLE CENTRE EXPERIENCE

*Radhakrishnan Sitaraman, Sushil Azad, Roli Shrivastava*  
Fortis Escorts Heart institute, New delhi, India

**Background:** Transcatheter closure of atrial septal defect (ASD) is a well established and well accepted alternative to surgical therapy and is considered safe and effective. Devices available for ASD occlusion combine different properties like self centering mechanism to allow achieving good positioning, ability to recapture and redeploy device. The Amplatzer septal occlude (ASO: St Jude Medical) has been widely used with favourable follow up results. More recently the Figulla ASD occluder (FSO: Occlutech, Germany) has been developed with structural innovation

**Aim:** To perform a retrospective comparison of the two occluders

**Methods:** From January 2016 to December 2017, 108 consecutive patients underwent percutaneous ASD closure. 77 with FSO and 31 ASO devices.

**Results:** There was no significant differences between two groups regarding patient demography. In ASO group (31) 12 (38.7%) were males and 19 (61.3%) were females. The median age was 29 years (range 4 to 58 years). Implantation was successful in 96.67% (30/31) patients. The mean device to defect ratio was 1.33 (range 1.18 to 1.6). In FSO group (77) 36 (46.7%) were males and 41 (53.2%) were females. The median age was 26 years (range 3 to 79 years). Implantation was successful in 76/77 patients. The mean

device to defect ratio was 1.32 (range 1.05 to 1.7). In ASO group 1 device embolised and in FSO group also 1 device embolised. In both ASO and FSO groups there was no incidence of arrhythmia, pericardial effusion in the immediate post procedure period. During follow up period (mean 11.9 months) in ASO group there was no residual shunt. One patient had a small shunt through the adjacent ASD close to the device. In FSO group mean follow up was 8.36 months.

In FSO group there were 5 patients with multiple ASDs, of which 2 patients single device used, 1 patients required implantation of 2 devices, 1 patient required 3 devices. No incidence of erosion, thromboembolism, endocarditis or late embolism in both groups.

**Conclusion:** Transcatheter closure of ASD with FSO is feasible and safe. FSO results are comparable with ASO results. However long term results that include more patients are mandatory.

### 18. ASSESSMENT OF FETAL INTRA-CARDIAC HEMODYNAMICS DURING FETAL BALLOON AORTIC VALVULOPLASTY: CORRELATION WITH FETAL ECHOCARDIOGRAPHIC FINDINGS AND POTENTIAL UTILITY IN PREDICTING PATIENT OUTCOMES

*Jeffrey Zampi, Marjorie Treadwell, Albert Rocchini, Carly Fifer, Cosmas van de Ven, Wendy Whiteside, Sarah Gelehrter*  
University of Michigan, Ann Arbor, USA

**Background:** In-utero balloon aortic valvuloplasty increases the likelihood of a biventricular (BiV) circulation in fetuses with severe aortic stenosis. Current predictors of BiV circulation focus on echocardiographic assessments of left ventricular (LV) systolic pressure and size. Using a pressure wire instead of a standard guidewire, intra-cardiac pressures can be measured during fetal aortic valvuloplasty (FAV) and may enhance predictive models for a BiV circulation and improve our understanding of correlations between intracardiac pressures and echocardiographic measures in the fetus.

**Methods:** We performed a descriptive retrospective review of FAV procedures performed at our center using a pressure wire to measure fetal intra-cardiac pressures. Measurements of LV end diastolic pressure, LV systolic pressure, and aortic valve gradient were compared to pre- and post-natal hemodynamic and functional assessments by echocardiography, and post-natal circulatory physiology.



**Results:** Since 2012, a pressure wire was used in all FAV procedures (n=13) with a procedural success rate of 92% (versus 77%-81% in the two largest published reports). Fetal intracardiac hemodynamics were available for retrospective review in 7 procedures. Of these fetuses, a BiV circulation was achieved in 4 (with 1 fetus currently still in utero). Comparing intracardiac pressure data to fetal echo data, the measured aortic valve gradients and LV systolic pressures correlated well with the echocardiographic estimates. LV end diastolic pressure was not recorded in all patients to allow association with BiV circulation. However, in those with serial measurements, LVEDP generally improved after aortic valvuloplasty, from a median of 22 mmHg pre-valvuloplasty to 16 mmHg postnatally (all BiV patients).

**Discussion:** Intra-cardiac hemodynamics can be successfully and easily measured during FAV procedures. The use of a pressure wire may improve procedural success, facilitating quicker recognition of wire position across the aortic valve. Invasive and non-invasive assessment of LV pressure and aortic gradient correlate closely, and although our data are limited in this case series, assessing LV diastolic function may aid in the ability to predict a successful BiV circulation. If additional centers adopt our technique to measure fetal intra-cardiac hemodynamics, we may build a more robust understanding of how these measurements may predict and improve patient outcomes.

### 19. TRANSCATHETER AORTIC LEAFLET LACERATION TO PREVENT CORONARY ARTERY OBSTRUCTION DURING TRANSCATHETER AORTIC VALVE REPLACEMENT: CONCEPT TO FIRST-IN-HUMAN

Jaffar Khan<sup>1</sup>, Danny Dvir<sup>2</sup>, Adam Greenbaum<sup>3</sup>, Vasilis Babaliaros<sup>4</sup>, Toby Rogers<sup>1</sup>, Robert Lederman<sup>1</sup>

<sup>1</sup> National Heart Lung and Blood Institute, Bethesda, USA

<sup>2</sup> University of Washington, Seattle, USA

<sup>3</sup> Henry Ford Hospital, Detroit, USA

<sup>4</sup> Emory University, Atlanta, USA

Transcatheter aortic leaflet laceration to prevent coronary artery obstruction during transcatheter aortic valve replacement: concept to first-in-human

**Background:** Coronary artery obstruction is a rare but devastating complication of transcatheter aortic valve replacement (TAVR), with a 50% mortality. "Chimney" stents deployed in the coronary ostium and snorkeled into the aortic root are an inelegant solution, with risk of stent thrombosis, delayed coronary obstruction, and difficulty re-engaging the coronary artery. We developed

a technique called Bioprosthetic or native Aortic Scallop Intentional Laceration to prevent Iatrogenic Coronary Artery obstruction (BASILICA) to cut the aortic leaflet in front of the threatened coronary artery immediately prior to TAVR.

**Methods:** We lacerated bioprosthetic pericardial leaflets in vitro using catheter electrosurgery, and tested leaflet splaying after benchtop TAVR. The procedure was tested in anesthetized naïve swine. BASILICA was then offered to patients at high risk of coronary obstruction from TAVR and ineligible for surgical aortic valve replacement. BASILICA used marketed devices. Catheters directed an electrified guidewire to traverse and lacerate the aortic leaflet down the centerline. TAVR was performed as usual. Carotid protection using marketed devices was used at operator discretion.

**Results:** TAVR splayed lacerated bovine pericardial leaflets on the benchtop. BASILICA was successful in pigs, both to left and right cusps. Necropsy revealed full length lacerations with no collateral thermal injury. Seven patients underwent BASILICA on a compassionate basis. Six had failed bioprosthetic valves, both stented and stent-less. Two had severe aortic stenosis, including 1 patient with native disease, 3 had severe aortic regurgitation, and 2 had mixed aortic valve disease. One patient required laceration of both left and right coronary cusps. There was no hemodynamic compromise in any patient following BASILICA. All patients had successful TAVR, with no coronary obstruction, stroke, or any major complications. All patients survived to 30 days.

**Conclusions:** BASILICA addresses the pathophysiology of TAVR-related coronary obstruction with transcatheter leaflet laceration. It may be more durable than "chimney" stenting as a coronary protection strategy. The procedure was successful across a range of presentations, and is under evaluation in a prospective trial (NCT03381989). Its role in treatment of degenerated TAVR devices remains untested.

### 20. HOW CAN WE RESCUE A CRITICAL EXTREMELY SMALL INFANT? BALLOON AORTIC VALVULOPLASTY (BAPV) FOR AN INFANT WEIGHING ONLY 890G.

Naomi Nakagawa<sup>1</sup>, Masahiro Kamanda<sup>1</sup>, Yukiko Ishiguchi<sup>1</sup>, Yuji Moritoh<sup>1</sup>, Takayuki Suzuki<sup>1</sup>, Kengo Okamoto<sup>1</sup>, Kuhikazu Hisamochi<sup>2</sup>, Takuya Kawabata<sup>2</sup>

<sup>1</sup> Department of Pediatric Cardiology, Hiroshima City Hospital, Hiroshima, Japan

<sup>2</sup>Department of Cardiac Surgery, Hiroshima City Hospital, Hiroshima, Japan

A baby boy was born via emergent cesarean section at 26 weeks of gestation, weighing 438 g. Echocardiography revealed a large PDA and valvular aortic stenosis (AS) of 1.9m/s, requiring PDA ligation at 5 days of age. He rapidly developed systemic edema and bradycardia with motion when he was 111 days old and 890 g. Echocardiography revealed an AS of 5.1 m/s, LVEDD of 219%, LVEF of 54%, and no patency of the foramen ovale. The emergent intervention was required. The ultrasonography revealed that the RCCA (2.7 mm) could accommodate the sheath, although the femoral artery was too small (1.6 mm). The patency of the anterior communicating artery was proved which maintained blood perfusion to the brain even the RCCA might be obstructed by the sheath. The length needed for the sheath was measured by determining the distance between the point of insertion and AoV –then the length between AoV and LV apex (must be longer than half the length of balloon plus balloon shoulder length). Silkworm-gut was tied 20 mm from the tip of the sheath to ensure the sheath was not inserted too far. In a hybrid operating room, the surgeon made a semicircle incision on the RCCA and a 4-Fr sheath was inserted. We avoided the pull-back gradient measurement and left ventriculography before BAVP due to critical condition. An ascending aortography revealed the diameter of AoV, and orifice of AoV were recognized using a negative jet of contrast medium. A 0.014' guidewire was inserted into LV and BAVP was performed immediately using TMP-Ped/4 mm without raid pacing. The Pull-back pressure gradient between LV and Ao after BAVP was 22 mmHg after BAVP and cardiac function and edema rapidly improved. His prognosis was very good following the procedure and a second BAVP was performed by antegrade approach through the femoral artery when he was 11 months old and 3.2 kg. And the angiography revealed the patency of RCCA. When performing complex procedures, simulation should be used to evaluate the procedure, determine possible risks, and create strategies to ensure the best possible outcome.

## 21. PERCUTANEOUS CLOSURE OF PERIMEMBRANOUS VSD IN INFANTS AND CHILDREN USING AMPLATZER DUCT OCCLUDER I ; SINGLE CENTER EXPERIENCE

Hala Moustafa, Hala Hamza, Amal El Sisi, Sonia El Seidi, Aya Fatouh, Rodina Sobhy, Doaa Abd El Aziz, Wael Attia  
Cairo University, Cairo, Egypt

**Background/aim:** Amplatzer duct occluder I (ADOI) devices appear to be an attractive option in perimembranous

(pmVSD) type. In developing countries, the lack of early available and affordable surgery, and the relatively high cost of currently devices designed for VSD closure create additional problems. We report on the immediate and mid-term follow-up results of using ADOI devices to close pmVSDs in a consecutive series of young patients.

**Patients & Methods:** Retrospective case note review of all children referred for transcatheter closure of pm VSD using the ADO I device.

**Clinical inclusion criteria:** at least 3 of the following had to be present: Overt heart failure, Failure to thrive, Recurrent respiratory infections, C/T ratio  $\geq 0.55$ , LA/AO  $> 1.5$ , LVEDD z-score indexed to body surface area of  $\geq 2$ , QP/QS  $> 1.5$  at cardiac catheterization, 8History of IE related to the VSD.

**Morphologic inclusion criterion:** Isolated pm VSD, up to 10 mm minimum diameter by TTE. **TEE:** to describe the anatomical position of the VSD, the distance to important structures such as the aortic valve, the diameter of the defect at the LV and RV sides, the shape of the defect and the presence of tricuspid tissue from the septal leaflet trying to estimate the needed device size

**Conclusion:** the transcatheter closure of pm VSD with Amplatzer ductal occluder I was successful in 95% without

**21. Table:** Characteristic of the 28 studied patients who underwent VSD closure.

Variables	Median (range)
Age (yrs)	4 (13 months–12Y)
Wt (kg)	15 (6.5–51)
VSD diameter angio(mm)	
Fluoro time (min)	5.2 (3.75–9)
Device diameter/length	55 (34.5–99)
6 × 4	N(%)
8 × 6	5 (17.9%)
10 × 8	8 (28.6%)
	13 (46.4%)
Procedure results	
<b>Variables</b>	<b>N(%)</b>
Success rate	24/28 (85.7%)
Unstable device	3/28 (10.7%)
Embolized to RV & percutaneous retrieval	1/28 (3.5%)
Immediate closure	22/24 (91.7%)
Closure at 3months	23/24 (95%)

any residual flow or heart block. \*ADOI is safe and effective for transcatheter closure of pmVSDs in symptomatic infants and children. The device is affordable and widely available.

## 22. ACUTE MYOCARDITIS AND PEDIATRIC DILATED CARDIOMYOPATHY; IMAGE GUIDED DIAGNOSIS BY CARDIAC MRI AND ECHOCARDIOGRAPHY TISSUE DOPPLER IMAGING

*Hala Moustafa, Manal Abd El Hamid, Alae Sobeih, Antoine Abd El Messih, Ahmed Kharabish*

Cairo University, Cairo, Egypt

**Objectives:** To differentiate acute myocarditis from pediatric dilated cardiomyopathy by using Cardiac magnetic resonance imaging (CMRI) and tissue Doppler imaging (TDI).

**Patients and methods:** Twenty-four patients with suspected acute myocarditis or dilated cardiomyopathy underwent CMRI and TDI. CMRI was performed for cardiac functions assessment, detection of myocardial edema, capillary leakage and late Gadolinium enhancement (LGE). Pulsed tissue Doppler imaging (TDI) measures included systolic myocardial velocities at the basal lateral LV and septal wall segments (LV-S', IVS-S' respectively), early and late diastolic myocardial velocities and their ratio of the same basal segments (LV-E', LV-A', LV-E'/A', IVS-E', IVS-A' and IVS-E'/A').

### Results:

**CMRI findings:** myocardial edema in 100% and capillary leakage in 55.6% of myocarditis group, these 2 findings are absent in DCM group ( $p < 0.001$ ,  $p = 0.003$ ), while LGE in 66.7% of myocarditis group and 6.7% in DCM ( $p = 0.004$ ).

**Tissue Doppler imaging findings:** The median value of IVS-S' and LV-S' was significantly higher in myocarditis group compared to DCM group [3.99cm/sec and 4.62cm/s versus 3.16cm/s and 3.79 cm/s respectively ( $p = 0.04$ ,  $p = 0.04$ )].

**Conclusion:** All myocarditis patients had myocardial edema by CMRI. In patients having acute myocarditis proved by CMRI had less severe left ventricular systolic dysfunction compared to DCM patients detected by TDI.

## 23. RESULTS OF THE NIT-OCCLUD PDA POST APPROVAL TRIAL

*Daniel Levi<sup>1</sup>, Morris Salem<sup>2</sup>, Thomas Forbes<sup>3</sup>, Brent Gordon<sup>4</sup>, Brian Soriano<sup>5</sup>, Thomas Jones<sup>5</sup>, Vivian Dimas<sup>6</sup>, Alex Javois<sup>7</sup>,*

*John Bass<sup>8</sup>, Darren Berman<sup>9</sup>, Matthew Gillespie<sup>10</sup>, John Moore<sup>11</sup>, Carl Owada<sup>12</sup>, Brian Goldstein<sup>13</sup>*

<sup>1</sup>UCLA, Los Angeles, USA. <sup>2</sup>Kaiser Permanente, Los Angeles, USA. <sup>3</sup>Detroit Children's Hosp, Detroit, USA. <sup>4</sup>Loma Linda Univ, Loma Linda, USA. <sup>5</sup>Seattle Children's Hosp, Seattle, USA. <sup>6</sup>Children's Hosp of Dallas, Dallas, USA. <sup>7</sup>Advocate Christ Medical Ctr, Chicago, USA. <sup>8</sup>Univ of Minnesota, Minneapolis, USA. <sup>9</sup>Nationwide Children's Hosp, Columbus, USA. <sup>10</sup>CHOP, Philadelphia, USA. <sup>11</sup>UCSD-Rady Children's Hospital, San Diego, USA. <sup>12</sup>Valley Children's Hosp, Fresno, USA. <sup>13</sup>Cincinnati Children's Hosp, Cincinnati, USA

**Intro:** The FDA granted PMA approval for the Nit-Occlud PDA in 2013 based on the results of the pivotal trial which along with the continued access protocol enrolled 357 patients prospectively. The results of the Nit-Occlud prospective post-approval study (PAS) which was performed at 11 centers is reported along with a comparison to the results of the pivotal trial.

**Methods:** A total of 184 subjects greater than 6 months of age and 5 kg with PDAs less than 4 mm by angiogram were enrolled at 11 centers for the PAS. Patients were followed prospectively with ECHO and clinical assessments at 2 months, 12 months and 24 months post-procedure. These outcomes were compared to the 357 subjects enrolled in the pivotal and continued access protocols.

**Results:** Of the subjects enrolled in the PAS trial, 68.5% were female, the median age was 3.4 years. 83.7% had a Type A PDA. A venous approach was used in 95.6% of the subjects. There was no significant device obstruction to the pulmonary arteries or aorta and there were no deaths, no episodes of hemolysis and no need for blood transfusion or surgery. 97.0% (165/170) of subjects had trivial or no residual shunt as assessed by ECHO at the 2 month follow-up and the remainder had a small residual shunt. At 12 month follow-up, 98.7% (150/152) had trivial or no residual shunt as assessed by ECHO and the remainder had only small residual shunts. Together with the pivotal study, there was a total of 541 subjects enrolled with no mortality and no serious adverse events. When combining both studies, 97.4% (449/461) had echocardiographic follow up at 1 year demonstrating no significant shunt. In both trials, there were a total of five Nit-Occlud device embolizations and all were snare retrieved with catheters and without clinical consequence.

**Conclusion:** As evidenced by follow up of 541 patients enrolled prospectively in two large clinical trials, the NitOcclud PDA device is a very safe and effective device for

PDA occlusion. In this large cohort, there was no hemolysis, mortality, need for surgery or other serious adverse events.

#### 24. TRANSCATHETER STENTING OF SUPERIOR VENA CAVA OBSTRUCTION AFTER PEDIATRIC HEART TRANSPLANTATION: A SINGLE-CENTER EXPERIENCE OF RISK FACTORS AND OUTCOMES

Arash Salavitarab<sup>1</sup>, Jonathan Flyer<sup>2</sup>, Warren Zuckerman<sup>1</sup>, Marc Richmond<sup>1</sup>, Matthew Crystal<sup>1</sup>, Mariel Turner<sup>1</sup>, Paul Chai<sup>1</sup>, Alejandro Torres<sup>1</sup>

<sup>1</sup>New York-Presbyterian Morgan Stanley Children's Hospital/ Columbia University Medical Center, New York, USA. <sup>2</sup>The Robert Larner, M.D. College of Medicine at The University of Vermont, Vermont, USA

**Objective:** Transcatheter stent implantation for superior vena cava (SVC) obstruction following orthotopic heart transplantation (OHT) has been well-described. Pediatric patients may be at greater risk due to smaller absolute vessel size, donor-recipient size discrepancies, and complex congenital cardiac disease (CHD). We report a large single-center pediatric OHT experience that investigates the risk factors for SVC stenosis and procedural outcomes of stent implantation.

**Methods:** Single-center retrospective study of all pediatric OHTs between 1/1/00 and 12/31/16. Primary outcome was stent implantation in the SVC after OHT. Secondary outcomes included procedural success, clinical improvement, complications, and re-interventions. Primary risk factors included bicaval versus biatrial surgical anastomosis and history of previous superior cavo-pulmonary anastomosis (SCPA).

**Results:** Nineteen stents were implanted in 12/349 (3.4%) patients at a median 1.8 months (IQR 0.9, 4.8) after OHT. Indications included chylous effusion in 7, SVC syndrome in 3, and echo/angiographic stenosis in 2. Femoral access used in 6 patients, and right and left jugular veins in 4 and 2, respectively. Two patients underwent mechanical thrombectomy pre-stent placement. In 9 patients, a single stent was implanted while the other 3 patients received 2, 3, and 5 stents. Eleven (58%) stents were premounted (1 covered). All procedures were successful with no residual obstruction and no acute procedural complications. Most patients received enoxaparin for 3-6 months. Stent recipients were younger (2.5yrs vs 10.0yrs,  $p=0.0097$ ), weighed less (8.6kg vs 26.0kg,  $p=0.0024$ ), and more likely to have had CHD (83% vs 32%,  $p=0.001$ ) or previous SCPA (58% vs 18%,  $p=0.002$ ). Bicaval anastomosis was not associated

with subsequent SVC stent implantation. Post-procedure median follow-up 29.7mo. (IQR 9, 141). Chylous effusions resolved within 2 weeks in 6/7 patients and SVC syndrome patients improved. One patient died of multi-organ failure 4 months post-procedure. Four (33%) patients required re-intervention (3 angioplasties, 1 stent) at a mean of  $5.7 \pm 3.6$  months post-stent implantation. There was no residual obstruction at last follow-up.

**Conclusions:** SVC stent implantation after OHT is a safe and effective procedure that is associated with younger age, smaller weight, CHD, and history of SCPA, while showing no association with bicaval vs. biatrial anastomosis.

#### 25. NEW FUSION IMAGING - VESSELNAVIGATOR IN CHD INTERVENTIONS

Ji Seok Bang, Ja Kyung Yun, Eun Young Choi, Su Jin Park, So Ick Jang, Chung il Noh, Seong-Ho Kim  
Sejong General Hospital, Bucheon, Korea, Republic of

**Background:** VesselNavigator is a new fusion imaging modality which overlays 3D CT image onto a live fluoroscopy image. It provides an intuitive and continuous 3D roadmap by rotating overlaid CT imaging at any directions and allows for both advanced diagnostic and interventional cardiac catheterization procedures in patients with congenital heart disease(CHD). Therefore, lesions previously considered resistant to interventional therapies can now be managed with high success, such as peripheral pulmonary artery stenosis.

**Objectives:** Recently, in our institute VesselNavigator was available first in Asia. We would like to share our initial experiences with the audiences.

**Methods:** Between May 2016 and March 2018, VesselNavigator has been used in 38 patients with post-operative CHD; tetralogy of Fallot or pulmonary atresia in 17, transposition of great artery in 5, coarctation of aorta in 4, functional single ventricle in 4 and others in 8. Mean age was 13.3(0.4 – 73) years, and mean body weight was 32.4(5.4 – 98) kg. It helped to access a target vessel easily, and to find out the best angiocamera angle for diagnosis and interventional procedure without additional angiography.

**Results:** VesselNavigator was used for pulmonary arterial interventions in 24 (stent in 12, balloon angioplasty in 12), aortic arch interventions in 3, collateral occlusion in 3, other intervention in 3 and diagnosis in 6 patients. Mean

fluoroscopic time and procedure time were 20.3(4.9 – 52.3) and 80.3(33.0 – 166.0) min., respectively.

**Conclusions:** VesselNavigator is a promising modality for CHD diagnosis and treatment. It is tremendously beneficial for some CHD interventional procedures. Using VesselNavigator as a 3D roadmap without additional 3D rotational angiography, we can reduce fluoroscopic and procedural time, contrast amount and radiation exposure.

## 26. SUBACUTE BACTERIAL ENDOCARDITIS PRESENTING IN PATIENTS WITH PERCUTANEOUSLY IMPLANTED PULMONARY VALVE NOT DETECTED ON INITIAL TRANSESOPHAGEAL ECHOCARDIOGRAM

Angela Li, Sawsan Awad

Rush University Medical Center, Chicago, USA

**Introduction:** Percutaneous pulmonary valve replacement (PPVR) within an existing bioprosthetic pulmonary valve (BPV) is an increasingly attractive surgical alternative for adult congenital heart disease patients with BPV failure. Infectious endocarditis (IE) in this subset of patients may be subacute as described below.

### Case Description:

**Case #1:** A 57 year old female with unknown congenital heart disease (recent percutaneous Melody valve replacement within old bioprosthetic valve) presented to cardiology clinic with one month of early satiety and progressive fatigue. EKG in clinic revealed new onset atrial fibrillation; TTE with increased right ventricular outflow tract (RVOT) gradient and evidence of acute on chronic right heart failure. Patient was admitted with plan for cardioversion, but developed fevers prior to intervention. Serial blood cultures obtained with growth of *Strep milleri*. Initial TEE did not reveal vegetations; however, repeat TEE was performed which confirmed vegetations. Patient received 2 weeks of IV antibiotics prior to surgical replacement of pulmonary valve and MAZE procedure.

**Case #2:** A 21 year old male with history of Tetralogy of Fallot (status post pulmonary homograft replacement with resultant pulmonic insufficiency, and subsequent percutaneous Melody valve replacement), presented to outside hospital with five days of nausea, vomiting that progressed to fevers and myalgia. Initially treated for viral gastroenteritis, patient developed frank hematuria prompting additional workup. CBC with acute thrombocytopenia, serial blood cultures with growth of *Methicillin resistant staph aureus*. Outside hospital TEE showed no

obvious vegetation, noted severe stenosis of bioprosthetic pulmonic valve with increased RVOT gradient. Repeat TEE after transferring to our institution significant for large vegetation on pulmonic valve leaflets. Patient received 3 weeks of IV antibiotics prior to surgical replacement of pulmonary valve.

**Discussion:** Reports on IE in PPVR patients are limited; one prospective study of patients undergoing PPVR found that vegetations were not seen on TTE/TEE for all patients, but all had increase in RVOT gradient compared to prior echocardiogram, as was true in our patients. New increase in RVOT gradient may serve as a good indicator of IE in PPVR patients, when standard diagnosis with imaging has shown to be limited due to difficult cardiac anatomy.

## 27. HOW TO PENETRATE TOUGH AND SCLEROTIC LESIONS IN POSTOPERATIVE PATIENTS WITH COMPLEX CONGENITAL HEART DISEASE. NOVEL TECHNIQUE BY COMBINATION OF A STEERABLE SHEATH AND SHARPENED STIFF WIRE

Hisashi Sugiyama, Kouta Taniguchi, Hiroki Mori, Keiko Toyohara

Tokyo Women's Medical University, Tokyo, Japan

**Background:** Recently, the necessity for penetration of tough and sclerotic lesions increased in postoperative patients with complex congenital heart diseases (CHD). We developed a new technique, which combined a steerable sheath and sharpened stiff wire, to penetrate tough and sclerotic lesions. Efficacy and safety of the procedure was evaluated.

**Subjects and Methods:** A total of 4 lesions in 4 patients (2 male and 2 female, age ranging from 11 to 41 years old, 3 total cavo-pulmonary connections and one Mustard procedure) were applied for the procedure. Purpose was access for catheter ablation in 3 and recanalization of SVC syndrome in one. In all patients, penetration could not be achieved by the Brockenbrough procedure. Three of those were a synthetic conduit used for total cavo-pulmonary connection and one was an occlusion between the SVC and neo right atrium in the patient after Mustard operation with transposition of the great arteries. Multi-planar reconstruction (MPR) imaging by cardiac CT was done for planning before all procedures. Under ICE and fluoroscopy guidance, a steerable sheath (8 Fr) was perpendicularly adjusted to objects. The sharpened edge of 0.014 inch guide wire was pushed via the sheath. Adding continuous force could easily penetrate the tough lesions. Then micro catheter was advanced over the wire. Subsequently,

a balloon catheter was exchanged. Balloon dilatation was performed from a small balloon to a large one step by step.

**Results:** In all patients, penetration could be successfully completed. Catheter ablation could be achieved in 3 patients and symptom of SVC syndrome disappeared in one patient. No complication was recorded.

**Conclusion:** This procedure could safely penetrate for even calcified synthetic conduits or sclerotic lesions, which could not be penetrated by a Brochenbrough needle or radiofrequency wire. Steerable sheath could easily become perpendicular to the object for preventing from slippage and conveying effective force. MPR imaging is an essential modality for planning the procedure.

## 28. AN UNUSUAL CASE OF TRANSTHORACIC ACCESS FROM THE RIGHT AXILLA

Saadeh Jureidini<sup>1</sup>, Robert Petersen<sup>1</sup>, Lisa Bade<sup>2</sup>, Charles Huddleston<sup>1</sup>

<sup>1</sup>Saint Louis University, St. Louis, USA. <sup>2</sup>SSM Cardinal Glennon Children's Hospital, St. Louis, USA

Transthoracic access (TTA) in congenital heart disease (CHD) has been well described for the purpose of diagnostic and transcatheter interventional procedures. TTA is used when other routes fail to allow access to target areas. Typically, TTA requires adherent heart to chestwall, as in post operative conditions, and is performed mostly from para sternal approach. We describe, herewith, the performance of TTA in an unconventional location, to achieve difficult interventions, that would have been otherwise not possible.

A 4 year old, 17 kg male with recently diagnosed left pulmonary veins stenosis presented for transcatheter therapy prior to completion of an extracardiac Fontan. He was born with a complex CHD including hypoplastic left heart, Scimitar syndrome and interruption of IVC to right azygous. His surgical procedures included Norwood with Sano, Kawashima operation and resection of the right lung due to severe hypoplasia of right pulmonary artery contributing to pulmonary hypertension. Two cardiac catheterizations, including transhepatic were performed somewhere else and were unsuccessful to enter the left pulmonary veins. At our center, a MRI and transthoracic echo from the right axilla confirmed that the right atrium is adherent to right axillary chest wall. In the cath lab, angiography in the left pulmonary artery, azygous vein and right ventricle allowed spatial understanding of his anatomy. Transthoracic access was performed in mid right

axillary location to place a 7 French sheath and allowed successful access to the right and left atria, and left lower and upper pulmonary veins. Balloon angioplasty of the lower vein to 12mm and upper vein to 9mm resulted in resolution of angiographic discrete stenosis and drop in gradient from 6 to 3 mm Hg. Removal of sheath with manual pressure allowed hemostasis as confirmed by echo. He later underwent successful extracardiac Fontan with fenestration. After a year of follow-up he continued with very good clinical and echocardiographic evaluations.

We conclude that TTA can be performed safely from unusual locations if proper imaging is done to understand the chest wall – atrial relationship.

## 29. ACUTE OUTCOME OF PULMONARY BALLOON VALVULOPLASTY FOR THE TREATMENT OF PULMONARY VALVE STENOSIS

Bianca Lavoile<sup>1</sup>, Siddharth Gupta<sup>2</sup>, Richard Ringel<sup>3</sup>, Allen Everett<sup>3</sup>, Ram Bishnoi<sup>4</sup>

<sup>1</sup>Geisinger Medical Center, Danville, USA. <sup>2</sup>Rutgers New Jersey Medical School, Newark, USA. <sup>3</sup>Division of Pediatric Cardiology Johns Hopkins, Baltimore, USA. <sup>4</sup>Division of Pediatric Cardiology Geisinger Medical Center, Danville, USA

**Title:** Acute Outcome of Pulmonary Balloon Valvuloplasty for the Treatment of Pulmonary Valve Stenosis

**Introduction:** Balloon pulmonary valvuloplasty (BPV) is the primary treatment modality for congenital pulmonary stenosis. The Mid-Atlantic Group of Interventional Cardiology (MAGIC) registry, is a centralized database for submission, storage, and analysis of pediatric cardiac catheterization data.

**Aim:** To review data from the registry to assess technical aspects, safety, and effectiveness of BPV.

**Methods:** All patients who underwent BPV from 11/2004–3/2013, with data in the registry, were included. Data included: demographics, associated cardiac defects, fluoroscopy time, hemodynamics, assessments of pulmonary valve (PV), pulmonary annulus size, right ventricular pressure, Doppler gradient through the PV, balloon sizes, and procedurally related adverse events.

**Results:** Data from 349 patients was analyzed. Patient age ranged: 1 month to 57 years. Annulus size measured by echo ranged from 2–24mm (mean 9.08±3.96mm; median 8mm), versus angiography, 2.2 – 25mm (mean 9.89±4.2mm; median 8.65mm). Balloon to annulus ratio (BTA) was divided

into three groups: <1.2, 1.2 – 1.4, and ≥1.4. In 68.67% of patients, the BTA ratio was between 1.2 – 1.4. BTA ratio was further divided based on valve morphology. Mean BTA ratio in patients with dysplastic valves was 1.3±0.2, and 1.28±0.1 (*p*=0.526) in non-dysplastic cases. Mean pre-BPV peak pulmonary valve gradient (PVG) was 71±20.69 and post-BPV PVG was 30.75±20.69mmHg (*p*=0.0001). Average RV to aortic pressure ratio pre-BPV was 101.9±43.24%, and post-BPV was 59.22±22.77% (*p*=0.0001). The success rate in this cohort was 72.3%. Success rate in patients with dysplastic valves was 54.1% compared to 85.4% in non-dysplastic valves. Overall success in patients <3months of age was 76.7%. Average percent reduction (PR) in RV/AO ratio was 38.92%±18.02. Mean PR of RV/AO in patients ≤3months of age was 43.59±17.57%, compared to those >3months, 33.83±17.15% (*p*<0.0001). Mean PR reduction in the dysplastic group was 32.79±18.84%, compared to non-dysplastic group 43.52±16.25% (*p*<0.0001).

**Conclusions:** BPV is effective and safe in treating PV stenosis with good acute outcome. It's more effective in younger patients with non-dysplastic PV.

### 30. RETROPERITONEAL HEMORRHAGE ASSOCIATED WITH PEDIATRIC AND CONGENITAL CARDIAC CATHETERIZATION

Grace Wang<sup>1</sup>, Lisa Bergersen<sup>1,2</sup>, Ryan Callahan<sup>1,2</sup>, Jesse Esch<sup>1,2</sup>, Diego Porras<sup>1,2</sup>

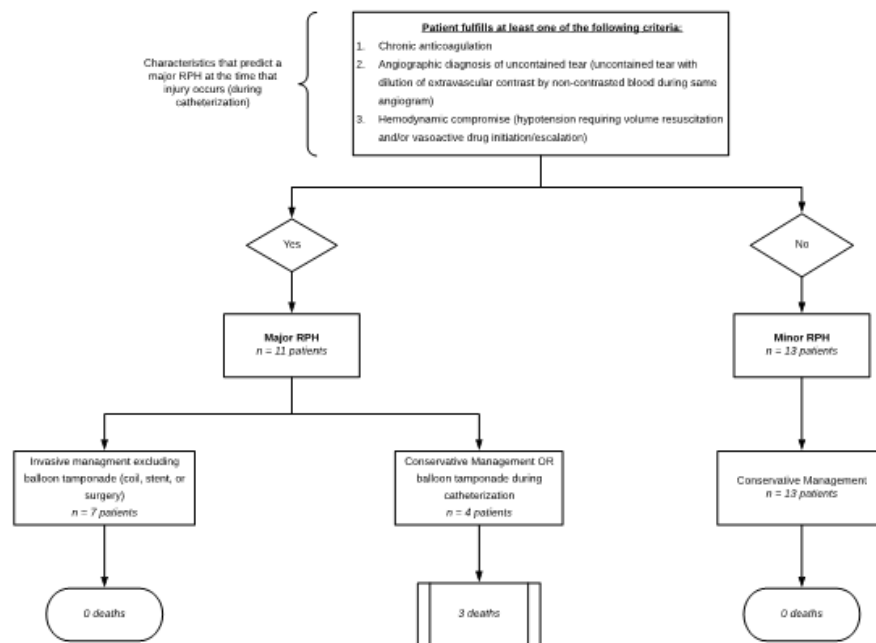
<sup>1</sup>Boston Children's Hospital, Boston, USA. <sup>2</sup>Harvard Medical School, Boston, USA

**Objectives:** We aimed to describe the clinical presentation, risk factors, management strategies, and outcomes of retroperitoneal hemorrhage (RPH) associated with cardiac catheterization in patients with pediatric and congenital heart disease.

**Background:** RPH is a rare but serious complication of cardiac catheterization. Data regarding incidence, management, and outcomes in this population is limited.

**Methods:** Retrospective review of all patients that underwent catheterization with femoral access at Boston Children's Hospital from January 2005 to July 2017 and had a documented RPH adverse event. Patients were further categorized as having major or minor RPH based on a modification of the widely used Standardized Bleeding Definitions for Cardiovascular Clinical Trials<sup>4</sup>.

**Results:** Among 15,187 catheterizations performed using femoral access during the study period, we identified 24 patients with RPH (0.16%), 11 major RPH (0.07%). 8 patients underwent invasive management (6 catheter-based, 1 surgical, 1 catheter-based and surgical). There were 3 deaths in the cohort (13%). By univariate analysis, patient and procedure related factors associated with major RPH included pre-procedure anticoagulation use (*p* = 0.03)



30. Figure 1. Balloon dilatation during PTMC.

**31. Table 1.** Hemodynamic Data with bold numbers showing final RPM.

Patient	RPM	CVP	PAS	PAD	PAM	PASat	PCWP	CI	SBP	DBP	MAP
1	2600	8	35	14	24	68	12	3.5	60	56	96
	<b>2760</b>		<b>35</b>	<b>12</b>	<b>23</b>	<b>71</b>	<b>11</b>	<b>4.0</b>	<b>63</b>	<b>59</b>	<b>96</b>
	2800	8	35	12	23	70	14	4.0	67	61	64
2	2040	8	36	12	23	68	12	3.5	60	56	96
	<b>1800</b>	<b>12</b>	<b>55</b>	<b>20</b>	<b>38</b>	<b>69</b>	<b>16</b>	<b>3.6</b>	<b>71</b>	<b>44</b>	<b>37</b>
3	2100	11	55	28	40	70	15	2.9	67	55	61
	2140		55	28	39	69	16	2.9			
	2180		50	25	38	71	12	3.2			
	<b>2220</b>		<b>50</b>	<b>25</b>	<b>36</b>	<b>71</b>	<b>12</b>	<b>3.2</b>			
4	<b>2440</b>	<b>14</b>	<b>33</b>	<b>16</b>	<b>23</b>	<b>73</b>	<b>13</b>	<b>2.6</b>	<b>88</b>	<b>49</b>	<b>65</b>
	2200		34	16	24	76	14	2.8	68	37	48
	2000		34	16	24	76	14	2.9	68	37	48
	1800	14	38	20	28	71	18	2.4	74	37	51
5	1800	9	39	14	24	74	19	2.6	71	66	68
	2540	6	28	12	20	87	10	3.2	71	67	68
	<b>2640</b>		<b>26</b>	<b>12</b>	<b>18</b>		<b>8</b>	<b>3.2</b>	<b>70</b>	<b>64</b>	<b>68</b>
6	2400	16	15	18	16	77	11	4.8	76	75	76
	2500				17		12				
	2600				15	78	11	5.0			
	<b>2700</b>				<b>14</b>		<b>10</b>				
7	2660	13	26	11	18	77	9	3.1	65	55	58
	<b>2700</b>	<b>11</b>	<b>27</b>	<b>10</b>	<b>17</b>	<b>79</b>	<b>9</b>	<b>3.3</b>	<b>66</b>	<b>62</b>	<b>64</b>
8	2400	8	22	12	16	76	9	4.8	83	70	76
	1800		21	12	16	74	10	4.2	82	51	66
	<b>2100</b>		<b>22</b>	<b>12</b>	<b>16</b>	<b>74</b>	<b>9</b>	<b>4.4</b>	<b>78</b>	<b>60</b>	<b>69</b>
9	2400	5	30	14	19	76	13	4.5	73	65	69
	<b>2460</b>		<b>42</b>	<b>24</b>	<b>31</b>	<b>64</b>	<b>22</b>	<b>3.0</b>	<b>101</b>	<b>86</b>	<b>92</b>
	2340		52	27	38	69	29	3.6	96	84	88
10	2260	15	26	13	19	77	11	4.3	70	64	64
	2100		25	13	20	74	13	3.7	77	62	66
	1800		32	15	24	70	18				
	<b>2160</b>	<b>15</b>	<b>28</b>	<b>16</b>	<b>20</b>		<b>15</b>		<b>79</b>	<b>63</b>	<b>68</b>
11	2300	3	17	8	12	79	8	3.6	88	53	63
	1800	2	21	12	16	76	14	3.1	92	54	68
	<b>2000</b>	<b>4</b>	<b>4</b>	<b>10</b>	<b>14</b>	<b>79</b>	<b>10</b>	<b>3.6</b>	<b>83</b>	<b>52</b>	<b>53</b>
12	<b>2600</b>	<b>5</b>	<b>28</b>	<b>5</b>	<b>9</b>	<b>68</b>	<b>4</b>	<b>2.9</b>			<b>62</b>
	2560	5	29	10	16	62	9	2.2			70



and interventional procedures ( $p = 0.04$ ). We identified three factors that, if present at the time of RPH diagnosis were associated with major RPH: (1) chronic anticoagulation, (2) angiographic diagnosis of uncontained tear, and (3) hemodynamic compromise (Figure 2). Among patients that had at least one of these three factors at the time of RPH diagnosis, death was correlated with receiving conservative management or balloon tamponade with no other invasive management (stenting, coil embolization, and/or surgery) ( $p = 0.02$ ).

**Conclusions:** RPH is a rare but potentially serious complication of cardiac catheterization in patients with pediatric and congenital heart disease. Patients with pre-procedure anticoagulation, angiographic diagnosis of uncontained tear, and hemodynamic compromise at time of diagnosis of RPH have a high risk of major RPH and death, so early and aggressive invasive management should be considered for this sub-group. Conservative management can be successful for patients that don't meet these criteria at time of diagnosis.

### 31. UTILIZATION OF HEMODYNAMIC ASSESSMENT OF PEDIATRIC HEART FAILURE PATIENTS ON CONTINUOUS FLOW VENTRICULAR ASSIST DEVICES

Subhrajit Lahiri<sup>1</sup>, Swati Choudhury<sup>2</sup>, Robert Loar<sup>2</sup>, Athar Qureshi<sup>2</sup>, Iki Adachi<sup>2</sup>, HariPriya Tunuguntla<sup>2</sup>

<sup>1</sup>Baylor College of Medicine, Houston, United Kingdom. <sup>2</sup>Baylor College of Medicine, Houston, USA

**Introduction:** Optimizing the continuous-flow ventricular assist device (CFVAD) setting is critical for successful long-term support. This is particularly true in pediatric patients supported with adult CFVAD given the inherent issues related to the patient-device size mismatch. We sought to evaluate our single-institutional experience in CFVAD optimization using the hemodynamic assessment.

**Method:** A retrospective analysis of all patients on CFVAD support who underwent right heart catheterization (including central venous pressure [CVP], Pulmonary artery pressure [PAP], pulmonary capillary wedge pressure [PCWP], and blood pressure [BP]), at Texas Children's Hospital (2013 to 2017) was performed.

**Results:** Twelve patients on CFVAD support had right heart catheterization performed for CFVAD optimization (8/12, 66%) to achieve balance between cardiac index and right heart function or assessment of explant (4/12, 33%). Dilated cardiomyopathy (7/12, 60%) was the most common diagnosis. The median age at catheterization was 11

years (IQR 8, 17). Median time since CFVAD placement was 318 days (IQR 200, 900). Median baseline speed of device was  $2333 \pm 253$  rotations-per-minute (RPM). Eight patients (61%) had normal CVP ( $10 \pm 4$  mmHg) and PCWP ( $11 \pm 3.7$  mmHg) at their original RPM settings. Hemodynamic data was found to be recorded anywhere between 2 to 4 speed settings. Six patients (50%) had their CFVAD speed increased to achieve optimal balance of cardiac index and right heart function. In 4 (33%) patients CFVAD speed was decreased for case-based hemodynamic optimization or explant. For the remaining two patients speed was not changed as they were found to be already at their optimal hemodynamics. (Table 1) On follow up, 5 patients underwent heart transplant; CFVAD was successfully explanted in 2 patients; and 5 patients remains on CFVAD support (median 3.3 years). Although all patients were on anticoagulation there was no post-procedural bleeding.

**Conclusion:** Use of hemodynamic assessment in pediatric patients with CFVAD support provides objective means of optimizing RPM, and has the potential to guide medical management.

### 32. OUTCOME OF NORWOOD PATIENTS HAVING CARDIAC CATHETERIZATION WHILE ON ECMO SUPPORT

Haysam Baho, Mohamed Mashaly, Jameel Al-Ata, Amjad Kouatly, Omar Galal

King Faisal Specialist Hospital, Jeddah, Saudi Arabia

**Introduction:** Norwood repair of hypoplastic left heart syndrome is a complex procedure which occasionally requires extracorporeal membrane oxygenation support (ECMO). Our aim was to evaluate the outcome of those patients who require cardiac catheterization while on ECMO

**Methods:** Retrospective review of all Norwood repair patients placed on ECMO and had catheterizations performed at a single tertiary care center between 2005-2017. Demographic data, diagnosis, catheterization type, surgical shunt used and days to decannulation were collected. Primary outcome was in-hospital mortality. Outcome was calculated according to Catheterization results. These were categorized into 4 types: New unsuspected findings (group 1), Confirmed suspected findings (group 2), Ruled out suspected findings (group 3) and needed interventional procedures (group 4). Outcome was also calculated according to shunt type.

**Results:** 20 patients out of 142 Norwood procedures performed were placed on ECMO (14%) with a total mortality rate of 70%. 12 BT shunt (mortality rate 75%) vs. 8 Sano (Mortality rate 62%). 16 catheters performed, 8 group 1, 4 group 2, 4 group 3 and 8 group 4 with a mortality rate of 50%, 75%, 100% and 62% respectively. 10/12 BT shunt group had catheter, 7 interventional and 3 none interventional with a mortality rate of 71% and 66% respectively. 6/8 Sano group had catheter, 3 interventional and 3 none interventional with a mortality rate of 33% and 100%.

**Discussion:** Patients who need ECMO Post Norwood procedure have high mortality rate (70%) which is consistent with other studies. While performing catheter and/or an intervention is safe and was performed with no complications, it did not improve outcome in most patients. Those who had a catheter finding confirming a post-op echo adverse finding and had a therapeutic intervention may have a better prognosis. This was more evident in the Sano shunt group (33%). Patients who did not have an indication for intervention had a worse outcome due to a none anatomical etiology causing clinical worsening but not responding to medical treatment such as pulmonary hypertension. Sano shunt patients had lower rate of interventions and may have a better outcome. The number of patients is small to have statistical significance.

#### 34. A RARE CAUSE OF CYANOSIS IN CHILDREN, COMPLEX PULMONARY AV FISTULA-OCCLUSION WITH ADO-II DEVICE

Ali Baykan<sup>1</sup>, Suleyman Sunkak<sup>1</sup>, Onur Tasci<sup>1</sup>, Cagdas Vural<sup>1</sup>, Ozge Pamukcu<sup>1</sup>, Kazim Uzum<sup>1</sup>, Nazmi Narin<sup>2</sup>

<sup>1</sup>Erciyes University Medical Faculty, Kayseri, Turkey. <sup>2</sup>Erciyes University Medical Faculty Erciyes University Medical Faculty, Kayseri, Turkey

**Pulmonary arteriovenous (AV) malformations** are rare vascular anomalies of the lung, in which abnormally dilated vessels provide a right-to-left shunt between pulmonary artery and vein.

Despite most patients being asymptomatic, some may have cyanosis and dyspnea. Age of presentation can be extremely variable from infant to old age in proportion to the size of malformation.

Herein, we reported a girl with pulmonary AV malformation treated with trans-catheter method.

**Case:** A 7 months old age girl was referred for cyanosis. The patient had no complaints other than central

cyanosis. Other physical examination findings were normal. Transcutaneous oxygen saturation was measured as 80-82%. Hemoglobin level was 10.4 g/dl. Chest x-ray and echocardiographic examination showed no abnormal findings. CT angiography revealed a fistula in left lung lower lobe.

The fistula was planned to be closed by transcatheter method. In catheterization laboratory, hemodynamic evaluation was performed. Pulmonary artery pressure was in normal range. When pulmonary angiography performed pulmonary AV fistula was seen in left lung lower lobe. There were 4 arterial branches and venous return was directly to left atrium. The balloon occlusion test resulted in significant elevation on oxygen saturation. The main two branches that feed the fistula were closed with 6x6 ADO II and 5x6 ADO II. In the control angiogram, a marked reduction in fistula blood flow was noticed and saturation was increased significantly (% 94). Remained two smaller vessels planned to be closed in the following months, because of prolonged procedure time and for not exceeding the maximum radioopaque and radiation doses.

**Discussion:** Definite therapy for pulmonary AV malformations are therapeutic embolization or surgical resection.

Transcatheter technique is a safety treatment choice instead of major surgery. Long-term follow-up evaluation has shown potentially serious complications in 2% of patients treated with transcatheter occlusion. Symptomatic recanalization was observed with 0.5% of procedures. In this case we used Amplatzer duct occluder II for branches occlusion. We occluded only 2 branches for prolonged procedure time and not for exceeding the maximum radioopaque and radiation doses. We planned to follow up patient with clinical symptoms. If necessary, re-evaluation and treatment with angiography may be considered.

#### 35. USING IN VITRO MODEL TO ASSESS STENT-STENT INTERACTION IN PATIENTS WITH CORONARY ARTERY COMPRESSION

Jenny E. Zablah, Rachel Fry, Neil Wilson, Michael Ross, Gareth Morgan

Children's Hospital of Colorado, Aurora, USA

**Background:** One rare but potentially devastating complication of percutaneous pulmonary valve implantation is coronary artery compression due to pre-stent or prosthetic valve placement in the right ventricular outflow tract. In these cases, percutaneous stent implantation in the coronary artery is a potential bailout option, but the

structural integrity of the coronary stent in this environment is uncertain.

**Methods:** An invitro model was constructed to represent the interaction between coronary and outflow tract stents. One AndraStent, four CP stents, one Edwards SAPIEN XT valve stent and combination of AndraStent with CP stent were incrementally compressed against a 4mm coronary stent. The test apparatus designed to compress the stents was constructed from a linear slide table with custom Aluminum wall mounts. The stent diameters were measured with a code developed in MATLAB. The relative decrease in diameter was calculated for each stent over a range of compression.

**Results:** In all combinations of stents, the coronary stent lost significant more relative diameter when compared with the larger outflow tract stents. At the maximum compressive amplitude, the average percent decrease in diameters of the AndraStent versus the coronary stent were  $8.1\pm 0.8\%$  and  $36.5\pm 11.1\%$  respectively. For the CP stent versus coronary stent, was  $5.7\pm 0.8\%$  and  $45.2\pm 9.2\%$  respectively. Combination CP stent within the AndraStent, versus the coronary stent were  $3.9\pm 0.5\%$  and  $54.5\pm 4.2\%$  respectively. Edwards Sapien stent versus the coronary stent were  $1.7\pm 0.1\%$  and  $68.9\pm 1.1\%$  respectively. Deformation of the coronary stents varied significantly depending on the outflow tract stents with greater than 1mm of compression. The coronary stent had the greatest relative decrease in diameter when interacting with the Edwards SAPIEN XT valve.

**Conclusion:** The Edwards Sapien XT valve stent has the greater relative radial force demonstrated by the greater relative decrease in diameter of the coronary stent at final compressive amplitude. These results support the concern that coronary stenting in the presence of coronary compression by an outflow tract stent implantation is likely to result in a significantly compromised coronary lumen; however, it may still be the best lifesaving option in the face of potentially catastrophic acute ischaemia.

### 36. OUTCOMES OF TRANSCATHETER PULMONARY ARTERY REHABILITATION IN PATIENTS WITH SYNDROMIC PULMONARY ARTERIOPATHIES

Scott Leopold<sup>1</sup>, Patrick Sullivan<sup>1</sup>, Cheryl Takao<sup>1</sup>, Sarah Badran<sup>1</sup>, Frank Ing<sup>2</sup>

<sup>1</sup>Children's Hospital Los Angeles, Los Angeles, USA. <sup>2</sup>University of California, Davis, Sacramento, USA

**Background:** There are few reports in the literature on the outcomes of transcatheter pulmonary artery rehabilitation in patients with syndromic pulmonary arteriopathies.

**Methods:** Single-center review of pts with syndromic pulmonary arteriopathies undergoing catheterization from 2005 to 2017.

**Results:** 27 pts with syndromic pulmonary arteriopathies [Williams (n=11), Non-Williams familial arteriopathy (n=8), Alagille (n=7), and infantile arterial calcinosis (n=1)] underwent initial cath procedures for evaluation of their PA anatomy at a median age and wt of 19 mo and 10.7 kg. 17 pts underwent interventional cath procedures, 10 of whom had undergone prior surgical pulmonary arterioplasty.

At initial intervention, 37 vessels (17 central, 20 peripheral) underwent balloon angioplasty and 17 vessels (9 central, 8 peripheral) underwent stent implantation. Cutting balloons were used once. Mean minimal PA diameter increased from  $2.34\pm 1.05$  to  $3.75\pm 1.51$  mm ( $p < 0.0001$ ). RV:systemic pressure ratios were  $0.93\pm 0.42$  initially and  $0.74\pm 0.27$  post intervention ( $p=0.14$ ). Stent implantation was acutely superior to balloon angioplasty in all genetic diagnoses.

40 vessels in 17 pts underwent 96 cath reinterventions [46 repeat angioplasties, 20 stent implantations after initial angioplasty, 26 repeat stent dilations, and 4 repeat stent implantations] over a median follow up time of 26 mo (range 0-113). Pts on average had a reintervention every 15.8 mo. In-stent restenosis occurred after 54% of stent implantations and restenosis occurred after 76% of balloon angioplasties. 3 pts were referred for post intervention surgical PAplasty.

At most recent catheterization, among pts with follow up, mean minimal PA diameter had increased from an initial  $2.36\pm 1.30$  to  $4.17\pm 2.04$  mm ( $p < 0.0001$ ) and RV:systemic pressure ratio decreased from an initial  $0.94\pm 0.43$  to  $0.68\pm 0.25$  ( $P = 0.015$ ). There was 1 stent embolization in a Williams pt, 3 cases of pulmonary hemorrhage in 2 Alagille pts, no emergent operations, and no procedural deaths.

**Conclusions:** Transcatheter PA rehab, often coupled with surgical PA plasty, can safely and effectively reduce RV:DAO pressure ratios and result in branch PA growth in pts with syndromic pulmonary arteriopathies.

### 37. AMPLATZER DUCT OCCLUDER II IS AN IDEAL DEVICE FOR CLOSING CONGENITAL GERBODE DEFECTS

*I B Vijayalakshmi*

BMC&RI Super Specialty Hospital (PMSSY), Bengaluru, India

**Background:** Congenital left ventricle to right atrial communications (Gerbode defects) are extremely rare (0.08%) type of ventricular septal defects. They were traditionally closed by surgery in the past. There are few case reports and small series of acquired and congenital Gerbode defects, closed with various types of devices.

Aim of our study is to assess the feasibility, efficacy, and complications of transcatheter closure of congenital Gerbode defects with Amplatzer duct occluder II (ADO II).

**Material and Results:** Thirteen consecutive cases of Gerbode defects, age ranging from 10 months to 16 years (mean 6.7 years), weight ranging from 6.5 kg to 34 kg (mean 19.3 kg), were diagnosed on transthoracic echocardiography. The left ventricular angiogram done in AP, RAO view with 10° cranial angulation illustrated the contrast from LV opacifying the right atrium (RA). The defect was crossed by over the wire technique by 0.0 25" Terumo guide wire through the retrograde approach from aorta. 4F Cooks Shuttle sheath was passed over the guide wire anchored in SVC. The distal retention skirt was released in RA and the whole system was pulled under fluoroscopy and TTE guidance to LV to release the proximal disc. Transcatheter closure of Gerbode defects was done successfully through retrograde approach with ADO II. No aortic or tricuspid regurgitation or residual shunt occurred in any of the patients. One patient developed transient complete heart block needing temporary pacing for 48 hours and steroids for five days.

**Discussion:** The soft low profile, easily trackable ADO II appears to be ideal for closure of Gerbode defects, as the central cylinder fits in the defect and the soft retention discs on either side, without polyester material, do not impinge on either aortic, mitral, or tricuspid valve. We report the successful transcatheter closure of thirteen cases of congenital Gerbode defects with ADO II.

**Conclusion:** Transcatheter closure of congenital Gerbode defects with ADO II is safe, effective, and an attractive alternative to surgical closure. ADO II appears to be tailor made for Gerbode defects, as the success rate is very high and complication rate is very low.

### 38. ROLE OF TRANSCATHETER INTERVENTION IN DIVIDED RIGHT ATRIUM

*I B Vijayalakshmi*

BMC&RI Super Specialty Hospital (PMSSY), Bengaluru, India

Cor triatriatum Dexter is an extremely rare congenital anomaly (0.025%), in which the right atrium is divided into two chambers by a septum, diagnosed on autopsy in the past. We describe antemortem diagnosis, by 2D transthoracic echocardiography with agitated saline contrast echocardiography and inferior venacava or superior venacaval venography. For the first time we report a novel method of transcatheter balloon disruption of membrane along with the interventions for associated lesions, to reduce morbidity and mortality.

**Objective:** To describe the importance of transthoracic echocardiography with agitated saline contrast echocardiography and to assess the feasibility and efficacy of transcatheter interventions in divided right atrium.

**Material and Results:** Out of sixteen consecutive patients of divided right atrium diagnosed with transthoracic echocardiography with agitated saline contrast echocardiography, five patients who underwent transcatheter balloon disruption of membrane and other interventions formed the material for study. Three patients were boys and two were girls, age ranged between 3 to 17 years, median age was 10 years. Three patients presented with exertional dyspnea and two were asymptomatic. Two who had rheumatic heart disease with mitral stenosis underwent balloon mitral valvuloplasty and one case with atrial septal defect without pulmonary artery hypertension underwent device closure. For the first time in the world we present the transcatheter intervention in divided right atrium.

**Conclusion:** Cor triatriatum Dexter is not benign as mortality occurs due to pulmonary embolism. Timely diagnosis with transthoracic echocardiography with simple agitated saline contrast echo followed by balloon disruption can prevent cyanosis, pulmonary artery hypertension, morbidity and mortality.

### 39. DEVICE CLOSURE IN RAREST OF RARE CONDITIONS

*I B Vijayalakshmi*

BMC&RI Super Specialty Hospital (PMSSY), Bengaluru, India

Amplatzer Duct Occluder II (ADO II) was especially designed for closing long ducts in infants. There are few reports of "off-label" use of ADO II in non-ductal positions.

Aim of our study is to evaluate the feasibility and efficacy of ADO II in non ductal position

**Material and Results:** 102 cases of VSDs and one case each of aorta right ventricular, aorta right atrial tunnel, infantile hepatic endothelioma, aortopulmonary window, paravalvar leak, perforation of LV, common iliac artery aneurysms were closed by retrograde transcatheter method with ADO II, formed the material for this prospective study. Age: 45 days old neonate to 30 years (mean 9.4 years). 74 perimembraneous VSDs, 14 muscular VSDs, 13 Gerbode defects, one midmuscular VSD with dextrocardia, were closed with ADO II of various sizes. The shortest fluoroscopic time was 4.2 min, mean was  $8.4 \pm 4.1$  min. In six cases there was initially a small residual shunt which had closed on three months follow up. Eleven cases developed transient complete heart block which resolved on medical management and only patient needed temporary pacing.

**Discussion:** ADO II has a very low profile, and is easily trackable as there is no polyester material in it and can be easily delivered through 4-5F guiding catheter, needs very short fluoroscopic time as artero-venous (AV) loop is not needed in this retrograde approach. Cost is 1/3 the cost of regular ventricular septal occluder. However, it is not useful in VSDs measuring more than 6 mm and in those with insufficient aortic rim. Trackability of ADO II is excellent in rare, tortuous tunnels.

**Conclusion:** ADO II is efficacious in non ductal position. Procedure time and the cost are significantly lesser than regular devices. The success rate is very high and complication rate is very low.

#### 40. TIMING OF THE EVALUATION OF THE BALLOON PULMONARY VALVULOPLASTY EFFECTS IN NOONAN SYNDROME.

*Masahiro Kamada, Naomi Nakagawa, Yukiko Ishiguchi, Yuji Moritoh, Takayuki Suzuki, Kengo Okamoto*

Dep. of Pediatric Cardiology, Hiroshima City Hp., Hiroshima, Japan

In most center, balloon pulmonary valvuloplasty (BPVP) is the first choice for the treatment of pulmonary valvular stenosis (PVS). Balloons with a diameter approximately 1.25x times that of the pulmonary valve (PV) annulus are recommended. Although balloons 1.4-1.5x the PV diameter may be used to dilate dysplastic PVs, BPVP is often ineffective and surgical valvotomy is required.

**Cases:** We experienced 3 cases of Noonan syndrome with dysplastic PVs. In the first 2 cases (cases 1, 2: 2.5-, 1.3-year old boys), BPVP was performed with a balloon 1.25 x the PV annulus. The results were unsatisfactory and propranolol was started. However, the gradients decreased even after propranolol was stopped. The maximum gradient on echocardiography (Echo-G) decreased from 64 to 24 and 19mmHg at 2 and 5 years respectively in case 1, and from 39 to 24 and 18mmHg in 1 and 2 years respectively in case 2.

In case 3 (2-month old boy), the first BPVP with a 1.2x the PV was not effective. The maximum gradients on catheterization (Cath-G) decreased from 48 to 37mmHg and Echo-G decreased from 65 to 61 mmHg. Based on experiences, we awaited improvement. However, as the Echo-G increased to 80mmHg at 1 year, a second BPVP (1.26x the PV) was performed. The Cath-G increased from 47 to 56mmHg because of reflex subvalvular stenosis. After 6 months on propranolol, the Echo-G stabilized at 58mmHg. A third BPVP (1.39x the PV) improved Cath-G from 49 to 32 mmHg and Echo-G from 48 to 30mmHg at 1 year. (261)

PV thicknesses was measured on cine-angiography. The anterior/posterior leaflets (PV annulus) measured 1.7/2.0 (10) mm, 1.9/1.9 (10.4) mm and 1.3/1.5 (13.0) mm on the first, second, and third cineangiograms respectively. The thicknesses/annulus ratio of the 2 leaflets decreased from 0.37 to 0.22 over time and motion improved.

**Conclusion)** In PVS with dysplastic PV, thick and redundant valves generate resistance in a small PA and mask the effects of BPVP. The true effects of BPVP require a wait of the pulmonary artery growth at least  $\geq 1$  year prior to evaluation.

#### 41. DOUBLE MELODY VALVE (VALVE-IN-VALVE) IMPLANTATION IN PULMONARY AND TRICUSPID VALVE POSITION. : A UNIQUE CASE

*Ashish Garg, Satinder K. Sandhu*

University of Miami/Jackson Memorial Hospital, Miami, USA

**Case presentation:** A 66 year old female with congenital pulmonary valve stenosis requiring pulmonary valvotomy at 12 years of age. Her clinical course was complicated with heart failure from severe pulmonary and tricuspid valve regurgitation. She underwent placement of a #25mm Bioprosthetic valve in the pulmonary (Pericardial prosthesis) and tricuspid valve (St. Jude) position at 48 and 60 years of age. Six years after replacement of tricuspid valve she again developed exercise intolerance (NYHA Class

III) and pedal edema. An echocardiogram demonstrated moderate pulmonary valve stenosis (PISG 57 mmHg) and tricuspid stenosis (mean gradient 10 mmHg). At cardiac catheterization there was a 56 mmHg gradient across the pulmonary valve and a 12 mmHg gradient across the tricuspid valve with elevated right atrial (RA) pressure of 18 mmHg.

**Procedure Description:** A balloon was inflated across the pulmonary valve and coronary angiogram was done. Balloon sizing of the pulmonary valve and the tricuspid valve was performed. A 22 mm Melody Medtronic Valve<sup>®</sup> was mounted on a 22-mm proprietary delivery catheter (Ensemble NU10, Medtronic), advanced through the femoral vein, positioned and implanted across the bioprosthetic pulmonary valve (valve-in-valve). The residual systolic pressure gradient across the pulmonary valve was 7 mmHg. A lunderquest wire was positioned in the left pulmonary artery, a second 22 mm Melody Medtronic Valve<sup>®</sup> was placed on 22-mm delivery system. The delivery system was positioned across the bioprosthetic tricuspid valve and a Melody Medtronic Valve was implanted. The residual gradient across the tricuspid valve was 4 mmHg and the RA pressure was 11 mm Hg. At 1 month follow-up, she had no edema, improved exercise tolerance (NYHA Class II) which improved to NYHA class I at 3 month follow up. Echocardiogram demonstrated no stenosis or gradient across the pulmonary valve and 6 mmHg gradient across the tricuspid valve.

Discussion: Bioprosthetic valves often require reintervention due to degeneration. Surgical intervention has its associated morbidities. We present a successful and unique case of transcatheter implantation of double valve in valve in pulmonary and tricuspid valve position.

#### 42. TRANSCATHETER DEVICE CLOSURE OF CARDIAC SHUNT LESIONS WHEN FEMORAL VEIN IS INACCESSIBLE

*Rajasekaran Premsekar*

Dr.Kamakshi Memorial Hospital, CHENNAI, India

Femoral venous access for transcatheter device closure is not feasible when the inferior vena caval interruption is either congenital with multiple small venous channels draining in to the azygous system or when it is acquired owing to thrombosis from previous interventions. The prevalence of interruption in inferior vena cava (IVC) is reported at 0.2-3%. While IVC interruption with azygous continuation to superior vena cava provides a circuitous channel for cardiac catheterisation and intracardiac interventions,

rarely the caudal venous drainage occurs through multiple small venous channels which denies femoral venous access to the heart.

We report three cases where successful transcatheter device closure was performed in the setting of inaccessible femoral venous access to the heart. The first was in a 4 years old female child with a large secundum atrial septal defect (ASD) and IVC interruption with multiple small, tortuous venous channels coursing cranially to the azygous vein. The defect was closed with a 20mm septal occluder (Lifetech Scientific Co Ltd) from the jugular access. The second case was an one year old female child with a 8mm perimembranous Ventricular septal defect (VSD), whose IVC interruption was diagnosed during the catheterisation procedure. The VSD was closed retrograde with a 10mm symmetrical perimembranous VSD occluder (Lifetech Scientific Co Ltd) through a 7 French delivery sheath. The third case was in a 17 years old male patient who had undergone surgical patch closure of a large aortopulmonary window during infancy and presented with a small 4mm residual shunt and was detected to have bilateral thrombosed femoral veins during the procedure. The defect was closed with a 5mm Amplatzer duct occluder II (St Jude Medical) from the jugular access.

We conclude that judicious choice of occluder and route ensures successful transcatheter device closure in the absence of femoral venous access.

#### 43. EVALUATION OF THE INFLUENCE OF SINGLE VENTRICLE MORPHOLOGY ON THE QUALIFICATION FOR FONTAN COMPLETION.

*Jacek Kusa<sup>1,2</sup>, Pawel Czesniewicz<sup>2</sup>*

<sup>1</sup>Medical University of Silesia, Katowice, Poland. <sup>2</sup>Regional Specialist Hospital in Wroclaw, Research and Development Centre, Wroclaw, Poland

**Objectives:** The purpose of this paper is to report our experience in interventional treatment of patients before last stage of Fontan palliation and to focus on the influence of single ventricle morphology on the need for percutaneous interventions.

**Background:** The staged-Fontan operation is widely used to treat patients with a single functional ventricle. Cardiac catheterization remains a basic tool in the evaluation of haemodynamic data before last stage of Fontan palliation. A lot of percutaneous interventions can be successfully performed during this procedure. We hypothesize that the

morphology of the dominant ventricle may predispose to the need to perform some percutaneous interventions.

**Methods:** We analyzed medical data of 77 patients aged  $3,8 \pm 3,3$  years (range: 0,8-17,8) before last stage of Fontan palliation who underwent cardiac catheterization procedures in our institutions from 2013 to 2016. Patients were divided into two groups: with left ventricular morphology (LV) and right ventricular morphology (RV). Anthropometric measurements, haemodynamics variables, morphometric parameters and number of percutaneous procedures were compared in both groups of patients.

**Results:** Anthropometric measurements of LV and RV groups were not statistically significant. Mean pulmonary artery pressure and pulmonary vascular resistance were similar in both groups. RV patients had higher end-diastolic pressure (11,65 mmHg vs. 10,21 mmHg  $p < 0,05$ ) and smaller pulmonary arterial diameters with less favourable McGoon ratio (1,56 vs. 2,01  $p < 0,05$ ). For this reason, those patients required a larger number of percutaneous interventions (3,18 vs. 1,79  $p < 0,05$ ).

**Conclusion:** Left ventricle anatomy of single ventricle in patients before last stage of Fontan procedure is associated with significantly better diastolic function. They have better haemodynamic and morphometric conditions to complete Fontan procedure and require less interventions.

#### 44. THE IMPACT OF ECHOCARDIOGRAPHIC AND HAEMODYNAMIC PARAMETERS ON FORMATION OF AORTO-PULMONARY COLLATERALS IN PATIENTS AFTER THE GLENN PROCEDURE.

Pawel Czesniewicz<sup>1</sup>, Jacek Kusa<sup>2,1</sup>

<sup>1</sup>Regional Specialist Hospital in Wroclaw, Research and Development Centre, Wroclaw, Poland. <sup>2</sup>Medical University of Silesia, Katowice, Poland

**Objectives:** Aorto-pulmonary collaterals are common in patients after Glenn shunt and number of studies have shown that they might be associated with development of heart failure and adverse outcome after the Fontan operation. The exact cause of formation of those vessels remains unknown. In this study we analyse the impact of echocardiographic and hemodynamic parameters on formation of aortopulmonary collaterals.

**Methods:** We analysed data of 77 patients aged  $3,8 \pm 3,3$  years (range: 0,8-17,8) with single ventricle anatomy after Glenn shunt who underwent cardiac catheterization from 2013 to 2016 at our institutions. We identified 70 significant

aorto-pulmonary collaterals in 52 patients. All collaterals were embolized. Imaging and hemodynamic data were compared in two groups: patients with aorto-pulmonary collaterals versus patients without aorto-pulmonary collaterals.

**Results:** Echocardiographic measurements did not reveal any group differences. Pulmonary arteries were equally developed in both groups. Patients with aorto-pulmonary collaterals had lower mean pulmonary artery pressure (13,15 mmHg vs. 15,2 mmHg,  $p < 0,05$ ) and end diastolic pressure (10,63 mmHg vs. 12,16 mmHg,  $p < 0,05$ ). They had also lower pressure gradient between ascending and descending aorta (3,5 mmHg vs. 6,5 mmHg,  $p < 0,05$ ). Patients without aorto-pulmonary collaterals and with higher pressure gradients in aortic isthmus had more often aorto-aortic collaterals. The remaining haemodynamic parameters did not show statistical significance

**Conclusion:** Hypoperfusion of the pulmonary vascular bed contribute the development of aorto-pulmonary collaterals.

The higher gradient in the aortic isthmus can have a beneficial effect by inhibiting the formation of aorto-pulmonary collaterals. Because aorto-pulmonary and aorto-aortic collaterals often arise from the same vessels we hypothesise that these vessels preferably participate in the creation of collateral circulation between ascending and descending aorta rather than in formation of aorto-pulmonary collaterals.

#### 45. EMBOLIZATION AND SUCCESSFUL TRANSCATHETER RETRIEVAL OF CERAMIC COATED PDA DEVICES: ARE WE SIZING THEM WRONG?

Supratim Sen<sup>1</sup>, Sneha Jain<sup>1</sup>, Bharat Dalvi<sup>1,2,3</sup>

<sup>1</sup>SRCC NH Children's Hospital, Mumbai, India. <sup>2</sup>HN Reliance Hospital, Mumbai, India. <sup>3</sup>Nanavati Hospital, Mumbai, India

PDA device closure is the commonest pediatric cardiac intervention, with excellent outcomes. The Amplatzer Duct Occluder and similar devices, especially the ceramic coated PDA devices, are a routine choice in most PDAs.

We present two cases of spontaneous embolization of ceramic coated PDA devices despite the initial angiographic result appearing adequate.

The 1st case was a 15-month, 8.2 kg female child with a Krichenko Type E PDA with a small ampulla and a slightly tubular PA end measuring 2.5 mm. A Lifetech Cera 4/6 mm

Duct Occluder was deployed and released with a satisfactory echocardiographic and angiographic result. However, there was spontaneous embolization to the descending aorta after 2 hours, necessitating transcatheter retrieval of the device from the venous end with a Gooseneck snare, and PDA occlusion with a 6/8 Cera Duct Occluder.

The 2nd case was 6-month, 5.5 kg, with a Krichenko Type E PDA with a tubular PA end. The Lifetech Cera 4/6 mm Duct Occluder chosen initially embolized to the descending aorta soon after release, requiring transcatheter retrieval from the arterial side and PDA occlusion with a 6/6 mm ADO2 device.

The lower profile and softer design of the ceramic coated devices generally allows a smaller delivery sheath size and easy deployment, which is advantageous in small children. Our standard sizing dictum for the ADO and similar devices has been 2 mm above the narrowest PA end. However, in slightly tubular PDAs as ours, there may be no protrusion of the PA end of the device from the PDA, with no consequent distal splay of the PA end, and a possible recoil during release. Also, as the softer ceramic devices would exert less perpendicular stenting forces on the ductal wall, the only stabilizing segment is the retention skirt. Hence, downward descending aortic systolic forces on the retention skirt could potentially dislodge the device.

We conclude that perhaps the softer ceramic coated devices need to be oversized by one size to form a tighter waist, or Nitinol ADO type devices or even ADO2 or vascular plugs may be preferable devices for slightly tubular ducts.

#### **46. ESTIMATING RADIATION EXPOSURE DURING PEDIATRIC CARDIAC CATHETERIZATION; A POTENTIAL FOR RADIATION REDUCTION WITH AIR GAP TECHNIQUE**

*Reid Chamberlain, Alexis Shindhelm, Gregory Fleming, Kevin Hill*

Duke University, Durham, USA

**Background:** Patients with congenital heart disease frequently undergo cardiac catheterization exposing them to harmful ionizing radiation. The air gap technique (AGT) is a novel approach to radiation dose optimization during cardiac catheterization where an "air gap" is used in place of an anti-scatter grid to reduce dosing. This technique remains largely untested in children and may confer a beneficial reduction in radiation exposure. We hypothesize the AGT has differential effects on absorbed radiation

dose depending on patient size with most benefit in larger patients and with lateral imaging where scatter irradiation is greatest.

**Methods:** Fluoroscopy and cineangiography were performed using a Phillips Allura Fluoroscope on tissue simulation anthropomorphic phantoms (CIRS, Norfolk, VA) ages 0, 5 and 15 years. Testing was first performed using a standard imaging approach (anti-scatter grid removed in the neonate and 5 year; kept in place for the teenager). Images were then repeated using the air gap technique, constructed so as to appear identical to the baseline images. Air Kerma per 1000 frames was measured and input to Monte Carlo simulation software (PCXMC, Amsterdam, Netherlands) to estimate effective dose in millisieverts. Objective image assessments performed using image quality phantom (CIRS, Norfolk, VA).

**Results:** Effective radiation doses for the neonate and 5 year phantom were similar or increased when using the AGT compared to standard imaging for both PA and lateral imaging when using recommended imaging guidelines. When the anti-scatter grid is placed for the 5 year phantom, the effective radiation dose increases an average 53% for fluoroscopy and 55% for cineangiography, thus exceeding AGT effective radiation doses by 46% and 53%, respectively. In the teenage phantom the AGT reduced effective doses by 21% for fluoroscopy and 28% for cineangiography. The AGT increased geometric magnification but the difference in image blur and contrast was not significant for any of the phantom imaging.

**Conclusions:** The air gap approach is an effective technique for dose reduction in larger patients where scatter irradiation is significantly increased, particularly when higher magnification is needed.

#### **47. THE INCIDENCE OF RECURRENT LARYNGEAL NERVE INJURY RESULTING IN VOCAL CORD PARALYSIS FOLLOWING INTERVENTIONAL PEDIATRIC CATHETERIZATION PROCEDURES: AN INFREQUENT AND UNRECOGNIZED ENTITY.**

*Howard Weber<sup>1</sup>, Athar Qureshi<sup>2</sup>, Rajiv Devanagondi<sup>3</sup>, Sara Trucco<sup>4</sup>, Agustin Rubio<sup>5</sup>, Jaana Pihkala<sup>6</sup>, Mark Law<sup>7</sup>, John Bass<sup>8</sup>, Lourdes Prieto<sup>9</sup>, Daniel Levi<sup>10</sup>, Daniel Turner<sup>11</sup>*

<sup>1</sup>Penn State Hershey Childrens Hospital, Hershey, USA. <sup>2</sup>Texas childrens Hospital, Houston, USA. <sup>3</sup>University of Rochester Medical Center, Rochester, USA. <sup>4</sup>Pittsburgh Childrens Hospital, Pittsburgh, USA. <sup>5</sup>Seattle Childrens Hospital, Seattle, USA. <sup>6</sup>Helsinki University Childrens Hospital, Helsinki, Finland. <sup>7</sup>University of Alabama at Birmingham, Birmingham, USA. <sup>8</sup>University of Minnesota, Minneapolis, USA. <sup>9</sup>Nicklaus Childrens



Hospital, Miami, USA. <sup>10</sup>Mattel Childrens Hospital, Los Angeles, USA. <sup>11</sup>Childrens Hospital of Michigan, Detroit, USA

In 2015, Children's National Medical Center reported a 1.1% incidence of vocal cord paralysis (VCP) secondary to recurrent laryngeal nerve injury (RLNI) following congenital heart surgery in 3036 patients and multifactorial in origin due to its location during aortic arch, left pulmonary artery (LPA) and patent ductus arteriosus procedures (PDA). Recovery of VCP varies between 0-82%. The incidence of left RLNI and VCP following pediatric interventional catheterization procedures has been reported as isolated cases. We queried member institutions of the CCISC (Wayne State University) regarding RLNI and VCP following PDA closure, LPA stenting or both procedures. Eleven centers submitted data demonstrating a significantly lower incidence of VCP following PDA closure (N=3680) or LPA stenting (N=1208) vs the reported surgical incidence. When both procedures were eventually performed in the same patient (N=15), VCP incidence was significantly increased compared to the reported surgical incidence, isolated PDA closure or LPA stenting. VCP incidence was significantly increased post LPA stenting vs PDA closure. Symptoms resolved in 8/9 pts by 2 yrs.

Proce- dure	Proce- dure	Statistics	OR	95% Conf Interval	P-Value
PDA (1/3680 = 0.03%)	LPA (5/1208 = 0.41%)	Mantel	10.1	(1.54, 884)	0.007
PDA (1/3680 = 0.03%)	PDA + LPA (3/15 = 20.0%)	Mantel Haenszel odds ratio	479	(45.5, 30001)	< 0.0001
LPA (5/1208 = 0.41%)	PDA + LPA (3/15 = 20.0%)	Mantel Haenszel odds ratio	41.9	(5.72, 383.1)	0.0002
PDA (1/3680 = 0.03%)	Surgery (32/3036 = 1.05%)	Exact odds ratio	39.2	(6.54, 1596)	< 0.0001
LPA (5/1208 = 0.41%)	Surgery (32/3036 = 1.05%)	Exact odds ratio	2.56	(1.00, 8.44)	0.05

Proce- dure	Proce- dure	Statistics	OR	95% Conf Interval	P-Value
PDA+L- PA (3/15 = 20.0%)	Surgery (32/3036 = 1.05%)	Exact odds ratio	0.04	(0.01, 0.25)	0.0006

Although rarely reported as a potential complication following transcatheter PDA closure or LPA stenting, the incidence of RLNI and VCP is lower than previously reported in the surgical literature. VCP appears to be of greater risk in pts undergoing LPA stenting vs PDA closure. In the unusual patient who requires both PDA closure and LPA stenting, the incidence of VCP appears significantly increased which requires further investigation.

#### 49. RIGHT VENTRICULAR REMODELING FOLLOWING TRANSCATHETER FENESTRATED ATRIAL SEPTAL DEFECT CLOSURE

Joseph Vettukattil<sup>1,2</sup>, Vishal Kaley<sup>1</sup>, Bennett Samuel<sup>1</sup>, Yasser Al-Khatib<sup>1,2</sup>, Reda Girgis<sup>3,2</sup>

<sup>1</sup>Spectrum Health Helen DeVos Children's Hospital, Grand Rapids, USA. <sup>2</sup>Michigan State University, Grand Rapids, USA.

<sup>3</sup>Spectrum Health Medical Group, Grand Rapids, USA

**Introduction:** Complete closure of atrial septal defects (ASD) in the setting of pulmonary hypertension (PH) can be detrimental to the patient due to the progressive nature of the disease. Fenestrated ASD closure is preferable in patients with PH as the fenestration allows a restricted interatrial shunt. The shunt can enhance systemic ventricular output at the expense of desaturation if shunt reversal occurs when progressive PH ensues. Improved hemodynamics after the fenestrated ASD closure may lead to remodeling of the right ventricle (RV). We present our experience of two patients with ASD and severe PH treated percutaneously using the Occlutech® Fenestrated Atrial Septal Defect (FASD) device.

**Case Description:** A 56-year-old female with 24mm ASD and mean pulmonary artery pressure (MPAP) of 47mmHg presented with NYHA Class III symptoms despite dual medical therapy consisting of Tadalafil and Macitentan.

A 41-year-old female with 27mm ASD and severe PAH with MPAP of 60 mmHg was initially treated with one drug for PH followed by dual medical therapy consisting of

Sildenafil and Ambrisentan. She had NYHA Class III symptoms despite being on dual medical therapy for 6 years.

As per the recommendations of a multi-disciplinary team, both patients underwent FASD implantation using a 27mm device with a 6mm fenestration. Both patients were discharged to home the following day after confirmation of device position and patency using transthoracic echocardiogram (TTE). PH medications were continued. Cardiac catheterization with TTE was scheduled at 6 months following implantation to monitor hemodynamics and right ventricular (RV) and left ventricular (LV) dimensions.

**Results:** Both patients were noted to have significant symptomatic improvement. Case 1 status post 18 months after implantation had RV/LV ratio improve from pre-implantation value of 1.8 to 0.74 at follow-up. Case 2 status post 7 months after implantation had marked improvement in the RV/LV ratio from pre-implantation value of 1.2 to 0.77 at follow-up.

**Conclusion:** RV remodeling following fenestrated ASD closure suggests the FASD device may be beneficial in patients with ASD associated PH. However, PH medications may need to be continued as it is a chronic, progressive disease.

#### 50. TRANSCATHETER FONTAN COMPLETION IN A CYANOTIC ADULT CONGENITAL PATIENT WITH CLASSIC GLENN SHUNT

*E. Oliver Aregullin<sup>1,2</sup>, Vishal Kaley<sup>1</sup>, Stephen Cook<sup>1,2</sup>, Samuel Lacina<sup>1</sup>, Bennett Samuel<sup>1</sup>, Joseph Vettukattil<sup>1,2</sup>*

<sup>1</sup>Spectrum Health Helen DeVos Children's Hospital, Grand Rapids, USA. <sup>2</sup>Michigan State University, Grand Rapids, USA

**Introduction:** Patients with single-ventricle physiology require staged palliation. Additional interventions may be required due to Fontan failure, formation of collaterals or pulmonary arteriovenous malformations (PAVMs). Transcatheter interventions are preferable in this setting to avoid the risks of redo-sternotomy, and cardiopulmonary bypass. We present our experience with transcatheter Fontan completion in a cyanotic adult congenital heart patient born with hypoplastic left heart syndrome (HLHS).

**Case description:** A 31-year-old female born with HLHS underwent stage-1 palliation as a neonate followed by classic-Glenn shunt at age 6 months. Intracardiac Fontan procedure with inferior vena cava connected to the left pulmonary artery was performed at age 2 years. Prior hemodynamic evaluation revealed Glenn and Fontan circulation mean pressures of 11 and 15mmHg, respectively. PAVMs were noted in the right lung, presumably due to

lack of hepatic flow in this area. Eventually, she also developed Fontan-associated liver cirrhosis. Anticipating the potential benefits of decreasing cyanosis, and ultimately improving end-organ function, a multi-disciplinary team recommended transcatheter Fontan completion to connect both systems with even distribution into the lungs.

**Intervention:** After hemodynamic and angiographic assessment, an 8.5 Fr SL2-transseptal sheath with 21 gauge transseptal Brockenbrough needle was advanced from the right internal jugular vein into the roof of the Fontan baffle. Once the needle was placed into the Fontan baffle, a 0.014 inch Mailman wire was advanced and then snared from the femoral vein, creating a veno-venous loop. Using V-18 control wire as a buddy, 0.035 Amplatzer super-stiff wire was placed between the Glenn and Fontan circuits. Subsequently, a 28mm Cheatham-Platinum (CP) covered stent pre-mounted on 20mm balloon-in-balloon catheter was deployed in between the two circuits. Unobstructed flow was noted with immediate decrease in Fontan mean pressure from 15 to 13mmHg. The patient had no complications during overnight observational stay and was discharged to home the next day. Computed tomography scan 6-weeks after the procedure showed Glenn and Fontan circuits connected by in-situ CP stent.

**Conclusion:** Transcatheter Fontan completion may be a feasible option in selected patients in the setting of high risk for redo-sternotomy or co-morbidities contraindicated for surgical intervention with optimal outcomes.

#### 51. TRANSCATHETER TREATMENT OF SEVERE PULMONARY VEIN STENOSIS IN PATIENT WITH 3-P DELETION SYNDROME

*E. Oliver Aregullin<sup>1,2</sup>, Vishal Kaley<sup>1</sup>, Chad Hopkins<sup>1</sup>, Bennett Samuel<sup>1</sup>, Joseph Vettukattil<sup>1,2</sup>*

<sup>1</sup>Spectrum Health Helen DeVos Children's Hospital, Grand Rapids, USA. <sup>2</sup>Michigan State University, Grand Rapids, USA

**Introduction:** Pulmonary vein stenosis is a rare condition with prevalence of about 1.7/100,000 children. Often pulmonary vein stenosis has syndromic association and can be difficult to manage due to multiple vein involvement. We present our experience of managing pulmonary vein stenosis in a patient with 3p deletion.

**Case description:** A 19-month-old female was diagnosed with atrial septal defect (ASD), pulmonary vein stenosis, and 3p deletion. She was born at 26-weeks gestation, weighing 650 grams requiring care in intensive care unit. Ventilatory support was needed for 7-days with discharge on supplemental oxygen after 97-days hospital stay. At 8-months

of age, she was diagnosed with moderate ASD and flow turbulence was noted in the right lower pulmonary vein (RLPV). Computed tomography (CT) scan confirmed the diagnosis of pulmonary vein stenosis with near-complete disconnection of the right upper pulmonary vein (RUPV) and discrete narrowing of the RLPV.

**Intervention:** Cardiac catheterization was performed at the age of 9-months. Pulmonary artery wedge injection demonstrated the exact site of stenosis in the RLPV. The left-sided veins were normal and the RUPV could not be accessed. Using a right Judkins catheter and a whisper guidewire, pressures in the RLPV were measured at 22mmHg. Balloon angioplasty was performed using a 5x30mm coronary balloon. Post procedure the pressures were noted to have decreased to 11mmHg. She was discharged to home with a plan to monitor the pulmonary veins.

At 18-months of age she underwent catheterization for concerns of increasing pressure gradients. Injection into the right lower pulmonary artery demonstrated a good sized pulmonary vein without any evidence of obstruction. However, the wedge injection into the right upper lobe showed a severely obstructed pulmonary vein. The RUPV was dilated using a 4x30mm coronary balloon. Angiogram after the balloon dilatation revealed unobstructed flow. She was discharged the following day and is stable from a cardiac point 6-weeks post-dilatation.

**Conclusion:** Pulmonary vein stenosis should be suspected in infants with syndromes presenting with refractory hypoxemia, persistent respiratory distress, and unexplained pulmonary hypertension. Frequent monitoring and transcatheter interventions may be required in selected patients.

## 52. TRANSCATHETER STENTING OF NEAR-INTERRUPTED AORTA

*E. Oliver Aregullin<sup>1,2</sup>, Vishal Kaley<sup>1</sup>, Bennett Samuel<sup>1</sup>, Paul Nelson<sup>1</sup>, Joseph Vettukattil<sup>1,2</sup>*

<sup>1</sup>Spectrum Health Helen DeVos Children's Hospital, Grand Rapids, USA. <sup>2</sup>Michigan State University, Grand Rapids, USA

**Introduction:** Transcatheter stenting is preferred over the surgical interventions for treating coarctation of aorta in adolescents and adults. However, percutaneous reconstruction of an interrupted or near-interrupted aortic arch is technically challenging. We describe our experience with transcatheter stenting in a patient with near-interrupted aorta.

**Case Description:** A 43-year-old male with history of long standing severe hypertension, and embolic stroke with residual left-sided weakness presented with complaints of nausea, diaphoresis, and passing bright red blood per rectum. On examination, he was noted to be hypertensive in upper limb with blood pressures of 176/101 mmHg as compared to lower limb blood pressure of 120/87 mmHg with diminished pulses in the lower limbs. Computed tomography demonstrated severe narrowing in the proximal part of the descending aorta measuring about 2mm in diameter along with an extensive network of collaterals joining the distal segment.

**Interventions:** Right radial artery and right femoral artery were catheterized. Simultaneous pressure measurements revealed a peak-to-peak gradient of 60 mm Hg across the coarctation. The angiogram demonstrated nearly interrupted segment in the proximal part of the descending aorta that appeared to connect through a pinhole to the distal thoracic aortic segment. Subsequently, via a radial artery access a 0.014 inch coronary whisper wire was snugly passed into the descending aorta. The coronary wire was snared from the femoral artery to create an arterio-arterial loop. The narrowest segment was dilated using a 4x20mm Advance balloon to pass a 0.035inch Amplatzer stiff wire. Once the stiff wire was secured in an acceptable position, a 12F long sheath was passed from the femoral artery across the coarctation. Finally, a 39mm Cheatham Platinum covered stent was deployed using a pre-mounted balloon-in-balloon catheter. Post-deployment angiogram showed good antegrade flow through the descending aorta measuring 15mm at the narrowest point. The stent was in-situ without any evidence of extravasation of the contrast or aneurysmal formation.

**Conclusion:** This case suggests that transcatheter stenting can be a safe and effective intervention even in patients with near-interruption of aorta. However, the physician expertise, accurate hemodynamic measurement, and anatomic assessments are critical for optimal outcomes.

## 53. MEDIUM- AND LONG-TERM OUTCOMES OF STENT IMPLANTATION FOR COARCTATION OF AORTA IN SMALL PATIENTS ( $\leq 20$ KG)

*Brian Boe<sup>1</sup>, Emefah Loccoh<sup>2</sup>, Katie Stockmaster<sup>1</sup>, Ralf Holzer<sup>3</sup>, Sharon Cheatham<sup>1</sup>, John Cheatham<sup>1</sup>, Aimee Armstrong<sup>1</sup>, Darren Berman<sup>1</sup>*

<sup>1</sup>Nationwide Children's Hospital, Columbus, USA. <sup>2</sup>The Ohio State University, Columbus, USA. <sup>3</sup>Weill Cornell Medicine, New York City, USA

**Background:** Stent implantation (SI) is more effective than balloon angioplasty for the treatment of coarctation of the aorta (CoA). Due to the large sheath size required for SI and requirement for repeat intervention, balloon angioplasty is more commonly performed in small patients. We sought to evaluate the medium and long-term outcomes of percutaneous adult-sized SI for the treatment of CoA in small patients.

**Methods:** A single center retrospective review of all patients  $\leq 20$  kilograms who underwent adult-sized percutaneous SI for CoA was performed.

**Results:** From 2004-2015, 39 patients  $\leq 20$  kilograms (21 patients  $\leq 10$  kgs) underwent percutaneous SI for CoA. The majority of lesions were recurrent (74%) that failed balloon angioplasty (56%). At the time of SI, the median [range] patient age and weight were 1.1 [0.3 – 7.9] years and 10 [5.5-20.4] kilograms. Stents used included: Palmaz Genesis XD (n=32), eV3 Mega LD (n=2), eV3 Max LD (n=2), Palmaz XL (n=2), and premounted Valeo (n=1). SI resulted in significant improvements in both coarctation diameter [mean $\pm$ standard deviation] (4.0 $\pm$ 2.0 mm to 8.2 $\pm$ 2.2 mm,  $p < 0.05$ ) and gradient (32.3 $\pm$ 18.2 mmHg to 0.9 $\pm$ 1.5 mmHg,  $p < 0.05$ ). Most stents were delivered through a 6 French (n=13) or 7 French (n=12) sheath (range 6-10 French). Seven patients had 7 (18%) complications: arterial vascular access site injury (n=3), vascular injury at site of CoA (n=2), intraprocedural hypotension and bradycardia (n=1), and stent embolization (n=1). No patient required surgical intervention at the site of vascular access or stented CoA. Mean follow-up was 75.6 $\pm$ 46.5 months. Twenty-five (64%) patients have undergone elective re-intervention at a mean time of 42.7 $\pm$ 33.7 months from original stent implantation. Eight (21%) stents (all Palmaz Genesis XD) developed fractures which were successfully treated with coaxial SI. In follow-up, femoral arterial occlusion has been documented in 2/16 (13%) patients.

**Conclusions:** Adult-sized SI is a viable option for small patients with either native or recurrent CoA with increased risk of vascular access complications. As with all stents implanted in children, repeat intervention is expected as the patient grows. Longer-term follow-up into adulthood is needed.

#### 54. THE EFFECTIVENESS OF BALLOON ANGIOPLASTY OF NATIVE COARCTATION OF THE AORTA IN NEWBORNS AND SMALL INFANTS - OWN EXPERIENCE

Jacek Kusa<sup>1,2</sup>, Pawel Czesniewicz<sup>2</sup>, Agnieszka Skierska<sup>1</sup>, Malgorzata Ras<sup>2</sup>

<sup>1</sup>Medical University of Silesia, Pediatric Cardiology Department, Katowice, Poland. <sup>2</sup>Regional Specialized Hospital, Pediatric Cardiology Department, Wroclaw, Poland

**Introduction:** Balloon angioplasty of coarctation of the aorta in children is an accepted method of treatment but is not recommended in patients under six months of age because of the significant risk of early recoarctation.

The aim of study is to evaluate the effectiveness of this method in newborns and youngest infants.

**Material/Methods:** Between 01.03.2011 and 10.04.2018 balloon angioplasties of aortic coarctation were performed in 24 patients aged between 6 and 149 days (mean-73 $\pm$ 53). Only patients with naïve form of coarctation were qualified. There were 9 newborns (37,5%). Nine patients had a bicuspid aortic valve. Eight patients (33.3%) had critical form of coarctation (heart failure), six (25%) - patent ductus arteriosus (Prostin in 2).

**Results:** After procedure the stenosis diameter increased from 1.8 (0,4-2,8) to 4.0mm (1,9-6,2)mm. The maximum echocardiographic gradient decreased from 70.1 (48-120) mmHg to 27,9 (15-38)mmHg, average from 36,7 (21-62) mmHg to 11,2 (6-17)mmHg, and hemodynamic gradient from 35.4 (6-69) to 9.3mmHg (1-30)mm Hg. There were complications associated with procedure- limb ischemia in two cases (8,3%), In one- the normal blood flow returned after heparin administration. In the second patient, despite heparin and actylise the pulse did not returned, but the efficient collateral circulation developed.

During FU- 40 $\pm$ 24 (1-83) months 6 patients required some intervention (one more child is currently awaiting the date of surgery). Three patients (12,5%) required surgical plasty (1 month after angioplasty) because of the ineffectiveness of percutaneous intervention, in another 3 patients the treatment was effective, but during FU stenosis returned and after 18 (6-36) months the successful repeated balloon angioplasty was performed. In the remaining patients the good effect of treatment is still present.

**Conclusions:** Percutaneous angioplasty of aortic coarctation in the youngest age groups may be an effective treatment, alternative for cardiac surgery. The incidence of recoarctation during medium-term FU does not differ significantly from cardiac surgery and can be successfully treated by repeated percutaneous angioplasty.

### 55. LEFT RECURRENT LARYNGEAL NERVE PALSY AFTER LEFT PULMONARY ARTERY STENT INSERTION

Seul Gi Cha, Seung Min Baek, Gi Beom Kim

Department of Pediatrics, Seoul National University Children's Hospital, Seoul, Korea, Republic of

We report a 10-year-old boy with left recurrent laryngeal nerve palsy (LRLNP) after left pulmonary artery (LPA) stent insertion. He received device closure of patent ductus arteriosus (PDA) at 1 year old and was transferred to our hospital for LPA stenosis nine years after PDA device closure. Echocardiography (Fig A,B) and computed tomography (Fig C) confirmed LPA stenosis owing to PDA device. Follow-up echocardiography showed aggravation of LPA stenosis. Lung perfusion scan using technetium-99m showed a decreased perfusion in the left lung (25%) compared to the right lung (75%). We, thus, performed a LPA stent insertion using EV3 stent 10 mm diameter-17mm length, under general anesthesia.

Post-interventionally, hoarseness developed. Laryngoscopy performed 1 month after intervention revealed hypo-mobile left vocal fold and electromyography performed at 2 months post-intervention showed that the left thyroarytenoid muscle had no motor unit action potential except for fibrillation suggesting LRLNP. He still had difficulty in making high tone voice at 1 year follow-up.

LRLNP after endovascular procedure is extremely rare. Including this case, only three cases of LRLNP after LPA stent insertion have been reported. A more careful intervention is suggested in patients with pulmonary artery hypoplasia not associated with congenital heart defect or those with a PDA device.

### 56. ADO II OFF LABEL USE IN THE CLOSURE OF VARIOUS CONGENITAL HEART DEFECTS:

Nazmi Narin, Ozge Pamukcu, Ali Baykan, Suleyman Sunkak, Aydin Tuncay, Gozdenur Erkan

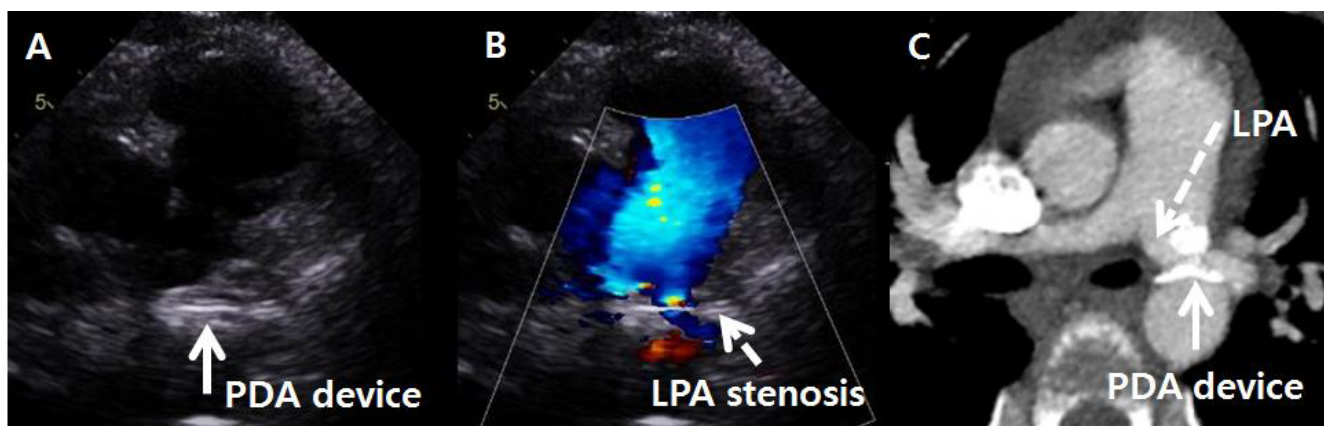
Erciyes University, Kayseri, Turkey

**Background:** Devices may be used for special purposes different than their production purpose. For instance, Amplatzer Ductal Occluder is actually designed for duct closure and its usage for closing defects other than ductus are named as off-label. The aim of this study is to emphasize off-label use of device: not only for PDA and VSD but also for other various congenital heart defects.

**Material Method:** This study is designed retrospectively, performed by the evaluation catheterization records of patients in whom ADO II and ADO II-AS devices were used in Erciyes University Medical Faculty Children Hospital, Pediatric Cardiology Department between 2011 and 2018. Patients' demographic criteria: age, weight at the time of procedure was gathered. The diagnosis, size of device, follow-up period and complications were also noted.

**Results:** From April 2011 to March 2018, a total of 121 patients underwent transcatheter closure by ADO II and 66 patients by ADO II AS. The number of PDA closure with ADO II was 48; with ADO II AS were 62. Rest of the procedures were all off-label. Types of off-label procedures performed were: VSD closure, residual mitral cleft closure, Aorta-Right atrium tunnel closure, pulmonary arteriovenous fistula occlusion, aorta-pulmonary window closure, and occlusion of the artery feeding accessory lobe in scimitar syndrome, Gerbode defect occlusion.

**Conclusion:** Up to our knowledge; this study includes the largest pediatric case series with various different



55. Figure 1.

congenital heart defects which were closed with ADO II. Also our ADO II occluded VSD case series is one of the largest series in the literature with almost 6 years' follow-up.

We believe in that ADO II device may be an alternative in percutaneous closure of various rare heart defects. It is used successfully for non-ductal defects with low complication and high compliance rates.

### 57. SHOULD THE NORMAL RANGE OF PULMONARY VASCULAR RESISTANCE BE RE-DEFINED IN PATIENTS WITH FONTAN CIRCULATION?

Ashish Shah<sup>1</sup>, Kelly Rohan<sup>2</sup>

<sup>1</sup>St Boniface Hospital & the University of Manitoba, Winnipeg, Canada. <sup>2</sup>University of Manchester, Manchester, United Kingdom

**Background:** The Fontan operation provides a palliative cure to those born with anatomical or physiologically single ventricle. The long-term outcomes are poor and survivors are at a high risk of constellation of medical problems, described as "Fontan failure". Adult patients with Fontan circulation have limited exercise capacity, mainly due to inability to augment the cardiac output, predominantly secondary to limited venous return. Studies have suggested that pulmonary vasodilator therapy results in marked improvement in hemodynamics. Normal range of pulmonary vascular resistance (PVR) is defined in those with bi-ventricular physiology, and pulsatile pulmonary flow. We evaluated observed PVR in a cohort of patients with Fontan circulation from a tertiary adult congenital heart disease centre.

**Materials and Methods:** We retrospectively reviewed data from a large tertiary adult congenital heart disease centres in UK. Clinical and procedural details were obtained by reviewing electronic charts, with special emphasis on haemodynamic data.

**Results:** From a cohort of 4454 patients with complex ACHD conditions, 154 had Fontan circulation; of whom 70 patients with failing Fontan were investigated by cardiac catheterization. Thirty-four (48.6%) were male, mean age of 30.1±6.2 years (17-43), and mean body mass index of 24.1±5.3 kg/m<sup>2</sup> (16.6-47.7). Mean Fontan pressure was 16±4 mmHg (7-29), mean wedge capillary pressure was 11±3 mmHg (4-19), and mean trans-pulmonary gradient (TPG) was 5±3 mmHg (0-15). Mean cardiac output was 4.1±2.7 L/min and calculated PVR was 1.7±1.2 Wood units (0.25-5.3). Although cardiac output was well maintained, Fontan pressure was significantly correlated with capillary wedge pressure (P<0.0001) and PVR (P<0.0001). Rise in

Fontan pressure was observed earlier than increase in PVR; however, 3/4<sup>th</sup> of patients with failing Fontan were noted to have normal PVR.

**Conclusions:** In this large series of patients with Fontan circulation, rise in PVR above the normally accepted range was observed only after moderate rise in Fontan pressure. In patients without sub-pulmonic ventricle and passively filling pulmonary circulation, range of normally accepted PVR should be re-defined, as patients can be treated in a timely fashion.

### 58. RELIABILITY OF THE CARDIAC OUTPUT MEASUREMENTS DURING CATHETERIZATION: COMPARISON OF VARIOUS COMMONLY USED FORMULAE CALCULATING ASSUMED O<sub>2</sub> CONSUMPTION.

Ashish Shah<sup>1</sup>, Guy Kendall<sup>2</sup>

<sup>1</sup>St Boniface Hospital & the University of Manitoba, Winnipeg, Canada. <sup>2</sup>University of Manchester, Manchester, United Kingdom

**Background:** Cardiac output (CO) measurement guides management of various medical conditions, including adult congenital heart diseases (ACHD), and pulmonary hypertension. It is mandatory to calculate patients' oxygen consumption (VO<sub>2</sub>), to measure CO. Ideally VO<sub>2</sub> consumption should be measured by using a metabolic facemask apparatus; however, due to complexity in their routine use, various formulae derived assumed VO<sub>2</sub> are incorporated to obtain CO values. The most commonly used formula in catheter laboratories treating adult patients was reported by LaFarge and Miettinen (1970). However, it was based on data from paediatric population, and their use in adult population is not validated. Moreover, these individual formulae were compared with true VO<sub>2</sub> consumption; however, limited information exploring agreement between these formulae is available. Such a comparison is very important, as individual catheter laboratories use these formulae at their discretion to derive cardiac output, influencing patients' management.

**Materials and Methods:** We sought to compare cardiac output measurement based upon four commonly used formulae, (1) LaFarge and Miettinen, (2) Dehmer, Firth & Hills, (3) Bergstra, Van Dijk, Jillege, and (4) Seckeler, Hirsch, Beekman methodology, in 112 ACHD patients who underwent diagnostic catheterization at the Manchester Royal Infirmary, UK between 1<sup>st</sup> January 2015 to 31<sup>st</sup> March 2017.

**Results:** CO measured by various formulae is reported here with. LaFarge and Miettinen: 4.31±1.43 L/min; Dehmer,

Firth & Hills:  $4.91 \pm 1.50$  L/min; Bergstra, Van Dijk, Jillege:  $6.1 \pm 2.22$  L/min; and Seckeler, Hirsch, Beekman:  $2.96 \pm 0.88$  L/min. LaFarge and Miettinen formula derived CO was significantly lower than Dehmer and Bergstra formulae ( $P < 0.0001$  for each), whereas significantly higher than the formula by Seckeler.

**Conclusion:** There is no agreement between the formulae derived assumed  $VO_2$  and resultant CO. Such assumed formulae derived CO may be misleading. Every cardiologist should be cognizant of these limitations. Metabolic face-mask apparatus should be routinely used in catheter laboratories to obtain true  $VO_2$ , especially, when such a value is likely to influence major management decisions.

### 59. SPLITTING OF SURGICAL PULMONARY VALVE RING WITH HIGH PRESSURE BALLOONS INCREASES PULMONARY VALVE ANNULUS DIAMETER FACILITATING transcatheter PULMONARY VALVE IMPLANTATION

Farhouch Berdjis<sup>1</sup>, Sharib Gaffar<sup>2,3,4</sup>, Michael Recto<sup>3</sup>

<sup>1</sup>Children's Hospital Of Orange County, Orange, USA. <sup>2</sup>University of California Irvine, Irvine, USA. <sup>3</sup>Children's Hospital Orange County, Orange, USA. <sup>4</sup>Miller Children's and Women's Hospital Long Beach, Long Beach, USA

**Background:** Melody valve implantation is an accepted therapy for patients who have previously undergone placement of prosthetic right ventricular outflow tract (RVOT) conduits in the setting of significant conduit stenosis or insufficiency. This abstract documents our experience splitting pulmonary valve rings with high pressure Atlas Balloons (Bard Peripheral Vascular) in patients with Tetralogy of Fallot

**Methods:** 4 patients (3 males, 1 female) with mean age 11.6 years (range 9-15 years) and mean weight 47.1 kg (range 31-77 kg) developed severe pulmonary valve insufficiency (2 patients) or moderate pulmonary valve stenosis with severe insufficiency (2 patients). All patients had initially undergone complete repair with transannular RVOT patch. They developed significant right ventricular enlargement secondary to pulmonary valve regurgitation. The pulmonary valve ring was measured pre- and post- splitting. A 20 mm Atlas Balloon was utilized for the 19 mm valve, 22 mm balloon was utilized for the 21 mm valve, and 24 mm balloon utilized for the 23 mm valve. The balloons were inflated to 22 atm with successful splitting of the valve ring. Mean gradient across the pulmonary valve ring decreased from 16.8 mmHg to 4.5 mmHg. All 4 patients subsequently

underwent successful placement of a 22 mm Melody valve on a 22 mm Ensemble. There were no complications.

**Conclusion:** Splitting of a surgical pulmonary valve ring with a high-pressure balloon prior to Melody Valve placement decreases pulmonary valve stenosis and increases the maximum diameter of the pulmonary valve, facilitating successful placement of the Melody valve.

Patient #1: 19mm valve		
	Pressure gradient	Ring
Pre-split	PA: 21/7 RV: 30/7 Gradient 9mmHg	16.7mm
Post-split	PA: 19/13 RV: 20/5 Gradient 1mmHg	18.3mm
Change	(-) 8mmHg	(+) 1.6mm
Patient #2: 21mm valve		
	Pressure gradient	Ring
Pre-split	PA: 18mmHg RV:41mmHg Gradient 23mmHg	19.9mm
Post-split	PA: 16mmHg RV: 21mmHg Gradient: 5mmHg	21.7mm
Change	(-) 18mmHg	(+) 1.8mm
Patient #3: 21mm valve		
	Pressure gradient	Ring
Pre-split	10mmHg	19.9mm
Post-split	3mmHg	21.1mm
Change	(-) 7mmHg	(+) 1.2mm
Patient #4: 23mm valve		
	Pressure gradient	Ring
Pre-split	PA: 20/11 RV: 45/11 Gradient: 25mmHg	19.7mm
Post-split	PA: 33/16 RV: 42/10 Gradient: 9mmHg	21mm
Change	(-) 16mmHg	(+) 1.3mm

### 60. CATHETER-DIRECTED THERAPY IN ACUTE PULMONARY EMBOLISM IN CHILDREN

Jyothsna Akam Venkata<sup>1</sup>, Thomas Forbes<sup>1</sup>, Theodore Schreiber<sup>2</sup>, Amir Kaki<sup>2</sup>, Mahir Elder<sup>2</sup>, Daniel Turner<sup>1</sup>, Daisuke Kobayashi<sup>1</sup>

<sup>1</sup>Children's Hospital of Michigan, Detroit, USA. <sup>2</sup>Detroit Medical Center, Detroit, USA

**Background:** Acute pulmonary embolism (PE) is a potentially life threatening condition requiring prompt management in children. The safety and efficacy of catheter

**60. Table.** Patient characteristics and catheter-directed therapy (CDT) for acute pulmonary embolism (PE) in children

Case	Age (yrs)	Sex	Wt (Kg)	Chest CTA thrombus	PE classification	Cardiac catheterization				Outcome		
						Time from PE diagnosis to CDT	Mean RA (mmHg)	RVSP (mmHg)	CDT	tPA complication	LOS after CDT	Mortality
1	20	F	40	LPA	Massive	4 hours	40	NA	tPA (EkoS)	NA	NA	Died
2	17	M	105	BL PA	Submassive	8 hours	30	53	tPA (EkoS)	None	5 days	Survived
3	16	F	77	BL PA	Massive	5 hours	19	49	tPA (EkoS)	GI bleed	5 days	Survived
4	12	M	90	RPA	Submassive	4 hours	16	55	tPA (EkoS)*	None	10 days	Survived
5	15	F	76.7	RPA	Submassive	26 hours	8	48	tPA (EkoS)	None	8 days	Survived
6	18	F	109	BL PA	Massive	29 hours	23	76	tPA (Pigtail)	NA	NA	Died
7	16	M	89.2	BL PA	Submassive	15 hours	6	55	Angiojet, balloon angioplasty	None	8 days	Survived
8	17	F	100	RPA	Submassive	4 days	11	33	tPA (multitrack)	None	11 days	Survived
9	14	F	107	BL PA	Submassive	7 days	20	56	tPA (Pigtail)	GI bleed	24 days	Survived

BL PA, bilateral pulmonary artery; LPA, left pulmonary artery; RPA, right pulmonary artery; CTA, computed tomography angiography; RA, right atrium; RVSP, right ventricular systolic pressure; tPA, tissue plasminogen activator; NA, not applicable; LOS, length of stay; GI, gastrointestinal.

\*Case 4 required 2<sup>nd</sup> CDT.

directed therapy (CDT) in pediatric patients are not well established. We report a single centered experience in the management and outcome of catheter-directed therapy in acute PE in children.

**Methods:** This is a retrospective study of patients, aged  $\leq 21$  years, who had no underlying congenital heart disease and underwent CDT for management of acute PE at Children's Hospital of Michigan during 12 years (2005 to 2017). Demographic and clinical data associated with PE were collected along with the outcome.

**Results:** Nine patients (median age 16 years: range 12-20, **Table**) received CDT for submassive (n=6) and massive PE (n=3). One patient received ANGIOJET thrombectomy and balloon angioplasty, whereas 8 pts received catheter directed thrombolysis using tPA through infusion catheters (n=3) or EkoSonic ultrasound accelerated thrombolysis system (n=5). In 4/5 patients treated with EkoSonic, a significant clinical improvement was noticed within 24 hours. Two patients had minor gastrointestinal bleeding among 7 patients who survived (median hospital stay 8 days: range 5-24). Two patients with massive PE died possibly due to the delayed institution of CDT.

**Conclusion:** CDT with/without EkoSonic is an emerging alternative therapy for submassive and massive PE in children. A timely institution of CDT appeared important to improve the outcome.

### 61. EROSION OF FIGULLA FLEX II DEVICE AFTER CLOSURE OF ATRIAL SEPTAL DEFECT PRESENTING AS CARDIAC TAMPONADE

Tadaaki Abe, Shinya Tsukano, Yuko Tosaka

Niigata City General Hospital, Niigata City, Japan

Transcatheter device closure of atrial septal defect (ASD) is a minimally invasive technique that offers an alternative to conventional surgical repair. In Japan, transcatheter device closure of ASD with AMPLATZER Septal Occluder has been started since 2005, and Figulla Flex II (FF II) has been available since 2016. There has never been death related to transcatheter closure of ASD, and the ratio of device related cardiac erosion was 0.17% in our nationwide. We present a case of 8 years boy suffering from sudden-onset terrible chest pain and cardiogenic shock due to cardiac tamponade caused by erosion of a FF II device 4 days after placement. The transcatheter ASD closure was performed under general anesthesia. His ASD was about 7 mm round shape and had no aortic rim in a range of 90 degrees by a transesophageal echocardiography (TEE) resulting in a Qp:Qs of 2.0:1.0. The stop-flow diameter with sizing balloon was 11.0 mm by TEE. We chose a 15 mm FF II device intending to make the aortic side device flared shape. However, the aortic side device was closed shape after placement and the device was located along the atrial septal primum which was mal-alignment position to left atrium side. As a result, the right atrial disc of the device pressed the aortic wall perpendicularly after detachment. Four days later, he suddenly complained of severe chest pain, and then became hypotensive and unconscious due to pericardial tamponade. Emergent pericardiocentesis, followed by emergent operation was performed. A right atrial incision was carried out and the device lay in an appropriate position. The device was removed easily, and a perforation site was seen at antero-superior wall on right atrium and another pinhole perforation was also seen at the opposite aortic wall. Surgical direct closure of the ASD and repair of the perforation sites were performed successfully. Fortunately, he was discharged without sequelae. Although there has been few reports about erosion of this flexible device, in



case of right atrial disc of the device rubs perpendicularly and deeply, lethal complication can occur.

## 62. CLOSURE DEVIE FOR CONGENITAL HEART DISEASE: SINGLE CENTRE EXPERIENCE FROM A DEVELOPING COUNTRY

*Tawfiq Shahriar Huq*

National Heart Foundation Hospital and Research Institute, Dhaka, Bangladesh

Bangladesh is a country of 170 million people, which is the fifth largest country in the world by population. With a crude birth rate of 19.45 and Neonatal mortality rate of 20.1. It is estimated 12% of these deaths are due to congenital abnormalities and 1% of these may be due to cardiac anomalies. Early diagnosis and treatment still remains a challenge. National Heart Foundation Hospital and Research Institute which is a tertiary care cardiac hospital and the prime institute for cardiac care has a well organized department for diagnosis and treatment of congenital heart disease. Besides diagnostic cardiac catheterization since 2015 this institute is performing intervention for congenital heart disease. Till December 2017 a total of 595 patients both pediatric and adult age group underwent implantation of device for ASD, VSD and PDA. Of them 342 (57.5%) are for Atrial Septal Defect, 214 (36%) for PDA and 39 (6.6%) for VSD. Female population was dominant 377 (63.8%). Procedural success was high and complication rate was low. Thorough pre procedural assessment through different imaging modalities team work is the key behind success. On the flip side besides it is remarkable that the patient population was older than expected. At the same time significant number of patients with ASD presented to us with pulmonary hypertension. Lack of regulation for proper health check up of preschool children at the same time failure to understand the natural history of the disease by the primary care physicians are to be blamed. By creating awareness both among general population and health care providers are essential to reduce mortality and morbidity from congenital heart disease.

## 63. STENTING OF STRAIGHT AND TORTUOUS PDAS IS SAFE AND EFFECTIVE PALLIATION FOR NEONATES WITH DUCTAL-DEPENDENT PULMONARY BLOOD FLOW

*Carrie Herbert<sup>1,2</sup>, Jeffrey Jacobs<sup>1,2</sup>, Nhue Do<sup>1,2</sup>, Colleen Bauza<sup>1</sup>, Gary Stapleton<sup>1,2</sup>*

<sup>1</sup>Johns Hopkins All Children's Hospital, Saint Petersburg, FL, USA.

<sup>2</sup>Johns Hopkins University, Baltimore, MD, USA

**Purpose:** Ductal stenting in neonates with ductal-dependent pulmonary blood flow is an alternative palliation strategy to surgical shunt placement that may reduce cumulative morbidity and mortality. We reviewed our entire institutional experience with ductal stenting to assess safety and efficacy.

**Methods:** We placed our first ductal stent for palliation of ductal-dependent pulmonary blood flow in November 2014, and by 2016, we adopted an institutional policy of preferential ductal stenting in patients with suitable anatomy.

For all patients undergoing attempted ductal stenting, we reviewed anatomic, preprocedural, procedural, and postprocedural data. All procedures were performed by the same 2 interventionists; therefore, fluoroscopy time and radiation dose were used as surrogates for procedural difficulty.

**Results:** Ductal stenting was attempted in 24 neonates and was successful in 22 (91.6%). Diagnoses: PA/IVS (6), DORV/PS (5), TOF (4), PA/VSD (3), Heterotaxy syndrome/PS (3), DILV/TGA/PS (2), and TGA/VSD/PS (1).

9/24 patients had tortuous ducts (7/9 successfully stented). Unsuccessful PDAs had a 360° loop or a 180° "hairpin" turn that could not be straightened.

Table 1 documents fluoroscopy time and radiation dose stratified by ductal anatomy and the angle of ductal sheath.

3/22 (13.6%) patients who received a ductal stent required catheter-based re-intervention (2 for end of PDA uncovered, 1 for intimal buildup). Approach: 13/25=femoral

**Table 1 Fluoroscopy Time and Radiation Dose stratified by ductal anatomy and the angle of sheath to entry of the PDA**

Ductal Anatomy	Fluoroscopy Time (in min)	Radiation Dose (in cGycm2)
	Median (IQR)	Median (IQR)
Straight (n=15)	28.45 (14.72, 41.42)	103.00 (67.00, 171.50)
Tortuous (n=7)	16.87 (14.70, 20.58)	102.00 (87.00, 143.50)
Angle of sheath to entry of the PDA	Fluoroscopy Time (in min)	Radiation Dose (in cGycm2)
	Median (IQR)	Median (IQR)
60-90° (n=6)	48.66 (32.52, 66.20)	200.5 (134.50, 370.80)
91-120° (n=10)	18.26 (9.24, 66.20)	76.50 (56.25, 143.00)
150-180° (n=6)	16.70 (11.73, 22.17)	97.50 (86.75, 151.80)

artery, 7/25=left carotid artery cutdown, 2/25=left axillary, 2/25=umbilical artery, and 1/25=femoral vein.

There were no procedural or interstage mortality or need for extracorporeal membrane oxygenation.

#### **Complications:**

- 1 attempted stenting had ductal spasm requiring urgent BT shunt,
- 1 left carotid artery contained dissection (with no long-term sequelae),
- 3 arterial thrombus at catheterization site, and
- 7 PRBC transfusion.

**Conclusions:** Ductal stenting as palliation for neonates with ductal-dependent pulmonary blood flow is safe and effective, with low reintervention rate. Stenting the tortuous duct is feasible if there is not a 360° loop or 180° hairpin turn. A more acute angle of entry into the PDA is technically more challenging; therefore, access site should be chosen to make the straightest angle of entry possible.

#### **64. SUCCESSFUL TRANSCATHETER OCCLUSION OF PERSISTENT DUCTUS VENOSUS IN A PATIENT WITH HEPATOPULMONARY SYNDROME USING AMPLATZER VASCULAR PLUG II.**

*Amr Matoq, Wolfgang Radtke*

Alfred I. duPont Hospital for Children, Wilmington, USA

**Background:** Ductus Venosus is the vascular structure that connects the umbilical vein to the inferior vena cava in the fetal period. It closes at birth, with complete obliteration around 2-3 weeks of life. Persistent Ductus Venosus is a form of portosystemic venous shunts that leads to pulmonary hypertension, hepatopulmonary syndrome, pulmonary arteriovenous malformation, and encephalopathy. Liver transplantation is the treatment of choice in the presence of significant liver disease or intrahepatic portal vein hypoplasia. Surgical ligation of the abnormal shunt is considered treatment of choice in an otherwise healthy portal venous system. Only few cases of transcatheter occlusion of persistent ductus venosus have been reported. **Objective:** We present a case of a rare portosystemic venous shunt, successfully closed by Amplatzer Vascular Plug II (AVP II).

**Case:** Three months old female born at 35-week of gestation. Presented with failure to thrive, murmur and hypoxemia requiring supplemental oxygen. Noted to have a patent ductus arteriosus, which was surgically ligated. Continued to have hypoxemia postoperatively. Multiple investigations were done for lung diseases, reflux and

chronic aspiration. At 5 months of age, she underwent cardiac catheterization revealing pulmonary venous desaturation, pulmonary hypertension and evidence of intra-pulmonary right-to-left shunt by injection of agitated saline into main pulmonary artery. Ultrasound and three-phase CT scan of the liver showed persistent ductus venosus.

**Procedure:** She underwent cardiac catheterization. Through right internal jugular access, a 5 French balloon wedge catheter that was advanced into the persistent ductus venosus and portal vein pressure was measured and was normal. Test occlusion of the persistent ductus venosus was performed and portal vein pressure did remain within normal limits. A decision was made to place a 6 mm AVP II (AGA medical) into the persistent ductus venosus. Device was deployed successfully. Repeat angiogram showed no residual shunt. Repeat ultrasound showed normal flow in left hepatic vein and portal vein.

**Conclusion:** Persistent Ductus Venosus in an otherwise normal portal venous system can be safely closed by AVP. Measuring portal venous pressure with test occlusion is necessary to rule out portal hypertension.

#### **65. TRANSCATHETER COVERED STENT PLACEMENT FOR NATIVE COARCTATION WITHOUT ANGIOGRAPHY IN A PATIENT WITH CHRONIC KIDNEY DISEASE**

*Amr Matoq, Wolfgang Radtke*

Nemours/Alfred I. duPont Hospital for Children, Wilmington, USA

**Background:** Coarctation of the aorta represents approximately 7% of live births with congenital heart disease. The best intervention for aortic Coarctation as regard safety and effectiveness remains debatable, due to lack of sufficient randomized trial and long term follow up. However, stent placement is considered a reasonable approach in the older child, adolescent, or adult presenting with a simple, juxtaductal, native Coarctation. Contrast is necessary for endovascular interventions like stent placement, but chronic kidney disease (CKD) is a major limitation for its use. CKD increase the risk for developing Contrast induced nephropathy (CIN).

**Case:** 17-year-old with male presents to ED with hypertension. Echocardiogram showed Juxta-ductal discrete Coarctation of the aorta, with peak gradient 45 mmHg, bicuspid aortic valve and moderate aortic root and ascending aorta dilatation. Screening labs showed elevated BUN and Creatinine at 38 mg/dL and 2.8 mg/dL respectively. Based on renal ultrasound and other laboratory findings,

he was diagnosed with chronic kidney disease with undetermined etiology. GFR estimated to be 32 ml/min/1.73m<sup>2</sup>. An MRI confirmed a severe juxtaductal coarctation.

**Management:** Typically, this patient is a candidate for stent placement. However, this would be problematic in the presence of CKD. A decision was made to attempt stent placement without using angiography. Patient underwent right and retrograde left cardiac catheterization without angiogram. We used an 18mm Amplatzer sizing balloon II to exactly locate and measure the Coarctation. The balloon sizing diameter was 7.2mm. We elected to place a covered stent to preemptively cover even small possible tears because angiography post stent placement would not be available for assessment. A 35 mm long covered CP stent mounted on a 20mm X 4cm BIB balloon was used. Temporary pacing of the right ventricle was done to avoid dislodgement of the stent during deployment. Coarctation diameter increased to 15.5mm and the pressure gradient was eliminated. Patient tolerated the procedure well.

**Conclusion:** Endovascular intervention, including stent placement, in the presence of CKD is challenging. The use of a sizing balloon and measures to prevent complications can facilitate Transcatheter treatment of aortic Coarctation without the use of contrast

## 66. PERCUTANEOUS ASD CLOSURE OF CHILDREN LESS THAN 10 KG

*Nazmi Narin<sup>1</sup>, Osman Baspinar<sup>2</sup>, Ozge Pamukcu<sup>1</sup>, Ali Baykan<sup>1</sup>, Suleyman Sunkak<sup>1</sup>, Aydin Tuncay<sup>1</sup>, Onur Tasci<sup>1</sup>*

<sup>1</sup>Erciyes University, Kayseri, Turkey. <sup>2</sup>Gaziantep University, Gaziantep, Turkey

**Introduction & Aim:** Traditionally the procedure of percutaneous ASD closure is used to be done in children more than 15kg. Main limitation factor for small children is the size of delivery system and how to manage in a state of complication.

The aim of this study was to discuss the success, efficacy, and safety of the percutaneous closure of symptomatic ASD in children less than 10kg

**Method:** Study was performed in two Pediatric Cardiology centers: Erciyes and Gaziantep University. Total 38 patients were included. Demographic and angiographic data of these patients were gathered retrospectively from patients' records.

**Results:** Median weight of patients was 9,0(8,0-9,5)kg. Bodyweight of 21 patients were less than 3 percentiles. In the follow-up this number was lowered to 9 at 12 months. However, we lost contact with 16 of 38 patients. Median age of patients was 18 (12,75-30,0)months. Female/male ratio was 27/11. Median mean pulmonary pressure was 25 (20,0-29,0) mmHg. The values of median defect size were measured angiographically as 13,0(10,75-15,3) mm. Median device size was 13,0(9,0-15,0) mm. Defect size was evaluated according to body weight and body surface area. The ratio of weight per defect size was 0,64(0,55-0,83) also ratio of body surface area per defect size was 0,030(0,028-0,041). Ratio of total septum per device diameter was 2,5(2,1-3,1).

Additional medical problems of patients were growth hormone deficiency, Mucopolysaccharidosis, Down syndrome in 3 patients. Additional heart problems of patients were severe pulmonary stenosis in 4 patients, large PDA in one patient, VSD in 2 patients. Pulmonary valvuloplasty and PDA occlusion, percutaneous VSD occlusion was done in these patients in the same session with ASD closure. Types of devices used were Amplatzer Septal Occluder in 30 patients, CeraFlex Septal Occluder in 2 patients, Figulla FlexII Atrial Septal Occluder in 5 patients, Memopart septal Occluder in 1 patient. The device had to be retrieved in one patient after successful positioning because it was detected that device compressed the aorta. No major complication was seen.

**Conclusion:** In the experienced centers, percutaneous ASD closure can be done effectively and safely in symptomatic children less than 10kg.

## 67. CARDIAC CATHETERIZATION VIA UPPER EXTREMITY VEINS IN PEDIATRIC CARDIAC CATHETERIZATION LABORATORY

*Jess Randall<sup>1</sup>, Osamah Aldoss<sup>1</sup>, Asra Khan<sup>2</sup>, Melissa Challman<sup>2</sup>, Gurumathy Hiremath<sup>3</sup>, Athar Qureshi<sup>2</sup>, Manish Bansal<sup>1</sup>*

<sup>1</sup>University of Iowa Stead Family Children's Hospital, Iowa City, USA. <sup>2</sup>Texas Children's Hospital, Baylor College of Medicine, Houston, USA. <sup>3</sup>University of Minnesota Masonic Children's Hospital, Minneapolis, USA

**Background:** Traditional approaches to pediatric cardiac catheterization have relied on femoral venous access. Upper extremity venous access may enable cardiac catheterization procedures to be performed without the need for general anesthesia, lead to quicker recovery times and in some instances, facilitate interventions. The objective of

this multicenter study was to demonstrate the feasibility and safety of utilizing upper extremity venous access for cardiac catheterization in pediatric cardiac catheterization laboratory.

**Methods:** We performed a retrospective review of all patients who underwent cardiac catheterization via upper extremity vascular access at all 3 institutions.

**Results:** There were 82 cardiac catheterizations attempted via upper extremity access (basilic or brachial vein) on 72 patients presenting to pediatric cardiac catheterization laboratory. Successful access was obtained in 75 (91%) catheterization attempts in 67 patients. Median age of catheterization was 18.79 years (n=76, interquartile range (IQR) 13.02-32.75) with a median weight of 59.4kg (n=75, IQR 43.3-76.5). The youngest patient was 4.1 months old, weighing 4.3 kg. Local anesthesia or light sedation was utilized in 58% (n=48) of procedures. Ultrasound was used for access in all patients. Diagnostic right heart catheterization was the most common procedure (87%, n=65), with 11 cases of acute vasoreactivity testing (15%), and intervention performed via the upper extremity in 8 cases (11%). Interventions included angioplasty, recanalization of occluded veins, thrombectomy, central line fragment retrieval, and veno-venous collateral vessel occlusion. Angiography was performed in 40 catheterizations (53%); with median fluoroscopy time of 10.02min (n=75, IQR 2.87-36.26) and dose area product (DAP)/kg of 3.765cGy cm<sup>2</sup>/kg (n=64, IQR 0.74-34.12). Patients had a median sheath duration time of 48 minutes (n=57, IQR 19.5-147) and median total procedure time of 116 minutes (n= 65, IQR 80.5-299). Excluding interventions, 36% (n=27) of patients were discharged directly from the catheterization laboratory or from post-anesthesia care, with mean length of stay for outpatient procedures of 5.37 hours (n=27, IQR 4.25-6.92). At a median follow-up of 10 months (n=32, IQR 5-17.75), there are no reported complications related to access site.

**Conclusions:** Upper extremity venous access is a useful, feasible, and safe modality for cardiac catheterization in the pediatric cardiac catheterization laboratory.

#### 68. MEDIUM- TO LONG-TERM OUTCOMES OF PERCUTANEOUS INTRAVASCULAR STENT THERAPY FOR TRANSVERSE AORTIC ARCH HYPOPLASIA

Darren P. Berman, MD<sup>1</sup>, Joanne L. Chisolm, RN<sup>1</sup>, Sharon L. Cheatham, PhD, ACNP<sup>1</sup>, Brian A. Boe, MD<sup>1</sup>, Aimee K. Armstrong, MD<sup>1</sup>, Zach Steinberg, MD<sup>2</sup>, Thomas K. Jones, MD<sup>2</sup>, Michiel Voskuil, MD<sup>3</sup>, Gregor J. Krings, MD<sup>4</sup>, Jyothsna Akam Venkata, MD<sup>5</sup>, Tom J. Forbes, MD<sup>5</sup>, John P. Cheatham, MD<sup>1</sup>

<sup>1</sup>Nationwide Children's Hospital, Columbus, USA. <sup>2</sup>Seattle Children's Hospital, Seattle, USA. <sup>3</sup>University Medical Center Utrecht, Utrecht, Netherlands. <sup>4</sup>Wilhelmina Children's Hospital of the University Medical Center Utrecht, Utrecht, Netherlands. <sup>5</sup>Children's Hospital of Michigan, Detroit, USA

**Background:** Transverse aortic arch hypoplasia (TAAH) and abnormal arch geometry are associated with coarctation of aorta (CoA). Both can contribute to systemic hypertension following repair of CoA. Intravascular stent therapy can relieve TAAH. Long-term outcomes from this intervention are unknown.

**Methods:** Multi-center retrospective review assessing the medium- to long-term outcomes from stent implantation for treatment of TAAH or obstruction.

**Results:** From 7/2002 – 12/2017, 146 patients underwent stent implantation with 187 stents to treat TAAH/obstruction. Median (range) age and weight at time of intervention were 14.4 yrs (neonate – 63.6 yr) and 53 kg (3-149 kg). Initial procedure was performed for reCoA in 108 (74%). Prior interventions included: end-to-end anastomosis (50), subclavian flap (19), patch (15), other (24). Most stents were bare metal (95%) and open-celled (55%). Stent(s) overlapped 142 arch vessels: left subclavian (92), left common carotid (37), innominate (3), other (10) in 118 (81%) patients. Number of overlapped vessels per patient varied (one - 95, two - 22, three - 1). Struts overlapping carotid branches were dilated in 27/40 (68%). Stent implantation significantly reduced the pressure gradient (25.9±16.5 to 4.0±6.1 mmHg, p<0.05). Procedure-related adverse events occurred in 19 (13.0%) patients. Nine (6.2%) events required treatment: stent migration (4); aortic wall injury (2) requiring covered stent in 1 and surgery in 1; femoral artery access site injury (1) treated with a covered stent; bradycardia requiring resuscitation (1); death (1) in a patient on ECMO with aortic wall injury. No neurologic events were seen in the 104 patients with follow-up data over a median time of 7 years, including 24 patients with a stent overlapping a carotid artery. Fifty-one patients underwent 72 elective re-interventions and 25 required additional stent implantation. Most patients remain on antiplatelet therapy (51%) and ≤1 anti-hypertensive medication (77%).

**Conclusions:** In this multi-center cohort, stenting the TAA is feasible and effective. Most cases utilize open-celled bare metal stents with dilation of the struts extending across the carotid branches. In medium to long-term follow up, there were no reported neurologic events and the majority of patients were on ≤1 anti-hypertensive medication. More long-term robust follow-up is needed.

### 69. TRANSCUTANEOUS PULMONARY VALVE REPLACEMENT IN PULMONARY ATRESIA WITH INTACT VENTRICULAR SEPTUM

Nicole Herrick<sup>1</sup>, Jesse Lee<sup>2</sup>, Kanishka Raynayaka<sup>2</sup>, John Moore<sup>2</sup>, Howaida El-Said<sup>2</sup>

<sup>1</sup>University of California San Diego, San Diego, USA. <sup>2</sup>Rady Children's Hospital San Diego, San Diego, USA

#### Abstract

**Background:** Pulmonary atresia with intact ventricular septum (PA/IVS) is a congenital heart lesion traditionally managed by multiple surgical interventions including eventual pulmonary valve replacement. In the current era, those without RV dependent coronary circulation are initially managed with radiofrequency perforation of the pulmonary valve with patent ductus arteriosus stenting (PDA) followed by surgical 1.5 ventricle repair (Glenn with antegrade pulmonary blood flow) or biventricular repair (RVOT patch augmentation). Significant pulmonary insufficiency is expected resulting in eventual need for pulmonary valve replacement. Transcatheter pulmonary valve replacement (TPV) in this population is not well described in the literature.

**Methods:** Our institution's catheterization laboratory database was queried to identify patients with PA/IVS with TPV from 2010 to 2017. Procedural reports, angiograms and clinical records of patients were reviewed. Procedural technique, procedural outcomes, adverse events, and post hospital courses are reported.

**Results:** Nine patients were found to have PA/IVS and eventually TPV. The median age at TPV 7 years (5-32) and weight 20.3 kg (17.1-80.1). RF perforation/balloon dilation was performed in five (5/9) patients, balloon dilation alone in one (1/9) and surgical valvotomy in one (1/9). Additional pulmonary blood flow was needed via a PDA stent in five patients (5/9) and a BT shunt in three (3/9). Eight patients underwent subsequent surgical repair (biventricular repair with patch outflow augmentation (n=4) or 1.5 ventricle repair with bidirectional Glenn (n=4)). One patient did not require surgical intervention. Most common indications for TPV were severe PR with RV dilation (5/9), severe PR (3/9). One patient with bi-directional Glenn had severe PR with hepatic fibrosis. TPV was successfully implanted in all patients without major complications. Transient ventricular ectopy was seen in two patients with native outflow tracts, one required 2 months of Nadolol without recurrence. At median 9 months follow up (6-35 months), all patients have functional pulmonary valves and are clinically doing well.

**Conclusion:** PA/IVS which was traditionally managed with multiple surgical interventions, can be conceivably managed mostly in the interventional catheterization lab with one surgical operation. TPV can be a safe and effective alternative to surgical valve replacement in this population.

### 70. EXPERIENCE FROM THE PILOT PHASE OF INTERNATIONAL QUALITY IMPROVEMENT COLLABORATION CONGENITAL HEART DISEASE CATHETERIZATION REGISTRY (IQIC-CHDCR) IN LOW AND MIDDLE INCOME COUNTRIES (LMICs)

Oliver Barry<sup>1</sup>, Fatima Ali<sup>2</sup>, Carlos Corona<sup>3</sup>, R. Krishna Kumar<sup>4</sup>, Miguel Ronderos<sup>5</sup>, Kaitlin Doherty<sup>1</sup>, Lisa Bergersen<sup>1</sup>, Kimberlee Gauvreau<sup>1</sup>, Kathy Jenkins<sup>1</sup>, Babar Hasan<sup>2</sup>

<sup>1</sup>Boston Children's Hospital, Boston, USA. <sup>2</sup>Aga Khan University Hospital, Karachi, Pakistan. <sup>3</sup>Kardias AC, Mexico City, Mexico.

<sup>4</sup>Amrita Institute for Medical Sciences, Kochi, India. <sup>5</sup>Fundacion Cardioinfantil de Bogota, Bogota, Colombia

**Background:** Creating a collaborative of health care teams worldwide, IQIC aims to encourage a culture of safety and quality care for CHD patients treated in LMICs. Participation in IQIC has been associated with reduction in major morbidity and mortality after CHD surgery. IQIC-CHDCR is established on the same principles and aims at decreasing risk-stratified adverse events and improve procedure efficacy for cardiac catheterization performed in CHD patients in LMICs.

**Objectives:** The objective is to present demographics, procedural details and outcomes related to cardiac catheterization in CHD patients whose data was entered in the IQIC-CHDCR during the pilot phase.

**Methods:** From the experience of IMPACT and C3PO-QI registries, IQIC-CHDCR was designed to collect patient demographics, procedural details and outcomes in all CHD patients undergoing cardiac catheterization. Additionally, a novel efficacy categorization, defined as ideal, adequate and inadequate based on technical results and safety events, was collected for 5 selected interventions (ASD closure, PDA closure, coarctation, pulmonary and aortic valvuloplasties). The IQIC-CHDCR pilot phase was opened to 6 participating sites from 5 countries (Mexico (2), Pakistan, India, Malaysia and Vietnam) from October 2017 through December 2018.

**Results:** A total of 429 patients were entered in the database. Most patients (66%) were 1-17 years of age. Majority (71%) of catheterizations were interventions with PDA closure (23%) being most common followed by ASD closure

(13%). There was low mortality (n=2, 0.5%). Adverse events were reported in 7% of cases; most common were blood transfusion within 72 hours (2.8%) and anesthesia related events (1.8%). In the 5 selected interventions, technical procedural competence was "ideal" most frequently in PDA (95%) and ASD closure (90%). Procedural competence was technically "inadequate" most commonly in coarctation (100%), and aortic and pulmonary valvuloplasties (50%) due to high post-procedure residual gradients.

**Conclusion:** IQIC-CHDCR is a unique effort to understand the spectrum of cardiac catheterization performed on CHD patients in LMIC. Safety event reporting and novel categorization of procedure efficacy may identify potential areas for quality improvement. Adverse events related to blood transfusions and anesthesia may benefit from such initiatives. Procedural efficacy in valvuloplasties and coarctation interventions may also be target areas.

### 71. THREE-DIMENSIONAL PRINTING AIDS IN PROCEDURAL PLANNING FOR TRANSCATHETER DUCTAL STENT PLACEMENT: A SINGLE-CENTER CASE SERIES

Reid Chamberlain<sup>1</sup>, Gregory Sturgeon<sup>1</sup>, Piers Barker<sup>1</sup>, Kevin Hill<sup>1,2</sup>, Gregory Fleming<sup>1</sup>

<sup>1</sup>Duke University, Durham, USA. <sup>2</sup>Duke Clinical Research Institute, Durham, USA

**Background:** Three-dimensional (3D) printing is gaining traction as a means to better understand complex congenital cardiac anatomy prior to trans-catheter interventions. In 2017 our institution initiated a protocol including 3D printing for ductal stent placement in infants with ductal dependent pulmonary blood flow. Herein we report our experience.

**Methods:** 3D printing was performed from CT angiogram using Materialise Mimics and 3-matic (Materialise Leuven, Belgium) software with Stratasys Polyjet J750 (Stratasys Ltd. Eden Prairie, MN) printer on Vero and Tango photopolymers. Determination of access was based on pre-procedural review of the 3D model. Ductal dimensions were measured from the 3D model and compared with intra-procedural biplane angiography. Ductal tortuosity was quantified as an index comparing actual length of the vessel along its curvature to the linear length from aortic take-off to pulmonary insertion [(actual/straight length-1) x 100].

**Results:** Ductal anatomy 3D printing was performed in 6 infants. Most (4/6) demonstrated reverse angle ductal

morphology classified as Krichenko type C (n=2), D (n=1) and E (n=3). Median age and average weight (range) at stent placement were 15.5 days (7-122 days) and 3.2 kg (2.3-4.5kg). From 3D models we identified appropriate access approaches (4 carotid and 2 femoral) and successfully placed ductal stents in all 6 patients, including one with bilateral PDAs. A total of 13 bare metal coronary stents were deployed at a median diameter of 3.5 mm (3.0mm-4.0mm). Overall, 5 of 7 PDAs required more than one stent for complete coverage. All PDAs were tortuous, mean tortuosity index 90.0 (11.2-194.0), with the lowest tortuosity index in the 2 patients requiring a single stent. Ductal length by 3D model tended to measure longer than angiography (17.1 ± 4.8mm vs 14.6 ± 4.3mm, p=0.30) and more closely approximated total stent length (mean difference in total stent to measured ductal length 1.9 ± 2.0mm by 3D vs 4.39 ± 2.3mm by angiography, p=0.07).

**Conclusions:** In our experience, 3D modelling and printing prior to ductal stent placement for ductal dependent pulmonary blood flow is useful in determining access approach for the procedure, and for optimally estimating ductal length and tortuosity.

### 72. LONG-TERM SUSTAINED INCREASE IN SYSTEMIC OXYGEN SATURATION WITH LOW MORBIDITY AND MORTALITY FOLLOWING TRANSCATHETER FONTAN FENESTRATION CLOSURE

Rajiv Devanagondi<sup>1</sup>, Glenn Leonard<sup>1,2</sup>

<sup>1</sup>University of Rochester, Rochester, USA. <sup>2</sup>Pediatric Cardiology Associates of Western New York, Buffalo, USA

**Background:** Surgical Fontan fenestration decreases central venous pressure and preserves cardiac output while decreasing systemic arterial oxygen saturation immediately following Fontan operation. Transcatheter fenestration closure increases oxygen saturation immediately, though the persistence of this increase and the long-term incidence of adverse outcomes such as death and heart transplant remain unknown. We describe immediate and long-term clinical and adverse outcomes following transcatheter fenestration closure.

**Methods:** Catheterization, echocardiogram, and clinic reports were retrospectively reviewed following transcatheter extra-cardiac Fontan fenestration closure between 1/1/2003 and 12/31/2016. Data were reported as n(%) and median (IQR). Continuous variables were compared using Wilcoxon ranked sum test.

**Results:** 51 patients had Fontan operation at age 4.7 (4-5.7) years. Duration to fenestration closure was 0.9 (0.7-1.5) years. The majority (84%) were closed with Amplatzer septal occluders. Following occlusion, systemic O<sub>2</sub> saturation increased from 87 (84-89)% to 95 (94-97)%,  $p < 0.05$ . Cardiac index decreased from 4 (3-5) to 2.9 (2.6-3.5) L/min/m<sup>2</sup> and systemic oxygen transport decreased from 718 (568-851) to 591 (504-640) mlO<sub>2</sub>/min/m<sup>2</sup>,  $p < 0.05$ . Fontan pressure (13 [11.5-14] to 13 [12.3-15] mmHg) and pulmonary vascular resistance (1.8 [1.2-2.2] to 1.9 (1.6-2.5) WU x M<sup>2</sup>) were not significantly changed. 9 (18%) patients had follow up cardiac catheterization; one for residual fenestration that was closed with an additional device, one for recurrent cyanosis 3 years following fenestration closure, at which time a veno-venous collateral was successfully occluded. Clinical follow up duration for all patients was 8.1 (5.3-10.6) years. Oxygen saturation at last follow up was 96 (94-98)% and did not decrease over time ( $p < 0.05$ ). One patient (2%) developed protein losing enteropathy 1.8 years after fenestration closure, 1 (2%) had heart transplant 4.1 years after fenestration closure, and 1 (2%) patient expired 9.4 years following fenestration closure. No patient required fenestration creation to decompress the Fontan circuit.

**Conclusions:** Transcatheter Fontan fenestration closure leads to sustained increases in systemic arterial oxygen saturation and a low incidence of adverse outcomes such as death and transplant. Further study comparing fenestration closure to non-closure and longer follow up duration are required to determine if there is a survival benefit to fenestration closure.

### 73. RADIATION FREE CARDIAC CATHETERIZATION WITH MRI GUIDANCE – FIRST TEN CASES

Yousef Arar, MD<sup>1</sup>, Riad Abou Zahr, MD<sup>1</sup>, Tarique Hussain, MD, Ph.D<sup>1</sup>, Jennifer Hernandez, MD<sup>1</sup>, Gerald Greil, MD, Ph.D<sup>1</sup>, Sébastien Roujol, Ph.D<sup>2</sup>, Mari Nieves Velasco Forte, MD<sup>2</sup>, Surendranath R. Veeram Reddy, MD<sup>1</sup>

<sup>1</sup>UT Southwestern, Dallas, USA. <sup>2</sup>King's College London, London, United Kingdom

**Introduction:** Cardiac MRI (CMR)-guided right heart catheterization is feasible and safe in children and adults. During this presentation, we describe our early institutional experience performing real-time interventional CMR (iCMR) procedures in the Phillips Ingenia 1.5 Tesla Magnet (Philips Healthcare, Best, NL). We also report our experience with the MRI compatible wire (angled-tip Emeryglide MRWire, Nano4Imaging, Aachen, Germany), which we have utilized in right and left heart catheterization (RHC and LHC, respectively).

**Methods:** 10 [7 single ventricle (SV) and 3 bi-ventricular (BiV)] patients underwent an iCMR procedure in the Phillips Magnet co-located adjacent to the Phillips AlluraClarity catheterization laboratory (Philips Healthcare, Best, NL). A dilute gadolinium-filled balloon-tip catheter (1 part gadolinium to 100 parts saline) was used for RHC and LHC under real-time MRI visualization. A novel passive catheter tracking technique with a partial saturation (pSAT) pulse between 30-40 degrees was used to visualize the gadolinium-filled balloon and cardiac structures.

**Results:** 10 CHD patients with a median age of 5 years (3months-17years) and weight of 19.1 kgs (7.6-54.2kgs) underwent an iCMR procedure. 7 of 10 patients had SV anatomy: 1 BT shunt patient for pre-Glenn evaluation, 4 post Glenn patients for pre-Fontan evaluation, and 2 post Fontan patients for PLE/cyanosis evaluation. 2 of the 3 BiV were TOF patients for RV volume and branch pulmonary artery stenosis evaluation and the remaining BiV patient had severe coarctation with suspected transverse arch hypoplasia.

Real time MRI-guided RHC and LHC with aortic pull back was successfully performed in 9 and 5 patients, respectively. Technical difficulty in completing RHC occurred in one post Glenn patient (a 4-year old) due to poor visualization of the gadolinium-filled balloon in the Glenn pathway. The MRI compatible wire was used successfully in one SV (prograde LHC) and one BiV (retrograde LHC). No complications were encountered.

**Conclusion:** We have demonstrated that diagnostic right and left heart iCMR procedures are safe and feasible in both single and two ventricle pediatric CHD patients. The pSAT pulse facilitates simultaneous visualization of the catheter balloon tip, MRI compatible wire, and cardiac anatomy during iCMR procedures.

### 74. TRANSCATHETER CLOSURE OF SINUS VENOSUS ASD

Edwin Francis, Annu Jose, Bijesh Viswambaran  
Lisie Hospital, Cochin, India

Atrial septal defects accounts for 8-10% of congenital heart defects of which sinus venosus type of ASD constitutes 5%. Surgical closure has been the norm for sinus venosus ASD till recent attempts at transcatheter closure of the same by deploying a stent in the superior vena cava. We report two cases of transcatheter closure of sinus venosus ASD

Our first case is a 36 years old lady who presented with complaints of occasional palpitation and dyspnea on exertion of recent onset. She was diagnosed to have an atrial septal defect 4 years ago during her second pregnancy. On examination she had a 2/6 ejection systolic murmur in left upper sternal border and wide fixed split second sound. Her echocardiography showed a sinus venosus type of ASD with right upper pulmonary vein draining into the SVC RA junction.

The second case is a fifty years old manual labourer who was recently detected to have a sinus venosus defect during an evaluation done for cough and fever. He complained of functional class II dyspnea on exertion.

Both the patients underwent cardiac catheterization under general anesthesia and TEE guidance. The sinus venosus defect and the anomalous RUPV was demonstrated. A pulmonary angiogram done in LAO cranial and lateral views with a sizing balloon kept inflated in the low RSVC (covering the area of entry of RUPV into SVC-RA junction as well as the septal defect) showed unobstructed right upper pulmonary venous drainage in its levophase. A 10 zig 7.5x24 covered cheatham platinum stent premounted over 24x12 BIB balloon was deployed under TEE and fluoroscopic guidance. Post deployment pulmonary angiogram showed unobstructed RUPV drainage with no evidence of any residual left to right shunt. The patient was discharged on aspirin and warfarin combination. The warfarin was subsequently discontinued on first follow up at 1 month. A follow up transesophageal echo showed good stent position, unobstructed flows with in the stent and RUPV as well as no residual shunt.

**Conclusion:** Transcatheter closure of SV ASD can be considered as an alternative to surgical option with appropriate planning in a patient with suitable anatomy

#### **75. DROPPING THE ANCHOR: A NOVEL APPROACH TO ALTER GUIDEWIRE STIFFNESS FOR TRANSCATHETER BALLOON DILATION AND STENT PLACEMENT WITH DIFFICULT VESSEL ACCESS.**

Rodrigo Rios<sup>1,2</sup>, Jesse Lee<sup>2,3</sup>, John Moore<sup>2</sup>, Howaida El-Said<sup>2</sup>

<sup>1</sup>Children's Minnesota, Minneapolis, USA. <sup>2</sup>Rady Children's Hospital/UCSD, San Diego, USA. <sup>3</sup>Children's Hospital of San Antonio, San Antonio, USA

**Background:** Stenoses of vascular structures are commonly in the congenital cardiac catheterization laboratory. Establishment of guide wire position across a stenotic lesion is necessary to perform interventions. Losing wire

position in small distal vessels during the exchange process is common with stiff guide wires. We describe a novel technique in which a flexible and steerable guide wire, 0.035" Wholey wire (Medtronic, Minneapolis, MN), is anchored in distal vessels allowing for tracking of sheaths and balloon catheters eliminating the need to exchange for stiff guidewires.

**Methods/Results:** We describe case examples where we used this technique during interventions on pulmonary veins or pulmonary arteries when stiff wire position was difficult to obtain or maintain. Several key manipulations are required:

1. Utilizing a steerable catheter, the wire is advanced distally in the vessel. The catheter should be advanced as close to the distal tip of the wire
2. Utilizing a torque device, the wire is rotated 10 to 20 times. This further advances the wire distally in the vessel locking the wire in place. The wire, locked in place, is utilized for interventions. Altering the tension allows tailoring guidewire stiffness to allow for balloon catheter exchanges.
3. To remove the wire, the catheter is re-advanced as far distally over the wire as possible. The torque device is then utilized to rotate the wire in the opposite direction the same number of rotations disengaging the wire allowing removal. If freeing the wire proves difficult, a 5 or 6 French dilator, from a long sheath, may be used in place of the glide catheter to provide extra support and prevent unravelling of the wire tip.

**Conclusions:** We describe a novel technique in which an 0.035" Wholey guide wire can be anchored and utilized as a working wire facilitating the establishment and maintenance of guide wire position for stenoses that require complex wire and catheter manipulations.

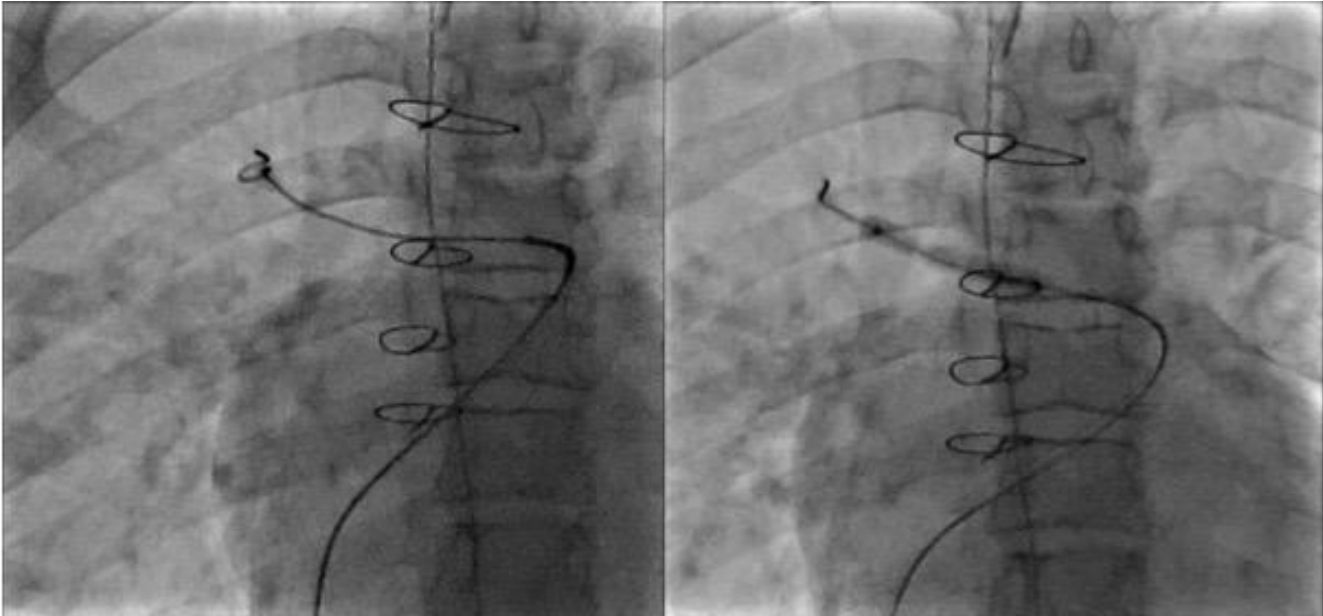
#### **76. THE RELATIONSHIP BETWEEN MATERNAL PERINATAL RISK FACTOR EXPOSURE AND CHILDHOOD CONGENITAL HEART DISEASE: A CASE-CONTROL STUDY IN TIBET**

Yipin ZHAO

Second Affiliated Hospital of Zhengzhou University, Zhengzhou, China

**Background:** This study aims to investigate the relationship between maternal perinatal risk factors exposure and the incidence of congenital heart disease (CHD) in children and provide reference for prevention and control of the disease.





**75. Figure.** Patient with recurrent right pulmonary vein stenosis. Stiff wire positioning could not be maintained due to difficult course and small distal vessels. Successful angioplasty accomplished with anchored Wholey wire.

**Methods:** This study was designed as a case-control study. 331 children with CHD were selected as the study subjects. 331 healthy children living in the same environment, age, and gender were selected as the control group. A face-to-face questionnaire survey was conducted on the mother's risk factors. Analysis of risk factors using multivariate logistic regression analysis.

**Results:** Cold during pregnancy (OR=32.660, 95%CI: 2.843~376.319), use of antibiotics during pregnancy (OR=14.645, 95%CI: 1.152~55.074), maternal passive smoking during pregnancy (OR=5.288, 95%CI: 1.076~25.995), fathers drinking (OR = 9.903, 95%CI: 2.860~ 34.293), patient parity (OR = 3.834, 95%CI: 1.923~7.644) as a risk factor for CHD, can increase the risk of fetal CHD, the mother during pregnancy Acceptance of health education as a protective factor (OR = 0.002, 95% CI: 0.000~0.028).

**Conclusion:** The incidence of CHD in Tibet is related to the exposure of risk factors during peri-pregnancy. Actively conducting health education and taking targeted prevention and control measures will help reduce the incidence of CHD in this area.

## 77. QUANTIFICATION OF IMPROVEMENT IN PULMONARY VASCULAR RESISTANCE AFTER RELIEF OF FONTAN OBSTRUCTION

Joshua Yell<sup>1</sup>, Michael Seckeler<sup>2</sup>

<sup>1</sup>University of Arizona College of Medicine-Tucson, Tucson, USA. <sup>2</sup>Department of Pediatrics (Cardiology), Banner University Medical Center/University of Arizona, Tucson, USA

**Background:** Patients with single ventricle congenital heart disease undergo staged surgical palliation through Fontan completion. Reliance on passive pulmonary arterial flow leads to systemic ventricular preload and cardiac index (CI) becoming primarily determined by pulmonary vascular resistance (PVR). Pulmonary vasodilators, such as Sildenafil, appear to improve CI by lowering PVR. Lower Fontan pressure has been shown after relieving stenoses within the Fontan, but to date the effect on PVR has not been quantified. The purpose of this study is to report the improvement in PVR after relief of Fontan stenosis.

**Methods:** Retrospective, single-center review was conducted with 3 patients post-Fontan who underwent cardiac catheterization with hemodynamics, pulmonary vasodilator testing and stenting of stenosis in the Fontan conduit from January 2017 – February 2018. All procedures were performed under general anesthesia. Baseline hemodynamics were obtained on 21% FiO<sub>2</sub>, followed by administration of 80 ppm iNO for 5 minutes with repeat

**77. Table.** Demographics and hemodynamics at baseline, with nitric oxide testing and after Fontan stent placement. Data are presented as median (intraquartile range) or n (%).

Age (y)	29 (18-33)
Female (n, %)	1 (33)
Fontan pressure (mmHg)	12 (12, 16)
Gradient (mmHg)	2 (2, 2.5)
Final Fontan pressure (mmHg)	13 (13, 17)
Final gradient (mmHg)	0 (0, 0)
Baseline CI (L/min/m <sup>2</sup> )	1.52 (1.46, 3.08)
Increase on iNO (%)	+19.3 (7.4, 34)
Increase post-stent (%)	+46.4 (18.9, 46.9)
Baseline PVR (iWu)	2.49 (1.73, 2.98)
Decrease on iNO (%)	-25.7 (-39.7, -19.6)
Decrease post-stent (%)	-28.9 (-32.1, -27.9)

hemodynamics. After stenting of the Fontan stenosis, hemodynamics were repeated on 21% FiO<sub>2</sub>. Data collected included demographics, hemodynamics in each condition and percent increase in CI and percent decrease in PVR on iNO and post-stent.

**Results:** Demographics and hemodynamics are shown in the Table. There was complete relief of the gradient after stent placement in all patients; post-stent Fontan pressure increased secondary to transient contrast-induced rise in ventricular end-diastolic pressure. There was an increase in CI and decrease in PVR with iNO and after stent placement.

**Conclusions:** This case series provides novel data quantifying the decrease in PVR after relief of Fontan stenosis, suggesting a mechanism to explain previous reports of decreased lower extremity edema, increased exercise tolerance and improvement in protein losing enteropathy. Larger studies will likely confirm the significance of these findings, but these data are a compelling addition to the long term management of this complex patient population.

## 78. TACKLING THE SHUNT LESION WITH LUNG PATHOLOGY: CASE BASED LEARNINGS

Neeraj Awasthy

max hospital, delhi, India

Pulmonary issues are an important confounding factors determining pulmonary artery hypertension

Presence of lung pathology in any shunt lesion is itself a diagnostic dilemma, not only to determine the feasibility of the closure of the cardiac defect but also ascertain the operability in such a case. We present case based scenarios (in large ASD and nonrestricted vsd) to show the importance of percutaneous device closure in these subsets, especially when associated pulmonary pathology was considered not suitable to undertake shunt closure. A 56 year old female with Ostium secundum Atrial Septal Defect presented in NYHA class IV presented with chest infection. Transthoracic echo revealed 30 mm ASD with bidirectional shunt, with tricuspid regurgitation max PG of 85 mmHg and right ventricle dysfunction. She was intubated and put on mechanical ventilator. CT chest showed right lower lobe bronchiectasis with infective changes. However repeated attempts to wean patient off bipap support were unsuccessful. Subsequently cardiac catheterization and Balloon Occlusion of ASD revealed Qp/Qs ratio of 5:1 with step up in oxygen saturation of 19%. She underwent successful device closure for ASD with AMPLATZER septal occluder (36mm) (AGA Medical Corp., Minneapolis, MN, USA). Her physical activity and symptoms improved. Follow-up echocardiography after 5 months revealed normal right ventricle contractility and no PAH. While initially chest infection prevented ASD device closure, underlying bronchiectasis which got worsened by ASD shunt, prevented her from weaning off ventilator. Atrial Septal Defect device closure thereby helped to reduce pulmonary blood flow and improvement in lung function enabling her to wean off ventilator support. Case 2: 8 year old child with 10 mm non restricted vsd with dextrocardia and Kartagener's syndrome was found not suitable for closure in view of marked lung issues, bronchospasm and repeated chest infection. Patient underwent percutaneous vsd device closure through antegrade approach using 10/12 duct occluder device with significant resolution of symptoms. We postulate that in view of disease lung segment, rest of the lung segment get flooded with the flow through the shunt lesions and compromise lung compliance. The closure of defects in such situations greatly facilitates the symptomatic improvement.

## 79. PERCUTANEOUS CLOSURE OF A LEFT VENTRICULAR PSEUDOANEURYSM IN A REDO POST MVR PATIENT: LEARNINGS FROM THE LARGEST REPORTED CASE

Neeraj Awasthy

Max Saket, Delhi, India

Percutaneous device closure of a left ventricular pseudoaneurysm have been rarely reported. We describe the case

of a 60-year-old woman with a history closed mitral valvotomy at 18 years of age, Mitral Valve (MV) replacement at 53 year of age in Feb 2016 at 60 year of age. She presented with shortness of breath and chest pain since for 2 weeks. Echocardiography (Echo) revealed left ventricle pseudoaneurysm with neck size of 12mm. Cardiac MRI showed a large left ventricle pseudoaneurysm (36x32 mm) that was filling from a small leak in the anterolateral aspect of the ventricle. Considering high-risk candidate for surgical treatment in view of three previous sternotomies, the pseudoaneurysm was closed percutaneously with use of a 16-mm AMPLATZER muscular VSD occlude successfully. The patient was discharged from the hospital the next day and was asymptomatic on followup.

#### 80. EXPERIENCE IN TRANSCATHETER INTER-ATRIAL DEFECTS DEVICE CLOSURE IN PATIENTS WITH PULMONARY ATRESIA AND INTACT VENTRICULAR SEPTUM

*Marhisham Che Mood<sup>1,2</sup>, Keijiro Ibuki<sup>1</sup>, Mazeni Alwi<sup>1</sup>*

<sup>1</sup>National Heart Institute, Kuala Lumpur, Malaysia. <sup>2</sup>

**Background:** Pulmonary atresia and intact ventricular septum (PA-IVS) is a rare congenital heart defect comprises of membranous atresia of pulmonary valve or RVOT muscular atresia and intact ventricular septum. Those with membranous atresia will require radiofrequency valvotomy + ductal stenting depending on the right ventricular size. Those with muscular atresia and borderline RV size may require RVOT reconstructive surgery + cavo-pulmonary shunt. In this group, inter-atrial communications are often left open during the treatment process. There are limited reports about the inter-atrial defect device closure for PA-IVS patients. The objective is to describe the results of transcatheter closure of inter-atrial communication in PA-IVS patients.

**Methods:** A total of 18 patients were enrolled (14 ASD cases and 4 PFO cases). The major indication was cyanosis for 14 patients. Two of these patients with low oxygen saturation underwent the procedure during early period after surgery (post-operative day 1 and 19 respectively).

**Results:** 14 patients had achieved 2 ventricular circulation and 4 patients with one and half ventricular circulation. 2 device complication were reported (1 device malposition and 1 device embolization) and both had successful device retrieval and re-implantation procedure. Median follow up was 14 months (3 months-129 months). All defects were completely closed without residual shunt. All patient were asymptomatic for heart failure and echocardiography in all

patients showed good ventricular function on subsequent follow up.

**Conclusion:** Transcatheter inter-atrial defect occlusion for PA-IVS patients is effective procedure with high success rate. On the other hand, judicious consideration is necessary to decide on appropriate device size due to high risk of device embolization.

#### 81. PERCUTANEOUS RE-TREATMENT OF PATIENTS WITH STENTED AORTIC COARCTATION AT EARLY AGE.

*Manuel Pan, Miguel Romero, Soledad Ojeda, Francisco Hidalgo, Javier Suárez de Lezo, Adrián Lostalo, Aurora Luque, Rafael González, Ernesto Martín, Francisco Mazuelos, José Segura, Cristina Pericet, Elena Gómez*  
Reina Sofía Hospital, Córdoba, Spain

The aim of our paper is to assess the efficacy and safety of the re-treatment in patients with stented aortic coarctation at early age, several years after the stent implantation, when the aorta reached a near definitive size. From 1993 to 2018, 177 patients with coarctation of aorta were treated in our center by stent implantation. For our study, we selected those patients who were treated by stent implantation younger than 12 years and required re-treatment because of their rate of growth (n=33). The age at the first procedure was  $6.6 \pm 3.5$  years and at the second procedure  $18.7 \pm 7.2$  years. So, the time between stenting of the aorta and re-treatment was  $13 \pm 5$  years. In this time interval, the aorta grew from  $8.3 \pm 3.3$  mm to  $12.3 \pm 4.5$  mm at the level of isthmus below the subclavia and from  $10.9 \pm 2.7$  mm to  $17.4 \pm 4.9$  mm at the level of the diaphragm. At the second procedure, 15 (45%) patients were treated with balloon re-expansion and 18 (55%) by re-stenting. Stent fracture was a frequent finding before re-treatment (n=13, 39%). Primary success was obtained in 32 patients (97%). An immediate reduction of the peak gradient across the coarctation was obtained in all of them. The final residual gradient was  $6 \pm 6$  mmHg. In the patient without primary success the stent remained unexpanded despite repeat dilations. There were no major complications. After the coarctation re-treatment, the minimal lumen diameter at the level of the coarctation changed from  $3.5 \pm 1.8$  mm to  $10.6 \pm 5.6$  (p<0.05). The mean follow-up time after the second procedure was  $5 \pm 4$  years. A third procedure was required in 3 patients (9%) in whom the stent was implanted when they were younger than 2 years. Only 1 additional patient continued with controlled hypertension (treatment with 1 drug) despite a successful re-treatment procedure. The remaining patients are currently asymptomatic and free of

systemic hypertension after 5±4 follow-up. Conclusions: Patients with aortic coarctation treated with stent at early age, can be successfully re-treated by balloon dilation or re-stenting after the completion their somatic growth.

## 82. THREE-DIMENSIONAL PRINTING AND DYNAMIC TESTING PRIOR TO PULMONARY VALVE REPLACEMENT

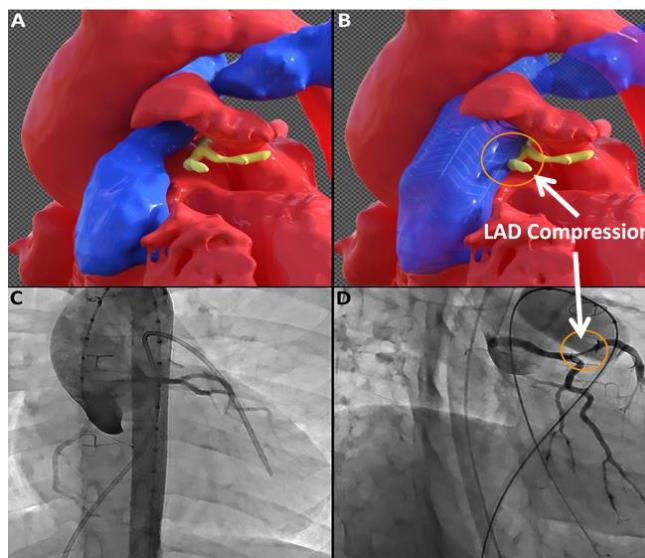
R. Allen Ligon, Sassan Hashemi, Timothy Slesnick, Christopher Petit

Children's Healthcare of Atlanta - Emory University School of Medicine, Atlanta, USA

**Background:** Three-dimensional (3D) virtual and printed models have emerged as promising tools in the planning of interventions for patients with complex congenital heart disease (CHD). 3D replications can provide vital anatomic information to operators in planning pediatric cardiac interventions both by optimizing the approach and possibly, deciding if a procedural approach is achievable. Typically, these 3D models are static representations of anatomy. We describe our approach with dynamic testing on 3D models of CHD prior to pulmonary valve intervention.

**Methods:** 9 patients underwent 3D modeling and printing prior to planned transcatheter pulmonary valve replacement (PVR) or surgical intervention. These patients underwent preprocedural cardiac magnetic resonance imaging (cMRI) or computed tomography (CT). From their imaging data, replications in the form of 3D virtual datasets (*see figure*) and 3D physical prints were generated. Dynamic evaluation of 3D models was performed with increasing diameter balloons to test for coronary artery (CA) compression. Results of 3D modelling analysis were compared with actual procedural results during transcatheter PVR.

**Results:** Of the 9 patients who underwent 3D modeling and printing, 4 were referred for surgical repair. The 5 remaining patients were or will be taken to the catheterization laboratory for transcatheter PVR. The dynamic 3D testing indicated CA compression in 3 patients and no CA compression in the remaining 2. In 2 of the patients with suspected CA compression, test dilation of the 3D renditions at diameters of 16mm and 18mm were normal. However, CA compression was subsequently suggested during dilation with an increase to an 18mm or 20mm balloon, respectively (*see figure*). These patients were taken to the cath lab for PVR and during angioplasty of the conduit were noted to have CA compression at the 18mm and 20mm balloon diameters, just as the 3D models had



predicted. These patients were ultimately referred for surgical PVR.

**Conclusions:** Anatomic 3D modelling is increasingly important in interventional and surgical planning for patients with CHD. However, dynamic 3D assessment may unveil limitations or potential complications, and should be considered an important adjunct to pre-procedural planning.

## 84. WHAT BALLOON SIZE SHOULD BE USED IN NEONATES WITH CRITICAL AORTIC STENOSIS?

Manish Malkar, Saadeh Jureidini

Saint Louis University, Saint Louis, USA

**Background:** The optimal size of the balloon for aortic valvuloplasty (BAV) for critical congenital aortic valve stenosis (CCAS) has not been identified. An ideal balloon decreases the pressure gradient to safe level and minimizes aortic regurgitation (AR).

**Methods:** We retrospectively reviewed data from neonates with CCAS who underwent BAV from the year 1999 through 2018. We aimed to determine the balloon size that reduces pressure gradient across aortic valve to safe level and minimizes AR.

**Results:** Twenty consecutive neonates with CCAS underwent BAV in the first 15 days of life. The balloon size used were ≤ 6 mm (group 6; n=12) and ≥ 7 mm (group 7; n=8). The birth weights were similar in both groups (P=0.1). Although the aortic valve annulus size in group 7 was

larger than group 6 ( $7.78 \pm 0.37$  vs  $6.67 \pm 0.7$  mm,  $P=0.004$ ), frequent overlap in absolute measurements occurred. The gradients decreased significantly ( $P<0.0001$ ) and similarly in two groups ( $P=0.46$ ). Post BAV, no or trace AR occurred in all infants in group 6 while in group 7 there was no or trace AR in 3(37.5%), mild AR in 4(50%) and moderate to severe AR in 1(12.5%) ( $P=0.004$ ). On 2-3 month follow-up, echocardiogram demonstrated 50% incidence of moderate to severe AR (3 out of 6) in infants with residual peak gradient of  $< 15$  mmHg post BAV. This incidence was 7% (1 out of 14) in infants with residual gradient of 15 to 30 mmHg ( $P=0.07$ ). On long term follow up (median 10 years), 4 infants (50%) in group 7 needed surgeries for AR (3-Ross operation, 1-aortic valve repair) while 1 needed Ross operation (7%) in group 6. Increasing pressure gradient across aortic valve needed repeat BAV in 4(33%) infants in group 6 vs 1(12.5%) infants in group 7 ( $P=0.33$ ). No mortality occurred.

**Conclusion:** Balloon size  $\leq 6$  mm adequately decreases pressure gradients to safe level ( $\leq 30$  mmHg) and minimizes AR. Repeat BAV as in group 6 carries less morbidity than surgeries for AR as in group 7. Thus, a  $\leq 6$  mm balloon is ideal for CCAS.

#### 85. VIRTUAL REALITY CARDIAC MODELLING FOR ANATOMIC EVALUATION OF PATIENTS WITH COMPLEX SINGLE VENTRICLE ANATOMY

Jenny E. Zablah, Michael Dimaria, Daniel Ehrmann, Michal Schafer, Daniel Vargas, Gareth Morgan, Neil Wilson, Michael Ross

University of Colorado School of Medicine, Aurora, USA

**Background:** Virtual Reality imaging (VR) is a novel imaging modality, with potential to provide more rapid assimilation and profound understanding of complex three-dimensional structures in congenital heart disease. Three dimensional(3D) reconstructions for use in VR can be created from computed tomographic angiography(CTA) or cardiac magnetic resonance imaging(cMRI) datasets. Patients undergoing staged palliation of single ventricle frequently require cross-sectional imaging related to poor visualization of crucial aspects of the anatomy using ultrasound. Based on the hypothesis that VR will provide both material and intangible advancements in comprehension of complex anatomy compared to traditional measurement of CT datasets, we sought to validate our novel measurement tool in a VR environment.

**Methods:** We developed a VR visualization software platform that enables assessment of 3D cardiac models derived

from CTA. A retrospective chart review identified infants with shunt dependent pulmonary blood flow who had CTA performed between January 2010 and September 2015. All gold-standard measurements of the proximal branch pulmonary arteries, aortic isthmus and descending aorta were performed using multiplanar reconstruction of a CTA dataset to achieve mutually orthogonal planes by a single investigator. 3D virtual models were created from the CTA dataset using Materialise Mimics 2.0 and uploaded in our VR environment. Using Oculus Rift goggles and our novel measurement tool, the same structures noted above were also measured by selecting two points on opposite sides of the vessel wall of interest. The measurements were compared using intraclass correlation coefficients and Bland-Altman plots.

**Results:** 22 patients were included. The VRI-derived measurements demonstrated excellent correlation and agreement with the CTA measurements with a mean difference of  $0.2\text{mm} \pm 0.7\text{mm}$  ( $r=0.98$ ) for descending aorta,  $0.3\text{mm} \pm 0.7\text{mm}$  ( $r=0.93$ ) for aortic isthmus,  $0.31\text{mm} \pm 1\text{mm}$  ( $r=0.99$ ) for LPA and  $0.33\text{mm} \pm 1\text{mm}$  ( $r=0.98$ ) for RPA. Aortic arch measurements showed stronger correlation when compared with the proximal pulmonary arteries.

**Conclusion:** We developed a novel tool for visualization and measurement of complex 3D structures in a VR environment showing excellent correlation and agreement of vessel diameter assessment with the gold standard approach. There was higher variability in VR assessment of pulmonary artery diameter maybe due to difficulty identifying common landmarks in the postsurgical anatomy.

#### 86. TO STUDY THE SAFETY, FEASIBILITY OF TRANSCATHETER CLOSURE OF DOUBLY COMMITTED SEPTAL VSD USING DUCT OCCLUDER DEVICE.

Muthukumaran Sivaprakasam, Anuradha Sridhar, Rajesh Kumar

Apollo Children Hospital, Chennai, India

**Introduction:** Doubly committed defect is defined as perimembranous extension with fibrous continuity between the leaflets of the aortic and tricuspid valves as well as between the aortic and pulmonary valves. A doubly committed defect used to be a contraindication for device closure.

**Method:** Total 20 patients were selected for transcatheter closure for doubly committed septal VSD. Mean age of the patients was 4 years (1-11 years).

**Inclusion Criteria:** Body weight > 8 Kg, No severe aortic valve prolapse, No moderate to severe AR, True defect  $\leq$  6 mm, No other cardiac abnormalities.

**Procedure:**

**Echo:** Profiling the VSD and to determine the distance of the VSD from aortic and pulmonary valve.

**LV Angiography:** In LAO 60-80° with cranially tilted view instead of standard LAO 45-55° & cranial 20°.

**Approach:** These VSDs can be crossed both retrogradely and antegradely .

**Hardware:** Judkin's RCA catheter (for crossing the defect antegradely) or cut Pigtail catheter (for crossing retrogradely)

**Selection of device:** If the VSD is located close proximity to the aortic valve or if it is associated with AR, low profile device like duct occluder-II is used.

**Results:** Antegrade approach was used for 12 of them and VSD closure was done using duct occluder-I device. Retrograde technique was used for other 6 patients & duct occluder-II was used. Predominant patients (10) had mild, AVP, 7 patients no AVP, 1 patients had moderate AVP. Mean follow up period was 9 months (3- 12) months. 12 out of 18 patients had no AR, 6 patients had Trivial AR. Technical success in 18/20 (90%). Two patient developed moderate AR post device deployment for which patient sent for surgery. Post device closure showed small residual shunt in 4 (18) patients. Median duration of follow up is 12 months (6-34 months). AR at 6 months follow up: Trivial/Mild:4/18 (22%), Moderate 0/18.

**Conclusion:** Closure of doubly committed VSDs can be done by transcatheter technique is possible in certain patients. Proper selection of patient is important for successful device closure. Long duration of follow up should be evaluated to look for the feasibility of device closure in these type of defects.

### 87. PERCUTANEOUS PULMONARY VALVE IMPLANTATION WITH OVEREXPANSION OF THE DIFFERENT TYPE AND SMALL CONDUITS

Ahmet Celebi, Ilker Kemal Yucel, Mustafa Orhan Bulut  
Siyami Ersek Hospital for Cardiology and CV Surgery, Istanbul, Turkey

**Background:** Percutaneous pulmonary valve replacement (PPVR) has not been feasible in patients with small right ventricular outflow tract conduits. It is also not recommended to dilate more than 2 mm than the nominal size of the conduits. We present our results of PPVR in patients with a small conduits dilated beyond its nominal diameter.

**Methods:** Between 2012 and 2017, 62 patients with severe conduit dysfunction underwent angiography for PPVR. 21 of them needed dilation to a final diameter of 23 mm, since the nominal conduit diameter was small (either  $\leq$ 16 mm or between 17-19 mm). To avoid conduit rupture, a covered stent was employed and PPVR was performed after gradual dilation of the covered stent with non-compliant balloons.

**Results:** The mean age and weight were 11.3 years (5-18) and 38 kg (18-60), respectively. The mean nominal diameter of the conduits was  $15.7 \pm 1.4$  (13-19) mm. The initial diameter was  $\leq$  16 mm in 14 patients. The type of conduits was Contegra in eight, Labcor in five, Homograft in three, Shelhigh in three, Hemashield in one, and PTFE in one. PPVR was abandoned upon detection of coronary compression in two. A Melody valve was implanted in 16, while a Sapien valve (20 and 23 mm) was used in three. Melody valves were implanted using 22 mm balloons in 11 and 20 mm in five. The mean narrowest diameter of the conduit increased from  $12.3$  (6.4-15.8) mm to  $20.2$  (17-23). The mean diameter of the conduits increased by 4.8 mm (1-8). There was no complication related to the procedures. The mean right ventricle (RV) pressure and RV-pulmonary artery pressure gradient were decreased from 80 (61-116) mmHg and 51 (20-96) mmHg to 37 (27-50) and 8.3 (0-16) mmHg, respectively. Infectious endocarditis responded to medical treatment was seen in one during the follow-up of 27 months. The last echocardiographic examination revealed a pressure gradient of  $25 \pm 11$  mmHg across the conduits.

**Conclusion:** Different types of conduits can be dilated gradually even beyond their nominal diameters. The use of a covered stent eliminates the risk of rupture and ensure implantation with larger valves.

### 88. TRANSCATHETER CLOSURE OF CONGENITAL VENTRICULAR SEPTAL DEFECTS

Ana Maria de Dios<sup>1,2</sup>, Julio Cesar Biancolini<sup>1,2</sup>, Maria Fernanda Biancolini<sup>1,2</sup>, Victorio Lucini<sup>1,2</sup>, Judith Ackerman<sup>1</sup>, Adelia Marques<sup>1</sup>, Jesus Damsky Barbosa<sup>1</sup>, Ignacio Lugones<sup>1</sup>  
<sup>1</sup>Pedro Elizalde, Buenos Aires, Argentina. <sup>2</sup>Sanatorio Trinidad Mitre, Buenos Aires, Argentina

**Material and Methods:** Transcatheter device implantation was accepted in 77 patients (p) with congenital VSD until 2016. All patients have transthoracic echocardiography initially, and TEE during all the time. The criteria for inclusion were clinical and/or echocardiographic evidence of a significant left to right shunt.

**The first cycle (35p):** The median age was  $9.7 \pm 7$  years. Devices was: 21p Amplatzer device (7p PM, 14p M) y 1p PDA device. 14 Nit Occlud VSD devices (13 PM, 1 M). The attempt to place device was successful in 34 patients (96.5%).

**Complications:** 21p con Amplatzer PmVSD occluder: 1p tricuspid regurgitation (no surgery), 3p light disrhythmia, 3p complete block atrio-ventricular (2p VSDpm y 1p infundibular muscular (2p transitory, 1 pace maker); 2p left anterior hemiblock (2 CIV M). 14p NIT OCCLUD device: 1p embolization, 1p light aortic regurgitation, 2p transitory haemolysis. Cox proportional hazards regression analysis showed that the age (<5 years) and weight (<5 Kg) was the variable significantly associated with of complication during the procedure ( $P=0.025$ ; relative risk 0.22).

**The second cycle (47p):** 51 procedures were performed in 47p. Median age was 7 years old (range 0,33 to 15y). Median weight was 26 Kg (range 4,3-83Kg); 5 procedures in p less than 10Kg. 3p had residual POP VSD, the rest were native. 2p had multiple VSDs: 1p had 2 VSDs closed in the same procedure; the other needed 3 different procedures. 43 procedures were **successful (84,3%)**, 41 in the first attempt and 2 needed a second procedure.

**Size of the VSD:** Median diameter of left orifice was 9.3mm, right orifice 4.7mm and median length of 7.12mm. 12 VSDs had more than one right orifice.

**Complications:** 3p **major complications (6,3%)**: 1p tricuspid stenosis, 1p hematuria with decrease in blood count; 1p, <10kg with muscular VSD and no aortic prolapse, had severe aortic insufficiency immediately post procedure and died. 6p required surgery (**11,7%**).

**Conclusion:** Transcatheter closure of congenital VSD offers encouraging results. Complications are limited; the most relevant one is complete atrioventricular block in perimembranous VSD. More experience and long-term follow-up are mandatory to assess its safety and effective

## 89. NOVEL USE OF A COVERED CP STENT TO CONVERT HEPATIC VEIN EXCLUSION FONTAN TO A COMPLETE (FENESTRATED) FONTAN

Sarosh Batlivala<sup>1</sup>, Makram Ebeid<sup>2</sup>

<sup>1</sup>Cincinnati Children's Hospital Medical Center, Cincinnati, OH, USA. <sup>2</sup>University of Mississippi Medical Center, Jackson, MS, USA

**Background:** This is a 4 year old patient with heterotaxy, dextrocardia, mitral atresia, pulmonary atresia, d-malposed great vessels, and supracardiac totally anomalous pulmonary venous return (TAPVR). She underwent TAPVR repair and central shunt placement in the first week of life, then bidirectional Glenn procedure at 5 months of age. Patient did well in the interstage and post-Glenn periods. Pre-Fontan catheterization demonstrated normal PVRI of 1.8 WUI though Glenn pressures were 16mmHg and pulmonary arteries were mildly hypoplastic diffusely. One right-sided hepatic vein was left draining directly to the atrium, with the other hepatic veins draining normally to the IVC. Given the dextrocardia and borderline PA anatomy, an extra-cardiac Fontan (18mm) was performed, excluding the one hepatic vein. Patient had a tenuous post-operative course related acute conduit obstruction related to her dextrocardia. Placement of a conduit stent was needed in immediate post-op period with a slow recovery. Patient then developed slowly progressive and profound hypoxemia related to massive right-to-left shunting via hepato-hepatic venous collaterals (SpO<sub>2</sub> 65% and Hb 22.4 gm/dL). These collaterals allowed systemic venous blood to bypass the pulmonary arteries and flow directly into the atrium, eventually resulting in limited antegrade pulmonary blood flow. An 8zig, 22mm long covered CP stent was modified by cutting a small hole (~1mm) in the ePTFE lining one-third from the stent edge. During catheterization, an 0.018" wire was advanced into the largest hepatic vein connected to the IVC. The back-end of this wire was placed through the side-hole of the CP stent, and the stent then mounted on an 18mm BIB. The stent was deployed, then 4mm and 6mm Sterling balloons were used to dilate the side-hole, creating a functional "fenestration". The procedure was well tolerated, with SpO<sub>2</sub> rising to 85% in room air immediately, and symptoms improving over coming months. Follow-up echocardiography demonstrated ~4mmHg fenestration gradient and normal hepatic venous Doppler signals (i.e. no stasis). Hepatic elastography will be followed serially.

**Conclusion:** CP stents can be modified to serve unique needs of maintaining access to "jailed" vessels and creating fenestrations for decompression.

### 90. PERCUTANEOUS CLOSURE OF NEONATAL COMPLEX VSD WITH THE NEW KONAR-MF MULTIFUNCTIONAL OCLUDER DEVICE

Liliana Ferrin<sup>1</sup>, Jesus Damsky Barbosa<sup>2</sup>, Marcelo Rivarola<sup>3</sup>, Victorio Lucini<sup>2</sup>, Jose Alonso<sup>4</sup>

<sup>1</sup>Corrientes Cardiology Institute, Corrientes, Argentina. <sup>2</sup>Children Hospital Pedro de Elizalde, Buenos Aires, Argentina. <sup>3</sup>Austral University Hospital, Buenos Aires, Argentina. <sup>4</sup>High Complex Hospital Juan Domingo Peron, Formosa, Argentina

Percutaneous closure of ventricular septal defect (VSD) is a successful therapeutic modality but remains challenging particularly in small patients. Congestive heart failure presentation in neonates with VSD is commonly associated with other complex lesions requiring surgical treatment without VSD resolution.

We will demonstrate the feasibility and effectiveness of percutaneous VSD closure in neonate patients with associated congenital heart diseases using KONAR-MF multifunctional occluder device (MFO).

We report 3 neonates under 4 kg weight with congenital heart diseases and non restrictive VSD with severe haemodynamics failure whom required percutaneous VSD closure at early post surgery stage.

A four month old baby, 5 kg weight, with congestive heart failure post Switch operation with residual moderate gradient at neopulmonary level was diagnosed a 5mm non restrictive muscular VSD at catheterization procedure. Therefore transcatheter closure was successfully performed with a 6-4 MFO occluder by venous antegrade right ventricular direct VSD approach, 5F sheath without arterial puncture. Non residual shunt was evidence.

A 15 days, 3 kg weight neonate with critical aortic stenosis and aortic coarctation undertook an effective valvuloplasty and coarctation angioplasty. Non restrictive 8 mm muscular VSD was showed at the procedure and surgical aortic coarctation correction was performed four days after. Because of severe heart failure, VSD transcatheter closure was attempted with a 10-8 MFO occluder by antegrade approach through the foramen ovale by 5F sheath avoiding arterial puncture.

The last patient, one month old, 2,9 kg weight, post surgical correction of Totally pulmonary venous anomaly and muscular VSD. Because of severe heart failure the residual 5 mm muscular VSD was closed with a 8-6 MFO occluder, venous approach through the foramen oval, 4F sheath.

After VSD closure the patients did well, but the first one went on sepsis and died three weeks later.

**Conclusions:** Neonates with congenital complex heart disease and associated VSD are difficult to solve by only one surgical approach. Percutaneous VSD closure with new Konar-MF (MFO) nitinol low profile occluder is an effective and safe alternative of treatment in this challenge group of patients

### 91. ENDOVASCULAR INTERVENTION IN PATIENTS WITH UNIVENTRICULAR PHYSIOLOGY: RISK FACTORS AND MEDIUM-TERM MORBIDITY AND MORTALITY

Justo Santiago<sup>1</sup>, Antonio Arias<sup>2</sup>, Juan Gallego<sup>1</sup>, Leonardo Blanco<sup>1</sup>, Claudia Flores<sup>1</sup>, Gabriela Karl<sup>1</sup>, Alvaro Duran<sup>1</sup>

<sup>1</sup>Colombian Cardiovascular Foundation, Bucaramanga, Colombia. <sup>2</sup>Colombian Cardiovascular foundation, Bucaramanga, Colombia

**Introduction:** Patients with univentricular physiology merit different interventions during their evolution and management, whose final objective is to achieve an adequate balance between pulmonary and systemic flow with a reduction in postload of the systemic ventricle. Many of these procedures can be performed endovascularly, however there is little existing literature on the overall analysis of these patients.

**Materials and methods:** In order to evaluate the medium term results in a group of patients treated at our institution, we conducted a retrospective study over a period of 2 years. The following data were investigated: demographic, main diagnosis, palliation stage, types of surgery, type and number of hemodynamic procedures, complications and results one year after the procedure. A summary and description of the variables was carried out and they were analyzed taking morbidity as a dependent variable.

**Results:** A total of 111 patients underwent cardiac catheterization during the period studied. The majority were males (63.5%), with a median weight of: 10 Kgrs and 11 months of age. The most frequent heart diseases were: Atresia tricuspidae (30%), Hypoplastic left heart syndrome (SVIH) (18.8%) and pulmonary atresia (13.5%). 75.6% of the catheterizations were therapeutic, of these the most performed procedures were: Collateral embolization (64%), balloon angioplasty (16%) and stent angioplasty (11%). There were no deaths related to catheterization. The complications in general were 10%, of which the majority (88.25%) were minor, with arrhythmias being the most frequent. Major complications were observed in 1.75% (3 cases), with stent



migration, vascular dissection and guide retention. These complications were more frequent although not statistically significant in patients less than 10 kgs. The analysis of mortality at 30 days, 6 and 12 months recorded a frequency of 3.6%, 9.2% and 19.3% respectively. The highest mortality was recorded in patients with SVIH.

**Conclusions:** There are a variety of procedures that can be performed in different groups of patients with univentricular physiology with low morbidity and mortality. The cases with SVHI are the most susceptible to merit cardiovascular interventions with lower survival at 12 months.

## 92. USE OF THE SAPIEN VALVE FOR PERCUTANEOUS TRANSCATHETER PULMONARY VALVE REPLACEMENT WITHOUT "PRE-STENTING": A MULTI-INSTITUTIONAL EXPERIENCE

Dan Levi<sup>1</sup>, S Sadeghi<sup>1</sup>, Morris Salem<sup>2</sup>, Neil Wilson<sup>3</sup>, Joseph Kay<sup>4</sup>, A Rothman<sup>5</sup>, A Galindo<sup>5</sup>, Mary Martin<sup>6</sup>, Bob Gray<sup>6</sup>, Michael Ross<sup>3</sup>, Jamil Aboulhosn<sup>1</sup>, Gareth Morgan<sup>3,4</sup>

<sup>1</sup>University of California Los Angeles, Los Angeles, USA. <sup>2</sup>Keiser Permenente, Los Angeles, USA. <sup>3</sup>Childrens Hospital of Colorado, Denver, USA. <sup>4</sup>University of Colorado, Denver, USA. <sup>5</sup>Childrens Heart Centre of Nevada, Las Vegas, USA. <sup>6</sup>Primary Childrens Hospital, Salt Lake City, USA

**Objectives:** To describe a multi-center experience of percutaneous transcatheter pulmonary valve replacement (TPVR) using the Edwards Sapien S3™ Valve without the use of a prior stent ("pre-stenting").

**Background:** Both the Sapien S3 and XT valves have durable cobalt-chromium stent frames. It has been hypothesized that they can allow for TPVR in large diameter dysfunctional right ventricular outflow tract (RVOT) without the use of other stents to buttress the landing zone. A multi-institutional experience at four centers with the SAPIEN valve for TPVR is presented.

**Methods:** A retrospective review was performed of all patients with CHD and dysfunctional RVOT who underwent TPVR using the Sapien valve without the use of a pre-stent. Imaging data, procedural elements and clinical follow-up data were collected to evaluate short and intermediate-term results.

**Results:** A total of 61 patients underwent percutaneous placement of the Sapien Valve in the pulmonary position without the use of pre-stenting. After elimination of Sapien TCPVRs performed after a surgical plication of the RVOT, a total of 57 cases remained for analysis in native RVOTs (n=41), conduits (n=10) and bioprosthetic valves

(BPVs, n=6). There were no cases in which the valve could not be implanted after introduction and no cases of valve embolization or misplacement. On short and intermediate term follow up (range 1 months (mo) to 2.2 years, median 5.3 months), no patients had significant obstruction or regurgitation around the valve requiring intervention. There were no frame fractures. There were no procedural deaths. Major complications included severe aortic compression (n=1) requiring surgical explantation and tricuspid valve injury requiring surgical intervention (n=2).

**Conclusions:** This limited multi-institutional experience demonstrates that the Sapien valve can be used for TCPVR without the use of a pre-stent without short term significant risk of frame fractures, perivalvar leak or embolization. Longer term follow-up is needed to ensure that late frame fracture is not an issue.

## 93. TRANSCATHETER CLOSURE OF ATRIAL SEPTAL DEFECT WITH THE OCCLUTECH FIGULLA ASD OCCLUDER - A COMPARATIVE STUDY WITH THE AMPLATZERSEPTAL OCCLUDER. SINGLE CENTER EXPERIENCE.

Vakhtang Khelashvili, Lilia Kapanadze, Ekaterine Kapanadze  
The Jo Ann Medical Center, Tbilisi, Georgia

**Background:** The closure of an atrial septal defect is procedure that is frequently performed in both adults and children. The most commonly used devices are the Occlutech Figulla and Amplatzer atrial septal occluders. These devices all have similar performance efficiency for the closure of secundum atrial septal defects.

**Objectives:** To evaluate and compare the performance of Occlutech Figulla and Amplatzer atrial septal occluders in the pediatric and adult population.

**Results:** We compared the results in 221 patients (73.6 % female) who underwent ASD device closure in our center using Occlutech Figulla from 2013 to February 2018 (91 patients) and Amplatzer atrial septal occluder from 2002 to 2013 (130 patients). The patients ranged in age from 3.9 to 74.2 years. There were no statistically significant differences between the two groups regarding patient baseline characteristics and procedure variables. The success rate using either device was excellent (OFSO 98.4 % and ASO 95.3 %). The median fluoroscopic time in the OFSO group was OFSO 8.7 min and in the ASO 9.4 min). All patients were followed-up with contrast transthoracic echocardiogram and clinical evaluation at 24 hours, 6 months and 12 months after the procedure. The overall median follow-up

time was 3.6 years. In all subjects, the residual shunt was small to trivial during follow up and the reduction in prevalence of residual shunt with time was similar in both groups. A high procedural and technical success was observed in both groups and no differences were recorded in patent foramen ovale closure efficacy. There were no significant differences between the complications when comparing the two devices.

**Conclusions:** For children and adults with an isolated secundum atrial septal defect percutaneous closure is equally safe and effective with either Occlutech Figulla or Amplatzer atrial septal occluders.

#### 94. FETAL INTRACARDIAC HEMODYNAMIC MEASUREMENT USING PRESSURE GUIDEWIRE DURING FETAL ATRIAL SEPTAL STENT PLACEMENT

Wendy Whiteside<sup>1</sup>, Sarah Gelehrter<sup>2</sup>, Carlen G. Fifer<sup>2</sup>, Albert P. Rocchini<sup>2</sup>, Cosmas Van de Ven<sup>3</sup>, Majorie C. Treadwell<sup>4</sup>, Karena Wu<sup>5</sup>, Jeffrey D. Zampi<sup>2</sup>

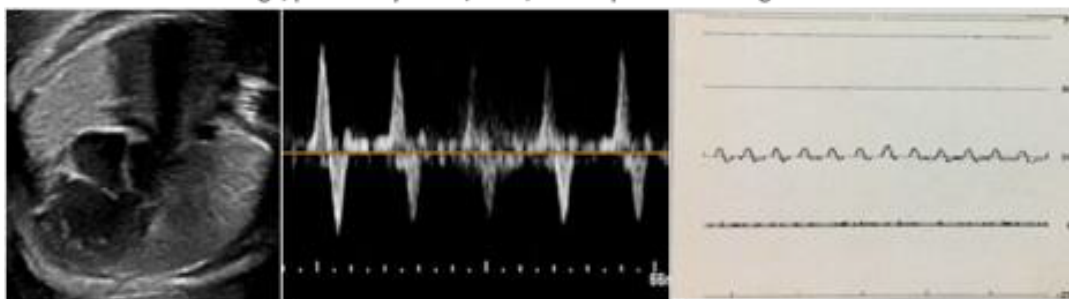
<sup>1</sup>University of Michigan; Congenital Heart Center, Ann Arbor, USA. <sup>2</sup>University of Michigan, Congenital Heart Center, Ann Arbor, USA. <sup>3</sup>University of Michigan, Division of Maternal-Fetal Medicine, Ann Arbor, USA. <sup>4</sup>University of Michigan Division of Maternal-Fetal Medicine, Ann Arbor, USA. <sup>5</sup>University of Michigan, Congenital Heart Center, Ann Arbor, USA

**Background:** Hypoplastic Left Heart Syndrome (HLHS) with intact atrial septum represents one of the most

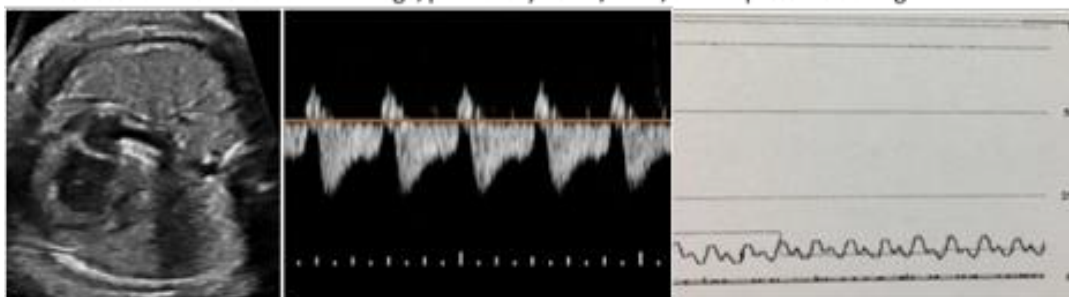
lethal forms of congenital heart disease due to pulmonary venous hypertension and resulting effects on lung development. Fetal intervention with left atrial (LA) decompression and atrial septal stent placement can be performed to lessen the urgency of post-natal atrial decompression, and may help improve survival by altering LA hemodynamics during fetal life. Data on direct intracardiac pressures in the fetus are limited. We report fetal hemodynamics using a pressure guidewire to record fetal intracardiac pressures and the corresponding change to echo Doppler tracings before and after LA decompression.

**Methods:** We report the case of a 33-year-old woman at 30 3/7 weeks gestation with fetal diagnosis of HLHS with an intact atrial septum. By fetal echocardiogram, the pulmonary veins were dilated with marked flow reversal and Doppler forward/reverse velocity time integral (F/R VTI) ratio  $<1$  suggesting severely elevated LA pressures. She was referred for fetal intervention with atrial septal stent placement. With the mother under epidural anesthesia and under transabdominal ultrasound guidance, an 18-gauge x 15 cm Trocar was advanced through the maternal abdomen and into the fetal right atrium, through the atrial septum, and into the left atrium. Through the trocar, a 2.5 mm x 8 mm Medtronic Integrity stent and 0.014" Volcano pressure wire were advanced into the LA, positioning the stent across the atrial septum. Stent was deployed in good position and repeat pressure recorded with the pressure wire.

#### 94. A. Baseline Echo 2D image, pulmonary vein F/R VTI, and LA pressure tracing



#### B. Post-Stent Placement: Echo 2D image, pulmonary vein F/R VTI, and LA pressure tracing



**Results:** Initial mean LA pressure as measured with pressure wire was 25 mmHg. Following placement of the atrial septal stent, mean LA pressure immediately fell to 9 mmHg with corresponding immediate normalization in pulmonary venous Doppler pattern and increase in F/R VTI ratio to 20 (figure). There was non-restrictive stent flow by color flow Doppler.

**Conclusions:** Intracardiac pressure measurements using a pressure guidewire during fetal atrial septal stent placement provides adjunctive hemodynamic information that is useful to assess the effectiveness of intervention and may also provide information for postintervention prognostication.

### 95. AMPLATZER VASCULAR PLUGS AND AMPLATZER DUCT OCCLUDER II ADDITIONAL SIZES FOR OCCLUSION OF PATENT DUCTUS ARTERIOSUS: A MULTI-INSTITUTIONAL STUDY

Dennis VanLoozen, MD<sup>1</sup>, Juan Pablo Sandoval, MD<sup>2</sup>, Jeffrey Delaney, MD<sup>3</sup>, Carlos Pedra, MD<sup>4</sup>, Damien Kenny, MD<sup>5</sup>, Bharat Dalvi, MD<sup>6</sup>, Zahid Amin, MD<sup>1</sup>

<sup>1</sup>Children's Hospital of Georgia, Augusta, USA. <sup>2</sup>Instituto Nacional de Cardiología Ignacio Chavez, Mexico City, Mexico. <sup>3</sup>University of Nebraska, Children's Hospital & Medical Center, Omaha, USA. <sup>4</sup>Instituto Dante Pazzanese de Cardiología, Sao Paulo, Brazil. <sup>5</sup>Our Lady's Children's Hospital, Dublin, Ireland. <sup>6</sup>Glenmark Cardiac Centre, Mumbai, India

**Background:** Variable patent ductus arteriosus (PDA) morphology and the desire to close PDAs in small size patients has led physicians to use Amplatzer Vascular Plug (AVP) I – IV and newly available Amplatzer Duct Occluder II – Additional Sizes (ADO II-AS). The purpose of this study was to analyze data, extrapolate results and compare complications of patients who underwent PDA closure with these devices.

**Methods:** Patients who underwent PDA closure with ADO I or II were excluded. Variables analyzed included demographics, procedure and device data, complications during the procedure and at 6 month follow up. Demographics included age, weight, gender and prematurity. Procedure and device data included PDA morphology, size, hemodynamic significance, device type and size used. Complications during procedure included device embolization, removal or referral to surgery. Follow up complications included assessment of left pulmonary artery (LPA) stenosis and aortic arch gradient.

**Results:** PDA closure was successfully accomplished in 466/471 pts (98.9%). Median age and weight were 27

months (range 0.75-852) and 11.4 kg (range 1-92), with 51 pts < 5 kg. Type A PDA was most common in 48% (n=225), followed by type E (27%, n=129), type D (13%, n=61), type C (10%, n=49) and type B (2%, n=7). AVP II was used in 421 pts (89%), ADO II-AS in 30 pts (6%) and the remaining pts received AVP I and IV. At follow up, mild LPA stenosis was the most common complication overall (n=20), with no significant difference between device type (p=1.0), PDA morphology (p=0.16) or patient size (p=0.56). Mild aortic arch gradient was seen in 5 pts (1.2%), all with AVP II. Device embolization was more common with ADO II AS (n=3, 10%) compared to AVP II (n=5, 1.2%) (p=0.001). Referral to surgery was required in 5 pts, all < 5kg.

**Conclusion:** The AVP II and ADO II AS appear promising for PDA closure. However, the complication of LPA stenosis remains the same in both groups and embolization may be more common with ADO II AS. We believe both devices are effective in PDA closure with complex morphology and smaller size pts.

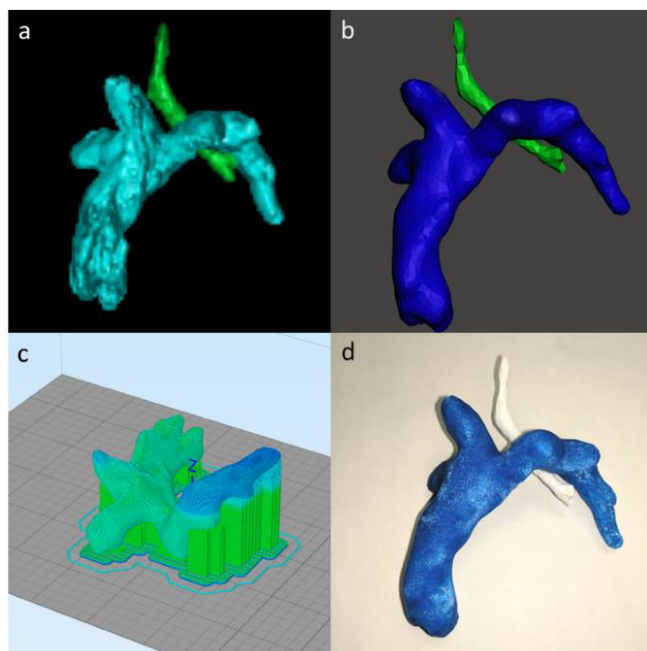
### 96. USE OF ROTATIONAL ANGIOGRAPHY TO GENERATE 3-D PRINTED MODELS - PROOF OF CONCEPT

Michael D. Seckeler<sup>1</sup>, Brian Boe<sup>2</sup>, Darren Berman<sup>2</sup>, Aimee K. Armstrong<sup>2</sup>

<sup>1</sup>Banner University Medical Center/University of Arizona, Tucson, USA. <sup>2</sup>Nationwide Children's Hospital, The Heart Center, Columbus, USA

**Background:** Three-dimensional (3-D) printing has been increasingly utilized in medicine for interventional planning, particularly in congenital heart disease. Typical datasets used are axial imaging (CT or MR), however similar datasets can be created in the catheterization laboratory using rotational angiography (RA). The purpose of this study was to assess the potential for generating 3-D printed models from RA datasets.

**Methods:** After approval from the Institutional Review Board, clinically indicated congenital catheterizations that used RA were identified. Catheterizations were performed in Toshiba and Philips laboratories. Use of rapid ventricular pacing, contrast concentration and contrast volume were based on standard practice and operator preference. DICOM data were segmented, cleaned, prepared for printing and then printed with poly-lactic acid on a Dremel® 3D Idea Builder (Dremel, Mount Prospect, IL, \$1,299; Figure). Data collected included demographics, diagnosis, contrast concentration and volume used, printing time and materials' costs. Two independent, non-interventional pediatric



**96. Figure.** Generation of a 3-D printed model. DICOM data is first segmented to define the anatomy of interest (a. Fontan in cyan, trachea in green.) The model is cleaned (b. Fontan in blue, trachea in green) and prepared for printing. (c). Final 3-D printed model (d. Fontan in blue, trachea white.)

cardiologists provided descriptions of the 3-D printed anatomy in addition to a subjective rating (1-5) on quality and accuracy compared to the digital models. Data were compared using Mann-Whitney U test,  $\chi^2$  and  $\kappa$  for agreement, as appropriate.

**Results:** RA data from 13 catheterizations were 3-D printed. Patient characteristics, details of image acquisition and 3-D printing are shown in the Table. All models were of vascular structures (aorta, pulmonary arteries, Glenn/Fontan conduits, coronary artery fistula). The independent reviewers correctly described 70 and 85% of the models ( $p=0.077$ ) and rated the quality and accuracy of the models high with good agreement (5 vs. 5,  $p=NS$ ;  $\kappa=0.458$ ).

**Discussion:** This proof of concept study has shown that DICOM data from standard RA can be successfully converted into 3-D printed models with good accuracy for defining anatomy. The cost of printing the models was negligible, but the time to print is still too long to allow for real-time use of the models. As the speed of 3-D printing technology increases, a novel future application of this technique could allow for printing of patient-specific

**96. Table.** Demographics, details of image acquisition and 3-D printing. Data are presented as median (interquartile range) or n (%).

Age (y)	4.45 (0.98, 11)
Weight (kg)	15.6 (10.1, 35.4)
Rapid pacing (n, %)	10 (77)
Contrast concentration (%)	60 (50, 91.5)
Contrast volume (mL/kg)	1.63 (1.07, 1.93)
Filament weight (g)	54.37 (25.35, 72.91)
Print time (h)	3.52 (3.26, 7.15)
Materials' cost (\$)	2.50 (1.31, 3.36)

stents and devices in the catheterization lab based on RA datasets.

### 97. TRANSCATHETER DEVICE CLOSURE OF AORTOPULMONARY WINDOW. IS IT A REASONABLE ALTERNATIVE TO SURGICAL REPAIR?

*Keneth Magaña, Aldo Campos, José Garcia Montes, Carlos Zabal, Jorge Cervantes, Juan Calderon, Juan Pablo Sandoval*  
Ignacio Chavez National Institute of Cardiology, Mexico City, Mexico

**Background:** An aortopulmonary window (APW) is a defect caused by incomplete separation between the aortic and pulmonary wall during early embryogenesis. Classical treatment is surgery with only few reported cases undergoing transcatheter device closure (TDC).

**Methods:** Single center, retrospective analysis including children with APW who underwent TDC as an alternative to surgery between 2004 and 2017. Patients were compared to those undergoing surgery during the same period. Clinical, interventional and surgical aspects were reviewed.

**Results:** Six children underwent TDC of APW. Median age was 4 years (1month-15years) and weight was 30 kg (3-45). Defects considered suitable for device closure were all type I defects according to the Mori *et al.* classification. Median diameter of the defect was 6.7 mm (2.31-14.9). Median systolic pressure of the pulmonary artery (sPAP) prior to closure was 50 mmHg (25-80); PVRi was 3.7UW (2.1-4.5); Qp:Qs of 3:1(1.5-4.56). APW's were closed using an Amplatzer Duct Occluder (n=3); ADO II (n=1), Cera PDA occluder (n=1), and an Amplatzer Septal Occluder (n=1). Device embolization occurred in two children (33%) within 24 hours post implantation. In both cases, devices

were retrieved and an alternative device used for closure. Another patient required implantation of a second device 12 months later due to a significant residual shunt. In all cases, sPAP decreased after closure. Median length of stay following intervention was 3 days (1-6). Median follow up (FU) is 6 years (2-11). FU echo revealed no evidence of aortic or branch pulmonary artery obstruction.

Seven children with isolated APW underwent uneventful pericardial patch repair. Median age and weight was 6.8 years (1-25) and 17.8 Kg(7-54) respectively. Defects were classified as type I in 2 patients but considered extremely large (>20mm) for TDC, type II (n=2) and type III (n=3). Median length of stay was 7 days. All children remain symptom-free upon latest FU

**Conclusions:** In selected cases, TDC of APW can be considered safe and effective. However, risk of device embolization is worth considering. Furthermore, excellent surgical outcomes play out in the decision-making process where TDC of APW seems distant from taking a leading role.

#### 98. TRANSCATHETER DEVICE CLOSURE OF PARAVALVULAR LEAK: SHORT AND MEDIUM-TERM OUTCOMES.

*Tatiana Molina, Piero Custodio, José Garcia Montes, Jose A Arias, Jorge Cervantes, Carlos Zabal, Juan Pablo Sandoval*  
Ignacio Chavez National Institute of Cardiology, Mexico City, Mexico

**Background:** Paravalvular leak (PVL) is not an unusual complication of surgical valve replacement (SVR) occurring between 5 and 17%. Reoperation (i.e. leak repair and/or valve replacement) has been considered the standard treatment modality, yet it is associated with significant morbidity and mortality. Transcatheter PVL device occlusion represents an attractive less invasive approach.

**Methods:** Retrospective, single institution review of patients with clinically relevant (i.e. heart failure, hemolysis) patients with PVL that underwent transcatheter device closure between 2006 and 2016. Clinical and interventional aspects were reviewed.

**Results:** Nineteen patients (female n=8); mean age 45±18 y.o. underwent transcatheter PVL closure. Indications for closure included: congestive heart failure n=13(68%); hemolytic anemia n=5 (26%), other n=1(5%). Mean time from index SVR to PVL intervention was 9.4 years. Nine (47%) patients were in NYHA functional class III prior to intervention. Mitral (n=15); aortic (n=5) and tricuspid

(n=1) PVL were all intervened under fluoroscopic and 2D or 3D (more recently) transesophageal echo guidance. Seventeen (81%) leaks were associated to mechanical prostheses. A retrograde approach was used for all aortic PVL and 2 (13%) cases of mitral PVL. An antegrade approach was performed in 13(87%) mitral PVL via standard transeptal needle puncture. Fifteen (79%) patients underwent closure using a single device while 4(21%) required an additional device to achieve occlusion. The most commonly used device was the Amplatzer Vascular Plug III in 13 (52%) PVL. Procedure success rate was 95%. None to mild residual leak was achieved in 80%. No procedure related mortality was encountered. Device embolization occurred in one patient. He underwent uneventful device retrieval and eventually had SVR 21 days later. Two additional patients underwent SVR for persistent hemolysis at 4 and 6 months respectively. Median latest follow-up is 24 months (6-60). Seventeen (85%) patients remain in NYHA functional class I.

**Conclusion:** Transcatheter device closure of PLV is a safe and effective procedure. This approach should be considered as an alternative to surgical valve replacement, particularly in the setting of surgical high risk patients.

#### 99. STENTING OF RIGHT VENTRICULAR OUTFLOW TRACT OBSTRUCTION IN INFANTS WITH UNIVENTRICULAR PHYSIOLOGY

*Hiroaki Kise, Yosuke Kono, Masashi Yoshizawa, Takako Toda*  
University of Yamanashi hospital, Chuo-city, Japan

**Background:** Right ventricular outflow tract (RVOT) stenting has been reported as a feasible alternative to other forms of intervention in the high-risk Tetralogy of Fallot (TOF). Furthermore, this strategy has been reported to promote better pulmonary artery growth compared with BTS. In univentricular physiology with pulmonary stenosis, RVOT stenting may become a feasible option in early infancy due to its many benefits.

**Methods:** RVOT stenting was performed in two cyanotic infants with univentricular physiology. Case 1 with asplenia, right single ventricle, RVOT stenosis and absent ductus (weight 3,100g) underwent RVOT stenting at 3 d/o due to hypercyanotic spell. Case 2 with tricuspid stenosis, hypoplastic RV, pulmonary stenosis and absent ductus (weight 4,530g) underwent RVOT stenting at 3 m/o.

**Results:** In case 1, two stents (Express Vascular SD 5mm/15mm, 5mm/19mm) were percutaneously placed in tandem. In case 2, one stent (Express Vascular SD

6mm/14mm) trimmed into 11 mm length was placed by a hybrid procedure following failure of the percutaneous approach. Post-dilatation or additional stenting was performed due to development of desaturation associated with somatic growth. Post-dilatations were performed twice (case 1) and 3 times (case 2). Two additional stents (Express Vascular SD 6mm/18mm x2) were placed at a narrow pulmonary trunk in case 2. Both infants grew up with optimal pulmonary artery growth. The stents were partially removed in subsequent surgery; bidirectional Glenn at 6 m/o and 9 m/o. Pulmonary artery sizes (rt./lt./PA index) at the surgery were 7.6mm (z-score +1.9)/6.2mm (z-score +1.2)/279.7 and 6.2 mm (z-score -0.8)/6.8 mm (z-score +0.4)/162.2, respectively.

**Conclusions:** RVOT stenting in single ventricle with pulmonary stenosis not only brings augmentation and stabilization of pulmonary blood flow, but also allows management of pulmonary blood flow on demand by post-dilatation and additional stenting. Furthermore, unlike with TOF, there is no concern regarding stent removal during subsequent surgery because stent-landing sites (RVOT and pulmonary trunk) are not to be used for the pulmonary circulation pathway. These properties will offer significant benefits for Fontan completion and better prognosis in univentricular physiology.

**100. SUCCESSFUL REDPLOYMENT OF A PROXIMALLY MIGRATED STENT IN A MALALIGNED SEVERE COARCTATION OF AORTA USING A BIOPTOME: DISCUSSING A UNIQUE CAUSE (MALALIGNMENT) AND A UNIQUE THERAPY**

*Neeraj Awasthy*

Max Hospital, Delhi, India

Endovascular stenting is an established method of treatment of Coarctation of the Aorta (CoA) in an adolescent and adult. Stent migration is a dreaded complication of any coarctation stenting. We present a case of stent migration in a 60 year old lady with coarctation amounting to near interruption with malaligned segments which was repositioned with a bioptome.

**Case:** A 60 year old lady presented with mild chest pain on and off since the past 6 years aggravating on exertion and relieved by rest radiating to the left arm associated with fatigue and palpitations not associated with difficulty in breathing not associated with cough and expectoration, no diurnal variations. History of giddiness was present and also failure to gain weight. There was no history of fever, vomiting, syncope. She was known case of hypertension

since the past 6 years and was on medications. She had no history of diabetes, bronchial asthma, COPD, Tuberculosis, seizure disorder, thyroid disorder, no bladder and bowel disturbances, no h/o previous surgeries. Her echo revealed coarctation of aorta with bicuspid aortic valve (thickened leaflets). On examination blood pressure (in supine position): upper limbs -130/70mmHg, lower limbs-80/60mmHg. Her CT aortogram was done which confirmed coarctation of aorta. In view of the above findings the patient was taken for coarctation stenting of aorta. Aortogram shows long segment coarctation of aorta, No PDA. Coarctation stenting done successfully with CP covered stent 20 (8zig) x 45 with BIB balloon. The stent migrated slightly distally while inflating and was repositioned with the help of bioptome and peripheral balloon. Post dilatation, no significant gradients across the coarctation segment. No complication. Total gradient across the coarctation segment was 140 mmHg before stenting, post stenting the gradient was reduced to 10. Her post-op recovery was satisfactory she was discharged in stable condition. She is doing well with one and half year follow up.

**101. NO DELIVERY SYSTEM: INGENEOUS DEVELOPMENT OF A DELIVERY SYSTEM IN PEDIATRIC POPULATION FOR DIAGNOSTIC CARDIAC CATHETERIZATION**

*Neeraj Awasthy*

Max Hospital, Delhi, India

**Introduction:** Study of delivery of NO for diagnostic cardiac catheterization in paediatric patient BIPAP vs paediatric Hud.

**Aims and objective:** Effective delivery of NO with the HUD is comparable to BIPAP delivery, in pediatric spontaneously breathing patient with the use of NOXBOX machine.

**Methods and material:** This is comparative prospective pilot study, to assess effectiveness of delivery of NO via HUD, compared to that of BIPAP mask. Study population is grouped into two based on mode of delivery as BIPAP receiving group and HUD receiving group. Each group contain 5 spontaneously breathing pediatric patient with underlying pulmonary hypertension, and, NO is delivered to assess reversibility of pulmonary vasculature.

**Result:** data collected as above, in HUD group, we were able to deliver NO effectively in acceptable range in all 5 patients same in BIPAP group.

**Conclusion:** we found that this system of NO delivery by HUD is a simple delivery system with wide applicability. We have shown that it has similar efficacy as that of BIPAP to deliver NO and O<sub>2</sub>. Its safety profile appears is comparable to that of standard, more complicated, delivery systems.

## 102. STENT PLACEMENT IN AN OCCLUDED LEFT SUPERIOR VENA CAVA TO RIGHT ATRIAL BAFFLE AIDED BY TRANSHEPATIC ACCESS IN A PATIENT WITH HETEROTAXY AND AN INTERRUPTED INFERIOR VENA

*Abraham Rothman<sup>1,2</sup>, Alvaro Galindo<sup>1,2</sup>, William Evans<sup>1,2</sup>, Humberto Restrepo<sup>1,2</sup>*

<sup>1</sup>Children's Heart Center Nevada, Las Vegas, USA. <sup>2</sup>University of Nevada Las Vegas, School of Medicine, Pediatric Cardiology, Las Vegas, USA

We describe covered stent placement in a completely occluded left superior vena cava to right atrial baffle in a patient with heterotaxy and an interrupted inferior vena cava. Left coronary angiography and transhepatic access were used to guide the Brockenbrough needle across the obstruction.

**Case Report:** A 9-year-old girl with a history of heterotaxy, dextrocardia, transitional atrioventricular septal defect, interrupted inferior vena cava to left sided superior vena cava and hepatic veins to right atrium underwent surgical rerouting of the left superior vena cava to right atrium and repair of the atrioventricular septal defect at 9 months of age. A catheterization at 7 years of age revealed obstruction of the left superior vena cava to right atrial baffle and markedly dilated abdominal venous collaterals from the inferior vena cava, which eventually drained into hepatic veins and right atrium. A CTA showed close proximity of the left coronary artery to the occluded baffle. At the catheterization procedure, performed with general anesthesia in a hybrid room, she weighed 23 kilograms. Left internal jugular (8F) and transhepatic venous (5F) access were obtained. Left coronary angiography was performed. An angled glide catheter advanced through the hepatic sheath was placed in the right atrium near the obstruction; small contrast injections delineated the target for puncture with a Brockenbrough needle, advanced through the jugular sheath. Complex right atrial morphology made it difficult to snare a wire from the hepatic vein. An 0.035 exchange wire was placed in a pulmonary artery branch. The obstruction was dilated with a 10mm x 3cm Evercross balloon followed by a 15 mm x 3 cm Zmed balloon, with simultaneous left coronary angiography. There was no coronary compression. A 4.5 cm Cheatham covered stent on a 14 mm balloon was delivered and was post-dilated

with a 16 mm x 2 cm Atlas balloon. A week later the stent was wide open on echocardiography. Six months later, the patient was doing well clinically and was due for a repeat echocardiogram.

**Conclusion:** Transhepatic access and simultaneous left coronary angiography were key to successful covered stent implantation in this patient with complex anatomy.

## 103. LEFT SUBCLAVIAN ARTERY TEST BALLOON OCCLUSION PRIOR TO COVERED STENT IMPLANTATION FOR RELIEF OF RE-COARCTATION AND EXCLUSION OF AN ANEURYSM

*Abraham Rothman<sup>1,2</sup>, Michael Ciccolo<sup>1,3</sup>, Alvaro Galindo<sup>1,2</sup>, William Evans<sup>1,2</sup>, Humberto Restrepo<sup>1,2</sup>*

<sup>1</sup>Children's Heart Center Nevada, Las Vegas, USA. <sup>2</sup>University of Nevada Las Vegas, School of Medicine, Pediatric Cardiology, Las Vegas, USA. <sup>3</sup>University of Nevada Las Vegas, School of Medicine, Pediatric Surgery, Las Vegas, USA

A frequent conundrum during coarctation intervention is the potential compromise to flow in the left subclavian artery (LSCA). We describe temporary balloon occlusion of the LSCA prior to covered stent implantation for re-coarctation with a coexistent aneurysm.

**Case Report:** A 57-year-old man had coarctation patch repair at 3 years of age and presented with a dilated and dysfunctional left ventricle (ejection fraction in low 30s). A CTA revealed obstruction in the distal arch and proximal descending aorta with a diameter of 11 mm and a saccular aneurysm near the origin of the LSCA measuring 30 x 23 x 20 mm. Surgical repair was deemed high risk. A hybrid procedure was performed. Under general anesthesia, a left radial arterial line and femoral venous and arterial sheaths were placed. The left ventricular end-diastolic pressure was 17 mmHg, the ejection fraction 32%, and the gradient from ascending to descending aorta was 35 mmHg. Coronary angiography revealed no significant lesions. A 5F Berman catheter was used to test balloon occlude the LSCA; the left radial arterial pressure decreased from near systemic level to 40/38 mmHg. The surgical team placed an 8mm Dacron graft from the left common carotid artery to the LSCA. Through a 14F femoral arterial sheath, a 4.5cm Cheatham covered stent was implanted with an 18 mm BIB balloon in the distal arch and proximal descending aorta, excluding the aneurysm. The minimum diameter increased from 11.5 to 16.4 mm. The gradient from ascending to descending aorta was 3 mmHg and from ascending aorta to left radial artery 20 mmHg. A CTA 6 months later showed no stent re-stenosis; the aneurysm and proximal LSCA were

completely occluded with thrombus. The common carotid to subclavian graft had mild stenosis. One year after the procedure, the patient was doing well clinically; he had a 24 mmHg peak systolic blood pressure difference between the right and left arms, a left ventricular ejection fraction of 38-41% and a peak velocity distal to the stent of 1.9 m/sec, without diastolic runoff.

**Conclusion:** Test balloon occlusion of the LSCA can aid in the interventional management of coarctation

#### 104. EARLY ELECTROCARDIOGRAPHIC CHANGES IN PATIENTS WITH TETRALOGY OF FALLOT AFTER SURGICAL REPAIR

Lukas Ljung<sup>1</sup>, Ida Jeremiasen<sup>1</sup>, Carl-Johan Rosenkvist<sup>2</sup>, Annica Maxedius<sup>1</sup>, Misha Bhat<sup>1</sup>, Torsten Malm<sup>1</sup>, Katarina Hanseus<sup>1</sup>, Gunnar Sjöberg<sup>3</sup>, Petru Liuba<sup>1</sup>

<sup>1</sup>Skåne University Hospital, Lund, Sweden. <sup>2</sup>Kalmar Hospital, Kalmar, Sweden. <sup>3</sup>Karolinska Hospital, Stockholm, Sweden

**Background:** Surgical repair of Tetralogy of Fallot (TOF) with RVOT enlargement with transannular patch results in pulmonary regurgitation with subsequent increasing RV volume overload and need for later pulmonary valve replacement. These changes are typically associated with progression of QRS and QTc duration, which are predictive for long term adverse events. RVOT reconstruction with monocusp has been increasingly used during the past decade in the attempt to improve early postoperative recovery and delay the PR particularly during the first years after surgery.

**Aim of Study:** To assess whether repair of TOF with monocusp influences the progression of QRS and QTc duration during the first years after surgical repair of TOF.

**Methods:** We performed a retrospective survey of all patients with TOF who underwent surgical repair between 1998-2014 with available conventional electrocardiograms:

- (A) before surgery
- (B) upon postoperative discharge
- (C) at 18-24 months after surgery who did not require re-operation during this period. Demographic, clinical, surgical and electrocardiographic data were obtained.

**Results:** In total, 92 patients fulfilling the above criteria were included. There was no mortality. Of these, 32 patients (median weight at repair 6.9kg) underwent pulmonary valve-sparing repair, 31 patients (median weight 6.7kg) underwent TAP repair, and 29 patients (median weight 6.5kg) had repair with TAP & monocusp. There were

no differences between the groups in QRS and QTc durations preoperatively or upon discharge after repair ( $p > 0.15$ ). At 18-24 months, both QRS and QTc durations were greater in the monocusp group ( $p < 0.05$  for QRS and  $p < 0.01$  for QTc). The percentage change in QRS and QTc durations from the early postoperative time were increased in the monocusp group as compared to the other groups ( $p < 0.05$ ).

**Conclusion:** Surgical repair of TOF with TAP and monocusp pulmonary valve appears to be associated with adverse changes in QRS and QTc durations during the first years after repair. These changes could be due to a more pronounced myocardial remodeling as a result of a more extensive RVOT patch enlargement during TOF repair with monocusp. Prospective studies exploring underlying mechanisms of RV remodeling by measuring circulating biomarkers for myocardial remodeling after TOF repair with TAP and monocusp are under way.

#### 105. STAGED PERCUTANEOUS BALLOON VALVOTOMY (PBMV) AND ASD DEVICE CLOSURE FOR SITUS INVERSUS TOTALIS DEXTRCARDIA AND LUTEMBACHER SYNDROME (LARGE ASD AND SEVERE MITRAL STENOSIS) IN A ELDERLY FEMALE

Sudeep Verma<sup>1</sup>, Dayasagar Rao<sup>2</sup>, Sharathbabu D<sup>3</sup>

<sup>1</sup>Krishna Institute of Medical Sciences, Secunderabad Hyderabad, India. <sup>2</sup>Krishna Institute of Medical Sciences, Secunderabad-Hyderabad, India. <sup>3</sup>Krishna Institute of Medical Sciences, Secunderabad- Hyderabad, India

**Introduction:** Lutembacher syndrome is a rare combination of congenital ASD and acquired Mitral valve pathology particularly Mitral stenosis (MS). The resultant haemodynamics depends upon the interplay between size of ASD and severity of MS. We are describing here a rare case of situs inverses totalis with Lutembacher syndrome and severe Tricuspid regurgitation (TR) underwent successful s PBV first followed by ASD device closure within 3 months. Patient symptoms improved dramatically after the procedure with complete abolition of TR.

**Case Details:** 41 years old lady weighing 40 kg presented with chief complaints of progressive dyspnoea and pedal oedema since 3 months. Examination revealed thin build habitus, situs inverses, dextrocardia, elevated left sided JVP with prominent V and Y descent, low volume pulses, right parasternal heave grade III, wide and fixed split S2, 4/6 Systolic murmur at right upper sternal border and short MDM at right apex.



TEE evaluation was done that showed severe MS with Effective Orifice area (EOA) of 0.6 cm<sup>2</sup> and ASD of 22 mm. After QP/QS measurement (4.1:1), underwent successful PBMV from left Femoral vein approach using 23-26 Accura Balloon with increase in EOA to 2.1cm<sup>2</sup>. Patient improved symptomatically and after 3months underwent successful ASD device closure using 26 Amplatzer Septal Occluder. PCWP checked before and after procedure that showed baseline value of 10 mm Hg increased to 14 after the procedure. TR which was severe before ASD occlusion decreased to mild after the procedure. Discharged on diuretics and dual anti platelets. 6 months follow up showed mitral valve area of 2.3 cm<sup>2</sup> with absence of any symptoms.

**Conclusion:** This case highlights the importance of meticulous assessment of haemodynamics while managing Lutembacher syndrome. Left sided femoral venous access helped in catheter and balloon alignment while performing PBMV and ASD device closure. Staging of procedure with PBMV first followed by ASD device closure is a good strategy for such patients. ASD closure is possible if mitral valve EOA is good without significant regurgitation. One interesting observation is that TR even if severe tends to decrease in absence of organic abnormality after ASD device closure.

#### 106. CARDIAC STRANGULATION CAUSING REFRACTORY CARDIAC ARREST DURING ELECTIVE PACEMAKER REVISION: A CAUTIONARY TALE

*Colm Breatnach, Rebecca Weedle, Matthew Coughlan, Damien Kenny, Lars Nolke, Paul Oslizlok*  
Our Lady's Children's Hospital, Dublin, Ireland

**Case Report:** A seven year old girl was admitted for elective pacemaker revision with a transvenous pacemaker. She originally had an epicardial system sited on day 2 of age for complete heart block. During the procedure, she had a sudden loss of cardiac output and fluoroscopy demonstrated cardiac standstill. Cardiopulmonary resuscitation (CPR), multiple rounds of ephinephrine and 8 defibrillations proceeded extracorporeal life support (ECLS). Aortography following ECLS suggested normal coronary arterial flow. On day two post paediatric intensive care unit (PICU) admission she was decanulated with a shortening fraction of 30%. She again deteriorated and was recanulated following a brief run of CPR. Selective coronary angiography demonstrated dynamic collapse of the left anterior descending (LAD) and left circumflex (LCx) coronary arteries. A CT thorax confirmed compression of the LAD and LCx just after the bifurcation by the original epicardial pacing lead. The cardiothoracic surgical team

identified the epicardial lead covered by a calcified capsule encircling the heart, with a 2cm fissure on the surface of the right ventricle. The pacemaker box and leads were removed and the patient is doing well.

Cardiac strangulation by epicardial pacemaker leads is an extremely rare event with only 10 cases reported in the literature. In our patient it is likely that the anaesthetic agent led to a reduction in myocardial perfusion and the compressing lead resulted in a spiral of worsening coronary blood flow, myocardial dysfunction, ventricular fibrillation and cardiac arrest. The impinging lead inhibited the effectiveness of the resuscitation effort with very limited flow to the LAD and LCx. Some groups advocate for serial chest x rays to assess lead position in these patients. Given our experience with this patient, our group agree with the need for radiological review. Aortography failed to demonstrate coronary collapse and if strangulation is suspected selective coronary angiography should be performed. If cardiac strangulation is suspected or confirmed, extreme caution should be taken during anaesthetic induction with an ECMO circuit primed and a surgical team on standby.

#### 107. LEADLESS MICRA PACEMAKER USE IN THE PAEDIATRIC POPULATION: SINGLE CENTRE EXPERIENCE

*Colm Breatnach, Khalid Al-Alawi, Paul Oslizlok, Damien Kenny, Kevin Walsh*  
Our Lady's Children's Hospital, Dublin, Ireland

**Background:** Pacemaker implantation is an effective treatment strategy for paediatric patients with symptomatic bradycardia. Until recently, device technology has allowed for insertion of epicardial systems, or when weight permits, transvenous devices. While effective, these devices are not without fault. The main risk is lead fracture or dislocation, resulting in the need for replacement and re-intervention. A leadless Micra pacemaker device has recently become available. Its success in the adult population has been well described although there is a lack of knowledge on its use in children. We review the data on Micra pacemaker insertion in our institution. We hypothesise that use of this device without early complications is feasible in this patient cohort.

**Methods:** We performed a retrospective case series review of paediatric patients who have undergone transvenous catheter implantation of the Micra leadless device. The medical records of these patients were reviewed to ascertain demographic and clinical details. A review of their pacemaker parameters was performed from the Medtronic

online system to capture: pacemaker threshold voltages, R waves, and impedance values.

**Results:** To date, we have successfully inserted the Micra pacemaker device in four paediatric patients aged 13 – 17 years, with weight range of 33 – 60kg. There have been no failed implantations. None of our patient group has suffered complications as a result of their procedure with a follow up range of 1 to 6 months. The immediate post procedural threshold voltages ranged from (0.35 – 1.5Vs @ 0.24ms), with satisfactory R waves in each patient (7.5 – 17mV) and mean impedance of (630 - 960 ohms). Repeat thresholds improved in three of the four patients and impedance values improved in all four patients at follow up.

**Conclusion:** This case series highlights the feasibility of implanting the Micra Leadless device in a younger patient group with no complications to date. Long term follow up studies with larger patient numbers are required to establish data on efficacy and complication rates in children.

#### **108. THE IMPACT OF RIGHT VENTRICULAR OUTFLOW TRACT STENTING ON EARLY POST OPERATIVE CARE IN PATIENTS WITH TETRALOGY OF FALLOT**

*Colm Breatnach, Aidan McGee, Sophie Duignan, Aine Lynch, Terence Prendiville, Paul Oslizlok, Kevin Walsh, Damien Kenny, Orla Franklin, Cathy McMahon, Colin McMahon*

Our Lady's Children's Hospital, Dublin, Ireland

**Background:** Timing of surgical repair for tetralogy of fallot is dictated by patient weight, however early intervention may be needed in patients with severe pulmonary stenosis and low oxygen saturation. Recently, early intervention has incorporated the use of a right ventricular outflow tract (RVOT) stent as a temporising measure in cyanotic low weight patients. We review our early post operative data in patients with and without an RVOT stent following complete tetralogy of fallot repair.

**Methods:** We performed a retrospective review of all patients undergoing tetralogy of fallot repair over a 5 year period. Peri-operative data during surgical repair was collected from the ICU electronic patient database (ICIP). Demographic details and clinical parameters were assessed. Outcomes included duration of ventilation and length of time in ICU. The patients were divided into those receiving an RVOT stent (stented) and those who underwent primary repair (non stented).

**Results:** Seventy nine patients were included in the study, twenty five stented and fifty four non stented. The mean age and weight at surgery were [6 months and 6.4kg in the stented versus 6 months and 6.8kg in the non stented group] respectively. The mean cardiopulmonary bypass and cross clamp times were longer in the stented group [189 and 141 versus and 144 and 103 minutes]. Mean duration of invasive ventilation and ICU stay were both longer in the stented group [89 minutes and 7.5 days versus 48 minutes and 4.4 days]. The vasoactive inotrope score was higher in the stented group [19.9 versus 10.1]. Complication rates were higher in the stented group including: post operative chylothorax and junctional ectopic tachycardia. There was one death in the stented group.

**Conclusion:** Our review compares the early post operative clinical course in patients with tetralogy of fallot (with and without an RVOT stent) following surgical repair. We have demonstrated the protracted treatment course in patients requiring early stenting. This is likely due to the severity of the condition in this group. Awareness of the increased challenges in stented patients is important for peri-operative care planning. Further studies are needed to ascertain long term outcomes in this cohort.

#### **109. VARIABLE APPROACHES TO HYBRID PULMONARY VALVE REPLACEMENT IN THE PAEDIATRIC SETTING**

*Colm Breatnach, Khalid Al-Alawi, Paul Oslizlok, Kevin Walsh, Damien Kenny*

Our Lady's Children's Hospital, Dublin, Ireland

**Introduction:** Hybrid approach to pulmonary valve replacement (PVR) in the paediatric population has been previously reported. Several strategies are possible including perventricular valve insertion; pulmonary artery plication; and surgically sutured valve insertion with intra operative ballooning. The aim of this study was to review our hybrid PVR strategy outlining a variety of different hybrid approaches employed in our centre.

**Methods:** We performed a retrospective case series review of paediatric patients that underwent hybrid PVR. The patients were identified from our dedicated National Institute for Cardiovascular Outcomes Research (NICOR) database. The medical records of these patients were reviewed to ascertain demographic and clinical details. Data was summarized using medians (range) and descriptive evaluation.

**Results:** Seven patients with a median age of 1.6 years (range 0.75 – 9.75) and weight of 8.7kg (range 6.8 – 28) were identified. In 3 patients, the pulmonary valve was inserted into the native pulmonary outflow tract, with four insertions into conduits. Three patients underwent PVR with a stent mounted valve (SAPIEN valve) via a sub-xiphoid approach (group 1); two patients had a surgically sutured stent valve (Melody) inserted within a transannular patch with intra-operative balloon dilation of the valve as part of a complex tetralogy repair (group 2); two patients had a periventricular valve inserted with subsequent plication of the right ventricular outflow tract (group 3). Three of the seven patients required bypass including both patients in group 2 and one patient from group 3 who also underwent a left ventricular outflow tract myectomy. No valve related procedural complications occurred and all patients were discharged home without the need for unplanned intervention.

**Conclusion:** A broad range of approaches to hybrid PVR may be employed as part of a comprehensive RVOT program. These approaches can be performed safely with a high success rate. Follow-up studies are required to evaluate the longer term durability of these approaches compared to a standard surgical replacement.

#### 110. ACUTE AND SHORT-TERM HEMODYNAMIC IMPACT OF TRANSCATHETER PULMONARY VALVE IMPLANTATION ON LEFT VENTRICULAR SYSTOLIC AND DIASTOLIC FUNCTION

Ryan Romans<sup>1</sup>, Wendy Whiteside<sup>2</sup>, Lori Harris<sup>2</sup>, Veronika Dotterman<sup>2</sup>, Jeff Zampi<sup>2</sup>

<sup>1</sup>Children's Mercy Hospital, Kansas City, USA. <sup>2</sup>University of Michigan Congenital Heart Center/C.S. Mott Children's Hospital, Ann Arbor, USA

**Background:** Transcatheter pulmonary valve implantation (TPVi) is a now widely available option to treat residual or recurrent pulmonary stenosis (PS) and pulmonary insufficiency (PI). TPVi acutely increases pulmonary artery size and diastolic pressure in patients with PI and acute pulmonary edema has been reported after TPVi, possibly related to acute left ventricular (LV) volume loading. However, the hemodynamic impact of TPVi on LV systolic and diastolic function, both acutely and on short-term follow-up, remains unknown.

**Methods:** We analyzed patients who underwent TPVi from 2010-2017 at our center. Patients were grouped based on indication for TPVi as either PS, PI, or mixed disease using standard TPVi criteria. Subgroup analysis was performed

on those who underwent TPVi for PS versus those with PI or mixed disease as those with PI were more likely to have acute LV volume loading. Intracardiac hemodynamics immediately before and after TPVi and echocardiographic assessment of LV systolic and diastolic function at baseline, 1-day post TPVi, and 1-year post TPVi were compared between groups and subgroups.

**Results:** Of the 102 patients included in analysis, TPVi was performed for PS in 29 (28%), PI in 28 (29%) and mixed disease in 44 (43%). There was no difference in LV function, MV peak E or A velocity, septal and lateral e', or septal and lateral E/e' between groups (PS versus PI/mixed) at baseline, 1-day after the procedure, or 1-year post implantation. In all patients, the mean pulmonary artery wedge pressure increased 3 (+/- 3.2) mmHg following TPVi but this was change was observed equally in all groups.

**Conclusions:** While patients with PI likely have acute LV volume loading following TPVi, this does not appear to be hemodynamically significant as TPVi was not associated with any changes in LV systolic or diastolic function either acutely or at 1-year follow-up. While pulmonary artery wedge pressures increase after TPVi, indicating increased LV end diastolic pressures, this was observed in all patients regardless of disease type and was not associated with other measures of diastolic dysfunction. Therefore, this is likely secondary to intraprocedural volume and contrast administration.

#### 111. ABSENT PORTAL VEIN AND BLEEDING HAEMORRHOIDS IN A TWO YEAR OLD CHILD POSTED FOR LIVER TRANSPLANTATION- TRANSCATHETER MANAGEMENT

Sudeep Verma<sup>1</sup>, Gouthami V<sup>2</sup>

<sup>1</sup>Krishna institute of medical sciences, Secunderabad-Hyderabad, India. <sup>2</sup>Krishna Institute of Medical Sciences, Secunderabad- Hyderabad, India

**Background:** Haemorrhoids is rare in paediatric age. We are presenting a case of bleeding per rectum in a two years old due to haemorrhoids secondary to portal hypertension and congenital absence of portal vein (Abernathy malformation I) referred for liver transplantation. Test balloon occlusion of the aberrant vessel demonstrated presence of portal radicals, followed by successful closure of the aberrant channel. 2 years follow up showed good growth of the portal radical and absence of bleeding per rectum.

**Description:** 2 years old, weighing 10.5 kg presented with complaints of recurrent bleeding per rectum. Examination showed severe pallor and splenomegaly. Suspected to have portal hypertension hence CT scan and MRI was done that showed congenital absence of portal vein with abnormal drainage of portal confluence to right iliac vein (Abernathy type I - Morgan classification and Kobayashi classification type C). Haemoglobin was 7 gm% and LFT were normal. Sigmoidoscopy revealed large venous channel into rectum with multiple internal haemorrhoids. Referred for liver transplantation in view of absence of portal vein. Balloon test occlusion of draining channel using 16x40 Tyhak balloon demonstrated presence of native portal radicals to the liver with hepatic staining (suggestive of moderate hypoplasia of portal radicals). Portal pressure measured 19 mm Hg after test occlusion. Device closure of the aberrant channel was done using 24/26 duct Occluder from right internal jugular venous route. Developed portal vein thrombosis after the procedure resolved within 48 hours of heparin infusion. Two years follow up showed decreased rectal bleeding and stable haemoglobin level of more than 11 gm% in presence of normal liver function test. Follow up angiogram and sigmoidoscopy done 6 months after first procedure showed good growth of portal veins and absence of internal haemorrhoids.

**Conclusion:** Bleeding haemorrhoids is a rare presentation of portosystemic shunt. Diagnosis of absent portal vein should always be consider only after balloon occlusion test. Surgical ligation or transcatheter closure of aberrant vessel is feasible option if portal pressure remained less than 25-30 mm Hg. Long term follow up is needed to assess portal venous pressure, growth of intrahepatic portal radicals and symptomatic status.

### 112. PERCUTANEOUS PULMONARY VALVE IMPLANTATION: INITIAL MEXICAN MULTICENTER EXPERIENCE.

Juan Pablo Sandoval<sup>1</sup>, Alejandro Flores-Arizmendi<sup>2</sup>, Lorenzo Gutierrez<sup>3</sup>, Carlos Zabal<sup>1</sup>, Jose Garcia-Montes<sup>1</sup>, Antonio Salgado<sup>2</sup>, Jesus Montalvo<sup>2</sup>, Jorge Villatoro<sup>3</sup>, Paola Castro<sup>3</sup>, Cristina Aguilar<sup>1</sup>, Carlos Pedra<sup>4</sup>, Daniel Springmuller<sup>5</sup>

<sup>1</sup>Ignacio Chavez National Institute of Cardiology, Mexico City, Mexico. <sup>2</sup>CMN 20 Noviembre ISSSTE, Mexico City, Mexico.

<sup>3</sup>UMAE Pediatria, Centro Medico Occidente, IMSS, Guadalajara, Mexico. <sup>4</sup>Instituto Dante Pazzanese, Sao Paulo, Brazil. <sup>5</sup>Pontificia Universidad Catolica de Chile, Santiago, Chile

**Background:** Percutaneous pulmonary valve implantation (PPVI) has become a well-recognized alternative to surgical pulmonary valve replacement in selected patients

with dysfunctional synthetic right ventricle to pulmonary artery (RV-PA) conduits, bioprosthetic pulmonary valves, or homografts. PPVI has been subject to a slow start in multiple countries in Latin America, ours included, mainly due to complex internal health policies and economic constraints. We describe the initial Mexican multicenter experience with the Melody<sup>®</sup> transcatheter pulmonary valve (Medtronic).

**Methods:** Retrospective review of eligible patients who underwent PPVI for treatment of conduit dysfunction at 3 centers. Standardized implantation protocols were used. Demographic, pre-procedural and interventional data were collected.

**Results:** Between October 2016 and March 2018, 9 patients were recruited. Median age and weight was 16 years (14-27) and 46kg (36-61). Primary indication for PPVI was stenosis (n=2), regurgitation (n=2) or both (n=5). PPVI was performed in 7 patients with a dysfunctional RV-PA conduit (Contegra<sup>®</sup> n=4; Synthetic Dacron graft / fibrous peel n=3); 1 with a dysfunctional 19mm bioprosthetic valve and 1 native right ventricular outflow tract. Median time from index RV-PA conduit /prosthetic valve placement to PPVI was 7 years (5-11). Six (67%) patients were in functional class III prior to intervention. Vascular access was obtained from a femoral approach in all cases. Pre-stenting with a covered (n=4) and/or bare metal stent(s) (n=5) was performed in all patients prior to Melody<sup>®</sup> valve delivery & implantation. In addition, 2 patients required previous branch pulmonary artery stent rehabilitation. All patients underwent successful PPVI. RV-PA gradient fell from 26±11mmHg to 8±5 mmHg (p<0.001). All had none or trivial regurgitation immediately following valve implantation. No procedure related deaths or major adverse effects were encountered. All patients remain in functional class I after a median follow-up of 5 months (2-18). None have required reintervention nor have experienced subacute infective endocarditis.

**Conclusion:** Our initial multicenter PPVI experience is consistent with worldwide reports of safety and efficacy using the Melody<sup>®</sup> valve. Experience in Latin America is steadily increasing and expanding to continue offering this treatment modality to selected patients with dysfunctional RV-PA conduits.

### 113. EARLY EXPERIENCE WITH SAPIEN 3 TRANSCATHETER PULMONARY VALVE IMPLANTATION

Jeremy Ringewald

St Joseph's Children's Hospital, Tampa, USA

**Background:** Transcatheter pulmonary valve implantation (TPVI) has expanded the options for addressing recurrent pulmonary valve dysfunction. The most commonly available valve is adequate only for those with a history of surgical conduit and rare others with a balloon-sized MPA landing zone <24mm. The Sapien 3 valve offers the possibility of TPVI for many additional patients with landing zones up to 30mm.

**Methods:** Retrospective single center study of all patients who underwent a catheterization with the intent to attempt TPVI with a Sapien 3 valve, 2015 – 2018.

**Results:** 39 patients were brought for evaluation for TPVI with the Sapien 3. 16/39 were female, mean age was 27.3yrs (Range 7-62), and mean weight was 74 kg (range 18.1-159). Diagnosis was TOF variant (n=27), PS (n=7), and other (n=5). 36/39 had undergone prior cardiac surgery (range 1-4) and 2/36 had a surgical RV to PA conduit. 26/39 patients were symptomatic. Indication for TPVI was PR (n=36), PS/PR (n=2), and PS (n=1). Pre-procedural MRI or CTA was performed in 35/39 and a potential landing zone was any location in the RVOT or MPA <30mm in diameter. 34/39 underwent balloon sizing and 22/34 underwent attempted valve delivery. 22/22 attempts were successful. Valve landing zone stent(s) were placed in 14/22 patients. 8/22 valve implants were difficult requiring an RA loop (n=3), buddy wire (n=2), balloon stabilization of delivery wire (n=2), or contralateral branch PA wire position (n=1). Mean fluoroscopy was 53.1minutes (range 22.5 – 105.8). A small perivalvar leak was noted in 7/22 patients. Length of stay was 1 day in 20/22 patients. Four major procedural adverse events occurred (stent migration in 2, arrhythmia in

1, and pulmonary hemorrhage in 1). There were no deaths or emergent surgeries. 4/22 developed ventricular ectopy and were discharged on beta blocker. In early follow-up all patients had normalization or near normalization of RV size and none had more than mild tricuspid regurgitation.

**Discussion/Conclusion:** Sapien 3 TPVI is possible in some patients with pulmonary valve dysfunction and larger right ventricular outflow tracts. Difficult valve advancement should be expected. Patient selection should improve with better analysis of pre-procedure imaging.

#### 114. TRANSCATHETER AORTIC VALVE REPLACEMENT TO TREAT AORTIC INSUFFICIENCY IN PEDIATRIC PATIENTS

*Carol McFarland, Mary Hunt Martin, Arvind Hoskoppal, Aaron Eckhauser, Robert Gray*

University of Utah, Salt Lake City, USA

**Background:** Transcatheter aortic valve replacement (TAVR) was designed to treat calcific aortic valve stenosis. Data regarding the use of TAVR to treat aortic insufficiency (AI) in adults is limited and no data exists regarding use within native valves in pediatric patients. These patients require multiple re-interventions over their lifespan. Less invasive options can improve symptoms and functionality while potentially decreasing open-heart surgical procedures.

**Methods:** Retrospective case series of pediatric patients who underwent TAVR at the University of Utah from 2015-2018 for treatment of predominant AI. Percent device oversizing =  $[1 - (\text{native valve area}/\text{nominal device area})] \times 100$ .

**114. Table.**

Pt	Diagnoses and surgical procedures	Age at TAVR (years)	Weight at TAVR	Device size and type	Procedure time	Procedural complications
1	Shone's, s/p CoA repair, mitral and aortic valvotomy, MVR and aortic valvotomy	14.0	36.3 kg	23mm Sapien XT	96 minutes	Femoral dissection requiring surgical repair
2	Supracristal VSD s/p repair, sub-AS repair, and sub-AS repair with Konno	17.9	53.3 kg	26mm Sapien 3	85 minutes	None
3	Unicuspid aortic valve s/p aortic valvotomy	8.7	23.4 kg	26mm Sapien 3	90 minutes	None

**Results:** Demographic and procedural information are summarized (Table 1). Pre-TAVR NYHA classification was a mean of II (I-III). All patients had  $\geq$  moderate AI and had AS peak gradients of 7-38mmHg. Native valve areas by CT ranged 325-444mm<sup>2</sup> and were oversized by 17-30%. All procedures utilized a percutaneous femoral approach. Length of stay was 1.7 days (1-3). Mean follow up was 15.2 months (1-26). At follow up, all patients had no AI, AS peak gradients of 5-25mmHg, and all were NYHA class I.

**Discussion:** We report the first use of TAVR for treatment of native AI in pediatric patients. All 3 patients underwent successful TAVR placement. All devices were over-sized to account for non-calcified aortic annuli. Short-term results are promising with sustained relief of aortic insufficiency and improvement in functional status at most recent follow-up. Ongoing investigation and additional follow up are needed.

#### 115. TRANS-JUGLAR PULMONARY VALVE PERFORATION IN A 32 WEEKS, 30 HOURS OLD TWIN PRETERM WEIGHING 1.2 KG FOR DUCT DEPENDENT PULMONARY CIRCULATION (PULMONARY ATRESIA INTACT INTER-VENTRICULAR SEPTUM) USING CTO WIRE

Sudeep Verma<sup>1</sup>, Gouthami V<sup>1</sup>, Nagarajan R<sup>2</sup>

<sup>1</sup>Krishna Institute of Medical Sciences (Kims), Secunderabad-Hyderabad, India. <sup>2</sup>Krishna Institute of Medical Sciences, Secunderabad-Hyderabad, India

**Introduction:** We are presenting here a case of pulmonary atresia with intact IVS in a 33 weeks one of twin preterm weighing 1.2 Kg, symptomatic just after birth with severe cyanosis requiring PG infusion. Neonate underwent successful pulmonary valve Perforation on day 2 of life from right internal juglar route using Miracle CTO wire.

**Case Description:** 33 weeks preterm twin weighing 1.2 kg delivered by emergency LSCS ventilated in view of respiratory distress and worsening cyanosis. With diagnosis of hyaline membrane disease one dose of surfactant was given. Cardiac evaluation revealed duct dependant pulmonary circulation with pulmonary atresia- intact IVS, moderate TR, TV annulus Z score of -1.2 with no sinusoids. Started on Prostaglandin infusion in view of desaturation, acidosis, low PO<sub>2</sub>, and haemodynamic instability. Decided to perform pulmonary valve perforation and if required PDA stenting. Internal Juglar and Femoral access were secured in NICU itself. After repeated unsuccessful attempts to enter RV from femoral venous route RV was entered from IJV route using 4Fr JR 1.5 catheter. With catheter in RVOT,

valve was perforated using 0.014 Miracle CTO wire in left lateral view. Subsequently pulmonary valve was dilated serially using PTCA and Tyshak balloons respectively. Post procedure developed retroperitoneal haematoma and persistent bleeding from puncture site which was managed conservatively with blood products and inotropes. Baby had fluctuating saturation requiring intermittent Prostaglandin infusion. Baby was ventilated for 4 days after procedure and managed in NICU with excellent preterm care and finally discharged home on day 35 of life with room air saturation of 88%. 6 months follow up showed asymptomatic status, good antegrade flow across pulmonary valve with no stenosis, moderate to severe PR, good sized RVOT and TV annulus (Z score of +0.04) with room air saturation of 92%.

**Discussion:** This case highlights the feasibility of doing pulmonary valve perforation using internal juglar route in case of difficulty in entering RV from femoral route. Also highlights the issue pertaining to puncture site complications and importance of good preterm care in improving outcome for such duct dependant situations presented as early as on day one of life

#### 116. EMERGENCY TRANS-UMBILICAL VERTICAL VEIN STENTING AS AN INTERIM PALLIATION IN A 10 HOURS OLD 33 WEEKS PRETERM FOR OBSTRUCTED SUPRACARDIAC TAPVC

Sudeep Verma<sup>1</sup>, Gouthami V<sup>2</sup>, Nagarajan R<sup>3</sup>, Anil Kumar Dharmapuram<sup>3</sup>, Raja R<sup>4</sup>

<sup>1</sup>Krishna Institute of Medical Sciences (Kims), Secunderabad-Hyderabad, India. <sup>2</sup>Krishna Institute Of Medical Sciences(Kims), Secunderabad- Hyderabad, India. <sup>3</sup>Krishna Institut Of Medical Sciences (Kims), Secunderabad-Hyderabad, India. <sup>4</sup>Krishna Institute O Medical Sciences (Kims), Secunderabad- Hyderabad, India

**Introduction:** Vertical vein stenting serves as an interim palliation for stabilisation of haemodynamically unstable obstructed supracardiac TAPVC. We are describing a case of supracardiac TAPVC with haemodynamic vise presented with low cardiac output and severe metabolic acidosis , underwent successful left vertical vein stenting from transumbilical route at 10 hours of life with improvement in the clinical condition followed by complete surgical correction

**Description:** 33 weeks preterm with birth weight of 1.8 kg born with emergency cesarean section presented with respiratory distress and cyanosis just after birth. Hyaline Membrane Disease was suspected hence ventilated and 2 doses of surfactant were given. In view of

worsening distress baby was shifted to High frequency ventilation but persisted to have low output state and severe metabolic acidosis and desaturation. X ray showed white out lung with reticular pattern consistent with HMD. In view of poor response to surfactant and ventilation, echocardiography was performed that revealed supra cardiac TAPVC draining to left innominate vein with severe obstruction at left vertical vein (haemodynamic wise). In view of persistent metabolic acidosis, low cardiac output, high ventilatory settings and worsening X ray picture, it was decided to do interim palliation with vertical vein stenting. After securing umbilical venous access with 6F Sheath, ductus venosus was crossed with 0.032 Terumo J tip wire with 4F JR 1.5 catheter. Vertical vein injection revealed obstruction at confluence to vein junction. Obstructed segment was crossed with 0.014 PTCA wire and obstruction was relieved initially with 1.5x12 and 3x15 PTCA balloon respectively followed by successful stenting using 5x15 Renal stent negotiated through 5F JR Guide catheter. Post procedure from second day onwards developed features of third spacing and odema with renal shut down that needed peritoneal dialysis for 5 days after which renal output improves and edema subsided. On day five of procedure underwent successful surgical correction of TAPVC with good recovery.

**Discussion:** This case highlights the feasibility of interim palliation for vertical vein obstruction in selected case of critical obstruction and unstable haemodynamics. In presence of patent umbilical vein it is feasible to perform the procedure from umbilical route safely.

### 117. TANDEM PLACEMENT OF TWO DUCT OCCLUDERS GENERATION II DEVICES IN SUPEROINFERIOR VENTRICLES WITH CRISS CROSS ATRIOVENTRICULAR FLOWS NORMALLY RELATED GREAT ARTERIES AND LARGE MEMBRANOUS VSD

Sudeep Verma<sup>1</sup>, Gouthami V<sup>2</sup>

<sup>1</sup>Krishna Institute of Medicalsciences, Secunderabad-Hyderabad, India. <sup>2</sup>Krishna Institute of Medical Sciences (Kims), Secunderabad- Hyderabad, India

**Introduction:** Superior inferior ventricles with criss cross atrioventricular flows associated commonly with discordant Ventricular-arterial relationship. We are presenting a rare case of membranous septal aneurysm with multiple VSD in superoinferior ventricles and criss cross AV connection with AV - VA concordance, closed with tandem placement of two duct occluder generation II devices.

**Case Details:** 15 month old toddler weighing 7.2 kg presented with poor weight gain and recurrent respiratory tract infection referred with diagnosis of CCTGA and VSD. Examination revealed features of large left to right post tricuspid shunt with poor localisation of apex beat. Chest X-ray showed cardiomegaly, differential vascularity with right lung plethora and left lung oligemia. ECG revealed sinus rhythm, left superior QRS axis and biventricular forces. Echocardiogram revealed situs solitus, levocardia, juxtaposed right atrial appendage, superior inferior ventricles, criss cross AV flows, AV-VA concordance, membranous septal aneurysm and multiple VSD's with severe pulmonary artery hypertension. Oximetry run showed step up of 17% across right heart with QP/Qs of 2.5:1. PA pressure were 70% of the systemic pressure with mean of 40 mm Hg. Ventricular injections revealed superior position of RV and LV in inferior position with elongated LVOT without obstruction. LPA was angulated with physiological oligemia due to preferential streaming from MPA towards RPA. Two Duct Occluder generation II devices ( 6/4 and 5/4 respectively) were deployed in tandem manner across septal aneurysm from retrograde technique with complete abolition of shunt. In both cases VSD were crossed using 6Fr JR 3.5 guide catheter with **0.032 Terumo angled wire**. Child persisted to have moderate pulmonary arterial Hypertension with absence of symptoms at 2years follow up hence continued on pulmonary vasodilators.

**Conclusion:** It is challenging to establish diagnosis of Criss Cross AV flows with AV-VA concordance and NRG. Orientation of the IVS changes hence device closure challenging in such cases. Delineation of the VSD by angiogram is difficult hence meticulous echocardiographic evaluation is needed. Tandem device placement with multiple ADO II is possible in such cases with membranous septal aneurysm and multiple defects.

### 118. PILOT STUDY FOR THE USE OF 3-D PRINTED MODELS TO REDUCE ANXIETY ABOUT CONGENITAL CARDIAC CATHETERIZATIONS

Preston J. Boyer<sup>1</sup>, Jennifer G. Andrews<sup>1</sup>, Trahern W. Jones<sup>1</sup>, Michael D. Seckeler<sup>2</sup>

<sup>1</sup>University of Arizona, Department of Pediatrics, Tucson, AZ, USA. <sup>2</sup>University of Arizona, Department of Pediatrics (Cardiology), Tucson, AZ, USA

**Background:** Cardiac catheterizations (caths) for congenital heart disease (CHD) can be times of anxiety for patients and families. Pre-procedure meetings are one strategy that could address this anxiety. A variety of educational tools (diagrams, echocardiograms, CT/MR imaging and

angiography) can be used to help families understand complex anatomy and pathophysiology. More recently, 3-D printed patient-specific models can be added to the armamentarium. The purpose of this study was to evaluate the effectiveness of different educational tools to help patients and families have a better understanding and less anxiety about their procedure.

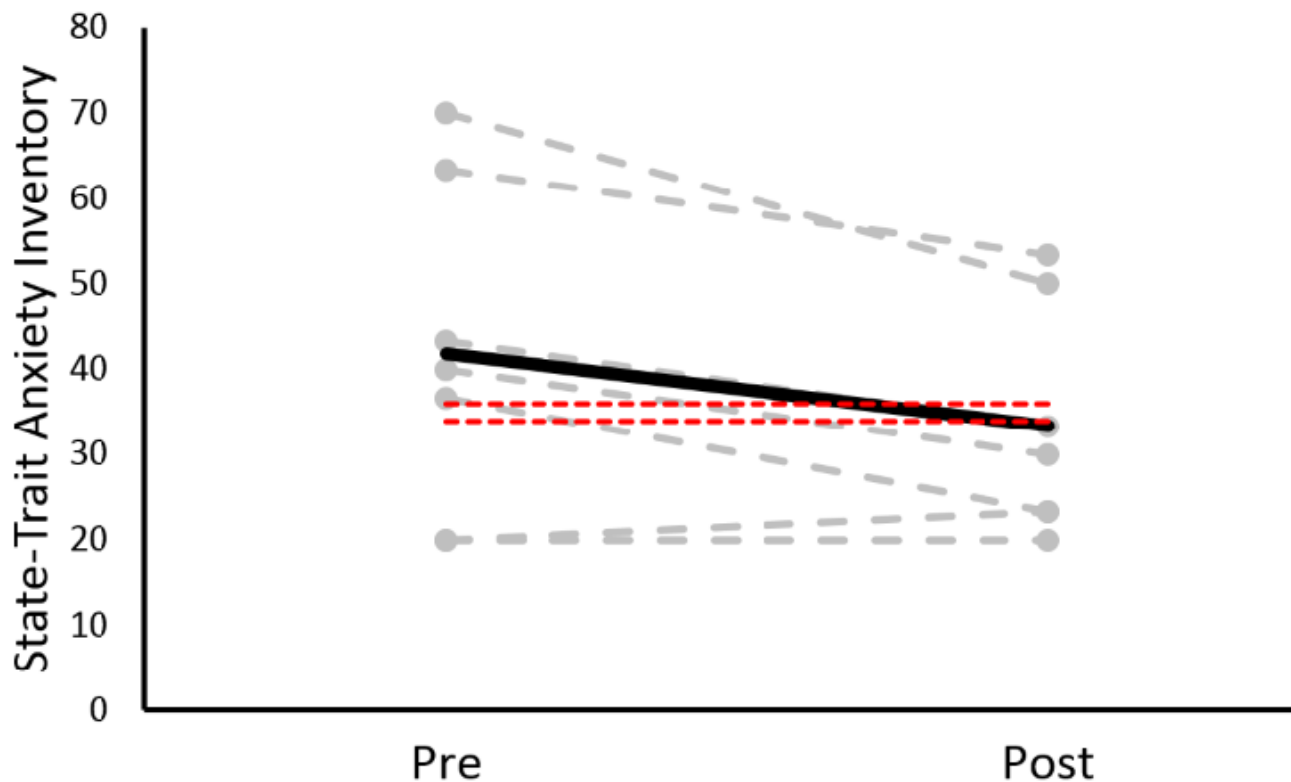
**Methods:** After approval from the Institutional Review Board, patients over 18 and parents of patients under 18 scheduled for clinically indicated catheters were invited to participate in two brief online surveys before and after meeting with the interventional cardiologist, who was blinded to study participation. Both the pre- and post-meeting surveys measured anxiety using the State-Trait Anxiety Inventory (STAI). In addition, the post-meeting survey evaluated the subjective value (from 1-4) of individual teaching methods: physician discussion, diagrams, echocardiograms, CT/MRI imaging, angiograms and 3-D printed cardiac models. Data were compared using paired t-tests.

**118. Table.** Demographics. Data are presented as median (interquartile range) or n(%).

Age (y)	9 (3, 24)
Female (n, %)	3 (43%)
Cardiac defect (n, %)	
ASD (secundum or sinus venosus)	3 (43%)
PDA	2 (29%)
S/p Fontan	2 (29%)

**Results:** 14 patients were invited to participate, 11 consented to participate and 7 had complete data; demographics are shown in the Table. Mean STAI were abnormally elevated at baseline and decreased into the normal range after intervention (41.9 to 33.3,  $p=0.028$ ; Figure). Physician discussion, diagrams and 3D models were reported to be most effective at increasing understanding and reducing

**118. Figure –** Pre- and post-intervention State-Trait Anxiety Inventory scores. Individual scores are shown with gray dashed lines and the mean scores are shown with the solid black line. There is a statistically significant decrease in scores after intervention into the normal range. Note, the normal low and high scores (34 and 36) are shown with dashed red lines.





anxiety about the upcoming procedure (each rated  $4\pm 0$ ), while angiograms, echocardiograms and CT/MRI scans were less effective (rated  $3.88\pm 0.35$ ,  $3.86\pm 0.38$  and  $3.57\pm 1.13$ , respectively).

**Conclusion:** In this pilot study, we have found that pre-cath meetings can produce a measurable decrease in patient and family anxiety before a procedure. Discussions of the procedure, diagrams and 3D printed cardiac models seem to be most beneficial, while CT/MRI scans and angiograms are less effective.

### 119. TRANSCATHETER TRICUSPID VALVE-IN-VALVE REPLACEMENT WITH AN INOVARE® VALVE

Mauricio Jaramillo-Hincapie<sup>1</sup>, Raul Arrieta<sup>2</sup>, Paulo Motta<sup>3</sup>, Maria Cristina Rezende<sup>1</sup>, Daniel Palmieri<sup>1</sup>, Barbara Costalonga<sup>1</sup>

<sup>1</sup>Brasilia'S Hospital, Brasilia, Brazil. <sup>2</sup>Heart Institute, Sao Paulo, Brazil. <sup>3</sup>Brasilia'S Hospital, Brasilia, Brazil

In this abstract we describe the case of a 13-year-old woman, 54 Kg, with severe bioprosthetic tricuspid valvular stenosis and regurgitation, 10 years after tricuspid valve replacement. She presents signs and symptoms consistent with right-sided heart failure. Transthoracic echocardiography revealed severe bioprosthetic TV stenosis and regurgitation, mean transvalvular gradient was 17 mmHg, peak transvalvular gradient, 27 mmHg; moderate right ventricular dysfunction and giant right atrium. The heart team consider a very high risk for a new valve replacement, and indicate an VIV procedure. Under general anesthesia, a surgical jugular vein access was done, a Judkins right catheter was advanced into de 11F sheath and across the tricuspid bioprosthesis, to the distal right inferior pulmonary artery with an 0.035-in Amplatz Extra-Stiff guidewire. Balloon valvuloplasty of the tricuspid bioprosthesis was performed with a 23-mm × 4.5-cm Cristal® Balloon Valvuloplasty Catheter (BALT, Inc). Next, the 22-mm Inovare® transcatheter Valve (Braile Biomedical, SJ Rio Preto, Brazil) mounted on 23mm x 4,5 cm -mm Balloon Valvuloplasty Catheter (BALT, Inc) was inserted over the Amplatz wire in the jugular vein trough an 23 cm -24F sheath (Cook Medical Inc.). After two unsuccessful attempts to across the tricuspid bioprosthesis by the jugular vein, the system was removed. Using a percutaneous right femoral vein access, the right Judkins catheter and Amplatz wire was advanced into the right pulmonary artery; next, removed the catheter and a 24F sheath (Cook Medical Inc.) was placed on femoral vein. The system 22-mm Inovare® transcatheter Valve (Braile Biomedical, SJ Rio Preto, Brazil) was inserted over the Amplatz wire. Under fluoroscopic guidance, the

valve was then advanced into the tricuspid bioprosthesis and positioned in the usual manner, with use of the prior metallic ring as a reference, the balloon was inflated and the valve was deployed with excellent results. Minimal residual tricuspid regurgitation and 10 mmHg peak gradient was observed on TEE. The patient's venous sheaths were removed, and hemostasis was obtained. The patient tolerated the procedure well with no complications. She was discharged from the hospital after an uneventful post-operative stay of 3 days.

### 120. STENTING FOR ANGLED OR BIFURCATED LESIONS ASSOCIATED WITH CONGENITAL HEART DISEASE USING A CURVED BALLOON: PRELIMINARY EXPERIMENT AND LIMITED CASE SERIES

Hiroaki Kise<sup>1</sup>, Takanari Fujii<sup>2</sup>, Hideshi Tomita<sup>2</sup>, Yosuke Kono<sup>1</sup>, Masashi Yoshizawa<sup>1</sup>, Takako Toda<sup>1</sup>, Minako Hoshiai<sup>1</sup>

<sup>1</sup>University of Yamanashi hospital, Chuo-city, Japan. <sup>2</sup>Showa University Hospital, Shinagawa, Japan

**Background:** Despite numerous procedural evolutions in surgical techniques, postoperative stenosis may develop especially at the anastomosis site or bifurcated lesion in CHD. Although successful percutaneous interventions for such lesions have been reported, stenting is still challenging due to its angled configuration, which may cause deformity of the stent or the target vessel.

**Objective:** To determine the effect of stenting for angled lesions using curved balloon, Goku curve (Tokai Medical Co. Nagoya, Japan).

**Methods:** In vitro study: A coronary stent (MULTI-LINK coronary stent 4mm/18mm) was placed in vertical (90°) vessel model (ePTFE graftφ4mm). After stenting by the conventional stent-mounted balloon system, post-dilatation using curved balloon (Goku curve 4mm/20mm) was performed. The vessels' angle, stent's adhesion and residual stenosis were assessed. Clinical utility: Stenting using curved balloon were performed in 2 patients (1 y/o and 5 y/o). The target lesions were anastomotic stenosis of BTS in unilateral absence of pulmonary artery (case 1) and RPS in TOF with absent pulmonary valve (case 2).

**Results:** In vitro study: Stenting at the angled lesion by initial stent-mounted balloon catheter made the 90°-angled lesion unbend to 140°. Mal-apposition of the stent was revealed at greater curvature and the stenosis was not relieved. Post-dilatation using curved balloon made the stent bend to the vessel's angle and released the stenosis. Clinical utility: In case 1, the stent (Palmaz genesis

4mm/15mm) was placed at the stenosis between BTS and distal pulmonary artery. Stenosis was completely relieved by the first stent's inflation. And deformity was revealed at distal end due to the small diameter of RPA, which could not be resolved by post-dilatation using curved balloon (GOKU curve 4mm/20mm). In case 2, the stent (Express vascular LD 8mm/17mm) was placed at the bifurcation of RPA. Although the stenosis was relieved, protrusion and mal-apposition on the edge were revealed on the greater and lesser curvatures, respectively, which were completely resolved by post-dilatation using curved balloon (GOKU curve 8mm/20mm).

**Conclusions:** Stenting using curved balloon can release the stenosis at angled lesion without deformity and mal-apposition of the stent.

### 121. INTRAVASCULAR STENTING FOR COARCTATION OF AORTA AND ACQUIRED INTERRUPTION WITH FIBROUS CONTINUITY -INDIAN EXPERIENCE WITH EARLY AND INTERMEDIATE FOLLOW UP

Sudeep Verma<sup>1</sup>, Rajendra Kumar Jain<sup>2</sup>

<sup>1</sup>Krishna Institute of Medical Sciences (Kims), Secunderabad-Hyderabad, India. <sup>2</sup>Krishna Institut of Medical Sciences, Secunderabad-Hyderabad, India

**Background:** Endovascular stent placement for treating coarctation of aorta is a well established treatment modality. We are sharing our experience of treating coarctation of aorta and functional acquired interruption with its technical challenges and effect of stenting on Aortic regurgitation associated with bicuspid valve.

**Methods-Observation/Results:** Since 2008, 28 patients with median age of 21 years (range 9-58 years) were attempted for Coarctation stenting. Procedure was abandoned in one due to profunda femoral artery injury. Three patients with interrupted aortic segment was crossed antegrade using CTO wire, while in one interrupted segment was crossed from left subclavian artery access using Guide catheter and balloon support. 11 patients underwent pre-dilatation using peripheral balloon or serial PTCA balloons (in acquired interruption cases). Palmaz / Genesis stent were used in 8 cases, in 2 cases Andra stents were used while in rest CP stents (covered in 6 and uncovered in 12) were used. In two patients due to more horizontal orientation of coarctation stent was deployed keeping traction on wire snared from right radial artery. Median pre procedure gradient was 70 mm Hg (range 30- 200 mm Hg) dropped to 10 mm Hg (range nil - 30 mm Hg). 6 patients had loss of lower limb pulsations with preserved

lower limb circulation. 2 patients developed severe radial artery spasm during the procedure recovered later. One patient developed large puncture site haematoma that is treated with blood products and compression bandage. On mean follow up period of 48 months, four out of 5 patients with significant residual gradient (mean 33 mm Hg) underwent successful balloon coarctoplasty while in one procedure was abandoned in view of inability to cross catheter across the residual coarctation. One of the interesting finding is decrease in severe AR in 5 cases (moderate in 4 and mild in one) after stent placement.

**Conclusion:** Coarctation of aorta and functional interruption of aorta with preserved fibrous continuity are amenable for stenting considering its technical challenges. Puncture site bleeding issues and radial artery spasm are the major procedure related complications. Interestingly severe AR associated with bicuspid valve tends to decrease after successful coarctation stenting.

### 122. AXILLARY APPROACH FOR DUCTAL STENTING IN CRITICAL RIGHT VENTRICULAR OUTFLOW LESIONS IN THE NEONATAL PERIOD

Colm Breatnach, Khalid Al-Alawi, Paul Oslizlok, Kevin Walsh, Damien Kenny

Our Lady's Children's Hospital, Dublin, Ireland

**Introduction:** Patent ductus arteriosus (PDA) stenting has become an accepted early palliative intervention for neonatal patients with critical right sided obstructive heart lesions. It also has the advantage of promoting branch pulmonary artery growth. Access to tortuous PDA's may be challenging via the femoral artery, while the carotid artery leads to concerns regarding stroke. Recently, the axillary artery has been utilised to gain access in these patients. We aimed to assess our early experience using this approach.

**Methods:** We performed a retrospective review of neonatal patients managed with PDA stenting via the axillary artery. Patients were identified from a dedicated National Institute of Cardiology Outcomes Research (NICOR) database. The medical records of these patients were reviewed to ascertain demographic and clinical details. Data were summarized using medians (range), means and descriptive evaluation.

**Results:** Neonatal stenting via the axillary artery was performed in six patients (4 males and 2 females) with a median age of 5 days (range 1 – 8 days) and weight of 3.4Kg (range 3 – 4kg). All 6 patients required PDA stenting for right ventricular outflow tract obstruction/atresia.

Five of the six patients required 2 stents to achieve adequate ductal cover. Median procedural time was 114 minutes (range 95 – 133), with a median fluoroscopy time of 20 minutes (range 15 – 55) and median radiation dose of 307 Greys (range 136 – 404). Three patients received the XIENCE Alpine stent and 3 the Abbott Vascular multi-link vision stent. There were no procedure related complications in any patients. Mean PICU stay was 40 hours with a mean intubation time of 23 hours. One patient subsequently died of a non-procedure related cause.

**Conclusion:** We have demonstrated that stenting of the patent ductus arteriosus via the axillary artery is a viable option in patients with critical right outflow lesions in the newborn period. This approach has advantages regarding ductal orientation. It avoids the need for carotid artery entry. Larger studies are needed to more accurately define complication the rates of this technique.

### 123. EMBOLIZATION THERAPY FOR GIANT PULMONARY ARTERIOVENOUS FISTULAS

*Mauricio Jaramillo-Hincapie, Luciano Liberato, Vinicius Pena, Ailton Dias, Edmur Araujo*  
Heart Hospital, Brasilia, Brazil

We report a 25 year-old-man referred by the pulmonologist, with notable clinical findings included cyanosis, clubbing, dyspnea at minimal efforts, frequent headache, left pulmonary bruits, periferal oxygen saturation 70% on room air and 50% after exercises. Abnormal findings on X ray and giant arteriovenous malformation in the lower left pulmonary lobe were observed on CT scan. Under intravenous conscious sedation and local anesthesia, a puncture in the right femoral vein was done and advanced a 11 cm 6F sheath. Using a Right Judkins catheter and 260 cm hidrofilic 0,035 guidewire, selective angiographies was performed in each pulmonary lobe. We found a little arteriovenous fistula on distal lower right pulmonary lobe and multiple in the lower left pulmonary lobe. Two of this with moderate flow and dilation of pulmonary veins and one bigger saccular malformation 10 x 7 cm, with proximal artery with 15 mm diameter and important flow and dilation of the inferior pulmonary vein. Selective catheterization of each anomalous branch with a slip catheter and 260cm Amplatz extra support 0,035" guide wire, we advanced a 90 cm Destination Hidrofilic Sheath (Terumo, Inc) into the each malformations to proceed the proximal branch embolization. We used 3 Amplatzer Vascular Plugs (AVP II) - (Abbott Inc): the first AV distal fistula with an AVP II 6 mm, the bigger anomalous branch with an AVP II 20 mm

and the medial fistula with an AVP II 8 mm. Control angiographies showed immediate and dramatic reduction on pulmonary fistulas flow with appearance a lot of normal vessels and increased on periferal oxygen saturation until 97%.

No complications were observed during procedure, and hospital discharge after 24 hours no adverse events. As shown in the literature a percutaneous embolization of pulmonary arteriovenous fistulas, even in giant malformations, is possible and good results are obtained with low complication rates, of this way, avoiding surgical procedures with higher morbidity like a surgical resection or lobectomy.

### 124. INITIAL EXPERIENCE OF DRUG ELUTING STENTS IN PEDIATRIC POPULATION WITH DUCT DEPENDENT CIRCULATION

*Umamaheshwar K L, Sivakumar Kothandam*  
Madras Medical Mission, Chennai, India

**Background:** The use of drug eluting stents (DES) to curb neo-intimal hyperplasia and restenosis associated with Bare metal stents, is well described in coronary interventions. However there is limited data on safety, efficacy and long term patency of DES in paediatric interventions.

**Objective:** This study was undertaken retrospectively to assess safety, efficacy and mid-term outcome of second generation DES in duct dependent pulmonary circulation.

**Methods:** Between January 2015 and February 2018, 21 patients with duct dependent circulation underwent elective implantation of second generation DES. Patients were followed by clinical examination, echocardiography, and repeat catheterisation prior to surgery.

**Results:** DES were deployed in ducts of TOF with PA (11), CTGA with PA (4), Tricuspid atresia with PA(3) and PA with intact ventricular septum(3). Mean age was 16+11days (range 3days -3months) and mean weight was 3.26+0.91kg (Range 2-5.1kg). Pre procedure left pulmonary artery(LPA) measured 4.35+0.95mm (2-6mm) while right pulmonary artery(RPA) measured 4.41+1.27(2-7mm). Femoral artery access was chosen in all cases except two requiring axillary access. Five cases were done under general anaesthesia. Mean fluoroscopic time was 19.75+/-14.82 min (3.15- 59.31min). 7 everolimus eluting, 2 zotarolimus eluting and 12 sirolimus eluting stents were used. Two or more stents were used in 6 cases. Size of stents ranged from 3 to 4mm x 8 to 28mm. The saturation improved from 72.11+10.92 to 87.37+5.1 post procedure. In 2 cases the LPA was jailed. Inotropes were used in 8 cases. Temporary femoral

pulse loss was seen in 8(38.1%) cases. Two deaths occurred during in-hospital stay due to failure and superimposed respiratory infection. One patient died at home on follow up. The total hospital stay was 7.83+4.2 days with ICU stay of 2.35+2.2 days. During last Echo follow-up, LPA measured 7.78+2.24mm (5-13mm) while the RPA measured 8.57+/-1.83mm (5.5-11mm). Six patients undergone successful surgery, single ventricular pathway in 5 and biventricular pathway in 1 case after 13.33+5.57 months (Range 9-24 months) of stenting. Mild LPA origin narrowing was observed in all cases except one during surgery.

**Conclusions:** The use of DES is associated with good patency over midterm follow-up with less restenosis.

### 125. ATRIAL SEPTOSTOMY WITH A PREDEFINED DIAMETER USING A NOVEL OCCLUTECH ATRIAL FLOW REGULATOR IMPROVES SYMPTOMS AND CARDIAC INDEX IN PATIENTS WITH SEVERE PULMONARY ARTERIAL HYPERTENSION.

*Rajesh Kumar, Sivakumar Kothandam, Umamaheshwar KI*  
Madras Medical Mission, Chennai, India

**Background:** Atrial septostomy relieves syncope in pulmonary arterial hypertension (PAH) by improving left heart filling, cardiac output and systemic oxygen transport despite hypoxia. Symptoms recur when small fenestrations close spontaneously.

**Methods:** AFR was implanted after informed consent in patients with severe PAH presenting with syncope and right heart failure. Symptoms, hemodynamics, echocardiographic parameters, brain natriuretic peptide (BNP) levels and device patency were serially documented.

**Results:** Twenty two patients aged 28.3±8.5 years with severe PAH underwent AFR implantation. All procedures were successful without any major complications. All patients had relief of syncope and 6-min walk distance improved significantly from 377.3 ± 33.2 to 423 ± 31.32 m. The cardiac index (2.36±0.52 to 2.89 ± 0.56 L/min/m<sup>2</sup>) and systemic oxygen transport (367.5 ± 75.5 to 428.0 ± 67.1 ml/min/m<sup>2</sup>) also showed a significant improvement. Inferior caval vein congestion and pericardial effusion reduced due to improvement in heart failure, but other echocardiographic parameters of right ventricular function did not show significant change. The reduction in BNP levels too did not reach statistical significance. The device was patent in all patients at a median follow-up of 189 days

(range 10–296 days) resulting in a significant reduction of oxygen saturations from 98±0.18 to 85.26 ± 2.86% after exercise.

**Conclusions:** AFR implantation was feasible and safe in all patients with PAH. There was a significant improvement of symptoms, six-minute walk distance, cardiac index and systemic oxygen transport. The device maintained patency in short-term follow-up and the resultant hypoxia was tolerated well.

### 126. FEASIBILITY, SAFETY, COMPLICATIONS AND MIDTERM FOLLOW-UP OF PATIENTS WITH ATRIAL SEPTAL DEFECTS CLOSED NON-SURGICALLY USING VERY LARGE 40-46 MM NITINOL SEPTAL OCCLUDERS

*Umamaheshwar K L, Sivakumar Kothandam*  
Madras Medical Mission, Chennai, India

**Aims:** Atrial septal occluders > 38mm are not routinely used in many countries. Feasibility, safety, complications and follow-up of patients with atrial septal defects closed with devices ≥ 40mm are unknown.

**Methods and results:** Patients with atrial septal defects closed using devices ≥ 40mm in a single center were retrospectively analyzed. Patients with 40mm devices were compared with those with 42-46mm devices on demographic, echocardiographic, hemodynamic parameters, procedural characteristics and complications. Among 48 patients with mean defect size of 36.3±3.7mm (32-42mm), 17 patients received 40mm device and 31 received > 40mm device. There were no significant differences between the groups except larger defect size and higher need for special deployment techniques in the latter. In spite of acute technical success in all patients, two procedures failed including device embolization at 24 hours in one and restrictive left ventricular physiology resulting in hypotension, multiorgan failure and death in spite of percutaneous device removal in one. Two late deaths on follow-up were unrelated to the device. There were no erosions, aortic or mitral regurgitation, thromboembolic events. One patient developed delayed atrial flutter. All survivors reported improved symptoms.

**Conclusions:** Use of ≥ 40mm devices in appropriately selected patients is feasible in all, successful and safe in majority. Special deployment techniques are more often needed for deploying these large devices. Complications during the procedure and on follow-up were infrequent. Patients with deficient margins should be excluded for percutaneous device closure.

### 127. TRANSCATHETER CLOSURE OF SINUS VENOSUS ATRIAL SEPTAL DEFECT: HOW TO SELECT PATIENTS - INSTITUTIONAL EXPERIENCE FROM 15 PATIENTS.

Rajesh Kumar<sup>1</sup>, Sivakumar Kothandam<sup>2</sup>, Umamaheshwar KP<sup>3</sup>  
<sup>1</sup>Mad, C, India. <sup>2</sup>Madr, C, India. <sup>3</sup>M, C, India

Transcatheter closure of such defects has been described in the literature as an isolated case series. In our institution We have developed an innovative technique to close this defect by transcatheter means after assessing the suitability by balloon occlusion testing of defect.

**Aim:** To present our institutional experience of SVASD covered stent exclusion.

#### Inclusion Criteria:

- Supero-inferior extent of the ASD should not be longer than its transverse diameter
- RUPV should drain in the SVC RA junction

#### Exclusion Criteria:

- Caudal extension of SVASD into the fossa ovalis is exclusion
- RUPV drainage to high SVC or low RA
- Multiple RUPV draining at multiple levels

**Patient Data:** Among 15 patients, predominant were females with 3:2 ratio (F:M). Mean age group is 29.14±8.55(7-41 years). All patients underwent Balloon occlusion testing to delineate the defect and the anatomy of the anomalous pulmonary vein.

In SVASD with PAPVD, posterior wall of RSVC and anterior wall of RUPV are common but posterior wall of RUPV is normally connected to LA. This formed the basis of our hypothesis that if we can create a common wall between RSVC and RUPV by placing a covered stent in RSVC, RUPV should normally drain into LA and the defect will be closed.

**Results:** 15 patients underwent test balloon occlusion, 8 patients found suitable for the procedure, 6 patients successful closure and 2 failures.

Among the 7 patients whom we referred for surgery, 2 patients had elevation of PV pressure post balloon occlusion, 4 patients had unsuitable anatomy with too low or too high RUPV drainage, and 1 patient had accessory RUPV with inability to occlude with balloon.

#### Choosing the stent:

- Covered CP stents – 8 zig or 10 zig (custom made)
- Covered Andra stent

- Optimus CVS XXL – Andratec
- Advanta Atrium V12
- LENGTH SHOULD BE LONG TO ANCHOR IN SVC
- DIAMETER SHOULD SNUG FIT THE SVC

**Conclusion:** Usual treatment of SVASD with anomalous drainage of RUPV is open heart surgery. In our institutional experience of 15 patients only 7 patients were suitable. Carefully selected patients with SV-ASD may have interventional option for correction.

### 128. PROSPECTIVE RANDOMIZED COMPARISON OF THREE DIFFERENT TYPES OF NITINOL SEPTAL OCCLUDER DEVICES USED FOR TRANSCATHETER CLOSURE OF ATRIAL SEPTAL DEFECTS

Umamaheshwar K L, Sivakumar Kothandam  
 Madras Medical Mission, Chennai, India

**Background:** Nitinol occluders with modified designs from Amplatzer devices are used for nonsurgical closure of atrial septal defects. Trials comparing these designs involved fewer patients, were not randomized and did not use the designs concurrently.

**Objective:** A randomized prospective comparison of Amplatzer(ASO), Cera(CSO) and Figulla(FSO) septal occluders to study the procedural outcomes and complications

**Methods:** The principal investigator supervised patient inclusion and monitored the procedure to provide uniformity in operator performance. The different occluders were serially allocated to the included patients in consecutive order, one after the other, in a cycle of three. All demographic, procedural details and complications were analyzed. After calculating a sample size of 122 patients in each group, additional patients were recruited to ensure at least 80% follow-up.

**Results:** 450 consecutive patients equally divided between the three designs, were comparable in age, shunt ratio and pulmonary artery pressures. There were no major complications and procedural success was 99.6%. The defect and device sizes were larger with the CSO group; the delivery sheath size was smaller with ASO group. Special deployment techniques were needed less often with FSO group; cobra deformity was noted more often with FSO. However, these differences did not translate into differences in outcome or complications.

**Conclusions:** The new occluders are comparable to Amplatzer septal occluder and the complications are

uniformly low for all occluders in current era at experienced centers. The modified structural new designs do not show any advantages on the procedural complications on early and midterm follow-up, but long-term studies are warranted.

### 129. CARDIAC INTERVENTION IN NEWBORN PRETERM LOW WEIGHT WITH FALLOT TETRALOGY AND CRITICAL COARTATION

Walter Mosquera Alvarez<sup>1,2</sup>, Gutierrez Gil Jaiber<sup>2</sup>, Luis Ernesto Ponce Bravo<sup>1</sup>

<sup>1</sup>Universidad ICESI, Cali, Colombia. <sup>2</sup>Fundacion Clinica Valle del Lili, Cali, Colombia

Patients with TOF obtain good response to surgical management in the first year of life, however in patients with low birth weight, in whom a surgical intervention could lead to poor results, we frequently choose conservative management awaiting weight gain to take then to surgical correction. Aortic coarctation (AoCo) can be a primary or secondary event and can coexist with other cardiac pathologies. The symptoms can be oligoanuria, metabolic acidosis, heart failure and finally cardiogenic shock.

Here we present two cases in which, through cardiac intervention, two critical pathologies can be solved in newborns with low birth weight with satisfactory results until reaching the appropriate weight for surgical correction.

### 130. TRANSCATHETER CLOSURE OF PATENT DUCTUS ARTERIOSUS IN INFANTS WEIGHING 3 KG OR LESS WITH DIFFERENT DEVICES: FEASIBILITY, SAFETY AND OUTCOME STUDY

Umamaheshwar K L, Sivakumar Kothandam  
Madras Medical Mission, Chennai, India

**Background:** The technique of transcatheter closure of PDA has evolved greatly, however data on safety and efficacy are limited in < 3kg infants with haemodynamically significant ductus.

**Objective:** This study aimed to investigate the feasibility, safety and outcome of transcatheter closure of PDA in infants weighing < 3kg.

**Methods:** Patients weighing 3kg or less in whom transcatheter PDA closure was attempted were analysed retrospectively to review the immediate and midterm outcomes.

**Results:** Fifteen patients underwent transcatheter PDA closure between July 2013 to January 2018. Three infants

had Rubella syndrome, one was operated for mal-rotation of gut, one was syndromic while four had PDA of prematurity. The mean weight was 2.41+0.65 kg (Range 1.4 -3.0; median 2.4kg) and mean age was 55+29 days (Range: 28 -120 days ). PDA measured 3.59+1.5mm with mean Pulmonary artery(PA) pressure of 40.13+ 12.36 mm Hg and PA to Aortic pressure ratio of 0.73+ 0.14.

All procedures were done from femoral venous access under conscious sedation. No arterial access was taken. The devices used were ADO I like occluders(5/4,6/4,8/6,8/6mm) in 4 cases , AVP II(4,6,7,8,8mm) in 5 cases, ADO II Additional Size (5/4mm) in 1 case , AVP IV (6,7,7,8mm) in 4 cases and biptome assisted Cooks coils in 1 case. Devices were deployed using 4F sheath in 4, 5F sheath in 7 and 6F Sheath in 3 cases. One case required upsizing to 7F for retrieval purpose.

Successful device implantation with complete occlusion was achieved in all cases. Device embolisation in 2 patients was successfully retrieved and upsized. The requiring average fluoroscopic time was 10.57+ 14.12 minutes, range (2.83 - 56.03 minutes), longer in 2 patients due to device embolisation. There was no case of device related obstruction of aorta or access related vascular injury or death while one patient left PA was impinged on follow up (8mm AVP II used). Post procedural weight gain on a mean follow up of 10.07+9.4 months was 4.45+3.43 kg.

**Conclusions:** Transcatheter closure of haemodynamically significant PDA in infants weighing 3kg or less can be accomplished safely and effectively with properly selected devices in selected patients.

### 131. TRANSCATHETER CLOSURE OF LARGE LEFT ATRIAL APPENDAGE ANEURYSM.

Rajesh Kumar<sup>1</sup>, Sivakumar Kothandam<sup>2</sup>, Avinash T<sup>2</sup>

<sup>1</sup>Madras Medica Mission, Chennai, India. <sup>2</sup>Madras Medical Mission, Chennai, India

Transcatheter closure LAA aneurysm is possible in certain patients with suitable anatomy as an alternative to surgery. We have performed transcatheter closure of large LAA aneurysm in a 17 year old girl presented with recurrent stroke using 24 mm Amplatzer muscular VSD occluder. This case represents the first known closure of a large left atrial appendage aneurysm with a percutaneous septal occluder device.

**Case History:** A 17 yr old female was referred to echocardiographic examination to rule out patent foramen ovale

for suspected cardioembolic stroke. He was evaluated in neurology clinic for evaluation of recurrent stroke. 2D TTE showed a large cavity next to the left ventricle in the four-chamber view. Color Doppler imaging clearly demonstrated that the cavity had a direct communication with the normal-sized LA and a LAA aneurysm was diagnosed. There was no thrombus within the aneurysm or in the left atrium. The LAA aneurysm measured 10 X 4 cm, and the ostium of the defect measured 1.8 cm. The diagnosis was further confirmed by CT scan which showed a 10.8X5.5 cm LAA aneurysm and the ostium of the defect measured 1.88 cm.

Septal puncture done followed by pigtail catheter was advanced to the level of the LAA, and contrast was injected near the ostium of LAA to prevent any thrombus migration if any from cavity. We have also used Bilateral SpiderFX embolic protection device placed in bilateral carotid to prevent thrombus migration if any from cavity during device deployment. After careful review of images, a 24 mm Amplatzer muscular VSD occluder was chosen to close the aneurysm and was advanced to the defect. Check angiogram done to rule out obstruction to left PV drainage and LCX compression. TEE revealed no significant residual flow through the device after release. On follow up serial echo's showed regression in size of thrombosed cavity. After 1 month patient underwent CT scan showed device in stable position and resolved thrombosed cavity.

**Conclusions:** Transcatheter closure of LAA aneurysm is possible in certain patients with suitable anatomy. Advanced imaging modalities helpful in decision making. Need to take all protective strategies to prevent thrombus migration during the procedure.

### 132. PERCUTANEOUS DEVICE CLOSURE OF PARAVALVULAR LEAKS - OUTCOMES AND MAJOR ADVERSE CARDIAC EVENTS WITH MULTIPLE DEVICES AND MULTIPLE ACCESS SITES: A SINGLE CENTRE EXPERIENCE

*Umamaheshwar KL, Sivakumar Koyhandam*  
Madras Medical Mission, Chennai, India

**Aim:** To study procedural outcomes and major adverse cardiac events in patients undergoing transcatheter paravalvular leak(PVL) closure our centre.

**Methods:** Patients who underwent percutaneous repair of PVL from August 2013 to March 2018 were analyzed for procedural outcomes and major adverse cardiac events in intermediate term follow up.

**Results:** Thirty-four patient aged 51.37+15.28 years (Range 12-69 years); 31.25% female formed the study group. The mean hemoglobin was 10.84 + 2.2gm% (range 7-14 gm%). The main symptom was heart failure (85.23%) followed by severe hemolysis warranting blood transfusions (21.88%). Target valve was mitral in 28 (82.35%), aortic in 5 (14.71%) or both in 1 (2.9%). Aortic paravalvular leaks were closed retrogradely. Transseptal access with arteriovenous looping was done in 25(73.52%) patients. Apical access was taken for crossing the defects in 12(37.5%) and for deploying the device in 2 of those. One, two and multiple devices were used in 17, 18 and 7 cases respectively. Overall 58 devices were used. ADO II was used in 5 cases, AVP II in 13, AVP III in 4, AVP IV in 4, muscular VSD occluders in 9 and Occlutech PVL devices in 12 cases.

Procedure was technically successful, that is a device could be delivered without interference with the valve prosthesis in 96.88% of patients and there was  $\geq 1$  grade regurgitation reduction post closure in 90.3% of patients. The mean fluoroscopic time was 44+/- 21min (12-116 min). Two cases had device embolization of which one required surgery. In seven cases upsizing of devices was done due to inadequate closure. Apical puncture site was closed with either duct occluders (ADO 6/4,6/8mm), ADO II(5/6mm) or vascular plugs (AVPII 6,10mm). Three patients had hemothorax post apical puncture and required thoracotomy. Four patients required repeat procedures within three months.

Post procedure 5 (12.9%) patients had mild insignificant residual leaks at last follow up (mean duration 2.23+1.48 years; range: 1month to 4.5 year). One patient died during in hospital stay, whereas 2 patients died late at home.

**Conclusions:** Transcatheter paravalvular leak-closure procedures are technically demanding but can be accomplished in a high percentage of cases.

### 133. PERCUTANEOUS CLOSURE OF PATENT DUCTUS ARTERIOSUS- A SINGLE BRAZILIAN CENTER EXPERIENCE

*Célia Maria Camelo Silva, Ana Carolina Faccinnetto, Raianne Cord, Priscila Galdeano, Thayana Hadad Farias, Diego D' Albuquerque, Vitor Rolim, Clarice Cunha, João Saba, Luciana Nina, Jamile Campos, Fernanda Rêgo, Antônio Carvalho*  
Unifesp, São Paulo, Brazil

**Background:** Percutaneous occlusion of patent ductus arteriosus (PDA) has proven to be an effective and safe method in recent years. The aim of this study was to

describe the experience of percutaneous closure of patent ducts arteriosus in a Brazilian center.

**Methods:** It is a retrospective study of a single center between the years 2010 and 2017 that analyzed the frequency and the characteristic of PDA's occlusion.

**Results:** From August 2010 to December 2017, a total of 89 patients underwent percutaneous occlusion of the ductus arteriosus, sixty (67.4%) of were female. The mean age was 4.5 years (5mo to 44yrs). By Krichenko's classification, 60 (67.4%), patients were type A ,11pts (12.3%) type C, 5 (5.6%) type E, 3(3.3%) type D, and 10 (11.2%) pts has not been classified. Type C PDA was the most frequent in patients with pulmonary hypertension, type C. The used devices were: AVP II (51.68%), followed by Coil Flipper (33.7%), ADO II (5.61%) and AVP IV (2.24%). Six of this patients (6.74%) presented associated mild congenital heart disease, without hemodynamic repercussion. Immediate complete occlusion was obtained in 87 (97.7%) patients. Residual shunt and embolization, were observed in 2 (2.24%) patients only with Coil Flipper, only in patients with PDA and had a second closure performed using the AVP II, without residual shunt. All 2 embolized device were successful retrieved.

**Conclusion:** In our center, the percutaneous treatment of ductus arteriosus closure has been effective and safe. Residual shunt and embolization were only seen in PDA occluded by coil Flipper. Since AVP plug were available in our center we do not have residual shunt neither device embolization.

### 134. TRANSCATHETER CREATION OF VENTRICULAR SEPTAL DEFECT FOR RELIEF OF RIGHT VENTRICULAR HYPERTENSION IN SEVERE PULMONARY ARTERIAL HYPERTENSION.

*Varun Aggarwal, Corey Chartan, Ryan Coleman, Nidhy Varghese, Fadel Ruiz, George Mallory, Ernestina Melicoff-Portillo, Henri Justino*

Texas Children's hospital, Houston, USA

**Background:** Pulmonary hypertension (PH) is a progressive disease and medical management can be insufficient and unpredictable in the late stage of the disease. Creation of an atrial septal defect (ASD) or reverse Potts shunt has been proposed as a bridge to lung transplant or even destination therapy for some of these patients. However, ASD unloads the right heart inconsistently and reverse Potts shunt creation carries significant procedural risk. Here, we describe transcatheter ventricular septal defect (VSD)

creation, for the relief of suprasystemic right ventricular (RV) hypertension in the setting of severe PH.

**Methods:** Retrospective review of patients with severe PH who underwent transcatheter VSD creation at Texas Children's Hospital.

**Results:** Three children underwent VSD creation for the relief of RV hypertension over a three year period (2015-2018).

1. An 11-year-old boy on VA-ECMO support due to severe pulmonary veno-occlusive disease underwent ASD creation (for conversion to VV-ECMO) and VSD creation with stent placement (for the relief of RV hypertension). He was successfully bridged to lung transplant at which time ASD/VSD were closed.
2. A 14-year-old girl with idiopathic PH and severe RV dysfunction underwent VSD creation with stent placement. She had significant improvement in her cardiac function and heart failure symptoms and has acceptable systemic desaturation at the last follow up 7 months post procedure.
3. A 5-year-old boy with repaired congenital diaphragmatic hernia, chronic lung disease, severe PH had progressive RV failure despite having an ASD. VSD creation with stent placement resulted in improvement in RV function. In this small series, there was no procedural mortality or heart block. The improvement in RV function was sustained and quality of life remained good.

**Conclusions:** We present a novel interventional management of VSD creation (with stent placement) as a viable option to salvage RV function in the setting of severe intractable PH. This approach allows for direct pressure unloading of the RV with subsequent function recovery. It appears to be a safe and feasible technique for a select group of patients experiencing worsening RV function with acceptable short-term results.

### 135. CONGENITAL ISOLATED CORONARY CAMERAL FISTULAE: TALE OF 21 TAMED DRAGONS WITH CLINICAL ,IMMEDIATE AND INTERMEDIATE TERM OUTCOME

*Umamaheshwar K L, Sivakumar Kothandam*  
Madras Medical Mission, Chennai, India

**Objective and Methods:** 21 consecutive cases of coronary cameral fistulae(CCF) who underwent percutaneous closure were assessed retrospectively for the clinical presentation, immediate and midterm outcomes



**Results:** 21 cases of CCF were seen from January 2009 to December 2017. The median age of patients was 2 years (range 15 days-65years), with M:F ratio of 1.33. Presentation was asymptomatic (60%), chest pain(10%),and heart failure(30%). 4 were adults who presented with myocardial steal, atrial fibrillation,murmur and palpitation respectively. All patients had continuous murmur. Fistulae most commonly arose from RCA (8/21),draining into RA (4), RV (3), and LV (1). Fistulae from LMCA drained into RA (5), LAA (1) and PA(1). One patient had LAD to RV fistula. Left circumflex fistula drained in RA (2) and RV (3). Thirteen and eight patients had proximal and distal fistula respectively. Fistulae were closed at the distally, proximally and at both ends in 15,4 and 2 cases respectively. Standard arteriovenous loop, retrograde arterial route and both routes were used in 13, 5 and 2 respectively and one case ( LMCA to LAA fistula) was closed separately from venous end and arterial end without forming a rail road. Devices used were ADO in 5 cases, ADO II in 1 case, AVP I in 4 cases, AVP II in 7 cases, AVP IV in 4 cases and coils in 4 cases. More than one devices were used in 4 cases. Post procedure all were kept on DAPT except 2 (warfarin and aspirin). All were followed regularly by clinical examination, ECG, Echocardiography at 1, 6, and 12 months interval. There were no clinical, ECG changes or residual fistulae on echocardiography at followup. Check angiogram was done one year post procedure in 7 cases, one of this case had evidence of thrombosis in conduit artery with the distal device in situ. Four

cases with proximal fistula showed good flows in the conduit artery and two distal fistulae cases showed good remodelling of the conduit artery.

**Conclusions:** Percutaneous closure of coronary cameral fistula of varying sizes can be safely undertaken with excellent mid-term results.

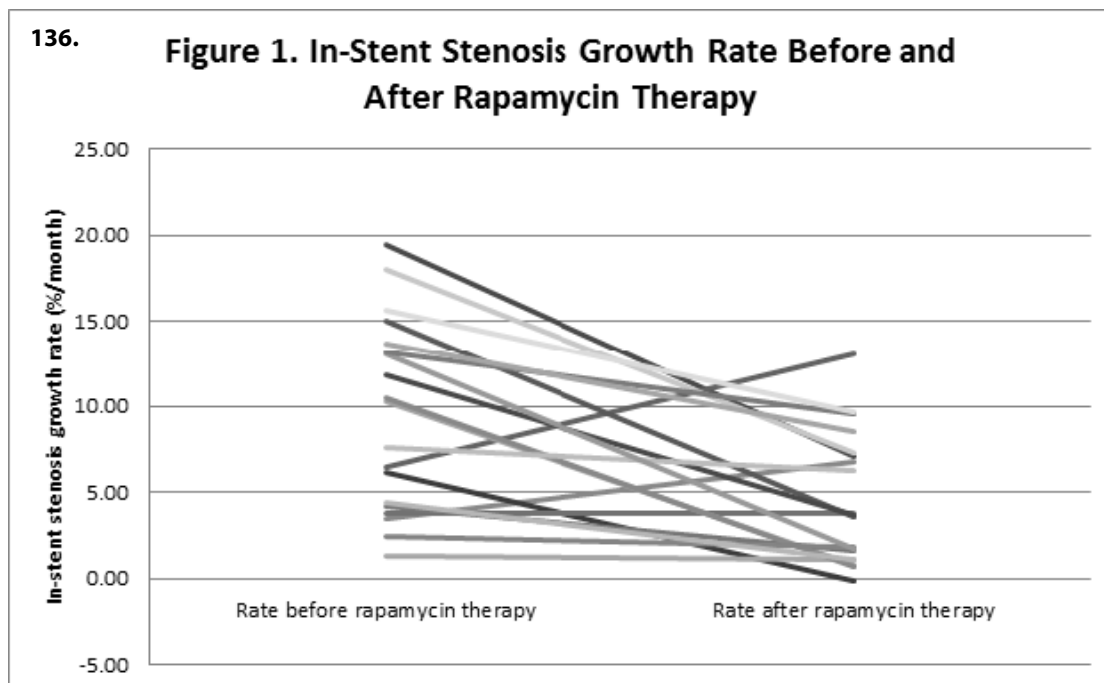
### 136. SYSTEMIC RAPAMYCIN TO PREVENT IN-STENT STENOSIS IN PULMONARY VEIN STENOSIS

Ryan Callahan, Jesse Esch, Grace Wang, Jim Lock  
Boston Children's Hospital, Boston, USA

**Objectives:** Evaluate the efficacy of systemic rapamycin (sirolimus) in preventing in-stent stenosis (ISS) in pulmonary vein stenosis (PVS). Report the adverse events related to rapamycin therapy.

**Background:** There is a high incidence of ISS following stent implantation in stenotic pulmonary veins. The use of systemic rapamycin in preventing ISS in PVS has not been reported.

**Methods:** Retrospective review of all patients who received systemic rapamycin (based on institutional protocol for ISS in peripheral pulmonary artery stenosis) for treatment of ISS for PVS between January 2013 and December 2017.



**Results:** Thirty-nine stents (36 bare metal, 3 drug-eluting) in 20 patients were treated with systemic rapamycin; 20 at the time of implantation (prophylactic) and 19 following documented ISS requiring transcatheter intervention (non-prophylactic). All patients had at least one follow-up catheterization. Treated patients were young (median 2 y/o [0.7-5.7]) and most had PVS associated with congenital heart disease (75%, 15/20; 4/15 with TAPVC). In the prophylactic group, 80% (16/20) of the stents (median diameter 6mm [4-7]) were without significant (<50%) ISS at median of 102 days (range 56-527); the growth rate of ISS in this group was 7.5 +/- 7.1 %/month. The largest series on the use of stents in PVS documented 52% (28/54) of stents were without significant ISS at median of 117 days (range 3-1314). In the non-prophylactic group (median diameter 5mm [3.5-10]), most stents had a slower growth rate of ISS after rapamycin therapy (9.5 +/- 5.6 vs. 4.6 +/- 3.8 %/month, p = 0.003; Figure 1). There was no association between the presence of significant ISS (prophylactic) or slower growth rate (non-prophylactic) and drug intensity (% time with therapeutic levels), whether a loading dose was given or if there was stenosis distal to the stent. One patient developed pneumonia on drug while concurrently taking another immunosuppressive agent. There were no other serious adverse events related to rapamycin therapy.

**Conclusion:** Systemic rapamycin may decrease the development of in-stent stenosis in pulmonary vein stenosis and can be administered safely in pediatric patients with complex heart disease. A prospective study is required to further understand the role of systemic rapamycin in PVS.

### 137. TREATMENT OF ISOLATED PULMONARY VALVE STENOSIS WITH BALLOON PULMONARY VALVULOPLASTY IN THE NEONATAL PERIOD.

*Célia Maria Camelo Silva, Ana Carolina Buso Faccineto, Rianne Cord, Clarice Learth Cunha, Thayana Hadad Farias, Priscila Galdeano, Jamile Campos, Fernanda Rego, Diego D'Albuquerque, Vitor Rolim, Luciana Nina, João Saba, Antônio Carvalho*  
Unifesp, São Paulo, Brazil

**Background:** Balloon pulmonary valvuloplasty (BPV) has been considered a safe and effective method for the treatment of isolated pulmonary valve stenosis (PVS) in the neonatal population.

**Objectives:** To evaluate the clinical, angiographic and echocardiographic characteristics of BPV in the neonatal population.

**Methods:** From January 2016 to February 2018, 27 newborns from a Public Reference Hospital were submitted to BPV for the treatment of pulmonary valve stenosis. A retrospective study, which analyzed the clinical characteristics (weight and associated genetic syndrome), angiographic (balloon, balloon ring and intercurrent relationship) and echocardiographic characteristics (gradient, ring and morphological characteristics) and considered as a therapeutic success the reduction of the gradient below 40 mmHg and or decrease in the RV/LV pressure ratio less than 0.50. Statistical analysis used Square Chi-square test with Yates continuity correction and Fisher's test.

**Results:** Of the 27 treated patients, 17 (63%) were female, mean age 12 days, weight ranged from 2.2 to 5.7 kg, with a mean of 3.2 kg, and no patient had genetic syndrome. There were no deaths during the procedure. All patients had therapeutic success, 4 (14%) of the patients presented transient arrhythmia during the procedure, the balloon diameter was 8, 9 and 10, respectively: 3 (11.5%), 13 (50%) and 10 (38.5%) and ring/balloon ratio > 1.4 in 16 (61.5%) patients. All patients presented with echocardiography after BPV gradients lower than 40 mmHg (ranged from 0-34 mmHg, with an average of 7.8 mmHg). Pulmonary insufficiency (PI) was found in post-procedure echocardiography in all patients being light (LPI) in 20 pts (74%) moderate (MPI) and in 7 (26%) patients. When compared patients with LPI vs MPI: there was predominance in both groups: female (65 vs 57.1% p = 1.0), with the valve ring between 6-7 mm (63.2 vs. 42.9% p = 1.0), with the ring/balloon above 1.4 (63.2 vs 57.1% p = 1.0), balloons with diameter 8-9 were the most used (73.7 vs. 28.6% p = 1.0).

**Conclusion:** BPV is an effective method with few adverse events. The occurrence of MPI is considerable and may be related to ring/balloon ratio above 1.4, and to morphological aspects of the pulmonary valve, known to be more severe in this age group.

### 138. PATIENTS WITH REPAIRED TETRALOGY OF FALLOT UNDERGOING PERCUTANEOUS PULMONARY VALVE IMPLANTATION SHOW IMPROVED FLOW HEMODYNAMICS WHEN COMPARED TO SURGICAL PULMONARY REPLACEMENT

*Daniel McLennan, Michal Schafer, Gareth Morgan*  
Children's Hospital Colorado, Aurora, USA

**Objective:** To compare flow dynamics in proximal pulmonary arteries in patients with repaired Tetralogy of Fallot (TOF) before and after either surgical or percutaneous pulmonary valve replacement.

**Background:** TOF is the most common cyanotic congenital heart defect. Once repaired the flow dynamics are different from structurally normal hearts. They are often left without a competent pulmonary valve resulting in severe regurgitation. Valve regurgitation and flow recirculation through proximal pulmonary arteries causes kinetic energy loss, which elevates RV afterload leading to progressive RV dilation and maladaptive remodeling.

**Methods:** Four-dimensional Flow MRI (4D-Flow MRI) covering the entire right ventricle and proximal pulmonary arteries was performed in age and size matched TOF patient treated with surgical valve, percutaneous valve, and in a patient prior to pulmonary valve intervention. Kinetic energy dissipation mediated by turbulent and recirculative flow was calculated between the right-ventricular outflow tract (RVOT) to the distal portion of the right pulmonary artery (RPA) and left pulmonary artery (LPA). Flow hemodynamic pattern was further evaluated using interactive dynamic pathline visualization.

**Results:** Both patients underwent complete primary repair prior to one year with a transannular patch. Patients treated with percutaneous pulmonary valve implantation presented peak systolic KE loss of 4.9 mW along the RVOT – RPA and along the RVOT – LPA 2.6 mW. The patient who underwent surgically implanted valve showed dramatically elevated peak systolic KE loss along both RVOT – RPA tract 8.1 mW, and RVOT – LPA tract 3.9 mW. Furthermore, the patient treated with percutaneous valve implantation presented cohesive laminar flow through the proximal pulmonary arteries, whereas patient treated with surgically implanted valve presented with helical formations typically associated with turbulent flow and energy dissipation.

**Conclusions:** Prior to valve repair, patients with repaired TOF present extensive KE loss associated with pulmonary regurgitation which is typically corrected post valve replacement. Patient treated with percutaneous pulmonary valves revealed comparatively reduced KE loss when compared to surgically implanted valves. Quantitative evaluation of hemodynamic flow patterns prior to and post valve intervention in patients with TOF might identify novel prognostic markers of further RV function and help with clinical planning and timing of valvular intervention

### 139. TEN-YEAR EXPERIENCE OF DUCTUS ARTERIOSUS STENTING IN PATIENTS WITH PULMONARY OR

### SYSTEMIC DUCTOAL-DEPENDENT CIRCULATION IN AN ECUADORIAN POPULATION.

*Boris Barreno Martínez<sup>1,2,3</sup>, Simón Duque Solórzano<sup>1,2</sup>, Edwin Rodríguez-Cruz<sup>4</sup>, María Cecilia Masshu-Coello<sup>1,2</sup>, Mayra Reyes<sup>1,2</sup>, Valeria Guevara<sup>1,2</sup>*

<sup>1</sup>Roberto Gilbert E. Pediatric Hospital, Guayaquil, Ecuador.

<sup>2</sup>Catholic University Santiago de Guayaquil, Guayaquil, Ecuador.

<sup>3</sup>Guayaquil University, Guayaquil, Ecuador. <sup>4</sup>San Jorge Children's Hospital, San Juan, Puerto Rico

**Background:** The use of stents to maintain patency of the ductus arteriosus has been accepted and performed by many cardiac centers as an alternative to the Blalock-Taussig shunt in neonates with congenital heart disease with pulmonary or systemic ductus arteriosus dependent flow (1,2).

**Methods:** Retrospective review in a period of 10 years (2007-2017) of the clinical records of patients undergoing ductal stent placement in the pediatric cardiovascular intervention service of the Dr. Roberto Gilbert Children's Hospital in Guayaquil, Ecuador. Overall survival and morbidity (hospital length of stay, sepsis, procedural complications) were the main study variables.

**Results:** We identified a total of 81 patients, with ages ranging from 1 day to 11 months at the time of the stent placement (mean 68 days, median 30 days), 43 (53%) male and 38 (47%) female.

Eighteen patients (22%) required ductus stent placement on two occasions and and three (3%) patients underwent Blalock Taussig shunt surgery due to ductus stent obstruction.

From the total of patients twenty-two patients advanced to another surgical phase: 13 patients with correction of Tetralogy of Fallot (biventricular correction), in 19 patients with univentricular physiology Glenn surgery was performed and 1 case (5%) progressed to Fontan surgery.

Regarding complications, 31 patients presented pulmonary artery stenosis, of which in 10 patients (32%) corresponded to left branch, 7 (22%) to right branch and in 7 (22%) stenosis of the stent. The average hospital stay after catheterization was 22 days and the main morbidity was sepsis in 16 patients (19%).

Mortality was 32%, corresponding to 28 patients, only in 14 patients (16%) occurred within the first 30 days after therapeutic catheterization.

**140. Table I: Pre-Procedural Characteristics Associated with ICU Admission (N =593)**

Patient & Procedural Characteristics	n (%)	Final Model	
		OR (95% CI)	P-value
Age <1 year	87 (15%)	3.57 (1.77, 7.19)	<0.001
Presence of Systemic Illness	126 (21%)	1.74 (0.90, 3.36)	0.10
Physiologic Category:			
Category I	316 (53%)	<i>Reference</i>	—
Category II	251 (42%)	2.42 (1.20, 4.89)	0.01
Category III	26 (4%)	13.8 (4.16, 45.9)	<0.001
Recent Intervention <90 days	87 (15%)	2.56 (1.32, 4.99)	0.006
Procedure Risk Group:			
Low	150 (25%)	<i>Reference</i>	—
Medium	299 (50%)	12.7 (1.61, 99.5)	0.02
High	144 (24%)	48.2 (6.23, 373)	<0.001

Logistic regression was used to evaluate relationships between potential predictor variables and outcome discharge to ICU. Final model c statistic 0.88.

**Conclusions:** Stent implantation is a good alternative for palliation treatment of ductal-dependent circulation. In our 10 years experience it has become the treatment of choice in our institution, especially when in later years the mortality and morbidity of the procedure has become lower with acquired experience.

#### 140. INTENSIVE CARE UNIT ADMISSION TOOL FOR CONGENITAL HEART CATHETERIZATION (ICATCH): A PREDICTIVE MODEL FOR HIGH LEVEL POST-CATHETERIZATION CARE

Brian Quinn, Juan Ibla, Diego Porras, Julie Slattery, Lisa Bergersen

Boston Children's Hospital, Boston, USA

**Background:** Currently, there is no standardized method for identifying patients at risk of needing high-complexity care following cardiac catheterization for congenital heart disease

**Objectives:** We sought to develop a pre-procedural prediction model for accurately identifying patients at risk for requiring intensive care unit (ICU) admission following elective cardiac catheterization for congenital heart disease.

**Methods:** Patient characteristics were prospectively collected on all cases scheduled for congenital cardiac

catheterization at Boston Children's Hospital who were not coming from the ICU, beginning in August, 2017. Additional exclusions included patients undergoing endomyocardial biopsy with or without coronary angiography. Patient and procedural characteristics were compared among those who were managed post-catheterization with ICU resources vs. patients admitted to the general floor or discharged home. Through univariate analysis, statistically significant characteristics ( $p < 0.001$ ) were further evaluated in a forward stepwise process and considered for inclusion in the final multivariate model if the variable remained statistically significant when accounting for other patient characteristics.

**Results:** A total of 593 cases were recorded between August 1, 2017 and April 11, 2018; of which 84% ( $n=499$ ) came from home and 16% ( $n=94$ ) were inpatients on a medical unit. Overall, 11% of patients ( $n=66$ ) were admitted to the ICU, while 64% ( $n=382$ ) were admitted to a medical unit and 11% ( $n=66$ ) were discharged home. In multivariate analysis, following predictors were identified: age <1 year (OR 3.57), presence of systemic illness (OR 1.74), physiologic category 2 (OR 2.42), physiologic category 3 (OR 13.8), recent intervention (catheterization or surgical) <90 days (OR 2.56), procedural risk group "medium" (OR 12.7), and procedural risk group "high" (OR 48.2), model c statistic 0.88 (Table I).

**Conclusion:** The ICU admission tool created in this study will be further tested and validated in larger datasets, improving the precision of ICU bed assignment planning and allocation of hospital resources, while generalizability will be broadened through tool refinement and multi-center collaboration.

#### 141. TRANSCATHETER PULMONARY VALVE IMPLANTATION FOLLOWED BY PFO CLOSURE IN A PATIENT WITH HYPOXEMIA DUE TO RIGHT TO LEFT INTRACARDIAC SHUNT

*Akanksha Thakkar, Stephanie Fuentes, Danish Bawa, Eunice Karanja, Gary Monteiro, John Breinholt, Thomas MacGillivray, Alan Lumsden, C. Huie Lin*  
Houston Methodist Hospital, Houston, USA

**Background:** Pulmonic valve stenosis (PS) and regurgitation (PR) are expected complications after Tetralogy of Fallot (ToF) repair. Perturbation of right heart hemodynamics may induce RV remodeling causing functional tricuspid regurgitation (TR) and a vicious circle of maladaptive RV remodeling. PFO in these patients may be hemodynamically advantageous, but resulting hypoxemia can be debilitating in some adults. We report a 44M with ToF repair complicated by RV-PA homograft PS and PR causing RV enlargement and functional TR who presented with hypoxemia due to R to L shunting through a PFO.

**Case:** 44M with ToF s/p initial repair at age 3 followed by pulmonary homograft repair at age 30 presented with dyspnea on exertion and hypoxemia in the 80s requiring home O<sub>2</sub>. Pulmonary workup demonstrated no intrinsic lung abnormality. TTE showed LVEF 55-59%, severe RV enlargement with moderately depressed function, PR and PS. CMR showed RV volume and pressure overload, severe RV enlargement (RVEDVi 152 ml/m<sup>2</sup>), moderately depressed RV function (RVEF 39%), PFO with R to L shunt (Qp:Qs 0.93), moderate PS, moderate PR and TR. Patient was taken to the cath lab for transcatheter pulmonary valve implantation and possible PFO closure. A Melody valve was successfully deployed in the RV-PA homograft conduit within a P4010 PALMAZ XL stent, and post-dilated to 24mm. Improvement in O<sub>2</sub> saturation occurred from the mid-80s (80% FIO<sub>2</sub>) to the mid-90s immediately post valve deployment, likely secondary to improved RV diastolic hemodynamics causing reduced R to L shunting through the PFO. Intra-cardiac echo demonstrated a continuous shunt by color Doppler, so the PFO was closed using a 25 mm Amplatzer PFO occluder. TTE 1-month post procedure showed a well-functioning transcatheter pulmonary valve and PFO occluder. Clinically, patient remained free of

hypoxemic episodes with O<sub>2</sub> saturation consistently in the high 90s without supplemental oxygen and improvement in symptoms.

**Conclusion:** As a PFO may be hemodynamically advantageous in RV pressure and volume overload, closure for hypoxemia should only be considered after addressing the underlying pathophysiology. Earlier RVOT intervention may be required to interrupt maladaptive RV remodeling, especially in the presence of functional TR.

#### 142. FREQUENCY OF LPA CATHETER INTERVENTIONS IN PATIENTS WITH TETRALOGY OF FALLOT AFTER SURGICAL PULMONARY ARTERY AUGMENTATION

*Melissa Webb, Beth Price, Manoj Parimi, Saadeh Al-Jureidini*  
St. Louis University, St. Louis, USA

**Background:** Patients with Tetralogy of Fallot (TOF) frequently undergo surgical augmentation of one or both of the pulmonary arteries and can require intervention on branch pulmonary artery stenosis throughout their life. The goal of this study was to describe the frequency of left pulmonary artery (LPA) catheter reinterventions in patients who have previously undergone different augmentation techniques.

**Methods:** A retrospective chart review was performed on all patients who underwent TOF repair between January 2012 until January 2016. Data obtained included type of TOF, age at time of repair, material and technique used for LPA augmentation (extended versus patch), and indications for and type of LPA reintervention required. The frequency and need for reintervention was then described according to technique used for LPA augmentation.

**Results:** Eighteen of 117 patients who underwent TOF repair also had LPA augmentation at the time of surgery. Seven of these patients underwent extended LPA augmentation using conduit material (3 pulmonary and 1 aortic homograft, 3 bovine jugular) and 11 underwent patch augmentation (1 pulmonary homograft, 7 pericardium, 2 bovine pericardium, 1 bovine jugular vein). The mean age of patient was 7 months (12 days to 2 years). Four patients (57%) who underwent augmentation with extension of conduit material and 8 (n=73%) patients who underwent augmentation with patch placement underwent LPA intervention.

**Conclusion:** Our study suggests that those patients who undergo extended rather than patch augmentation of their LPA may have a lower rate of LPA reintervention.

Limitations to this study include a low number of patients, the lack of pre-surgical LPA size data, and the variable material used.

### 143. PERFORATION OF ATRETIC VASCULAR STRUCTURES USING THE HIGH FREQUENCY APPLICATION THROUGH ELECTRIC SCALPEL IN PATIENTS WITH CONGENITAL HEART DISEASES.

*Giolana Cunha, Marcella Maia, Luiz Kajita, Expedito Ribeiro, Raul Arrieta*

Heart Institute - University of São Paulo, São Paulo, Brazil

**Introduction:** The use of perforation of atretic vascular structures using the radiofrequency system is the treatment of choice in cases of imperforate valves or "blind bottom" occlusion of vessels, however, cost and availability limit their use, especially in the Public System of Health. We aim to offer an alternative method of treatment using the high frequency through electric scalpel in patients with congenital heart diseases.

**Method and Results:** Case report. Two patients submitted to high frequency electrodissection using Electrical Surgical Unit (ValleyLab Force-Fx™ Scalpel). Technique: "triaxial" system consisting of a JR catheter 5 Fr, 2.3 Fr microcatheter and a 0.014 "chronic occlusion guide. The guide was connected to the electric scalpel being used 50-60W of cutting power.

**Patient 1:** female, 4yo, 15 kg, diagnosis of pulmonary atresia, VSD, hypoplastic pulmonary arteries and MAPCAs, Blalock Taussig shunts (right: with stenosis; left occluded). Chest angioCT: pulmonary trunk and confluent and hypoplastic pulmonary arteries (2 mm). The perforation: a "retrograde" form - from the pulmonary trunk to the right ventricle - advanced Microcatheter Progread (Boston Scientific) through the BT to the pulmonary trunk posteriorly a guide of chronic occlusion 0.014 "Hi-Torque Progress 80" was connected to the electric scalpel 50Watts) and perforated the pulmonary valve retrograde; performed arteriovenous loop, where it was advanced and implanted Renal Dynamic stent 5x19mm in the RVOT. After 5 months: patient SO2 75% awaiting angioTC control.

**Patient 2.** Female, 19yo, 64kg, diagnosis of coarctation of native aorta ("blind bottom"). The microcatheter positioned in a descending aorta, perforated area was drilled with a guidewire of chronic occlusion 0.014 "Progress 80 connected to the electrobisturi (60Watts cut), followed by angioplasty with a 4x12mm balloon and a 45mm covered CP stent implant mounted in a Maxi LD 14x40mm

balloon in the region of CoAo, later expanded with a Maxi LD 18x40mm flask. Hospitalar discharge on the 4th day after procedure. At follow-up 9 months after aortoplasty, asymptomatic patient.

**Conclusion:** The perforation using of high frequency (Electrosurgical Scalpel) and the "triaxial system" was possible in the two cases presented, and could be offered as an alternative technique for drilling in selected cases.

### 144. PERCUTANEOUS TRICUSPID VALVE IMPLANT IN THE LATE POSTOPERATIVE PERIOD OF CONGENITAL HEART DISEASES USING A BRAZILIAN BIOPROSTHESIS: INITIAL EXPERIENCE IN SOUTH AMERICA.

*Giolana Cunha, Marcella Maia, Luiz Kajita, Jose Honório Palma, Expedito Ribeiro, Henrique Ribeiro, Raul Arrieta*

Heart Institute - University of São Paulo, São Paulo, Brazil

**Introduction:** Primary diseases of the tricuspid valve (TV) are uncommon, either congenital or acquired. These patients (pts) usually require valve replacement and future reinterventions with high morbidity and mortality. We present an alternative on off-label transcatheter tricuspid valve-in-valve implantation (TVIV) using a bioprosthesis developed and manufactured in Brazil. Our aim is demonstrate the initial experience of transcatheter bioprosthesis implantation in the tricuspid position.

**Methodology:** Case report. The procedures were performed in a hybrid suit and patients under general anesthesia. The bioprosthesis used Braile Inovare prosthesis (Braile Biomedical, São José do Rio Preto, Brazil)). the valve is a balloon-expandable prosthesis with a lozenge cobalt-chromium frame, 20 mm height, three radiopaque markers (identifying base, valve and skirt) and a single sheet of bovine pericardium composing the leaflets in the following diameters: 20, 22, 24, 26, and 28 mm The access was the right jugular vein by dissection; in one case an approach was required via mini-thoracotomy. Pre-dilatation and balloon measurement were performed before implantation of the bioprosthesis. The procedures were guided using 3D transesophageal echocardiography (TEE) and fluoroscopy.

**Conclusion:** In this initial experience, the percutaneous implantation of the Braile Inovare bioprosthesis in the tricuspid position was effective and safe for patients with important dysfunction of the previously surgical TV implanted bioprosthesis; the use is capable of providing

**144. Table 1.** Valve tricuspid valve-in-valve.

Case	Sex	Age	Diagnosis	FC NYHA pre	Regurgitation	Approach	Size Valve	Hospitalar discharge	FC NYHA post
1	M	32	Ebstein Anomaly	II	Severe	Righ internal jugular vein	26	19	I
2	M	22	Endocarditis	II	Moderate	Righ internal jugular vein	26	11	I
3	F	42	Ebstein Anomaly	III	Severe	Transatrial	28	7	II
4	M	16	Tetralogy of Fallot	VI	Mod-Severe	Righ internal jugular vein	28	18	II
5	F	34	VSD +TV regurgitation	III	Mod-Severe	Righ internal jugular vein	30	10	II
6	F	46	Ebstein Anomaly	III	Severe	Righ internal jugular vein	30	<b>4</b>	II

encouraging results with increased functional and structural cardiac improvement.

#### **145. AIMING FOR LESS CONTRAST AND RADIATION: THREE-DIMENSIONAL IMAGE FUSION GUIDANCE IN THE TREATMENT OF AORTIC COARCTATION: A COMPARISON WITH TRADITIONAL ANGIOGRAPHY AND THREE-DIMENSIONAL ROTATIONAL ANGIOGRAPHY.**

Juan Pablo Sandoval<sup>1</sup>, Jose Garcia Montes<sup>1</sup>, Carlos Zabal<sup>1</sup>, Tomasz Moszura<sup>2</sup>, Pawel Dryzek<sup>2</sup>, Guillermo Aristizabal<sup>1</sup>, Carlos Sisniega<sup>1</sup>, Maciej Lukaszewski<sup>2</sup>, Jadwiga Ana Moll<sup>2</sup>, Sebastian Goreczny<sup>2</sup>

<sup>1</sup>Ignacio Chavez National Institute of Cardiology, Mexico City, Mexico. <sup>2</sup>Polish Mother's Memorial Hospital, Lodz, Poland

**Background:** Image-guidance using pre-existent CT or MR datasets with traditional fluoroscopy to provide real-time overlay of targeted anatomic structures represents a novel and promising tool in vascular and cardiac interventions including aortic coarctation. This imaging modality could potentially shorten the duration of interventions as well as reduce contrast and radiation exposure when compared with 2D angiography (2DA) and three-dimensional rotational angiography (3DRA).

**Methods:** Two-centre retrospective review evaluating and comparing three different imaging modalities in patients treated for aortic coarctation: 2DA, 3DRA and using a 3D image fusion software (Vessel Navigator, Philips) (VN). Data collected included patient demographics, type of coarctation (native vs recoarctation) and intervention (balloon angioplasty or stent), fluoroscopy

and procedure time as well as overall radiation exposure and amount of contrast. P value for continuous parametric variables was determined with ANOVA and for continuous non-parametric variables Kruskal-Wallis test was used. For categorical values  $\chi^2$  was used.

**Results:** From 2015 to February 2018, 77 patients underwent treatment for aortic coarctation; 54 (70%) native and 23 (30%) recoarctation. Seventy-two (93%) patients underwent aortic stenting. According to each imaging modality, 22 patients underwent treatment with 2DA, 24 with 3DRA and 31 with VN assistance. Median (IQR) age of the total cohort was 11 years (6-15) with a mean (SD) weight of 39.9(23.4) with no statistical differences regarding age or weight between the 3 groups. VN assisted patients received significantly less contrast, 90ml (50-159) when compared with 2DA, 140ml (75-207) or 3DRA, 162ml (120-200) ( $p < 0.001$ ). Also, Air kerma tended to be lower in the VN group, 136mGy (77-309) vs 303mGy (116-454) in 2DA and 233mGy (103-527) in 3DRA patients respectively,  $p = 0.089$ . There were no statistical differences among the groups regarding DAP, fluoroscopic and procedure time.

**Conclusions:** 3D image fusion between pre-procedural imaging datasets and live fluoroscopy results in reduction of contrast and absorbed dose of radiation (Air kerma) as compared to traditional 2D angiography and 3DRA for the treatment of aortic coarctation.

#### 146. 3D CARDIAC PRINTING TO PLAN TRANSCATHETER CLOSURE OF AN IATROGENIC PRIMUM ATRIAL SEPTAL DEFECT

Stephanie Fuentes Rojas<sup>1</sup>, Akanksha Thakkar<sup>2</sup>, Ponraj Chinnadurai<sup>2</sup>, Eunice Karanja<sup>2</sup>, Danish Bawa<sup>2</sup>, Stephen Little<sup>2</sup>, C. Huie Lin<sup>1</sup>

<sup>1</sup>Houston Methodist Hospital, Houston, USA. <sup>2</sup>Houston Methodist, Houston, USA

**Background:** Primum atrial septal defects (ASD) conventionally require surgical repair because of the proximity to the atrioventricular valves. We present the case of a percutaneous closure of an iatrogenic primum ASD using 3D printing to simulate the case during pre-procedure planning.

**Case Presentation:** A 71-year-old man with aortic dissection and endocarditis status post aortic and mitral valve replacement presented with dyspnea and abdominal distension. Transthoracic echocardiogram (TTE) showed preserved left ventricular (LV) function, depressed RV (RV) function and a transesophageal echocardiogram (TEE) identified an iatrogenic primum ASD (iASD, 0.9x1.3 cm) with L-R shunt (Qp/Qs 1.7) attributed to suture dehiscence after the most recent mitral valve replacement. He was deemed a poor surgical candidate, hence, 3D reconstruction guided percutaneous closure was planned. A high-resolution cardiac CT was used to print a 3D model of the patient's anatomy. Transcatheter closure was then performed on the 3D printed model. A 25 mm GORE® CARDIOFORM Septal Occluder (Gore, Flagstaff, Arizona) best apposed the septum and closed the iASD while minimizing impingement of the prosthetic mitral apparatus and tricuspid valve demonstrated by post-procedure rotational angiography and 3D reconstruction (Artis, Siemens, Hoffman Estates, Illinois) of the model and occluder. Once we demonstrated anatomic safety and feasibility on the model, patient underwent closure of the iASD using a combination of real time 3D-TEE and fluoroscopy with a 25mm CARDIOFORM Septal Occluder. Post-delivery, TEE confirmed adequate position, which was nearly identical to that on the 3D model. On follow up, the patient's symptoms had resolved.

**Conclusion:** This case demonstrates the utility of 3D printing and *in silico* modelling and closure of a primum iASD in a patient with a prosthetic mitral valve. Use of the 3D printed model in combination with rotational angiography and 3D reconstruction allowed determination of the behavior of the occluder device in unusual pathological anatomy in advance of the actual procedure. This strategy may facilitate innovative minimally invasive intervention of cardiovascular defects in the absence of purpose-built

devices and where traditionally surgery has been the only option.

#### 147. LONGITUDINAL IMPROVEMENTS IN RADIATION EXPOSURE WITHIN PROCEDURAL RADIATION RISK CATEGORIES IN CARDIAC CATHETERIZATION FOR CONGENITAL HEART DISEASE: A PROSPECTIVE MULTI-CENTER C3PO-QI STUDY

Priscila Cevallos<sup>1</sup>, Brian Quinn<sup>1</sup>, Aimee Armstrong<sup>2</sup>, David Balzer<sup>3</sup>, Howaida El-Said<sup>4</sup>, Susan Foerster<sup>5</sup>, Andy Glatz<sup>6</sup>, Andrea Goodman<sup>1</sup>, Bryan Goldstein<sup>7</sup>, Michael Hainstock<sup>8</sup>, Dana Janssen<sup>9</sup>, Jacqueline Kreutzer<sup>10</sup>, Larry Latson<sup>11</sup>, Ryan Leahy<sup>12</sup>, Christopher Petit<sup>13</sup>, Shabana Shahanavaz<sup>3</sup>, Sara Trucco<sup>10</sup>, Wendy Whiteside<sup>7,14</sup>, Jeff Zampi<sup>14</sup>, Lisa Bergersen<sup>1</sup>

<sup>1</sup>Boston Children's Hospital, Boston, USA. <sup>2</sup>Nationwide Children's Hospital, Columbus, USA. <sup>3</sup>St. Louis Children's Hospital, St. Louis, USA. <sup>4</sup>Rady Children's Hospital, San Diego, USA. <sup>5</sup>Children's Hospital of Wisconsin, Wauwatosa, USA. <sup>6</sup>Children's Hospital of Philadelphia, Philadelphia, USA. <sup>7</sup>Cincinnati Children's Hospital Medical Center, Cincinnati, USA. <sup>8</sup>University of Virginia Children's Hospital, Charlottesville, USA. <sup>9</sup>Monroe Carell Jr. Children's Hospital at Vanderbilt, Nashville, USA. <sup>10</sup>Children's Hospital of Pittsburgh, Pittsburgh, USA. <sup>11</sup>Joe Dimaggio Children's Hospital, Hollywood, USA. <sup>12</sup>Norton Children's Hospital, Louisville, USA. <sup>13</sup>Children's Healthcare of Atlanta, Atlanta, USA. <sup>14</sup>CS Mott Children's Hospital, Ann Arbor, USA

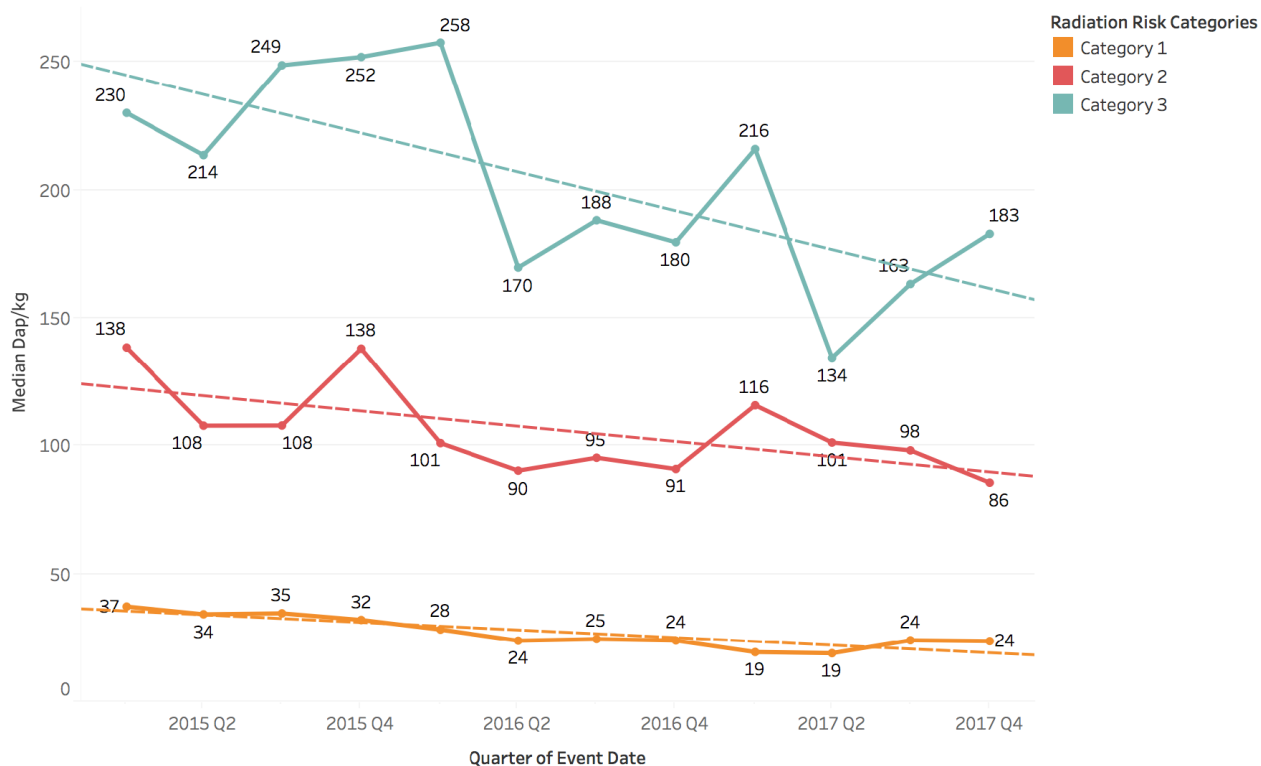
**Background:** Efforts to reduce radiation exposure in pediatric cardiac catheterization to the lowest reasonable levels achievable are important to decrease the impact of cumulative ionizing radiation exposure on long-term health.

**Objectives:** The Congenital Cardiac Catheterization Project on Outcomes (C3PO) multi-center collaborative sought to improve radiation safety practices and decrease radiation doses by at least 10% for all cases and among three procedural categories.

**Methods:** Data was collected prospectively for all cases performed at C3PO participating sites. Using established quality improvement methodology, a key driver diagram was created with strategic domains of intervention and utilized to implement institution-specific radiation safety practices. Examples of employed institutional strategies within various domains include: automatic operator radiation threshold alerts built into equipment, establishing institutional Radiation Reduction Committees with benchmark goals, increased staff education, lowering equipment default fluoroscopy rates, and working with equipment vendors to build weight category options. 40 heterogeneous procedure types were grouped into 3 radiation risk categories according to expected similar radiation



### 147. Longitudinal Radiation Exposure within RRC



exposure (low, medium, and high). Radiation exposure was expressed as dose area product (DAP) per kilogram of body weight ( $\mu\text{Gy}\cdot\text{M}^2/\text{kg}$ ) and summarized by quarter and percent change over time for all procedures and by radiation risk category.

**Results:** Between January 2015 and December 2017 a total of 15,067 cases from 9 centers with complete case capture were recorded (Radiation Risk Category I: 10,417 cases; Category II: 2,806; Category III: 1,844). The 10% radiation dose reduction goal was met for all procedures and within all radiation risk categories. Radiation exposure for all cases was reduced from 55  $\mu\text{Gy}\cdot\text{M}^2/\text{kg}$  (2015 Quarter 1) to 41  $\mu\text{Gy}\cdot\text{M}^2/\text{kg}$  (2017 Quarter 4), a 25% improvement. Radiation doses were lowest for Radiation Risk Category I and highest for Radiation Risk Category III, with the greatest improvement observed within Radiation Risk Category II (Category I: 35% change; Category II: 38%; Category III: 20%).

**Conclusions:** A purposeful combination of quality improvement approaches can lead to meaningful reductions in radiation exposure and increased patient safety, namely improved techniques over time

among complex procedures, education awareness initiatives, and mindful radiation reduction efforts. Figure 1.

### 148. EVALUATION OF TRANSCATHETER STENTING OF AORTIC COARCTATION IN PEDIATRIC AGE GROUP

Hala Mohamed Fawzy ElMarsafawy<sup>1,2</sup>, Naguib AbdelFattah<sup>3</sup>, Sherif Mostafa Kamal Reda<sup>3</sup>, Hassan Saad AbuSai<sup>3</sup>, Asmaa Bakr<sup>4</sup>, Shaimaa AbdelMeguid<sup>4</sup>, Hany Abuhadid<sup>4</sup>, Mona Hafez<sup>4</sup>, Gehan Attia<sup>4</sup>, Mohamed Matter<sup>4</sup>, Mohamed Magdy Abuelkhair<sup>4</sup>

<sup>1</sup>Cardiology Unit, Children Hospital, Mansoura, Egypt. <sup>2</sup>Faculty of Medicine, Mansoura, Egypt. <sup>3</sup>Faculty of Medicine, AlAzhar University, Cairo, Egypt. <sup>4</sup>Faculty of Medicine, Mansoura University, Mansoura, Egypt

**Introduction:** Coarctation of the aorta is relatively common defect that accounts for 5% to 8% of all congenital heart defects. Clinical presentation of coarctation varies, ranging from heart failure in infancy to asymptomatic hypertension and/or a murmur in an older child or adult. Transcatheter stent implantation for aortic coarctation is increasingly used as a treatment option at younger ages,

limited information is available on long-term results and follow-up in the pediatric population.

**Aim of Work:** to evaluate safety and efficacy of transcatheter stenting of native and recurrent coarctation of aorta at short-term and intermediate follow-up in pediatric age group.

**Subjects and Methods:** It was a prospective cohort study, which included 20 pediatric patients with hemodynamically significant CoA confirmed by ECHO and MDCT. It was conducted at Cardiology Unit, Mansoura University Children Hospital, From May 2014 to March 2017. Body weight  $\geq 15$  kg. M/F ratio 15/5, age ranges  $10.1 \pm 4.2$  years,  $37 \pm 22$  Kg. 12 patients have native coarctation and 8 with recurrent ones. Covered CP (Nu-MED) stent was used in 7 patients, Palmaz Genesis in 7, Andra stent in 5, and uncovered CP stent was used in one. Stent diameters varied from  $11 \pm 1$ , length  $35 \pm 6$ . Different types of balloons were used Zmed 12, Crystal 3, Opta 2, PowerFlex2, BIB 1. Peak to peak pressure gradient decreased from  $37 \pm 17$  to  $7 \pm 5$ . In stent stenosis was found in 3 patients, Redilatation of stent was needed in 3 patients after period 15.7 months (4-23), stents used were one covered CP stent 2 Bare metal Palmaz genesis stent. No stents fractures were found

**Conclusion:** Transcatheter stenting of native and recurrent coarctation of the aorta in pediatric age group appears to be an acceptable and effective treatment. This supported by of effective relief of the CoA pressure gradients in both native and recurrent coarctation. Reintervention is relatively uncommon and related to severity of coarctation, type of stent used, early and late aortic wall injury, and need for re-dilatation of relatively small diameter stents with growth.

#### 149. ANTIPLATELET THERAPY AFTER PFO CLOSURE IN A BREASTFEEDING MOTHER: EFFECT ON DEVICE CHOICE

Eunice Karanja<sup>1</sup>, Danish Bawa<sup>1</sup>, Stephanie Fuentes-Rojas<sup>1</sup>, Akanksha N. Thakkar<sup>1</sup>, Michael Pirics<sup>2</sup>, John J. Volpi<sup>3</sup>, C. Huie Lin<sup>1</sup>

<sup>1</sup>Houston Methodist DeBakey Heart & Vascular Center, Houston, USA. <sup>2</sup>Houston Methodist Hospital, Houston, USA. <sup>3</sup>Houston Methodist Neurological Institute, Houston, USA

**Background:** PFO closure in patients with cryptogenic stroke reduces the risk of recurrent events when combined with optimal medical therapy. However, there is limited data on maternal use of clopidogrel during breastfeeding and effect on infants. We report the case of a 31F with

cryptogenic stroke and PFO who underwent PFO closure six weeks post-partum.

**Case:** A 31F with a history of severe migraines presented with visual changes and a syncopal episode at 12 weeks of gestation. MRI brain showed chronic changes suggesting prior stroke. At 28 weeks, she presented with drooping of the right eye, likely secondary to a transient ischemic attack. TTE revealed a PFO with R to L shunt. No other cause for cerebral ischemia was found. Patient was placed on aspirin until delivery and PFO closure was planned for the post-partum period. However, the need for dual anti-platelet therapy post PFO closure presented a problem as maternal clopidogrel use and concentration in breast milk and effect on the infant is not characterized. In currently published studies, 1 month of clopidogrel therapy was used after PFO closure using an AMPLATZER™ PFO occluder (RESPECT) versus only 3 days after using a GORE® CARDIOFORM septal occluder (REDUCE). The day prior device implant, the FDA approved the use of the GORE® CARDIOFORM septal occluder for cryptogenic stroke, and so chose this device with a strategy to 'pump and dump' breast milk secreted during the time that the patient was on Clopidogrel, in order to minimize the effect of the drug on the baby. Patient resumed breastfeeding after completing the 3-day post-procedural course of Clopidogrel with no reported effects on the baby.

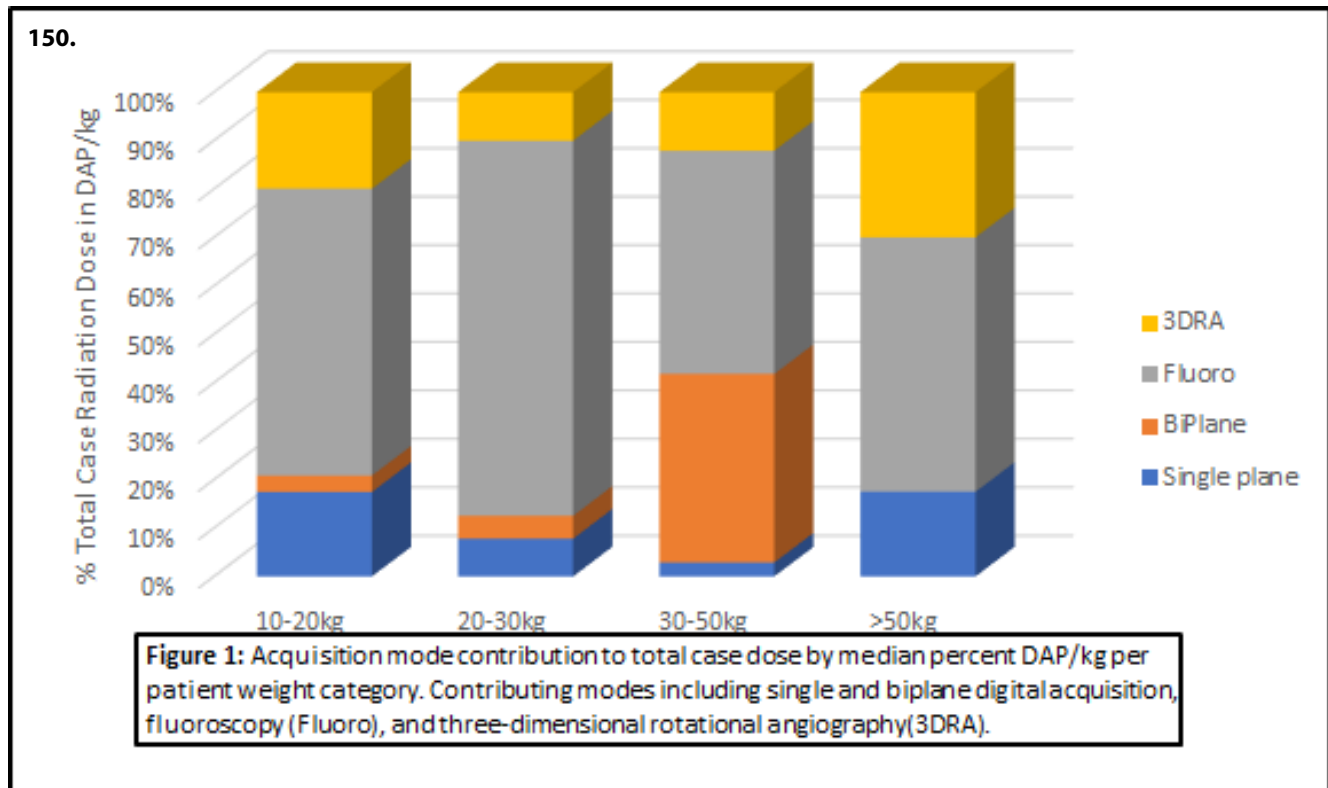
**Conclusion:** PFO closure during lactation presents a challenge due to the insufficiency of data on the effect of Clopidogrel in breast-feeding mothers. This factor may play a role in device selection to minimize exposure to Clopidogrel until more data is available.

#### 150. CONTRIBUTION OF THREE-DIMENSIONAL ROTATIONAL ANGIOGRAPHY TO RADIATION DOSE DURING CONGENITAL CARDIAC CATHETERIZATION

Kurt Bjorkman<sup>1</sup>, Quirina MB de Ruiter<sup>2</sup>, Veronika Shabanova<sup>1</sup>, Martine HG van Alfen<sup>2</sup>, William E Hellenbrand<sup>3</sup>, Jeremy D Asnes<sup>3</sup>

<sup>1</sup>Department of Pediatrics, Yale School of Medicine, New Haven, USA. <sup>2</sup>Philips healthcare, Image guided therapy systems, Best, Netherlands. <sup>3</sup>Division of Pediatric Cardiology, Yale School of Medicine, New Haven, USA

**Background:** The use of three-dimensional rotational angiography (3DRA) during congenital cardiac catheterization is increasing. While radiation dose associated with 3DRA has been studied, its impact on and contribution to overall procedure dose has not been characterized.



**Methods:** A retrospective review (September 2014 – April 2017) was conducted of all catheterizations utilizing 3DRA performed in our congenital cardiac catheterization lab (Philips Allura Xper FD10/10, 3DRA @ 121fr/4.1second acquisition; kVp 115, mA variable). Dose area product (DAP) from 3DRA and single and biplane digital acquisition (DA) runs were recorded. Fluoroscopy associated DAP was calculated: fluoroscopy dose = total procedure DAP – (3DRA + DA DAP). Median DAP per case was estimated with bootstrapped 95% confidence intervals, and showed non-inferiority with benchmarks (C3PO-QI) for similar patient age and case type. When advanced dose reporting was available, the contribution of the 4 acquisition modes employed during catheterization – 3DRA, single plane DA, biplane DA, and fluoroscopy – was analyzed using standard statistical tests.

**Results:** 71 procedures incorporated 3DRA: 48 pulmonary valve implants (TPVI), 12 coarctation interventions (CoA), and 11 pulmonary artery interventions (PA). Median DAP was below the non-inferiority margin for all comparable benchmark values in TPVI and CoA intervention categories, but greater in median analysis for PA interventions in children 1-4yrs (Table 1). 25 cases had advanced dose reports and were analyzed for acquisition mode contributions

(Figure 1). These cases were not significantly different from the larger cohort in terms of procedure or dose by permutation test ( $p=0.11$ ). Median DAP/kg was 74 mGy $\times$ m<sup>2</sup> (95%CI 48-91). Median contributions by mode were: 3DRA 20% (IQR 13%, 32%), single plane DA 17% (IQR 6%, 34%), biplane DA 3% (IQR 0%, 16%), and fluoroscopy 59% (IQR 34%, 80%).

#### Conclusions:

1. 3DRA accounts for a small portion of radiation dose in congenital cardiac catheterization.
2. The radiation dose associated with catheterizations utilizing 3DRA remains at or below benchmarks for most complex cases.

#### 151. PERSISTENCE OF ABNORMAL VERTEBRAL ARTERIAL FLOW AFTER SUCCESSFUL COARCTATION AND SUBCLAVIAN INTERVENTION

C. Huie Lin<sup>1</sup>, Stephanie Fuentes Rojas<sup>1</sup>, Akanksha Thakkar<sup>1</sup>, Eunice Karanja<sup>1</sup>, Danish Bawa<sup>1</sup>, John Volpi<sup>1</sup>, Thomas MacGillivray<sup>1</sup>, John Breinholt<sup>2</sup>

<sup>1</sup>Houston Methodist Hospital, Houston, USA. <sup>2</sup>UT Houston, Houston, USA

**Background:** Coarctation of the aorta accounts for 4-6% of all congenital heart defects and many patients have concomitant cerebrovascular abnormalities. In addition, the coarctation may involve the left subclavian artery or other arch vessels further complicating development of the cerebral vasculature and potentially leading to maladaptive response vascular tone. We present a case of abnormal left vertebral perfusion after successful coarctation and left subclavian arterial intervention.

**Case Presentation:** A 36M presented with bicuspid aortic valve, hypertension, asymmetric blood pressure readings in upper extremities, lightheadedness, and decreased exercise tolerance. His transthoracic (TTE), showed bicuspid aortic valve, normal left ventricular ejection fraction and cardiac CTA showed severe aortic coarctation at the take-off of the left subclavian artery associated with collateral vascularization as well as ascending aortic aneurysm. Preoperative transcranial Doppler (TCD) demonstrated retrograde flow through the left vertebral artery consistent severe subclavian stenosis. He underwent successful treatment of the coarctation using a Max LD 36 stent (Medtronic, MN) deployed on a 16 mm Numed Balloon in Balloon (Hopkinton, NY) catheter. The stent was crossed retrograde from the left radial artery, and the ostium of the left subclavian artery then treated with a 7 mm Sterling balloon with resultant brisk flow. Post intervention angiography showed no or residual stenosis in the aortic arch and there was no gradient from the left subclavian artery to the ascending aorta or across the prior coarct. However, intraop TCD continued to demonstrate retrograde flow through the left vertebral artery.

At routine follow up, patient reports having improved exercise tolerance and normalization of blood pressure, and equal blood pressures in both arms. However, left vertebral flow remained retrograde on TCD at one month post-intervention suggesting that changes in cerebral microvasculature may be fixed despite normalization of hemodynamics.

**Conclusion:** Late intervention of coarctation may be associated with residual cerebrovascular changes as a maladaptive response to chronic malperfusion, especially when the left subclavian artery is involved. Further study is required to determine the contribution of this to risk of stroke in these individuals.

## 152. APPLICATION OF THE CRISP SCORING SYSTEM TO ASSES THE COMPLEXITY OF CATHETERISMS IN AN EMERGING CARDIOVASCULAR PEDIATRIC CENTER

Alberto Zarate Fuentes<sup>1</sup>, Iñaki Navarro Castellanos<sup>1</sup>, Jorge Robles Alarcon<sup>2</sup>, Guadalupe Hernandez<sup>2</sup>, Claudia Orozco Galicia<sup>2</sup>

<sup>1</sup>Issste, Mexico, Mexico. <sup>2</sup>Issste, Mexico, Mexico

**Background:** The CRISP score predicts risk of occurrence of an Severe Adverse Event SAE for individual patients undergoing pediatric cardiac catheterization procedures. The aim of this paper is to determine the frequency of SAE during heart catheterization and show the experience of a recently open Cardiac Center in México, applying the registry based multi-institutional international database of pediatric cardiac catheterization.

**Methods:** We review the clinical charts of those patients undergoing heart catheterization during two years from 1st May 2016 to 2018, in order to determine the frequency of adverse events presented related to the procedure. Every single procedure was scored according to the CRISP scale to provide a risk assessment. SAE were recorded in special chart.

**Results:** During the 2 years period, 100 procedures were performed, by two operators. We had 11 serious adverse events in 100 patients. (Infection, Device embolization, stent occlusion, vascular damage)

According to CRISP score we classified in groups:

- Group 0-3points proportional cases 51%, Adverse events 0%
- Group 4-7 points proportional cases 26%, adverse events 3%
- Group 8-10 points proportional cases 8%, adverse events 3%
- >10 points proportional cases 15% adverse events 5%.

Comparing these results with the CCISC report we noticed that the proportion of patients with >10 points is higher in our center, and the total SAE are relatively low in the highest risk patients.

**Conclusions:** Cardiac catheterization performed in our facility is a safe and effective procedure, with a percentage of SAE according with the standards of care in the international database.

### 153. FIRST EXPERIENCE IN MEXICO OF AN HYBRID STRATEGY FOR NEONATES WITH DUCTAL-DEPENDENT SYSTEMIC CIRCULATION, IT WILL BE THE SOLUTION IN DEVELOPING COUNTRIES?

*Iñaki Navarro-Castellanos<sup>1,2</sup>, Alberto Zárate-Fuentes<sup>1,2</sup>, Carlos Alcántara-Nogues<sup>1,3</sup>, Alejandro Bolio-Cerdan<sup>1,3</sup>, Enrique Pazos-Alvarado<sup>1,3</sup>, Ivan Barrera-Martínez<sup>1</sup>, Jose Luis Salinas-Selaya<sup>1</sup>, Manuel Enrique Soriano-Aguilar<sup>1</sup>*

<sup>1</sup>Hospital Infantil Privado, Cdmx, Mexico. <sup>2</sup>Hospital Regional Lic. Adolfo López Mateos Issste, Cd, Mexico. <sup>3</sup>Hospital Infantil De Mexico Federico Gómez, Instituto Nacional De Salud - Ss, Cdmx, Mexico

In 2016 approximately 960 newborns had HLHS in the USA. Although we have no statistics of this condition in Mexico, we estimate around 355 newborns for the same period.

Although the first successful intervention in USA was in 1983, the actual mortality in Mexico of the classic Norwood is near 100%, and almost all the cardiovascular centers of the country lead to palliative treatment offering no surgery.

**Clinical Case:** we present the case of a 20-day-old patient, who arrived at a private hospital in cardiogenic shock and was stabilized with prostaglandins and diuretics in the NICU, and a HLHS was diagnosed. The cardiovascular team decided to perform a Hybrid approach. As we do not have a hybrid room, the intervention took place in the catheterism laboratory. After sternotomy, a bilateral selective bandage was performed, after which an 8 Fr Sheath was inserted in the main pulmonary artery, and a stent was placed in the arteriosus conduit, a 6Fr sheath was placed in the left atrium through which a catheter balloon was passed to perform an atrio-septoplasty.

The patient was extubated at the second day following the procedure, and discharged home at day 7. The 2<sup>nd</sup> stage is yet to be carried out.

**Conclusion:** In many centers the hybrid approach was initially used only for the high-risk infants. The high-risk factors included weight less than 2.5 kg, preoperative shock, non-cardiac/ genetic abnormality, preoperative mechanical ventilator or circulatory support, small ascending aorta, intact/restrictive interatrial septum, and the variant of HLHS with aortic atresia and mitral stenosis. However Galantowicz and colleagues made a cohort of patients who had a more typical risk profile to the usual HLHS patients, with impressive results: a hospital survival reaching 97.5% after the first hybrid stage. The hybrid approach reduces the early insult limiting pulmonary over-circulation and

securing systemic perfusion, thus resulting in an interesting approach.

This might be an attractive solution for centers with no access to ECMO, no experience with the classic Norwood procedure, or no hybrid room. The hybrid approach might be the premise in most centers in low and middle-income countries.

### 154. AORTIC ATRESIA IN A HIGH-PERFORMANCE ATHLETE USING RADIAL ACCESS IN PAEDIATRIC - CASE REPORT

*Iñaki Navarro-Castellanos<sup>1</sup>, Alberto Zárate-Fuentes<sup>1</sup>, Claudia Orozco-Galicia<sup>1</sup>, Juan Pablo Sandoval-Jones<sup>2</sup>, Guadalupe Hernández-Morales<sup>1</sup>, Jorge Robles-Alarcon<sup>1</sup>*

<sup>1</sup>Hospital Regional Lic. Adolfo López Mateos Issste, Cdmx, Mexico. <sup>2</sup>Instituto Nacional De Cardiología "Ignacio Chavez" Mexico City, Cdmx, Mexico

**Background:** Patients with functional aortic interruption of the descending thoracic aorta at the isthmus due to severe coarctation are extremely rare. This condition is typically solved by surgery.

**Case Presentation:** We describe the case of a high-performance adolescent athlete, asymptomatic but with high risk of sudden death, with an aortic atresia. Using a radial access with a Victory stiff guide due to the impossibility of reaching the ascending aorta through the femoral arteries, a sequential dilation with coronary catheter balloons, and a successful percutaneous reconstruction using a covered stent (CP) were performed.

**Conclusions:** This report remarks the importance of an early diagnosis in congenital cardiopathies and highlights the role of a minimally invasive approach in the management of a severe coarctation of the aorta as well as the utility of using the radial access in pediatric patients to avoid morbidity and mortality associated with more invasive procedures.

### 155. 133 CASES DIAGNOSED AS AORTIC COARCTATION RETROSPECTIVE ANALYSIS AND TREATMENT MODALITIES EVALUATION OF EFFICIENCY, EXPERIENCE OF ERCIYES UNIVERSITY

*Ali Baykan<sup>1</sup>, Emir Gokalp<sup>1</sup>, Aydın Tuncay<sup>2</sup>, Ozge Pamukcu<sup>1</sup>, Suleyman Sunkak<sup>1</sup>, Onur Tasci<sup>1</sup>, Cagdas Vural<sup>1</sup>, Kazim Uzum<sup>1</sup>, Nazmi Narin<sup>1</sup>*

<sup>1</sup>Erciyes University Pediatric Cardiology Clinic, Kayseri, Turkey.

<sup>2</sup>Erciyes University Cardiovascular Surgery, Kayseri, Turkey

**Aim:** Aortic coarctation (AC) is an important cause of childhood morbidity and mortality, which account for segmental narrowing in the aorta. Our aim in this study is to investigate the differences between the treatment modalities of patients who have received, treated and followed up with AC in our clinic, to evaluate their prognosis and to determine the current data which will shed light on the choice of treatment for future patients with AC.

**Methods:** This study included 133 cases (86 males, 47 females) admitted to Erciyes University Faculty of Medicine, Department of Pediatric Cardiology between 1999-2016.

**Results:** When the relationship between treatment options according to the age groups of the patients studied is examined; balloon angioplasty in 80.8% of newborns, surgery in 19.2%, balloon angioplasty in 95% of infants in the term, surgery in 5%, stent angioplasty in 45.6% of patients in 12 months determined. Four patients (28.5%) of the 14 patients who underwent surgery in the first treatment developed recoarctation after  $52.4 \pm 40.8$  months and cured in 10 patients. Of the 98 patients who underwent balloon angioplasty, 56 patients (57.1%) had recoarctation after  $12.6 \pm 17.3$  months and 42 patients were cured. Of the 21 patients who underwent stent angioplasty, 13 (61.0%) had recoarctation after  $25.2 \pm 24.5$  months, and 8 of them were cured. After the first treatment, 60 of the 133 patients were cured, and 73 was the second treatment. After the second treatment, 46 patients were cured and 27 patients were treated third. Fourth and fifth treatments were performed in nine of the 27 patients and in two of the nine patients, no recoarctation was detected after the fifth treatment. It was determined that 71.4% of the patients treated with interventional methods were cured without the need for surgery.

**Conclusions:** There is no clear consensus regarding primary treatment. Although surgical treatment is accepted as the first choice in neonatal period, diagnostic catheterization and palliative angioplasty are preferable options because they will provide partially or completely decompensated patients with elective surgery.

#### 156. CRITICAL PULMONARY VALVE STENOSIS IN A 9 YEAR OLD FEMALE, NEVER IS TOO LATE

Alberto Zarate Fuentes<sup>1</sup>, Iñaki Navarro Castellanos<sup>1</sup>, Claudia Orozco Galicia<sup>2</sup>

<sup>1</sup>Issste, Mexico, Mexico. <sup>2</sup>Issste, Cdmx, Mexico

**Case Report:** We report a case illustrating a 9 year old female with delayed presentation of critical pulmonary valve (PV) stenosis. Clinical evidence of congestive right heart failure: cyanosis and clubbing, enlarged liver, raised jugular venous pressure, and anasarca. Chest X-ray show enlarged right chambers, electrocardiogram showed significant right ventricular hypertrophy. Echocardiography show right ventricular dysfunction, Right ventricular systolic pressure RVSP 215 mmhg assessed by tricuspid insufficiency. Critical pulmonary valve stenosis. Atrial septal defect with right to left shunt.

In the lab we recorded median right atrial pressure: 23 mmhg, Right ventricle 130/23 mmhg, Left ventricle 80/10 mmhg. Initial gradient in the pulmonary valve: 115 mmhg. Extremely sensitive right ventricle. We did an angiography revealing a critical valve stenosis with a high velocity jet of 3 mm, and pulmonary ring of 14mm. We performed a sequential valvuloplasty starting with mini Tyshak 6mmx20mm, and then 9 mmx20mm trying to avoid as much as possible reperfusion pulmonary syndrome.

The final gradient was 28 mmhg, the oximetry raised to 92% immediately after the valvuloplasty, and the patient 24 hrs later improve her clinical status. She was discharge 5 days after procedure, with oximetry 93% room air.

#### 157. IMPLANTATION OF THE OCCLUTECH ATRIAL FLOW REGULATOR: PRELIMINARY RESULTS FROM SWINE MODELS.

Daniel McLennan, Gareth Morgan

Children's Hospital Colorado, Aurora, USA

**Objective:** Histopathological assessment of the Atrial Flow Regulator (AFR) (Occlutech) 1 month after implantation to assess the degree of endothelialization and the atrial communication size in relation to the initial communication diameter in a swine model.

**Background:** Pulmonary arterial hypertension (PAH) and left ventricular diastolic failure are diseases in which high diastolic pressure in either atrium can lead to poor cardiac output and atrial distension. The concept of reducing right and left atrial hypertension in these diseases has been the subject of much debate. One of many controversies has revolved around the technical ability to produce a reliable and predictably sized hole between the atrial chambers;

**Methods:** Five adolescent domestic pigs had transeptal punctures performed by standard technique using an SL-1 sheath via the femoral vein and a BRK 1 extra sharp needle

under general anaesthesia. The procedure was guided by an 8Fr Siemens Accuson ICE catheter. AFRs were then deployed by a technique similar to that for deploying the Occlutech Figulla Flex II ASD occluder. The pigs had follow up echocardiography at 3 weeks to assess flow and were euthanized at 28 +/- 1 days. Radiographs of the hearts were taken to assess device position. Gross examination was then performed. Plastic histology was undertaken in Spurr's resin. light microscopy histology and electron microscopy were then performed.

**Results:** At 28 days neointimal overgrowth was mild to moderate, partially covering both surfaces of the AFR in three out of four animals. The lumen of the device remained completely patent in three animals. Of the other two animals one had partial lumen overgrowth, remaining lumen was 4-5mm. The other animal showed closure of the AFR orifice. This was the only device that showed right and left atrial surface of the device to be completely covered by neointimal tissue.

**Conclusions:** The Occlutech AFR is a safe device to implant, with the technique similar to the implantation of an ASD device. This device should allow the creation of an atrial communication of set size, allowing better and safer treatment options for patients with PAH or Left ventricular diastolic failure

### 158. RETROGRADE DEVICE CLOSURE OF CLINICALLY RELEVANT PERIMEMBRANOUS VSD'S IN SMALL INFANTS VIA CAROTID CUTDOWN

*Damien Kenny<sup>1</sup>, Jonathan McGuinness<sup>1</sup>, McCrossan Brian<sup>2</sup>, Oslizlok Paul<sup>1</sup>, Colin McMahon<sup>1</sup>, Franklin Orla<sup>1</sup>, Terence Prendiville<sup>1</sup>, David Coleman<sup>1</sup>, Lars Nolke<sup>1</sup>, Mark Redmond<sup>1</sup>, Kevin Walsh<sup>1</sup>*

<sup>1</sup>Our Lady's Children's Hospital, Dublin, Ireland. <sup>2</sup>Royal Belfast Hospital for Sick Children, Belfast, Ireland

**Background:** Despite resurgence in percutaneous closure of perimembranous ventricular septal defects (PMVSD) in older children, clinically relevant PMVSD's in small infants remain a surgically treated defect. We describe a novel approach to retrograde device closure of clinically relevant PMVSD's in small infants via carotid cutdown.

**Methods:** Prospective data collection of all infants undergoing attempted transcatheter PMVSD closure using the approach described above in a single center. Data are expressed as median with ranges.

**Results:** Twelve infants with median weight 6.6kgs (range 5.0-9.5kgs) and clinically relevant PMVSD underwent attempted retrograde closure via carotid cutdown. Device delivery was successful in 9 patients. Median right ventricular:aortic systolic pressure ratio was 72% (range 40-100%). Median defect size was 8.6 mm (range 5-10mm) and median device size was 8mm (range 5-10mm). In one patient, the deployed device impinged on the tricuspid valve and was removed. In another with no aortic rim, it was not possible to achieve stable device position without impinging on the aortic valve. In the final patient, with a multifenestrated defect, attempted retrograde crossing lead to distortion of the tricuspid valve and decision to revert to open surgery.

All nine patients receiving a device recovered well with median hospital stay 1 day (range 1-3 days). There were no complications related to carotid cutdown. Complete closure is present in 8 patients with mild residual leak in the remaining patient at a median follow-up of 10 months (range 1-18 months). There has been no heart block noted on follow-up.

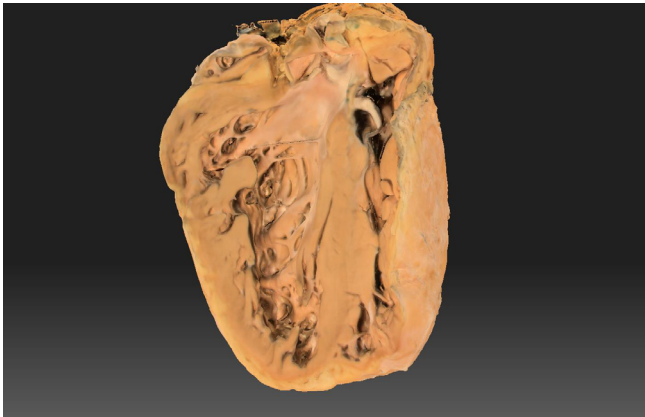
**Conclusions:** Retrograde device closure of hemodynamically significant PMVSD's is feasible and effective in small infants. Defect characteristics on transesophageal echocardiography, in particular aortic and tricuspid tissue rims, are key to successful patient selection.

### 159. 3D SCANNING AND PRINTING ENHANCES SURGICAL AND TRANSCATHETER PLANNING IN CONGENITAL HEART DISEASE

*Danish Vaiyani MD<sup>1,2</sup>, R. Allen Ligon MD<sup>1,2</sup>, Christopher Petit MD<sup>2,1</sup>*

<sup>1</sup>Children's Healthcare of Atlanta, Atlanta, USA. <sup>2</sup>Emory University, Atlanta, USA

Patients with congenital heart disease (CHD) require individualized treatment before and after surgical repair and palliation. Traditionally, procedural planning has relied on 2-dimensional modalities such as echocardiography, angiography, computed tomography (CT) and magnetic resonance imaging (MRI) which require re-creation of 3-dimensional constructs from 'stacks' of 2-dimensional images. 3D models can aid in determination of the optimal approach or type of cardiac intervention, be it surgical or transcatheter. 3D models are limited by the resolution inherent to the parent imaging modality. The quality of 3D models, then hinges on the resolution of ultrasound, MRI or CT source images.



**159. Figure 1.** Gross Pathological Specimen of Dilated Cardiomyopathy.



**159. Figure 2.** Melody Transcatheter Pulmonary Valve (Medtronic Corporation).

3D scanning (3DS) is a novel application where the resolution of imaging is limited only by graphical and processor capability. 3DS has potential to delineate, with previously unforeseen detail, highly complex anatomic structures. We review cases using pathologic specimens where use of 3DS enabled virtual 3D reconstruction with resolutions exceeding current clinically-available CT or MRI images. 3DS in the future can be used to scan pathological specimens to better understand the morphology and anatomy of congenital heart defects. Moreover, individual devices, pathological specimens, and animal specimens both with and without devices implanted can be scanned with the aim of designing novel devices for minimally invasive catheter-based interventions. Finally, not only can 3D printed models derived from imaging studies be scanned and assessed for accuracy, but different imaging modalities can be compared to see which produces the most accurate models. These 3D models and scans also have the secondary benefit of educating cardiology and surgical fellows.

In conclusion, 3D scanning and printing is a valuable supplement to traditional methods of procedural planning and has the capacity to offer novel treatments to patients.

**160. THE FIRST CASE OF SUCCESSFUL EMBOLIZATION BY A VASCULAR PLUG FOR A PARAVALVAR LEAK AFTER TRICUSPID VALVE REPLACEMENT IN A PATIENT AFTER EXTRACARDIAC FONTAN OPERATION FOR HYPOPLASTIC LEFT HEART SYNDROME**

*Satoshi Yasukochi, Hidehiko Hara, Kiyohiro Takigiku, Kouta Takei, Takeshi Hashimoto, Masaru Okamura*

Nagano Children's Hospital, Nagano, Japan

Paravalvar leak (PVL) is a possible complication after prosthetic valve implantation in adult which may cause significant symptoms of congestive heart failure (CHF) and hemolysis, but very rare in child.

We report here a 14-year-old boy as the first successful case of percutaneous closure of PVL in tricuspid prosthetic valve by a vascular plug, 11 years after extracardiac Fontan procedure (eTCPC) for hypoplastic left heart syndrome (HLHS).

He had been suffering from CHF with chest pain due to PVL after TVR (ATS  $\Phi$ 24mm), which underwent at 13 years old for severe progressive tricuspid regurgitation (TR) after eTCPC, whose postoperative course had a poor recovery. Transesophageal echocardiography (TEE) demonstrated a paravalvar defect in 3-5mm size along at 1-2 o'clock position of prosthetic TV and severe regurgitation. Hemodynamic measurements by catheterization showed elevated mean pulmonary wedge pressure (PAWP) as 12mmHg and ejection fraction of right ventricle (RV) was 32%.

Under general anesthesia, 4F customized catheter via left femoral artery was inserted retrogradely through RV into left atrium (LA) with 0.035" Terumo guide wire (GW). With TEE guide, a guide catheter in LA was changed to 5F Destination catheter with Safari GW, then Safari GW was exchanged by 0.014" Cruise GW as a leading GW.

The PLV was successfully closed by AVP-II ( $\Phi$ =10mm), after failing the first attempt by AVP-II ( $\Phi$ 8mm) which resulted in migration and retrieved. After closing PVL, mean LA pressure was down to 8mmHg.

Percutaneous closure of PVL by a vascular plug is a powerful alternative treatment of surgery even in a child with multiple surgery for complex heart disease like our case who limited the vascular access.



### 161. PRECLINICAL EVALUATION OF A NOVEL ZINC BIORESORBABLE STENT FOR USE IN CONGENITAL HEART DISEASE

*EC Kish, A Glavan, KM O'Neill, J Li, G Tensol, HG Bezerra, HG Moran, ML Bocks*

UH Hospitals, Cleveland, USA

**Background:** Infants and children with vascular stenoses associated with congenital heart disease are often treated with bare metal stents typically approved for coronary or peripheral artery disease in adults. These stents often cannot be dilated much beyond their implantation diameters, which can result in impaired growth of the vessel relative to somatic growth. Bioresorbable stents offer the potential for treatment in infancy without the concern for vessel growth restriction as vascular enlargement can proceed once the stent material resorbs. We report the results of bench and in vivo preclinical testing of our novel zinc bioresorbable stent (ZBS).

**Methods:** Various lengths and diameters of the ZBS were evaluated for radial hoop strength, recoil, and foreshortening by a certified laboratory following ASTM standards. Twenty-two 10mm ZBS mounted on 6mm balloons (NuMed Inc.) were implanted in 11 mini Yucatan swine and were followed out 30 days (n=3), 90 days (n=4), 150 days (n=2), and 180 days (n=2). Comprehensive evaluations with angiography, optical coherence tomography (OCT), micro CT, and histopathology were performed on all animals to assess for stent patency, neointimal hyperplasia (NIH), thrombus formation, apposition, and stent integrity.

**Results:** The 6 mm ZBS had higher radial force compared to the Cook Formula 418 stent and the Cordis Palmaz Blue stent. The 10 mm ZBS had slightly lower radial strength compared to the IntraStent double-strut LD stent. Angiography and OCT revealed minimal NIH, no restriction to vessel growth, no vascular injury, no thrombus, and near perfect wall apposition out to 180 days. Stent fractures related to tendency of the material become brittle over time with degradation were observed, but did not compromise stent integrity.

**Conclusion:** Early bench and in vivo testing demonstrates that the ZBS possess baseline radial strength similar to stents widely used in pediatric interventional cardiology. In vivo performance was very encouraging with excellent wall apposition and endothelialization, complete patency, no migration, no dissection, minimal NIH, no thrombus, and modest inflammatory response. Further work to optimize alloy content to make material less prone to fracture

is ongoing as this will ensure maintenance of radial force for the desired period of time.

### 162. AORTIC DISEASES TREATED WITH "PEDIATRIC DEVICES"

*Bogdan Cherpak, Nataliia Yashchuk, Igor Ditkivskyy, Bodan Batsak, Vasyl Lazoryshynets*

Amosov National Institute of Cardiovascular Surgery, Kiev, Ukraine

**Background:** The gold standard for aortic disease management remain surgery or endovascular aortic stent-grafting. But sometimes "pediatric" percutaneous devices may play a role when surgery is too risky and stent-grafts do not fit due to the variability of aortic anatomy. We present six cases of aortic disease management with pediatric devices.

**Cases presentation:** In our small group three patients presented with huge ascending aortic pseudoaneurysms at the needle or cannulation site following valve surgery. The first one was successfully treated percutaneously with 12 mm Figula Flex II ASD device. In second case, ascending aortic pseudoaneurysm was managed with 10 mm AGA pmVSD asymmetric device. After intervention this patient had tiny leak at the site of asymmetric disk. Six month following intervention routine ECHO examination showed that aneurysmal sack did not collapse. The leak was treated with 5 mm Co-Med ASD device with complete sack thrombosis according to the ECHO data. The third patient was managed with 16 mm PushMed ASD device. Angiography showed new entry site to the pseudoaneurysm and aneurysmal sack to right atrium shunt also appeared. The patient was regarded to have infective endocarditis due to fragile aortic wall and anamnesis of high fever and converted to surgery at the same day.

One patient had coarctation repaired by Andrastent with simultaneous closure of collateral network aneurysm. The feeding vessel was occluded with the couple of Cook coils and then entry site of the aneurysm was occluded with SHSMA pmVSD asymmetric device.

One man had Bental de Bono procedure more than ten years ago with the graft wrapping with the native tissue, distal suture line incompetence and surgically created fistula from false lumen (native tissue sack) to the right atrium. The entry site to the sack was managed with 12-14 mm LifeTech PDA occluder then fistula to the right atrium was closed with 10 mm MemoPart PDA device.

The last patient was unlucky to have no false lumen thrombosis and collapse following supracoronary aortic replacement, elephant trunk and TEVAR procedures. The proximal to the stent-graft fenestration was closed with 6 mm AGA ASD device. Six month after CT confirmed complete false lumen thrombosis and collapse in the thoracic aorta.

**Conclusion:** Pediatric devices are good solution in some patients with aortic diseases.

### 165. MULTICENTER TRIAL OF CONGENITAL PULMONIC VALVE DYSFUNCTION STUDYING THE SAPIEN 3 INTERVENTIONAL THV WITH THE ALTERRA ADAPTIVE PRESTENT-RESULTS OF THE U.S. EARLY FEASIBILITY STUDY

Shabana Shahanavaz MBBS<sup>1</sup>; David Balzer MD<sup>1</sup>; Vasilis Babaliaros MD<sup>2</sup>; Dennis Kim MD PHD<sup>2</sup>; Vivian Dimas MD<sup>4</sup>; Suredranath R; Veeram Reddy<sup>4</sup>; Evan Zahn MD<sup>5</sup>

<sup>1</sup>Division of Cardiology, Department of Pediatrics, Washington University in St. Louis School of Medicine, St. Louis, MO;

<sup>2</sup>Structural Heart Disease Center, Division of Cardiology, Emory University School of Medicine, Atlanta, GA; <sup>3</sup>Division of Pediatric Cardiology, Department of Pediatrics, Children's Healthcare of Atlanta, Emory University, Atlanta, GA; <sup>4</sup>Division of Cardiology, Department of Pediatrics, University of Texas Southwestern Medical Center, Children's Health System of Texas, Dallas, TX ;

<sup>5</sup>The Smidt Heart Institute and the Department of Pediatrics, Cedars-Sinai Medical Center, Los Angeles, California

**Disclosures:** Dr. Shahanavaz and Dr Zahn are consultants for Medtronic Inc. (Minneapolis, MN) and proctors for Edwards Life Sciences LLC. (Irvine, CA). Dr. Balzer is a consultant and proctor for Medtronic Inc.

Dr Babaliaros, Dr Kim, Dr Dimas and Dr Reddy do not have any disclosures.

**Objectives:** This study sought to demonstrate the safety and effectiveness of the Edwards Alterra Adaptive Prestent in conjunction with the

Edwards SAPIEN 3 Transcatheter Heart Valve (THV) System in patients with a dysfunctional right ventricular outflow

tract/pulmonary valve (RVOT/PV) who have an indication for treatment for severe pulmonary regurgitation (PR).

**Background:** Based upon the large size and irregular topography, many patients with dysfunctional right ventricular outflow tracts (RVOT) are currently not candidates for percutaneous balloon-expandable valves. The Alterra Prestent is a unique self-expanding device designed to

internally reduce and reconfigure the RVOT and provide a stable landing zone for percutaneous implantation of a 29 mm SAPIEN 3 THV.

**Methods:** Four U.S. sites participated in an FDA-approved early feasibility study (EFS). Potentially eligible patients underwent extensive non-invasive work-up and review by a screening committee to determine implant eligibility. Inclusion criteria included moderate/severe pulmonary regurgitation and RVOT dimensions > 27 and < 38 mm in diameter and > 35 mm in length. A total of 15 patients were enrolled in the EFS. Pre-procedural characteristics are reported for the first 6 patients.

**Results:** Between February 2018 and May 2018, 6 patients were implanted with the Alterra Prestent and Edwards

**165. Table 1.** Demographics and Baseline Characteristics All treated Population (N=6)

Variable	Summary Statistics
<b>NYHA Class</b>	
Class I/II	5
Class III/IV	1
<b>Original CHD Diagnosis</b>	
Atrial septal defect	1
Coarctation of the Aorta	1
Pulmonary valve stenosis	2
Tetralogy of Fallot	3
Ventricular septal defect	3
Other	3
Total Number of previous Surgical Cardiothoracic Interventions	1
Total Number of previous Percutaneous Cardiothoracic Interventions	1
<b>Total Pulmonary Regurgitation</b>	
None/Trace	0
Mild	0
Moderate	0
Severe	6
Mean RVOT Gradient	7.8 ± 4.32

Note: Categorical measures – Count; Continuous measures – Median (Range) or Mean ± Std. Dev.

Sapien 3 THV. Diagnoses included tetralogy of Fallot (n=3) or valvar pulmonary stenosis (n=3). All patients had severe pulmonary regurgitation (100%), and no or trivial stenosis. Median age was 30.5 years, median weight 69.5 kg, and median height 167 cm. Most patients were only mildly symptomatic with NYHA class I/II (5) symptoms. All six patients were successfully implanted with both the Alterra pre-stent and SAPIEN 3 THV during a single procedure. Primary and secondary endpoints will be available at the time of the presentation.

**Conclusions:** The Alterra Adaptive Pre-stent potentially expands the number of patients with dysfunctional RVOTs who are candidates for transcatheter pulmonary valve replacement.

### 167. NOVEL TECHNIQUE FOR CORRECTION OF SEVERE LEFT PULMONARY ARTERY STENOSIS USING A GORE® VIABAHN® VBX BALLOON EXPANDABLE ENDOPROSTHESIS

*Bawa, D., Thakkar, A., Rojas, S.F., Karanja, E., Monteiro, G., Breinholt, J., MacGillivray, T., Lumsden, A.L., & Lin, C.H..*

**Background:** Pulmonary artery stenosis not infrequently complicates congenital heart disease. Availability of covered stents for high risk dilations has been limited in the US to the covered Cheatham Platinum stent. We describe the first use of the GORE® VIABAHN® VBX balloon expandable covered stent in pulmonary arterial intervention in a 46F with severe left pulmonary artery (LPA) stenosis.

**Case:** A 46F with a history of childhood VSD s/p patch repair, RVOT stenosis s/p trans-annular patch and LPA stenosis s/p re-implantation of LPA at age 5 presented with heart failure. Transthoracic echocardiography (TTE) showed LVEF 25-29%, severe hypertensive RV with enlargement and severely depressed function, mod-severe pulmonary regurgitation. CTA revealed severe stenosis at LPA ostium. Catheterization demonstrated severe RV hypertension 93/19 mm Hg, RPA 88/17/40 mm Hg, distal LPA 18/12/15 mm Hg, LV 90/14 mm Hg, PVR 9 WU. Angiography demonstrated an atretic LPA ostium but a main vessel of 13mm diameter. Quantitative lung perfusion scan demonstrated 89% blood flow to right and 11% to left lung. Intervention on LPA stenosis to reduce RV pressure was planned, however, given the chronic severe RV hypertension and concern for disrupting the atretic ostium of the LPA, we planned to use a covered stent. As such, we chose a 9 mm x 29 mm GORE® VIABAHN® VBX Balloon Expandable Endoprosthesis (Flagstaff, AZ) and deployed this at nominal through an 8Fr Cook Checkflow Performer braided sheath at the lesion.

To optimize apposition, we then successfully post-dilated the stent using a 12 mmx40 mm Armada® balloon (Abbott Vascular). Post intervention hemodynamics demonstrated a reduction of RV pressure to half systemic and no residual gradient to LPA. TTE 1 week after procedure showed improved RV size and function.

**Conclusion:** We report the first use of the GORE® VIABAHN® VBX Balloon Expandable Endoprosthesis in pulmonary arterial intervention. The advantages of this device include the ability to deliver through an 8Fr system, ability to post-dilate up to 16mm, and balloon-expandable covered stent platform with excellent radial strength. These qualities may be ideal in pediatric and congenital heart interventions. However, long term outcomes with the use of this device in congenital heart interventions will require study.

### 168. DIFFERENCES AMONG EASTERN AND WESTERN REGIONS IN THE PATTERNS OF INTERVENTIONS IN PAEDIATRIC CARDIOLOGY-A REGIONAL COMPARISON

*Amjad Mehmood, M.D. Professor of Paediatric Cardiology Armed Forces Institute of Cardiology & National Institute of Heart Diseases Rawalpindi, Pakistan.*

**Objective:** This study was aimed to analyse the factors responsible for the variations in the patterns of paediatric cardiac interventions in Eastern and western regions of the world. This type of study is not carried before.

**Background:** Paediatric cardiac interventions are done globally in various centers of the world. The variety of cases and hardware is enormous to treat these cases in cath lab. There are multiple factors responsible for the variation in types of procedures and types of devices used. The major differences are Economics, Population, Literacy Level, Number of paediatric cardiac centers, Social Taboos, Training programmes, Types of manufacturing equipment, Structured sophisticated schedules, Accountability, Government priority for Paediatric cardiology, Allocation of budgets for Paediatric cardiac services, Public awareness. In this study all these factors are looked in to detail and short coming are highlighted with practical and feasible recommendations.

**Methods:** In this study Asian areas like Pakistan, India, China, Japan, Thailand, Vietnam are compared with European and American regions. Statistical data from all these regions are collected and analysed in detail. Major centers in all these countries are selected for comparison.

Major consultants from all these centers are invited for their feedback on the subject and their experiences are compared. Total 50 world renowned centers are selected to analyse with consent of respective directors of the cath labs.

**Conclusion:** Asian paediatric cardiac centers are far more different in types of interventional procedures from European and American places. Industry has a lot of role to play in the differences. Economics and Educational strategies are the major differentiating features. Work load due to population is the limiting factor for the difference.

### 169. 1-YEAR OUTCOMES FROM THE GORE® CARDIOFORM ASD OCCLUDER (GORE ASSURED) CLINICAL STUDY

*Matthew Gillespie<sup>1</sup>, Robert Sommer<sup>2</sup> on behalf of Gore ASSURED Trial Investigators*

Children's Hospital of Philadelphia<sup>1</sup>, Philadelphia; NY Presbyterian, Columbia University School of Medicine<sup>2</sup>, New York, USA

**Background:** The GORE® CARDIOFORM ASD Occluder is a permanently implanted occluder being tested for the indication of percutaneous, transcatheter closure of ostium secundum atrial septal defects (ASDs). The occluder system consists of an implantable occluder and a delivery system. The occluder is comprised of a platinum-filled nickel-titanium (Nitinol) wire frame covered with expanded polytetrafluoroethylene (ePTFE). The occluder configurations are capable of treating defects between 8-35 mm. When fully deployed, the occluder assumes a configuration complete with a left atrial disc, a right atrial disc, and an intra-disc region between these discs that is intended to occupy the defect.

**Methods:** Patients were enrolled from 22 Pivotal U.S. sites in a prospective single arm trial. Follow-up was immediately post procedure and at scheduled intervals through 6 months. Endpoints included successful device placement, immediate and late closure success and serious adverse events, including serious device-related events requiring intervention.

**Results:** Pivotal enrollment began March 10, 2017 and completed on September 5, 2017. Twenty-two (22) sites were initiated during the Pivotal phase. The study was comprised of 125 Pivotal subjects and 43 training cases. The first two patients at each site were considered training cases. All subjects are being followed per the study protocol. The median patient age was 14.3 years [5.5- 84.7]. The

mean "stop flow" stretched diameter was 18mm [9-34]. Multiple fenestrations were seen in 18.3% (19/104), and atrial septal aneurysm in 6.7% (7/104) of patients. The median retroaortic rim length was 5 mm [0.1-39].

A mid-term safety and efficacy analysis of 30-day data on the first 104 patients (67 Pivotal subjects and 37 training case patients) was performed in September 2017. Technical Success rate was 93.3% (97/104) overall (94% (63/67) for the Pivotal cohort); Procedure success rate (Technical and Closure success): 93.3% overall (94% for the Pivotal cohort). No residual defects were noted at 30 days. Serious AEs occurred in 7.7% overall (6.0% for the Pivotal cohort). No subject deaths have been reported.

**Conclusion:** Initial results from this prospective trial of the new Gore Cardioform Atrial Septal Occluder revealed high procedural success, and favorable 30-day outcomes. ***1-year follow up data, including echo and fluoroscopic assessment, will be available for presentation at the time of the PICS meeting (September 2018).*** This G-CASO is a promising new technology for ASD closure.

### 170. EARLY RESULTS OF THE CLINICAL TRIAL USING THE BEIJING MED-ZENITH PULMONARY ARTERY STENT FOR PULMONARY ARTERY STENOSIS

*John P Cheatham<sup>1</sup>, Gao Wei<sup>2</sup>, Zhouqing Liang<sup>3</sup>, Meng Jian<sup>3</sup>*

<sup>1</sup>Nationwide Children's Hospital, Columbus, OH, USA, <sup>2</sup>Shanghai Children's Medical Center, Pudong, Shanghai, China, <sup>3</sup>Beijing Med-Zenith Medical Scientific Co, Beijing, China

**Background:** Stent therapy for post operative pulmonary artery stenosis (PAS) is one of the most challenging interventional procedures in complex congenital heart disease (CHD). Balloon angioplasty (BA) has been performed since 1983, but has the disadvantage of elastic recoil and limited acute and long term efficacy. Balloon expandable stents (BES) were introduced for PAS in 1988 with better results, but the stents were not specifically designed for PAS and had limited applications. These BES were composed of 316L stainless steel and a closed cell (CC) design. Later, open cell (OC) stents were used in PAS with some advantages over CC stents.

Therefore, we designed a PAS stent (PASS) composed of cobalt chromium with a "hybrid" design, combining the advantages of both CC and OC. The recommended expanded diameters are: (S) 6-12mm, (M) 12-16mm, and (L) 18-22mm, and there are variable lengths from 15-40mm in increments of 5mm., and shortening of 0- 15%.

**Results:** 70 patients were enrolled in 6 cities in China: 27 females, 43 males; 1.5-33.8 years; 9.2-79Kg. 73 PASS were implanted in the 70 patients: 44 in LPA, 29 in RPA with percutaneous delivery in 64 pts and Hybrid in 6 pts. ~ 98% pts received a S or M PASS, with only 2% requiring L. Pre-implant mean gradient 41.5mmHg was reduced to 12.1mmHg post implant, while the mean vessel diameter increased from 4 to 9.5mm. There were no deaths and no significant morbidities.

**Conclusions:**

1. The specifically designed PASS was delivered safely and effectively.
2. The Hybrid design and cobalt chromium composition are unique for the transcatheter therapy of PAS.
3. Longer follow up will be important to evaluate the efficacy with patient and vessel growth.

**171. COMPARISON OF INTRACARDIAC ECHOCARDIOGRAPHY AND TRANS-CRANIAL DOPPLER ULTRASOUND IN DETECTING CARDIAC RIGHT TO LEFT SHUNT**

*Mohammed Numan*

Driscoll Children's Hospital, Corpus Christi, Texas

**Background and Objectives:** Right to left shunts (RLS) found with patent foramen ovale (PFO) are implicated in the pathophysiology of cryptogenic stroke, migraine headaches as well as decompression illness. RLS are typically diagnosed using intravenous agitated saline injections with transthoracic (TTE), transesophageal (TEE) and/or Intracardiac (ICE) echocardiography. Transcranial Doppler (TCD) is another method for detecting RLS that is not dependent on topographic imaging. Intracardiac echocardiography (ICE) provides a superior image of the cardiac septum. There is scarce data in the literature about comparing TCD and ICE in detecting right to left shunt across PFO and or ASD in children and adolescents.

**Methods:** We performed a retrospective analysis of a prospectively obtained registry of patients that underwent simultaneous TCD and ICE shunt testing  $\pm$  endovascular PFO/ASD closure. All patients had previously undergone a transthoracic echocardiogram bubble study (TTE) to confirm a RLS and then underwent general anesthesia and bilateral TCD monitoring of the middle cerebral artery. Valsalva was manually produced by the anesthesiologist at 40 mmHg. Simultaneous assessment of RLS was performed using ICE/TEE and TCD monitoring after injection of agitated saline into the femoral vein sheath. If negative, a direct right atrial injection was performed.

**Results:** Between 9/2010 and 7/2012, 112 patients underwent testing. Mean age 16 years (range 8 to 24 years). RLS was found in 82.1, 81.1 and 71.4 percent by TTE,ICE/TEE and TCD, respectively. After peripheral femoral vein injection (n=85), when compared to ICE, TCD had a sensitivity, specificity, PPV, NPV and accuracy of 95,100, 100, 64 and 95%, respectively. Combined peripheral and Intracardiac injections (n=112) when compared to ICE, TCD, and a sensitivity, specificity, PPV, NPV and accuracy of 88,100, 100, 66 and 90%, respectively. Curtain (Spencer Grade V) TCD shunts had larger physical ASDs compared to non-curtain (Spencer grade  $\leq$  IV) ( $2.8\text{mm} \pm 1.7$  vs  $1.7\text{mm} \pm 0.9$ ,  $p=0.004$ ). Additional cardiac abnormalities had larger PFO/ASD sizes compared to those without ( $3.5\text{mm} \pm 1.7$  vs  $1.9 \pm 1.3$ ,  $p=0.0001$ ).

**Comment on this Article or Ask a Question**

**Cite this article as:** Hijazi ZM. The Pediatric and Adult Interventional Cardiac Symposium (PICS/AICS) 21st Annual Meeting, Las Vegas, Nevada. Structural Heart Disease. 2018;4(4):114-206. DOI: <https://doi.org/10.12945/j.shd.2018.020.18>