

Successful Mitral Clipping Procedure for Severe Mitral Regurgitation Following Ring Mitral Annuloplasty

Fayez Bokhari, MD, Mirvat Alasnag, MD*, Ashraf M. Anwar, MD, PhD

Division of Cardiology, King Fahd Armed Forces Hospital, Jeddah, Kingdom of Saudi Arabia

Abstract

Percutaneous mitral valve repair has become an alternative to surgical MV repair in high-risk patients. It is primarily indicated in severe functional or degenerative MV regurgitation. The MitraClip system is a catheter-based device that places a stitch at the edge of the anterior and posterior mitral leaflets. Here, we describe a case of recurrent pulmonary edema secondary to severe MV regurgitation after treatment with an annuloplasty ring who was treated successfully using the MitraClip system.

Copyright © 2019 Science International Corp.

Key Words

Mitral Clip • Mitral Annuloplasty • High Risk

Introduction

Percutaneous mitral valve (MV) repair using the MitraClip (Abbott Laboratories) has become an alternative to surgical MV repair in patients who are high-risk for surgery. The primary indication for this system is in severe functional or degenerative MV regurgitation. This system is catheter-based placing a stitch at the edge of the anterior and posterior mitral leaflets (usually the P2 scallop). Published studies, such as the EVEREST II Trial, and case reports have largely focused on those two categories of pathologies [1]. The utility of this percutaneous system has expanded recently

as other pathologies have been identified. Individuals who had undergone previous surgical repair is one such condition. Reports of recurrent MV regurgitation following surgical valvuloplasty range from 8-13% in published trials [2]. To date, only isolated case reports or small case series have been published [3, 4]. No randomized data of the use of MitraClip in patients who develop severe MV regurgitation after surgical repair (annuloplasty) have been conducted. Here, we describe a case of a patient who suffered from recurrent pulmonary edema secondary to severe MV regurgitation after treatment with a ring annuloplasty.

Case Presentation

A 59 year-old female underwent mitral and tricuspid valve surgical repair in 2002 for rheumatic valve disease, severe mitral regurgitation/mild mitral stenosis and severe tricuspid regurgitation. Her co-morbidities include obesity, bilateral knee osteoarthritis significantly limiting mobility, poorly controlled Diabetes Mellitus Type II, hyperlipidemia, paroxysmal atrial fibrillation (on oral anticoagulation and rate control) and mild renal dysfunction. She did well for over 15 years. This last year she was admitted four times with recurrent pulmonary edema. She denied any chest pain or palpitations. A transthoracic echocardiogram revealed a severely impaired left ventricular systolic function, EF 20%, mitral annuloplasty



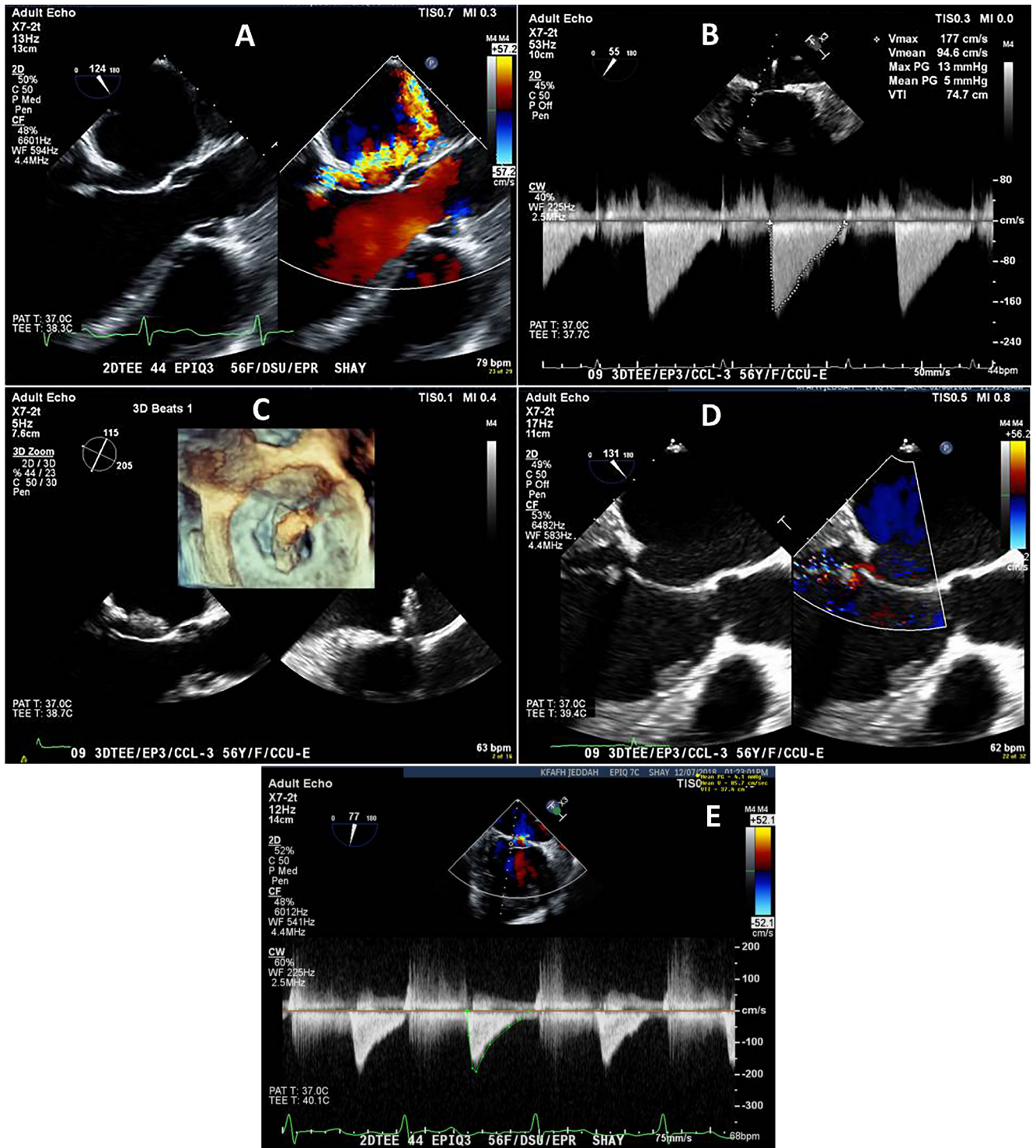


Figure 1. Panel A. 4-chamber Transesophageal Echocardiographic Image with color Doppler showing eccentric direction of severe mitral regurgitation. Panel B. Continuous wave-Doppler of mitral inflow showed pressure gradient across the valve before procedure. Panel C. Enface visualization of mitral clip by 3D transesophageal echocardiography to check perpendicularity before implantation. Panel D. 4- chamber Transesophageal Echocardiographic Image with color Doppler immediately post-procedure. Panel E. Continuous wave-Doppler of mitral inflow showed pressure gradient across the valve post procedure.

with a complete ring and an annulus of 2.7 cm, severe residual MV regurgitation that is anteriorly directed and mean gradient of 3 mmHg, tricuspid annuloplasty with severe residual regurgitation and mean gradient 1 mmHg, and severe pulmonary hypertension, systolic pulmonary artery pressure 65 mmHg. Further evaluation by transesophageal echocardiography (TEE) to assess severity and direction of MV regurgitation (Figure 1-A), to measure the anterior and posterior mitral leaflet lengths which were 2.4 cm and 0.8 cm respectively and to assess pressure gradient across the MV (Figure 1-B). A coronary angiogram ruled out any significant coronary artery disease. She was placed on intensive medical therapy that included Bisoprolol 10mg daily, furosemide 40 mg twice daily, spironolactone 25 mg daily, metolazone 2.5 mg twice a week, valsartan 80 mg daily, atorvastatin 40 mg daily, apixaban 5 mg twice daily. In spite of medical therapy, she continued to suffer from dyspnea class III requiring admission and intravenous diuresis. Her options were discussed at the multidisciplinary team meeting. She was deemed too high risk for a redo surgery. An off-label use of the MitraClip System was also discussed and offered to the patient.

Procedure

The procedure was performed under general anesthesia administered by a cardiac anesthetist and using fluoroscopic and transesophageal echocardiographic guidance. Both arterial and venous accesses were obtained in the common femoral vein and artery. Through the venous sheath, the trans-septal puncture was achieved superiorly (3.6 cm distance from the puncture site to the mitral valve annulus) and posteriorly with TEE assistance. Heparin was administered and a therapeutic ACT (> 300) was maintained throughout the procedure. The delivery sheath was advanced into the left atrium over a 0.035 inch stiff Amplatz wire. With delicate maneuvering the MitraClip was positioned and perpendicularity was confirmed guided by 3-dimensional transesophageal echocardiography (Figure 1-C). The clip was initially advanced more posteriorly with marked medial deflection (the knob was angled to 90 degrees medially). After diving into the left ventricle in closed position to a level just below the ring, the clip was opened.

Perpendicularity and alignment were confirmed just below the level of the leaflets using both fluoroscopic visualization of the ring and TEE imaging. More medial and anterior dialing was necessary for appropriate positioning of the clip. Upon pulling back up, both leaflets were grasped. Grasping was particularly easy given the limited excursion of the leaflets at this point, TEE evaluation revealed adequate grasp of both anterior and posterior MV leaflets, trace residual MV regurgitation (Figure A-D), and a mean gradient of 5 mmHg (Figure 2-A) and no pericardial effusion. Fluoroscopic assessment of the Mitral Clip alignment and perpendicularity below the annuloplasty ring was checked in Right Anterior Oblique 10 degree view before and after release of the device (Figure 2-B, C). Of note, she developed atrial fibrillation during the procedure which was successfully cardioverted using 200 J.

Her immediate post-procedure course was uneventful and her anticoagulation was resumed. Over the next four weeks, she showed significant clinical improvement and a follow up echocardiogram showed sustained results with remarkable reduction in her tricuspid regurgitation and negligible residual mitral regurgitation. She remained in sinus rhythm. The mean gradient across the mitral valve remained 5 mmHg. Accordingly, her medications were re-adjusted and decreased to include Bisoprolol 2.5mg daily, valsartan 80 mg daily, spironolactone 25 mg daily, atorvastatin 40 mg daily, and apixaban 5 mg twice daily. Both her furosemide and metolazone were discontinued.

Discussion

Surgical repair of the mitral valve remains the first line option for severe symptomatic mitral regurgitation. Percutaneous therapies have become a reasonable option for patients who are deemed too high risk for surgery. However, these percutaneous devices have not been approved for use in patients with previous surgical repair or annuloplasty rings. Although data suggests that up to 13% of individuals develop severe regurgitation after surgical repair, such post-operative patients have no options if their co-morbidities preclude a redo surgery. Often intensifying medical therapy is not sufficient to reduce hospitalizations for recurrent pulmonary edema or to

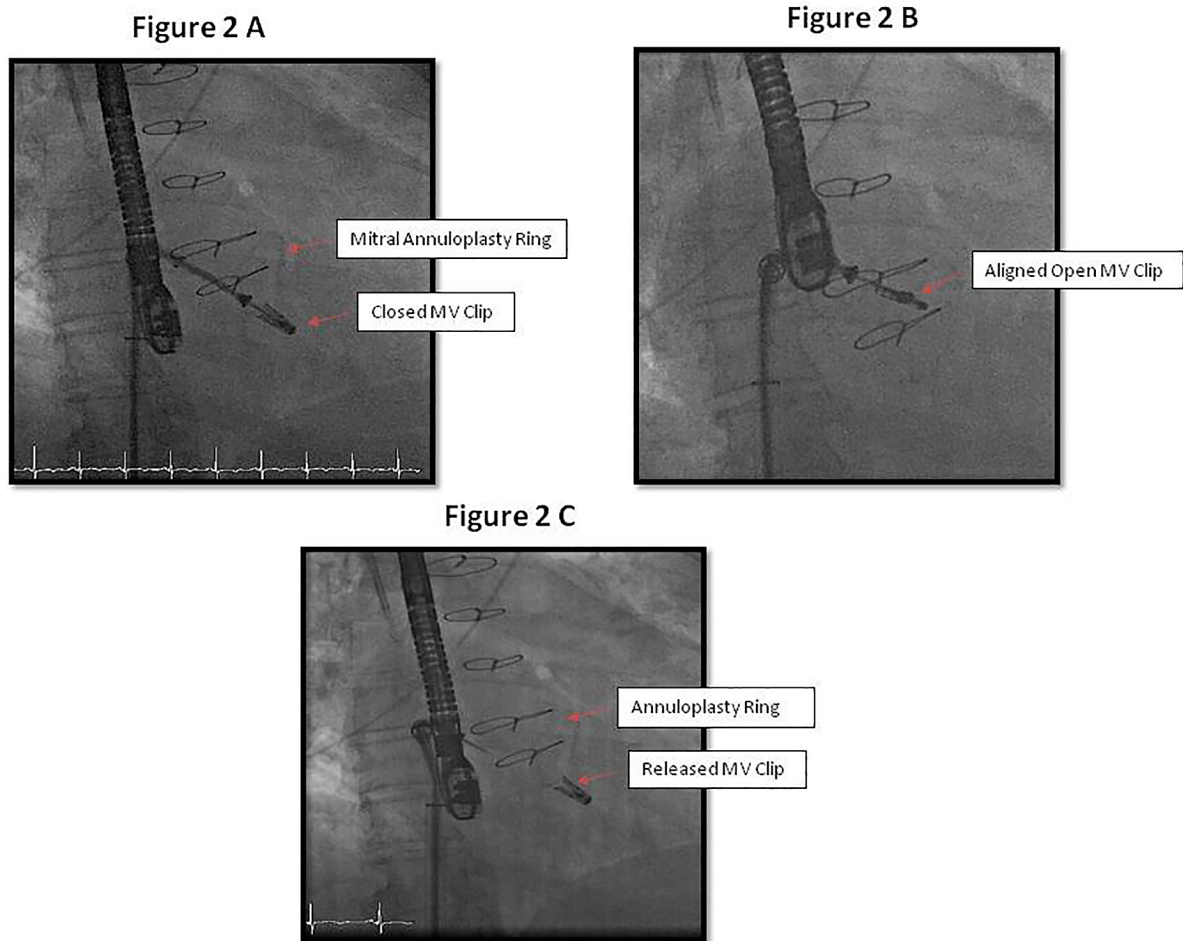


Figure 2. *Panel A.* Fluoroscopic visualization of the closed Mitral Clip below the annuloplasty ring in Right Anterior Oblique 10 degree view. *Panel B.* Fluoroscopic assessment of the open Mitral Clip alignment & perpendicularity below the annuloplasty ring in Right Anterior Oblique 10 degree view. *Panel C.* Released Mitral Clip seen fluoroscopically in situ.

improve quality of life. Off label use of devices, such as in this case, maybe the only reasonable approach. This requires a transparent discussion with the patient indicating the off label use, lack of long term data and entailed risks.

From a technical point of view, a high trans-septal puncture is necessary to allow comfortable manipulation of the device. Correlation with TEE is imperative as the device is positioned to clear the annuloplasty ring. Diving may need to be limited to the level just below the valve leaflets and annulus to avoid entanglement at the chordae as the jet is very eccentric. After diving, further manipulation may be necessary to position the clip at the jet while maintaining perpen-

dicularity. Meticulous assessment by TEE ascertaining adequate grip is a crucial step.

Patients with a previously repaired valve often have a gradient across the mitral valve. Upon placement of the clip, the mean gradient will increase further. It is important to realize that these patients likely will not tolerate a second clip as the gradient will be too high (over 7 mmHg). Appropriate positioning of the clip, optimizing medical therapy and maintaining sinus rhythm are all equally important in reducing the gradient to what the patient can tolerate. In our patient, her initial gradient was 3 mmHg. Post MitraClip placement, the gradient was maintained at 5 mmHg after we converted her to sinus rhythm.

In this case, the etiology of her valve dysfunction is rheumatic valve disease which manifested with regurgitation more than stenosis. The MitraClip device has rarely been used in this pathology. Its use has largely been for degenerative disease of the mitral valve. Results of the COAPT trial for functional mitral regurgitation were published this week. The study concluded that in patients with heart failure and symptomatic severe secondary mitral regurgitation on optimal guideline-directed medical therapy, transcatheter mitral repair resulted in lower hospitalizations and all cause mortality during the 24-month follow up period. The trial also met the prespecified safety endpoint [8].

Given her severe systolic dysfunction, she will require intensive afterload reduction, heart rate control and close follow up. Cardiac Resynchronization therapy (CRT-D) is another treatment option. Data supports its favorable effects on MV and left ventricular geometry with reduction of the prevalence of moderate and severe mitral regurgitation and heart fail-

ure symptoms [9]. Since her ECG showed narrow QRS complexes, she is not a candidate for CRT-D.

Conclusion

This case report suggests MitraClip can be a safe and feasible percutaneous alternative treatment for individuals with a previous MV repair who are deemed too high risk for a redo surgical intervention. However, long term clinical outcomes, durability and safety need to be ascertained through large randomized controlled trials.

Conflict of Interest

The authors have no conflict of interest relevant to this publication.

[Comment on this Article or Ask a Question](#)

References

- Feldman T, Foster E, Glower DD, Kar S, Rinaldi MJ, Fain PS, et al. EVEREST II Investigators. Percutaneous Repair or Surgery for Mitral Regurgitation. *N Eng J Med*. 2011;364:1395-1406. DOI: [10.1097/01.sa.0000410146.91957.d6](https://doi.org/10.1097/01.sa.0000410146.91957.d6)
- Suri RM, Clavel MA, Schaff HV, Michelena HI, Huebner M, Nishimura RA, et al. Effect of recurrent mitral regurgitation following degenerative mitral valve repair: long-term analysis of competing outcomes. *JACC*. 2016;67:488-498. DOI: [10.1016/j.jacc.2015.10.098](https://doi.org/10.1016/j.jacc.2015.10.098)
- Kanda BS, Jay D, Farivar RS, Sorajja P. Leaflet-to-annuloplasty ring clipping for severe mitral regurgitation. *JACC: Cardiovascular Interventions*. 2016;9:e63-e64. DOI: [10.1016/j.jcin.2015.12.272](https://doi.org/10.1016/j.jcin.2015.12.272)
- Simpson M, Daon E, Wiley M, Mujica F. A case of successful mitraClip placement in a patient with severe mitral regurgitation after failed mitral valve ring annuloplasty. *J Cardiothoracic and vascular anaesthesia*. 2018;32:1863-1865. DOI: [10.1053/j.jvca.2017.10.042](https://doi.org/10.1053/j.jvca.2017.10.042)
- Flameng W, Herijgers P, Bogaerts K. Recurrence of mitral valve regurgitation after mitral valve repair in degenerative valve disease. *Circulation*. 2003;107:1609-1613. DOI: [10.1161/01.cir.0000058703.26715.9d](https://doi.org/10.1161/01.cir.0000058703.26715.9d)
- Fuchs F, Hammerstingl C, Werner N, Grube E, Nickenig G. Catheter-based-edge-to-edge mitral valve repair after partial rupture of surgical annuloplasty Ring. *JACC: Cardiovasc Interv*. 2015;8:e263-e264. DOI: [10.1016/j.jcin.2015.08.023](https://doi.org/10.1016/j.jcin.2015.08.023)
- Nishimura RA, Otto CM, Bonow RO, Carabello BA, Erwin JP 3rd, Fleisher LA, et al. 2017 AHA/ACC Focused update of the 2014 AHA/ACC guideline for the management of patients with valvular heart disease: A Report of the American College of Cardiology/American Heart Association task force on clinical practice guidelines. *J Am Coll Cardiol*. 2017;70:252-289. DOI: [10.1016/j.jacc.2017.03.011](https://doi.org/10.1016/j.jacc.2017.03.011)
- Stone G, Lindenfeld J, Abraham WT, Kar S, Lim DS, Mishell JM, et al. Transcatheter Mitral-Valve Repair in Patients with Heart Failure. *N Engl J Med*. 2018;9:1-12. DOI: [10.1056/NEJMoa1806640](https://doi.org/10.1056/NEJMoa1806640)
- Mihos CG, Yucel E, Capoulade R, Orencole MP, Upadhyay GA, Santana O, et al. Impact of cardiac resynchronization therapy on mitral valve apparatus geometry and clinical outcomes in patients with secondary mitral regurgitation. *Echocardiography*. 2017;34:1561-1567. DOI: [10.1111/echo.13690](https://doi.org/10.1111/echo.13690)

Cite this article as: Kurtz JD, Hlavacek AM, Baker GH. Correlation and Agreement of Steady-State Free Processed Imaging Cardiac Magnetic Resonance Imaging and Balloon Waist Diameter of the Right Ventricular Outflow Tract for Percutaneous Pulmonary Valve Replacement. *Structural Heart Disease*. 2019;5(3):70-74. DOI: <https://doi.org/10.12945/j.jshd.2019.028.18>