

The Pediatric and Adult Interventional Cardiac Symposium (PICS/AICS) 22nd Annual Meeting

San Diego, California, September 4-7, 2019

2. ENDOVASCULAR TREATMENT OF CRITICAL COARCTATION OF THE AORTA (COA) IN NEWBORNS AND INFANTS

Elnur Imanov^{1,1}, Sabina Hasanova², Aysel Yusifli¹, Vasiliy Lazoryshynets³, Leman Rüstəmzadə², Fuad Abdullayev⁴, Farida Hajyeva², Samir Mamedov², Oleksandr Pliska⁵

¹ Health Ministry of Republic of Azerbaijanjan Education Therapeutic Clinic of Azerbaijan Medical University, Baku, Azerbaijan. ²Health Ministry of Republic of Azerbaijanjan Education Therapeutic Clinic of Azerbaijan Medical University, Baku, Azerbaijan. ³Amosov National Institute of Cardiovascular Surgery, Kiev, Ukraine. ⁴Health Ministry of Republic of Azerbaijan Scientific Center of Surgery Named After M.A.Topchubashov Pediatric Cardiac Surgery and Neonatal Surgery center, Baku, Azerbaijan. ⁵Dragomanov National Pedagogical University, Kiev, Ukraine

Background: Newborns and infants with CoA combined with hypoplasia of the aorta, CHD, and Ductus dependent flow (DDF) referred to critical heart defects.

Objective: To present in-hospital and mid-term results of endovascular interventions in newborns and infants with CoA.

Material: 60 patients with CoA underwent intervention, of them: 41(68.3%) - surgery; 19 (31.7%) - balloon dilatation. Age of patients =1 to 360 days (98.9 ± 10.8). In 34 (57.6%) patients the diagnosis was prenatal. In patients with DDF, prostaglandin E1 used after prior to the intervention.

In 22 (36.6%) patients CoA combined with other CHD. Pressure gradient in the CoA site during hospitalization was 58 ± 1.7mm Hg. LVEF (51 ± 12%). Mean pressure gradient in endovascular group before dilatation was 59 ± 18 mm Hg. LVEF 41 ± 9%.

Patients with hypoplasia of the aorta and concomitant CHD referred surgery. In presence of low pulmonary flow, and absence or hypoplasia of the aorta, dilatation performed urgently. After angioplasty pressure gradient decreased to 19 ± 7 mm Hg; LVEF increased to 63 ± 7%.

Group with endovascular treatment made an uneventful recovery. 13 (68.4%) patients need surgery for re - CoA on 3 - 6 months after dilation.

Conclusion: In critic patients endovascular intervention should be preferred with good immediate results. Feasibility of angioplasty of CoA in newborns and infants with CoA remains controversial through a high rate of re-coarctation and re-interventions

4. CARDIOVASCULAR DISEASE AND IT PREVENTION

Purusharth Kumar Sharma

Jaipur Rajasthan India
Dental College Affiliated
to Rajasthan University of Health Science

This is a condition which affects our heart, they are of many type such as heart attack, heart failure, CAD, aorta disease and many more. There are many other ways through which we can prevent this so my research work is on that how we can manage these fatal diseases at their early stages so we can prevent the death of patient, or some ways to manage this disease and I think these ways are very helpful to people and some technique which a person can do at their level. If they get heart attack and some medicine which has less side effects and more response.

Method and Sources: To reduce the level of LDL I have now introduced a new compound that will help decrease



the level of LDL by working on the receptor and dilute or we can say dissolve the obstruction in the artery and prevent cardiac disease and help the patient to survive. It is basically used as solid dosage from oral route. In liquid dosage form it can be given intravenously to the patient. The action time in oral route is around 20-25 minutes while intravenously action takes place in 5-7 minutes.

Summary: We find that there is decrease in LDL level in the body as it is good lowering agent as well as it has anti-oxidant property, also does not cause any type of gastric irritation.

Conclusion: There is decrease in level of LDL, so I think it should be used as medicine for patient.

5. ACCURACY OF 3D PRINTED MODELS OF THE RIGHT VENTRICULAR OUTFLOW TRACT: IMPLICATIONS FOR INTERVENTIONAL PLANNING

Animesh Tandon^{1,2}, Surendranath Veeram Reddy^{3,2}, Nicholas Brown^{3,2}, Paige McKenzie^{3,2}, Barbara Burkhardt^{3,4}, Song Zhang⁵, Rami Hallac⁶, Alex Kane⁶, Sana Ullah⁷, Gerald Greil^{1,2}, Tarique Hussain^{1,2}

¹Departments of Pediatrics (Cardiology); Radiology; UT Southwestern Medical Center, Dallas, USA. ²Children's Medical Center Dallas, Dallas, USA. ³Department of Pediatrics, UT Southwestern Medical Center, Dallas, USA. ⁴Pediatric Cardiology, Pediatric Heart Center, Department of Surgery, University Children's Hospital Zurich, Zurich, Switzerland. ⁵Department of Clinical Sciences, UT Southwestern Medical Center, Dallas, USA. ⁶Department of Plastic Surgery, UT Southwestern, Dallas, USA. ⁷Department of Anesthesiology and Pain Management, UT Southwestern, Dallas, USA

Background: Three-dimensional printed models (3DPMs) are used to plan percutaneous pulmonary valve implantation, but their accuracy is not well-characterized. We assessed the accuracy of 3DPMs of right ventricular outflow tracts (RVOTs) of patients with congenital heart disease.

Methods and Results: We used magnetic resonance angiograms from patients with RVOT disease and created 3D stereolithography (STL) files. These files were sent to 4 different 3D printers. The 3DPMs were optically scanned to create 3D digital models. We compared dimensions measured on anterior-posterior (AP) and lateral patient cardiac catheterization angiogram (CCA) projections to the models, created idealized diameters from 2D dimensions of the digital models, and compared the volumes and spatial overlaps of the 3D models.

We considered linear dimensions clinically equivalent if the 95% confidence intervals of the difference of the dimensions was <1 mm.

Twenty-six patients were included. The AP projection dimensions on models from all 4 3D printers were >1 mm larger than CCA dimensions, while the lateral dimensions were not larger. Dimensions derived from 2D dimensions were clinically similar to CCA dimensions. There were significant differences in spatial overlap and model volumes between printers.

Conclusions: We show that there are differences in dimensions between CCA and 3DPMs. The 3DPMs can be different from source data both in size and shape. There are limitations to both 1D measurements on CCA images and measurements on digital representations of 3D objects. We suggest that when using 3D prints for clinical purposes, it is important to understand their strengths and limitations.

6. INITIAL AND MEDIUM-TERM FOLLOW-UP RESULTS OF STENT IMPLANTATION OF PATENT DUCTUS ARTERIOSUS IN DUCT-DEPENDENT PULMONARY CIRCULATION (PULMONARY ATRESIA VARIANTS)

Hani Mahmoud Adel, MD

Pediatric Cardiology Unit, Department of Pediatrics, Alexandria University, Alexandria, Egypt
University of Alexandria Children's Hospital, Alexandria, Egypt

Objective: To study the initial and medium-term results of patent ductus arteriosus (PDA) stenting in cyanotic congenital heart disease with duct-dependant pulmonary circulation (DPC), in the Alexandria University Children's Hospital.

Background: PDA stenting has been proposed as an alternative to surgical shunt on account of postoperative complications and mortality. The initial results of PDA stenting have been discouraging. However, with improvement in coronary stent design and delivery systems, the results of PDA stenting became promising.

Patients and Methods: Babies with PDA-dependent pulmonary circulation in our NICU or referred to our unit were offered an attempt of PDA stenting after written informed parental consent. The study was conducted on 58 cases from 2010 through 2018.

Results: The mean age of the patients was 22.9 ± 21.4 days and mean weight 3.1 ± 0.7 kg. The mean length of

the PDA was 16.71 ± 3.37 mm and mean stent diameter was 4.01 ± 0.24 mm. Fifty-five cases (94.8%) were successfully implanted and 52 cases (89.6%) were completely successful. Three cases (5.2%) died. Five cases (8.6%) developed complications which were properly managed with successful outcome. The mean O₂ saturation increased from $71.2 \pm 6.8\%$ to $88.2 \pm 4.3\%$. *The mean duration of stent patency was 10.5 ± 2.25 months.*

Conclusion: PDA stenting is a very good alternative to surgical shunt with less complications and very good results, nevertheless it is technically demanding. In experienced hands it is feasible to stent nearly all types of PDAs even the very tortuous ones.

Keywords: PDA • PDA stent • Duct-dependent pulmonary circulation.

7. THE RELATIONSHIP BETWEEN LEFT VENTRICULAR DILATION AND RIGHT VENTRICULAR DIASTOLIC FUNCTION IN CHILDREN WITH A PATENT DUCTUS ARTERIOSUS

Jamison Miller¹, William Anderson², Joseph Paolillo³, Matthew Schwartz³

¹Atrium Health- Levine Children's Hospital, Charlotte, USA.

²Atrium Health, Charlotte, USA. ³Atrium Health- Sanger Heart and Vascular Institute- Charlotte Pediatric Cardiology, Charlotte, USA

Introduction: Right ventricular (RV) dilation can lead to left ventricular (LV) diastolic dysfunction due to negative ventricular-ventricular interaction in various forms of congenital heart disease such as repaired tetralogy of Fallot. However, the effect of LV dilation on RV diastolic function has not been examined. Patients with a patent ductus arteriosus (PDA) experience left ventricular volume loading and dilation. We aimed to determine if LV dilation is associated with RV diastolic dysfunction in patients with a PDA.

Methods: We retrospectively identified patients ages 6 months to 18 years who underwent attempted transcatheter PDA closure at our institution between 01/10 and 6/18. Patients with an elevated pulmonary artery pressure were excluded. Demographic variables, pre-catheterization echocardiographic data, and catheterization hemodynamic and angiographic data were examined. We evaluated the relationship between right ventricular end-diastolic pressure (RVEDP) and various patient variables.

Results: A total of 114 patients were included with a median age of 3.0 years (0.5 to 18) and weight of 13.6 kg

(6.2 to 76.4). 53.5% of patients had a small PDA and 43% had a moderate duct. Using linear regression, there was no significant association between RVEDP and LVEDD Z-score ($p=0.74$). Additionally, no association was found between RVEDP with LV end-diastolic volume ($p=0.96$) or Qp/Qs ($p=0.32$). A positive association was found between RVEDP and RV systolic pressure ($p<0.01$), the ratio of pulmonary artery systolic pressure/aortic systolic pressure ($p<0.01$), and pulmonary capillary wedge pressure ($p<0.01$). Student's t-test found no statistical significance when comparing the RVEDP between those with a LVEDD Z-score >2 to those with Z-score <2 ($p=0.57$).

Conclusions: In our cohort of children with a small or moderate PDA and normal pulmonary artery pressures, elevated RVEDP was not associated with left ventricular dilation, but was associated with markers of RV afterload including RV systolic pressure and the ratio of pulmonary artery/aortic systolic pressure. In children with a PDA, left ventricular enlargement does not appear to impact RV diastolic function through ventricular-ventricular interaction and, instead, RV diastolic function appears to be determined by RV afterload.

8. PIGGYBACK STENT MOUNTING AND DEPLOYMENT FOR RVOT PREPARATION DURING TRANSCATHETER PULMONARY VALVE IMPLANTATION

Jenny Zablah¹, Gaute Døhlen², Martin Ystgaard², Gareth Morgan¹

¹University of Colorado, Aurora, USA. ²Oslo University, Oslo, Norway

Background: Heterogeneous complexities of the Right Ventricular Outflow Tract (RVOT) may complicate the delivery and deployment of stents in preparing the landing zone for a transcatheter pulmonary valve. We report our experience with dual stent mounting on a single balloon for deployment of stents in the RVOT before and during transcatheter pulmonary valve placement.

Methods: Retrospective analysis of all patients from Children's Hospital of Colorado, USA; and Oslo University Hospital, Norway; undergoing transcatheter pulmonary valve replacement that had 2 stents mounted on a single balloon and deployed simultaneously in the RVOT. Data collection was carried out from procedural notes and the patients' medical record.

Results: Over a 12-month period, 13 patients (9 male) with a median age of 15.8 years (range 13-21) underwent piggyback stent deployment. All cases involved mounting a bare metal stent on top of a Melody® transcatheter pulmonary

valve delivered via the Ensemble® system. Six patients had a 39mm Andramed XXL stent mounted over the Melody valve, six patients had a 36mm IntraStent LD Max mounted over the Melody and one patient had a 3110 Palmaz XL stent mounted over the Melody valve. Conduit preparation for 2 of these patients included piggybacked stents (CP covered stent and a bare metal stent) mounted on a BIB balloon and deployed simultaneously followed by piggyback stent and Melody valve deployment. Access was via the femoral vein in 10/13 of patients, right internal jugular vein in 2/13 cases and left internal jugular vein in one patient. The mean total procedural time was 95 minutes. No patient had RVOT injury or increase tricuspid regurgitation noted during or after the procedure. All patients had satisfactory resolution of significant outflow tract stenosis with no evidence of melody valve dysfunction on immediate or 6 week follow-up echocardiography.

Conclusions: Conduit preparation, stent and valve delivery and deployment techniques have evolved significantly over the last 10yrs. Alongside this evolution, the complexity of outflow tracts deemed potentially suitable for percutaneous valve implantation has broadened. Given the knowledge that multiple pre-stent placement is mandatory in Melody valve deployment, this technique aims to simplify and facilitate adequate conduit preparation and valve deployment by minimizing manipulation across the outflow tract and decreasing the risk of stent distortion, misalignment and embolization. It inherently decreases the number of angiograms, radiation dose and procedure time for Melody valve deployment.

9. EFFECTS OF PERCUTANEOUS VSD CLOSURE ON NUTRITIONAL STATUS, APPETITE, ANTHROPOMETRIC MEASUREMENTS OF CHILDREN

Nazmi Narin¹, Ozge Pamukcu², Onur Tasci², Didem Barlakketi², Figen Narin¹, Aydin Tuncay²

¹Katip Celebi University, Izmir, Turkey. ²Erciyes University, Kayseri, Turkey

Objectives: The aim of this study was to investigate the changes in symptoms, nutritional growth status of patients before and after the transcatheter closure of ventricular septal defect.

Method: The study was performed prospectively in our clinic. Anthropometric measurements (weight and height for age, Z scores of body mass index (BMI)) were recorded at hospital admission and repeated at 1st and 6th month controls. WHO Anthro/ AnthroPlus programs were used to evaluate these measurements. The patients' subjective appetite evaluation was performed using a 100 mm

long Visual Analog Scale (VAS). Children's Eating Behavior Questionnaire-CEBQ was applied to parents. Furthermore; insulin growth factor-1(IGF-1), insulin growth factor binding protein-3(IGFBP-3), AST, ALT, total protein, albumin, ghrelin, leptin measurements were done and repeated at 1st and 6th month control.

Results: Twenty patients with VSD (13 girls, 7 boys) aged between 2-171 (median 27) months and as control group, 25 subjects (11 girls, 14 boys) (aged between 3-187 (median:46) months) were enrolled in the study. The weight for height, BMI and BMI Z scores were significantly higher in the control group ($p=0,016$, $p=0,029$ and $p=0,019$). The results of questionnaire asked to parents about appetite, frequency of illness, rapid breathing, fatigue and weight gain were similar.

In the first month after VSD closure, there was a significant increase in the z score of weight for age, weight for height, BMI and BMI Z scores of patients ($p=0,05$, $p=0,048$, $p=0,012$ and $p=0,018$). There was an increase in Anthropometric measurements of 6th months compared to others. Ghrelin levels were decreased linearly and appetite increased. Leptin, IGF-1, IGFBP-3, albumin levels before the procedure were significantly lower than control group. However; after the procedure the levels of all these parameters were elevated significantly.

Conclusion: Nutritional deficiency and failure to thrive are important problems of the patients with large VSDs. Treatment of patients should be planned at the appropriate time in order not to disturb their growth. Percutaneous VSD closure is one of the treatments that has an evident positive effect on appetite, nutritional, growth status and hormones.

10. ECHOCARDIOGRAPHIC EVALUATION OF THE PATIENTS AFTER PERCUTANEOUS VSD CLOSURE

Nazmi Narin¹, Ozge Pamukcu¹, Onur Tasci¹, Didem Barlakketi¹, Figen Narin², Aydin Tuncay¹

¹Erciyes University, Kayseri, Turkey. ²Katip Celebi University, Izmir, Turkey

Objective: We aimed to show the echocardiographic changes of the patients after transcatheter VSD closure.

Methods: This study was performed prospectively in our clinic. Left Ventricle Tei index (LVTEI), Right ventricle Tei index (RVTEI), Tricuspid annular plane systolic excursion (TAPSE), Mitral annular plane systolic excursion (MAPSE), inferior vena cava elasticity index (VCI-EI), left, right ventricle end diastolic diameters (LVDD, RVDD) measurements

and their z-scores were calculated before the procedure. Furthermore; area of left and right ventricle at end of diastole (LVa, RVa); left atrial end diastolic diameter (LADD), right atrial end diastolic diameter (RADD), area of left and right atria (LAa, RAa) were recorded. All echocardiographic measurements were repeated 1st and 6th months after the procedure.

Results: Twenty symptomatic patients with hemodynamically significant VSD were included in the study. Thirteen of these 20 patients were girls, patients aged between 2-171 months (median: 27months). Twenty-six patients (16 females, 10 male) were included as control group. Age of the control group was between 3-187 months (median: 46 months). Echocardiographic evaluation before the procedure were shown in Table 1. LVTEI (median=0,42 vs. 0,40 p=0,031), RVTEI (median=0,39 vs. 0,36 p>0,05) VCI-EI (median:17,65 vs. 14,34 p>0,05) were found significantly high in the patient group. Types of VSD in the patient group were 12 perimembranous, 8 muscular type. Pulmonary hypertension was detected in 14 patients in the catheter lab. There was no statistically significance in echocardiographic values of pulmonary hypertensive patients when compared to the ones without pulmonary hypertension. In the 1st month control after percutaneous VSD closure LVTEI, TAPSE and MAPSE z-scores, also LVDD/RVDD ratio significantly decreased (Table 2). LVTEI, RVTEI, TAPSE MAPSE z-scores were decreased linearly in the 6th month control.

Conclusion: Volume overload caused by VSD; had an inappropriate negative effects on left ventricle function at first but also on right ventricle by time. Percutaneous VSD closure is one of the safe and effective treatment model. In this study it was shown that percutaneous VSD closure had a positive effect on echocardiographic dynamics of the children

11. LONG SEGMENT COARCTATION WITH LARGE PDA AND SEVERE PHT IN A 16 KG: PLANNING AND APPROACH TO HYBRID STENTING

Supratim Sen¹, Sneha Jain¹, Priya Pradhan¹, Dipesh Trivedi¹, Bharat Dalvi^{1,2}

¹NH SRCC Children's Hospital, Mumbai, India. ²Glenmark Cardiac Centre, Mumbai, India

History and Physical: A 7 ½ year old girl presented with breathlessness on exertion. Her weight was 16.2 kg. BP was 112/67 mm Hg in the upper limb and 94/63 mm Hg in the lower limb. On auscultation, she had a loud P2, ejection systolic murmur and early diastolic murmur. There was no

mid-diastolic murmur. She had undergone a balloon aortic valvotomy for severe aortic stenosis 6 years ago.

Imaging: Echocardiogram revealed bicuspid aortic valve, moderate aortic regurgitation (AR), large PDA, moderate long-segment coarctation with severe pulmonary hypertension (PHT). AR and right femoral artery thrombosis were sequelae of balloon aortic valvotomy in infancy. The anatomy was delineated on cineangiography and CT angiography. Diagnostic cardiac catheterisation demonstrated significant coarctation and confirmed PHT reversibility after balloon occlusion of PDA and IV Sildenafil.

Indication for Intervention: Stenting is the preferred treatment for aortic coarctation in adolescents and adults. In younger children with coarctation, stents which can be post-dilated to adult size gradually are a good alternative to surgery. As our patient had significant coarctation and a large PDA causing severe pulmonary hypertension, a covered stent would optimally address both the coarctation and PDA.

Intervention: The large calibre arterial access required was of concern. Hence, a hybrid intervention was planned. The surgeon exposed the common iliac artery by cutdown, allowing direct introduction of the 12F Cook Check-Flo sheath. A 16 mm X 3.9 cm Numed covered mounted CP stent was implanted over a BiB balloon with rapid RV pacing under angiographic guidance. Post-stent aortogram showed endoleak and filling of the PDA around the distal stent. Hence post-dilatation of the stent was done using a 18mm x 4 cm Andra balloon to splay the distal end to completely occlude the PDA. Post-procedure, there was good flow across the stent with no residual PDA and no pressure gradient. On follow-up, pulmonary arterial pressures were normal.

Learning Points of the Procedure: Aortic coarctation with large PDA with severe PHT is a difficult combination where PHT reversibility needs to be confirmed followed by a well-planned treatment strategy. A covered stent in this setting is viable and effective. The limiting factor in young patients is the large calibre femoral artery sheath required, especially with covered stents.

Our hybrid approach allows safe arterial vascular access in smaller patients, enabling coarctation stenting for a younger subset of patients. In our case, meticulous planning and teamwork ensured procedural success.

12. IMPROVING LUNG PATHOLOGY BY TACKLING SHUNT LESIONS: MODERATE PM VSD CLOSURE IN

A CASE OF DEXTROCARDIA WITH KARTAGENER SYNDROME

Neeraj Awasthy

Max Hospital, Saket, Delhi, India

An 8 year old child with 10 mm non restricted vsd with dextrocardia and Kartageners syndrome was found not suitable for closure in view of marked lung issues, bronchospasm and repeated chest infection. Patient underwent percutaneous vsd device closure through antegrade approach using 10/12 duct occluder device with significant resolution of symptoms. We postulate that in view of decrease lung segment, rest of the lung segment get flooded with the flow through the shunt lesions and compromise lung compliance. The closure of defects in such situations greatly facilitates the symptomatic improvement.

13. ISOLATED CONGENITAL LEFT CORONARY ARTERY TO CORONARY SINUS FISTULA IN A NEONATE

William Fogarty¹, Robert English^{1,2}

¹University of Florida College of Medicine Jacksonville, Jacksonville, USA. ²Wolfson Children's Hospital, Jacksonville, USA

Case Report: A 20-year-old presented for her first prenatal care visit at 32 weeks gestation. Her pregnancy was uneventful. Past medical history was remarkable for schizophrenia and anemia. She denied use of medications, alcohol, tobacco, and illicit substances. Family history was unremarkable. The initial fetal ultrasound demonstrated an enlarged heart and aortic narrowing.

Fetal echocardiograms at 36 and 38 weeks gestation suggested: total anomalous pulmonary venous return with obstruction of the pulmonary venous confluence in the left atrium, right sided chamber dilation, right ventricular pressure and volume overload, and aortic flow reversal.

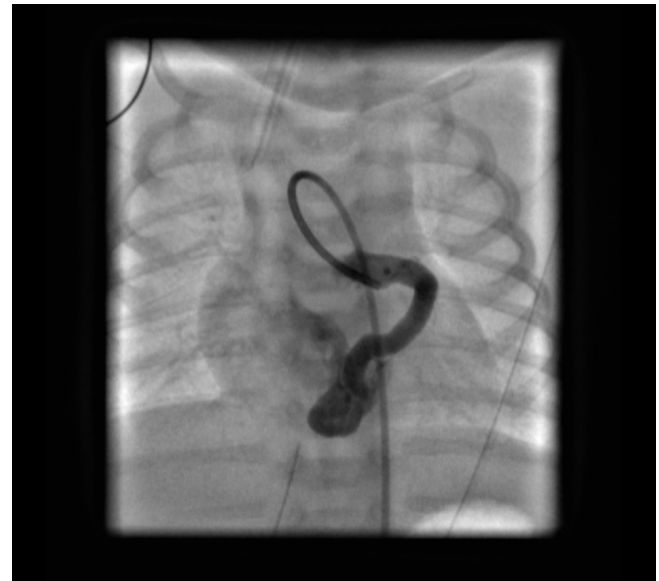Because of the likelihood of severe pulmonary hypertension and obstructed pulmonary venous return after birth, a C-section was performed at 39 weeks gestation.

The child's APGAR scores were 8 at 1 and 5 minutes. She was responsive and alert with no respiratory distress but was intubated due to the suspected cardiac pathology. Cardiovascular exam noted a soft systolic murmur to the left sternal border. An echocardiogram revealed normal pulmonary venous return and a severely dilated left main coronary artery. There appeared to be a fistula connecting the left coronary system to the coronary sinus.

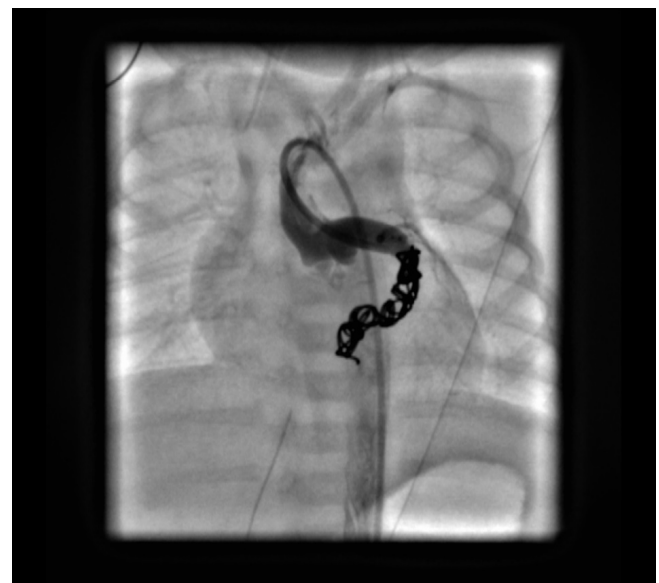Subsequent coronary angiography revealed the fistulous connection to the coronary sinus off of the distal left

circumflex coronary artery. Embolization of the fistula was performed using 2 coils (14cm x 4 mm distally and 14 cm x 6 mm proximally). Repeat coronary angiography confirmed complete occlusion of the fistula and good filling of the left coronary artery. See Figures 1 and 2.

The infant remained stable and was started on aspirin. Serial echocardiograms demonstrated closure of the PDA, persistent large atrial septal defect, aneurysmal atrial septum, and normal biventricular function. The infant was discharged on day of life 19.



13. Figure 1



13. Figure 2

Discussion: The overall prevalence of congenital heart disease (CHD) ranges from between 4 to 10 per 1,000 live birth. Several authors have reported the accurate prenatal diagnosis of CHD to range from 27%-36% with increasing detection rates in recent years.

Isolated congenital coronary fistula (CAF) occurs in 1:50,000 live births. Due to its low incidence and the difficulty in evaluation of the fetal coronary circulation, prenatal detection rates are low. There are only 8 reported cases of isolated coronary fistulae diagnosed prenatally.

The prenatal imaging in this patient clearly identified turbulent flow at the base of the left atrium. This turbulent flow and the dilated chamber proximal to it (the coronary system) were consistent with obstructed pulmonary venous return to either the coronary sinus or to the hepatic venous system. However, the reversal of flow in the aorta indicated the presence of significant runoff as would be expected from a large coronary fistula.

Although most patients with CAF are asymptomatic at diagnosis, heart failure, endocarditis, arrhythmia, and rupture of the fistula can be presenting findings. Additionally, premature arteriosclerotic changes within the fistula and thromboembolic events have been described as possible complications. Closure of hemodynamically significant fistulae is recommended. Transcatheter approaches have become increasingly favored as in our case.

14. UNIQUE CAUSE OF SYNCOPE IN A 29-YEAR OLD WOMAN WITH HISTORY OF VENTRICULAR SEPTAL DEFECT AND COARCTATION

Dana Konecny, David Laughrun, Tomas Konecny
University of Southern California, Los Angeles, USA

Case Presentation: 29-year old woman with history of ventricular septal defect (VSD) and aortic coarctation repair was referred for repetitive syncope. Syncopal spells lasted several minutes, occurred yearly, and they coincided with a prodrome of nausea and vomiting. On examination she had no signs of heart failure, no murmurs, equal pulses in both arms, and normal carotid upstrokes without bruits. ECG showed sinus rhythm with bifascicular block but normal PR interval and mild prolongation of QTc to 471. Echocardiogram showed normal heart function without detectable VSD. Holter monitor recorded sinus rhythm with a 4-beat run of supraventricular tachycardia. MRA confirmed normal aortic flow without stenosis or dilatation.

Diagnosis And Treatment: Our differential diagnosis included vasovagal syncope (nausea during prodrome),

infrastrian heart block (existing bifascicular block), ventricular tachy-arrhythmia (re-entry around the VSD scar), subclavian steal (left subclavian artery taken down during coarctation repair), supraventricular tachy-arrhythmia (short run on Holter monitor). Implantable loop recorder was placed parasternally in left 6th intercostal space, and after 6 months it successfully recorded a syncopal episode, showing complete heart block with 20 second ventricular asystole. Dual chamber permanent pacemaker was placed with minimum radiation exposure and extra-shielding (patient was at that time in the second trimester of pregnancy). Syncopal episodes have not recurred during the follow up period.

Discussion: Patients with history of VSD and coarctation repair present unique considerations when evaluating syncope. Their initial coarctation repair may lead to aortic flow impairments with subsequent aneurysmal dilatation or stenosis, but in this case MRA with gadolinium contrast excluded this possibility. Subclavian steal due to missing left subclavian artery (which was taken down for flap repair of the aortic coarctation) can be another potential etiology for syncope via reduction in vertebral artery flow. Patients with hemodynamically significant VSD can potentially suffer from left-to-right shunting and resultant Eisenmenger syndrome, but the Echocardiogram excluded significant residual septal defect. The VSD repair in infancy can lead to uniquely delayed rhythm abnormalities: ventricular tachycardia due to conduction heterogeneity around the previous VSD, and bradyarrhythmias due to infrastrian block. Ultimately, adult congenital heart disease patients can suffer from etiologies common to all patients with syncope: supraventricular tachycardias, vasovagal syncope, orthostatic hypotension, and multiple non-cardiac causes.

Conclusion: Adult patients with unexplained syncope who underwent VSD and coarctation repair in infancy should be evaluated at a specialized center for delayed, potentially lethal consequences of their condition. If imaging, hemodynamic, and short-term ECG monitoring results are reassuring, a pro-active serial surveillance should be taken with implantable rhythm monitoring and imaging studies to allow for timely implementation of potentially life-saving interventions.

15. TECHNICAL ASPECTS OF CLOSURE OF RCA TO RV FISTULA

Pablo Teixeira, Joao Felipe de Toledo, Luiz Antonio Gubolino, Vanessa Sousa, Wilson Guimaraes
Santa Casa de Misericordia de Limeira Hospital, Limeira, Brazil

Patient is an eleven year-old female, asymptomatic. Known heart murmur from birth, initially diagnosed as VSD. In the last year there was an increase in heart murmur intensity, pediatrician solicited an AngioCT that showed a large RCA fistula draining into RV cavity. Percutaneous treatment was indicated. Two strategies were programmed. Closure using a vascular plug or embolization with microcoils. Angiography showed a tortuous proximal right coronary fistula draining into RV, without significant stenosis, so the strategy with microcoils was aborted. Qp/Qs was 1,7/1,0. Approach was made with arterial and venous access with 6F sheaths. Catheterization of the fistula was achieved with JR 3.5 guiding catheter. A 0,014" x 300 cm floppy wire was used to cross the fistula and was positioned in the pulmonary trunk. Through the venous side, another JR 3.5 GC was positioned in pulmonary trunk and the floppy wire was snared and so the AV rail was made.

Then the venous guiding catheter was exchanged to a Cook® Flexor® Raabe® 6F sheath and through the 0,014" wire we sought to position it in the proximal part of the fistula, just next to a mild stenosis. The proximal diameter of the vessel was 7.2 mm and 3.8mm in the stenotic area. We chose an Amplatzer® Vascular Plug 2 of 8 mm and positioned it through the venous 6F sheath, keeping the 0,014" wire in place, to improve support and to keep the AV rail in place in case the plug would not keep its position in the desired location.

After contrast injection through the arterial side to ensure the correct location of the plug, we removed the 0,014" very carefully and released the plug unscrewing the delivery cable. Control injection showed a very stable plug position and a mild residual shunt. We kept the patient with aspirin, and she was discharged 48 hours after the procedure. An echocardiogram was performed pre-discharge and did not showed residual shunts. There was not any ischemic events, as the normal right coronary artery was irrigated through collaterals from the LAD.

Conclusion: closure of coronary fistula is feasible and easy to perform with vascular plugs, because they are flexible and emboligenic. New flexible sheaths are very safe and can cross tortuosities easily, making these procedures fast and predictable.

16. SEVERE CONDUIT CALCIFICATION PREVENTING PERCUTANEOUS PULMONARY VALVE IMPLANTATION SECONDARY TO CORONARY ARTERY COMPRESSION

Elyssa Cohen¹, Dennis VanLoozen^{2,1}, Zahid Amin²

¹Medical College of Georgia at Augusta University, Augusta, USA.

²Division of Pediatric Cardiology, Children's Hospital of Georgia, Augusta, USA

Coronary artery compression is a serious complication that can occur in patients who are candidates for percutaneous pulmonary valve implantation (PPVI). Coronary artery compression most commonly occurs in PPVI patients whose coronary arteries are in close proximity to the conduit or in PPVI patients who have an anomalous course of their coronary arteries. Aortography and selective coronary angiography is performed in all cases to rule out potential compression of the coronary arteries before PPVI. The risk of coronary compression in cases of severe conduit calcification needs increased awareness, and our case is unique in that it emphasizes the potential for late coronary artery compression by peri-conduit calcification before PPVI. We describe a patient status post right ventricle – pulmonary artery (RV-PA) conduit placement with normal origin and course of the coronary arteries in whom a PPVI procedure was aborted due to severe peri-conduit calcification displacement during full balloon inflation. The mobility of the peri-conduit calcification enabled the calcification to impinge the left main coronary artery with angiography evidence of blunted blood flow, despite adequate distance of the conduit from the coronary arteries. The goal of PPVI is to implant a valve of the maximum, and safest, diameter to ensure a maximum relief in RV to PA gradient. However, in this case, overextension of the initially placed conduit presented a risk of coronary artery compression. We emphasize that in order to evaluate for the potentially catastrophic complication of peri-conduit calcification mobility causing delayed coronary artery compression, it is critical to dilate the conduit to the diameter of the proposed valve diameter via balloon angioplasty with simultaneous coronary angiography in order to assess coronary blood flow. It is essential for physicians to consider the amount of conduit calcification as a potential cause of delayed coronary artery compression and for clinicians to recognize the importance of evaluating the mobility of the calcification upon balloon angioplasty, in order to avoid the potential detrimental complications associated with coronary artery compression.

17. UTILIZATION OF MULTIFUNCTION OCCLUDER (MFO) FOR SUBARTERIAL VENTRICULAR SEPTAL DEFECT (VSD) : A SINGLE CENTRE CASE SERIES

Anudya Kartika^{1,2}, Mahrus Rahman², Teddy Ontoseno², Alit Utamayasa²

¹Airlangga University, Surabaya, Indonesia. ²Soetomo General Hospital, Surabaya, Indonesia

Ventricular septal defects (VSD) remain the most common congenital heart defect at birth. Transcatheter closure has become the preferred strategy for isolated symptomatic defects, but it was formerly contraindicated to perform for this subtype of VSD. We hereby report percutaneously implanted MFO for 4 patients, aged 2 to 8 years at our center, without any device migration/embolization, shock, stroke, major morbidity, or mortality noted. The location of the subarterial VSD, with its close proximity to the aortic valve, often accounts for the possible subsequent development or even worsening of aortic regurgitation with this defect. Left-to-right shunting of blood through the defect is believed to pull aortic valve tissue progressively. Therefore surgical VSD closure has been the treatment of choice. The clinical judgement, approach, sizing, and careful implantation are important technical aspects to achieve feasible and successful procedures.

18. PRE-STAGE 2 VENTRICULAR END-DIASTOLIC PRESSURE IS ASSOCIATED WITH POOR OUTCOMES AFTER THE FONTAN OPERATION

Matthew Schwartz^{1,2}, Aravinth Karunanandaa², William Anderson³, J. Rene Herlong^{1,2}, Joseph Paolillo^{1,4}, Gonzalo Wallis^{1,2}, Paul Kirshbom^{1,2}, Thomas Maxey^{1,2}

¹Sanger Heart and Vascular Institute, Charlotte, USA. ²Levine Children's Hospital, Charlotte, USA. ³Center for Outcomes Research and Evaluation, Atrium Health, Charlotte, USA. ⁴Levine Children's Hospital, Charlotte, United States Minor Outlying Islands

Introduction: Systemic ventricular end-diastolic pressure (SVEDP) is an important physiologic variable in patients with single ventricle congenital heart disease. Predictors of an elevated SVEDP prior to the Stage 2 operation have been incompletely identified.

Methods: All patients with single ventricle congenital heart disease who underwent the Stage 2 operation at our center between 1/07 and 3/17 were retrospectively identified. All had undergone pre-Stage 2 catheterization and relevant patient variables were extracted. For patients who had undergone Fontan operation at the time of this study, relevant post-Fontan patient variables were also extracted. Statistical analysis was performed to identify patient variables that were associated with pre-Stage 2 SVEDP and to identify the association between pre-Stage 2 SVEDP and outcomes after the Fontan operation.

Results: 100 patients were included with a mean weight of 6.4 kg \pm 2.4 at the pre-Stage 2 catheterization. 71 (71%) patients had a systemic right ventricle (RV) and 55 (55%) had undergone a Norwood operation. At the pre-Stage 2

catheterization, the mean SVEDP was 8.7 mmHg \pm 2.4. The mean SVEDP was higher amongst those with systemic RV compared to left ventricle (9.1 mmHg \pm 2.1 vs. 7.7 \pm 2.7 mmHg, $p < 0.01$). On univariate analysis, pre-Stage 2 SVEDP was positively associated with the presence of a systemic RV ($p < 0.01$), history of reocclusion ($p = 0.03$), history of Norwood operation ($p = 0.04$), and ventricular systolic pressure ($p < 0.01$). On multivariate analysis, SVEDP was positively associated with the presence of a systemic RV ($p < 0.01$) and ventricular systolic pressure ($p < 0.01$). Amongst those who had undergone Fontan operation at the time of study ($n = 49$), the pre-Stage 2 SVEDP was associated with a composite post-Fontan outcome of death, transplantation, or listed for transplantation ($p = 0.02$) and with the presence of heart failure symptoms ($p = 0.04$) at a mean age of 5.2 yrs \pm 1.3 at last follow-up. Of those with a pre-Stage 2 SVEDP < 9 mmHg who eventually underwent Fontan operation, none met the composite post-Fontan outcome of death, transplantation, or listed for transplant (negative predictive value of 100%, CI 87-100%).

Conclusions: In a cohort of patients with single ventricle heart disease undergoing Stage 2 operation, pre-Stage 2 SVEDP was higher in those with systemic RV compared to LV and was predictive of death or need for transplantation after Fontan operation. The volume-loaded, pre-Stage 2 state likely exposes diastolic dysfunction that may have important prognostic value.

19. DO WE FULLY UNDERSTAND AORTOPULMONARY COLLATERALS? A PICS INTERVENTIONALIST SURVEY

Bassel Mohammad Nijres¹, E. Oliver Aregullin^{1,2}, Yasser Al-Khatib^{1,2}, Bennett Samuel¹, Joseph Vettukattil^{1,2}

¹Spectrum Health Helen DeVos Children's Hospital, Grand Rapids, USA. ²Michigan State University College of Human Medicine, Grand Rapids, USA

Background: Aortopulmonary collaterals (APCs) frequently develop in patients with single ventricle physiology. The triggers for APC development and hemodynamic impact are not clearly understood. Consensus guidelines for timing and type of intervention are also lacking.

Study Design: A survey was emailed to the PICS mailing list between February and March 2019 to appreciate APC management.

Results: The responses of the 142 interventionalists are summarized in Table 1.

19. Table 1. Responses from interventionalists across the world on APC management.

Questions	N (%)
Most important trigger for development of APCs	
Inflammation following surgery	6 (4.2)
Small pulmonary artery bed	26 (18.3)
Desaturation	77 (54.2)
Unsure	28 (19.7)
Other	5 (3.5)
Do APCs increase, decrease or stay the same following Fontan completion?	
Increase	24 (16.9)
Decrease	42 (29.6)
Stay the same	47 (33.1)
Unsure	29 (20.4)
Do you perform segmental aortic angiograms for all pre-surgical evaluations?	
Always	45 (31.7)
Sometimes	79 (55.6)
Never	13 (9.2)
Other	5 (3.6)
Do you perform bilateral selective subclavian artery angiograms for all pre-surgical evaluations?	
Always	35 (24.7)
Sometimes	87 (61.3)
Never	17 (12.0)
Other	3 (2.1)
Do you measure oxygen saturation at different pulmonary artery branch segments?	
Always	8 (5.6)
Sometimes	61 (43.0)
Never	72 (50.7)
Other	1 (0.7)
Do you favor aggressive APC occlusion, i.e., to occlude all collaterals if deemed safe and feasible?	
Yes	80 (56.3)
No	62 (43.7)
APC occlusion is	
Permanently effective	20 (14.1)
Temporarily effective as new feeders eventually grow and refeed the original network	36 (25.6)
Temporarily effective as new collateral networks will likely develop	71 (50.0)

Unsure or unknown 15 (10.6)

When do you prefer to occlude APCs?

Pre-superior cavopulmonary connection (Pre-Glenn) evaluation	17 (12.0)
Pre-total cavopulmonary connection (Pre-Fontan) evaluation	66 (46.5)
Post cavopulmonary connection (Fontan) evaluation	12 (8.5)
The stage of palliation does not influence my decision	47 (33.1)

What device do you most frequently use to occlude APCs?

Coils	105 (73.9)
Plugs	22 (15.5)
Microspheres	12 (8.5)
Other	3 (2.1)

What is your approach for occluding feeder vessels such as the internal mammary artery?

Occlude the entire length of the vessel as much as possible (make the vessel impacted with devices)	71 (50.0)
Occlude only the origin of the vessel	19 (13.4)
Occlude the distal, middle, and proximal sites, but not the whole course	31 (21.8)
I don't occlude the feeder vessel, but occlude the distal network using microspheres	10 (7.0)
Other	11 (7.8)

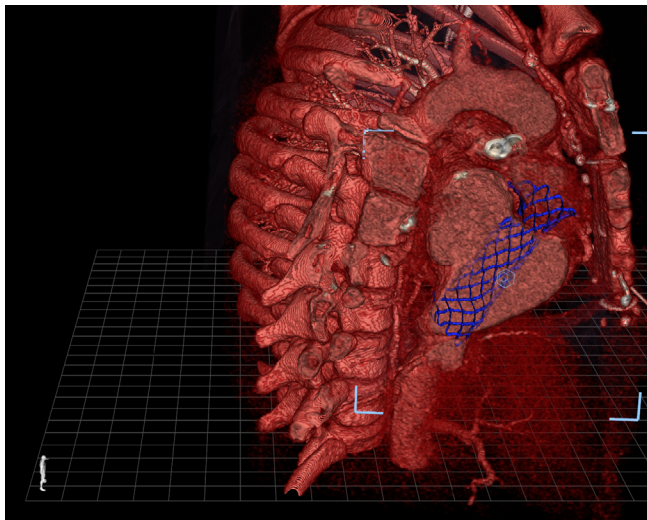
20. TRANSCATHETER FONTAN COMPLETION USING CUSTOM-MADE CHEATHAM-PLATINUM STENT

Bassel Mohammad Nijres¹, E. Oliver Aregullin^{1,2}, Yasser Al-Khatib^{1,2}, Jordan Gosnell¹, John Byl¹, Bennett Samuel¹, Allison Amidon¹, Cody Pinger³, Timothy Hudson^{4,2}, Joseph Vettukattil^{1,2}

¹Spectrum Health Helen DeVos Children's Hospital, Grand Rapids, USA. ²Michigan State University College of Human Medicine, Grand Rapids, USA. ³Michigan State University, East Lansing, USA. ⁴West Michigan Anesthesia, PC, Grand Rapids, USA

Introduction: Transcatheter Fontan completion is a challenging procedure with no dedicated commercially available devices. We describe transcatheter Fontan completion using a custom-made Cheatham-Platinum (CP) Stent™ (NuMED, Inc., Hopkinton, NY).

Case Description: A 15-year-old male with history of double inlet left ventricle and L-transposition of great arteries



20. Figure 1



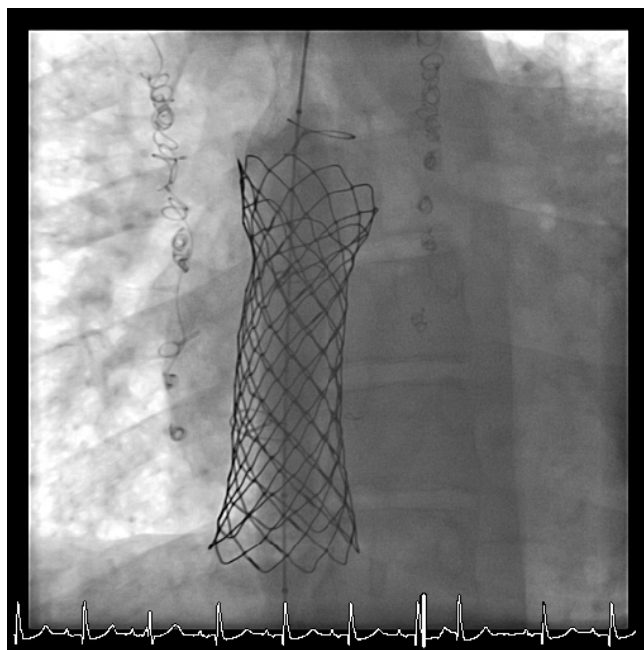
20. Figure 2

underwent multiple interventions with a total of 6 sternotomies at another institution. The last surgical procedure was a failed fenestrated lateral tunnel Fontan palliation at 4-years of age with conversion to Hemi-Fontan circulation 3-weeks later due to severe hypoxemia requiring ECMO support. Evaluation at our center at age 15-years revealed elevated LVEDP with systemic hypertension. Following medical management, LVEDP was 10mmHg with MPAP of 14mmHg. 3D transesophageal echocardiogram and cardiac CT were performed to evaluate suitability for Fontan completion. Due to complex medical/surgical history, a multidisciplinary team recommended transcatheter Fontan completion. A prototype CP Stent was designed based on 3D visualization of cardiac CT on True3DViewer

(EchoPixel, Inc., Santa Clara, CA), and deployed in a flexible 3D-printed model to evaluate stent positioning and foreshortening (Figure 1 & 2).

A significant ePTFE tear was noted. The ideal deployed stent length was determined to be 82mm mounted on a custom dog-bone shaped BIB catheter: 10mm upper end uncovered for anchoring, and 15mm lower end uncovered to avoid obstructing the hepatic veins flaring to 32mm in diameter; and middle 57mm covered segment (22mm in diameter) with a 4-6 mm fenestration punched into the ePTFE. After obtaining compassionate use authorization for the custom CP Stent from the FDA, IRB and institutional risk and compliance, we brought the patient to the catheterization laboratory for intervention.

Intervention: A transeptal needle was inserted into the femoral venous sheath and advanced across the hemi-Fontan pouch. Subsequently, a 0.018" V18 wire was snared from the left internal jugular vein (LIJV). Serial balloon dilations of the punctured hemi-Fontan pouch were performed using Advance balloons. The V18 wire was exchanged for a 0.035 Amplatz super stiff wire. The LIJV sheath was exchanged for a Gore 22Fr DrySeal sheath (65cm in length). The CP Stent was prepped and loaded into the long sheath over the Amplatz super stiff wire. The stent was deployed after confirming optimal positioning. Repeat angiograms showed the stent seated in a stable position connecting the hemi-Fontan pouch with the inferior vena cava.



20. Figure 3

A large residual shunt was noted possibly due to ePTFE tear. Three commercially available covered CP Stents (2x45mm and 1x40mm) were deployed inside the custom stent to close the residual shunt. Final angiography showed good stent position without significant residual shunt. Mean Fontan pressure was recorded at 14mmHg. The patient was discharged to home after 2-days of observation with systemic oxygen saturation in the low 90s on room air. At 3-weeks follow-up, baseline oxygen saturation was 93% on room air with improved exercise tolerance and saturation of 87% at peak exercise.

Conclusion: Transcatheter Fontan completion can be achieved in select cases after thorough evaluation using advanced imaging technologies. Custom-made stents may be required for specific and unique anatomy for minimally invasive Fontan completion.

21. EXPANDED ACCESS TO INVESTIGATIONAL AND CUSTOM-MADE DEVICES FOR EMERGENCY AND COMPASSIONATE USE: A SINGLE CENTER EXPERIENCE

Bennett Samuel¹, Brittany Karl², Deepthi Datla³, Allison Amidon¹, Nathalie Hautala¹, Rebecca Vanderzand¹, Bassel Mohammad Nijres¹, E. Oliver Aregullin^{1,4}, Joseph Vettukattil^{1,4}

¹Spectrum Health Helen DeVos Children's Hospital, Grand Rapids, USA. ²Spectrum Health Office of Research, Grand Rapids, USA. ³Spectrum Health Hospitals, Grand Rapids, USA. ⁴Michigan State University College of Human Medicine, Grand Rapids, USA

Background: Approval of Class III medical devices by the U.S. Food and Drug Administration (FDA) can take from 3 to 7 years. However, patients with serious or life-threatening conditions have limited time to wait for device approval for necessary treatment or therapy. In these patients, expanded access to investigational devices may be the only treatment option. The FDA's Center for Devices and Radiological Health (CDRH) regulates and authorizes expanded access including the manufacturing and use of patient-specific custom medical devices. We present our experience in providing expanded access to investigational devices to our patients through emergency and compassionate use of unapproved and custom-made devices with exemplary support from the FDA, which is often considered to be an impediment by physician implanters. **Methods:** From January 2014 to March 2019, 7 patients underwent transcatheter intervention at the Congenital Heart Center, Spectrum Health Helen DeVos Children's Hospital, Grand Rapids, MI with expanded access investigational devices.

Results: Two female patients, aged 54 and 60 years, underwent emergency use of the Occlutech® Atrial Flow Regulator device (Occlutech International AB, Helsingborg, Sweden)

for severe pulmonary arterial hypertension. A 62-year old male underwent compassionate use of a custom-made vascular plug for closure of saphenous vein graft aneurysm 23 years following coronary artery bypass graft surgery. Two female patients, aged 41 and 56 years, underwent compassionate use of the Occlutech® Fenestrated Atrial Septal Defect device (Occlutech International AB, Helsingborg, Sweden) for atrial septal defect-associated pulmonary hypertension. Two patients underwent compassionate use of custom-made Cheatham-Platinum Stent™ (NuMED, Inc., Hopkinton, NY, USA): one for transcatheter Fontan completion in a 15-year-old male, and the other in a 53-year-old male for closure of superior sinus venosus atrial septal defect with redirection of flow from the partial anomalous pulmonary venous return to the left atrium. The request for emergency/compassionate use was initially authorized by the institutional review board (IRB) chair, and institutional risk and compliance prior to applying to the FDA. In one case, the IRB authorized compassionate use pending FDA determination prior to providing IRB chair letter of concurrence. Risk & compliance authorization included review and modification of the informed consent form to meet institutional compliance. Insurance authorization for all patients was received following peer-to-peer consultation. All devices were successfully implanted. **Conclusions:** The FDA has a number of pathways for expanded use of unapproved medical devices for patients where there are no comparable or satisfactory therapies or alternative treatment options available in the country. The FDA-CDRH is a great resource and provides excellent support to physicians for expanded access to investigational devices. Local IRB and institutional risk and compliance often provide additional guidelines and support for expanded access cases. Peer-to-peer review for insurance authorization may be required based on the patient's insurance and state or local laws. Expanded access to investigational devices can be made available to patients with no other treatment options with guidance from the FDA, IRB, and institutional risk & compliance.

22. BAILOUT TECHNIQUE FOR UNEXPECTED PROXIMAL MIGRATION OF MELODY VALVE DURING DEPLOYMENT

E. Oliver Aregullin^{1,2}, Bassel Mohammad Nijres¹, Bennett Samuel¹, Joseph Vettukattil^{1,2}

¹Spectrum Health Helen DeVos Children's Hospital, Grand Rapids, USA. ²Michigan State University College of Human Medicine, Grand Rapids, USA

Introduction: Transcatheter pulmonary valve replacement is a minimally invasive procedure. However, it is not risk-free as complications may occur in any step during

transcatheter assessment and valve deployment. We describe a rare complication and its management.

Case Description: A 9-year-old male with history of pulmonary atresia with ventricular septal defect (VSD) had VSD patch closure and right ventricular outflow tract reconstruction with transannular patch at 1-week of life. At 15-month of age, he underwent left pulmonary artery (LPA) stent placement. At 3 years of age, he required surgical pulmonary valve replacement using a 23mm Trifecta valve, partial removal of the LPA stent and patch augmentation of the LPA. Recent cardiac magnetic resonance revealed severely dilated right ventricle (RV) with moderately depressed RV systolic function (indexed RV end diastolic volume of 202 mL/m²). He was taken to the cardiac catheterization laboratory for possible transcatheter pulmonary valve replacement and balloon angioplasty of the LPA stent.

Intervention: Access was obtained via right femoral vein and artery. The distal LPA was accessed using an end-hole catheter and a 0.035" Lunderquist wire. Balloon angioplasty of the LPA stent was performed using a 12mm x 40mm Powerflex balloon. Following coronary compression test using a Z-MED II 22x4mm balloon, a 22mm Melody valve was prepped and loaded on the Ensemble system in the usual fashion, tracked over the Lunderquist wire and positioned in the LPA. Due to difficulty in advancing the delivery system, the valve was partially unsheathed to advance it. With this maneuver, the Melody valve was positioned inside the Trifecta valve, but the balloon slipped back with only the proximal half of the Melody valve still loaded on the BIB balloon. Moreover, part of the distal Melody valve stent strut was flared out presumably by being pushed against the "carrot". The Melody valve was then completely unsheathed and the proximal end was deployed inside the Trifecta valve by inflating the inner and the outer balloons, giving the valve a conical configuration. While keeping the Lunderquist wire in place, the Ensemble system was carefully exchanged for a 12x40mm Powerflex balloon across the Melody valve. This balloon was inflated to a maximum pressure of 6 ATM resulting in partial expansion of the distal segment of the Melody valve. Subsequently, the Powerflex balloon was exchanged for a 22x40mm Atlas Gold balloon and inflated to 10 ATM pressure. Following complete inflation, the Melody valve was fully expanded. Angiographic assessment showed optimal valve position with good function and no paravalvular leak.

Conclusion: The presence of a branch pulmonary artery stent may hinder the smooth advancement of the Melody valve Ensemble system. Unsheathing the valve prior to

positioning in the intended position may carry the risk of dislodging it off the balloon; although challenging, the valve can still be deployed in a good position with the aid of several balloon combinations.

23. SAFETY AND FEASIBILITY OF DAY CASE PFO CLOSURE. COMPARISON BETWEEN OCCLUTECH AND AMPLATZER DEVICES USING TRANSTHOCACIC ECHOGRAPHY AND FLUOROSCOPIC GUIDANCE.

François Godart, Jean Benoit Baudelet, Ali Houeijeh, Olivia Domanski, Anne Sophie Polge

Institut Coeur Poumon, Lille, France

The purpose of this work is to report one-year experience in day case transcatheter PFO closure using Figulla Flex II and PFO Amplatzer devices. A comparison study is also performed between 2 occluders.

From January to December 2018, 102 patients suffering from a stroke underwent transcatheter PFO closure as day-case. Devices employed included: Figulla^R Flex II (Occlutech, n=66), PFO AmplatzerTM (AGA, Saint Jude medical) (n=36). Procedure was performed under local anesthesia with fluoroscopic and transthoracic echocardiographic (TTE) guidance. Implantation succeeded in all. The complications included transient ST deviation in 10 patients due to air embolism with no permanent damage. In 2 cases, hospital discharge was delayed: one because femoral fistula requiring compression (day 5) and the other because of pericardial effusion requiring no drainage (day 2). At the one-month control, 5 patients complained of chest tightness, 8 reported palpitations, 5 had AF. Eighty-five patients had no shunt on contrast TTE, 16 had a persistent shunt, and 1 was lost on follow-up. At the 6-month control, 7 of these 16 patients had no residual shunt. In the comparative study, patients were older in-group Amplatzer but had a similar weight. No significant difference could be observed between the 2 groups concerning time of fluoroscopy, dose of radiation, ST deviation, and persistence of shunt at one month (p = NS). No recurrence of stroke was noticed during follow-up (127±98 days).

To conclude, day-case procedure for percutaneous PFO occlusion is safe and effective. This approach is not more risky for the patients in terms of embolization. No significant difference could be observed between the Occlutech and Amplatzer PFO devices achieving both similar good results.

24. FUNCTIONAL TRICUSPID REGURGITATION AFTER TRANSCATHETER CLOSURE OF ATRIAL SEPTAL DEFECT IN ADULTS

Yvonne Bach^{1,2}, Lusine Abrahamyan^{3,4}, Jennifer Day⁵, Eric Horlick^{6,7}

¹University Health Network, Toronto, Canada. ²University of Toronto, Toronto, Canada. ³University Health Network, Toronto, Canada. ⁴University of Toronto, Toronto, Canada. ⁵University Health Network, Toronto, Canada. ⁶University Health Network, Toronto, Canada. ⁷University of Toronto, Toronto, Canada

Background: There remains a large proportion of patients who continue to have moderate to severe tricuspid regurgitation (TR) after transcatheter atrial septal defect (ASD) closure. The baseline predictors and long-term outcomes of persistent TR are not well defined.

Objectives: This study aims to determine the clinical significance of functional TR in ASD patients and identify the baseline predictors of persistent TR after ASD closure to help define non-existent adult congenital heart disease guidelines.

Methods: 1509 patients who underwent transcatheter ASD closure from 1997-2016 were reviewed. Clinical and echocardiographic data were retrieved from electronic medical records at the University Health Network, Toronto. Primary (cardiovascular-related death and hospitalization due to heart failure) and secondary (stroke, new-onset atrial fibrillation, ASD re-intervention, and tricuspid valve surgery) long-term outcomes are currently being collected from Ontario health registries.

Results: A total of 804 patients met the inclusion criteria and had pre- and post-closure data. At baseline, 629 (78%) patients had mild/no TR and 175 (22%) patients had moderate to severe TR. 66 patients of the latter group (38%) did not have a reduction in TR grade at a median follow-up of four months, and were categorized as having persistent TR. Age ≥ 65 years (OR = 4.95, 95% CI 2.26-11.1) and right ventricular systolic pressure (RVSP) ≥ 45 mmHg (OR = 3.46, 95% CI 1.55-7.97) were independent predictors of persistent moderate to severe TR. Event-free survival and long-term analyses stratified by pre-procedural grade and post-procedural grade will be available by the conference date.

Conclusions: In this single-centre study, isolated ASD closure was insufficient in alleviating TR grade to at least mild in 38% of patients with pre-closure moderate to severe TR. If event-free survival is shown to be worse in patients with persistent TR, perhaps offering early device closure or surgical ASD closure and concomitant tricuspid valve annuloplasty/replacement may be of benefit to high-risk patients (i.e., patients older than 65 years old with a RVSP greater than 45 mmHg).

25. DILATATION WITH LARGE BALLOONS OF A MELODY VALVE IN MITRAL POSITION IN A 14KG CHILD WITH TRANS-APICAL ACCESS.

Marinos Kantzis, Suhair Shebani, Sanfui Yong, Saeed Imran
EMCHC Glenfield Hospital, Leicester, United Kingdom

Background: The use of the stented bovine jugular vein graft (Melody™ valve) in the mitral position in children is an off-label treatment option for valve replacement. It is useful as not only it can be implanted in very small annuli but also it may limit pannus formation. Additionally only antiplatelet treatment is sufficient postoperatively, compared to anticoagulation for mechanical valves.

Case Report: We describe a case of Melody™ valve implantation in the mitral position in a three year old girl with Shone's complex who underwent two unsuccessful mitral valve repairs followed by two mechanical valve replacements. Both mechanical valves prosthesis were 19 mm Saint Jude®, placed supra-annular. Within 3 months of each valve placement she presented with signs of valve obstruction. Removal of both mechanical valves revealed pannus formation and secondary thrombus formation, which was impinging the valve mechanism with restricted leaflet motion.

It was felt that further mechanical valve replacement would lead to the same problem. An 18 mm Melody™ valve was implanted surgically as per the technique described by the Boston Group (Shortening and trimming of the valve, creating a wide V shape opening to the outflow). The Melody™ valve was then directly balloon expanded up to 18 mm. The heart resumed activity in complete heart block needing pacing. Later a permanent pacemaker was implanted. The immediate post-operative Echo showed valve length 23 mm with circumferential inner diameter 16mm. The mean estimated inflow gradient through the Melody™ valve was 4 mmHg with no regurgitation or leak. The peak velocity in the left ventricle outflow tract was 1.6 m/sec. During the follow up two paravalvular leaks were documented. Five months after implantation of the valve the child presented with symptoms and signs of right heart failure Echocardiography showed severe leak around the valve and catheter documented pulmonary artery hypertension and elevated left atrial pressure. Due to the small size of the patient and the need for large balloons to dilate the valve, a hybrid approach with trans-apical access was felt to be the best option for balloon dilatation. Valve was gradually dilated up to 24mm with low pressure balloons and paravalvular leak was totally eliminated. Right heart failure signs were reversed, and the patient was discharged after a week in good condition.

Conclusion: In selected patients Melody™ valve should be considered as a treatment option for mitral valve disease in children especially where all other techniques have failed. This technique as described by the Boston Group can be safely performed. Re-adjustment of the valve size to the size of the mitral annulus is mandatory especially when paravalvular leaks are present and transapical access can be helpful to accommodate large balloons for the valve dilatation. This use of the Melody™ valve, is however off-label without long-term follow-up data, and so close follow-up of the patient is needed.

26. BALLOON ANGIOPLASTY OF BIDIRECTIONAL GLENN ANASTOMOSIS.

Amr Matoq¹, Wolfgang Radtke²

¹Alfred I. DuPont Hospital for children, Wilmington, USA. ²Alfred I. DuPont Hospital for Children, Wilmington, USA

Background: The second stage of single ventricle palliation consists of superior cavo-pulmonary anastomosis (SCPA). Two ways to achieve that is Bidirectional Glenn (BDG), or Hemi-Fontan (HF). Stenosis of SCPA can lead to impaired pulmonary blood flow and subsequently hypoxemia. It would also favor right to left shunt via azygous vein if it was not routinely ligated during the SCPA surgery. Balloon dilation of SCPA has been rarely reported among other transcatheter interventions in single ventricle staged palliation. The efficacy and clinical outcomes of this procedure has not been previously reported.

Objective: We aim to assess the safety, efficacy and clinical outcomes of transcatheter balloon dilation of SCPA.

Methods: Retrospective chart review of patients with 2nd stage single ventricle palliation surgery who underwent cardiac catheterization and angioplasty of SCPA (Hemi-Fontan (HF) and/or Bidirectional Glenn (BDG)). We reviewed the following 1) patient's demographics, 2) cardiac diagnosis, 3) SCPA surgical details and post-operative course, 4) Cath hemodynamics, procedural technique, and angiography of each cardiac catheterization, and 4) Follow up cardiac catheterization following SCPA angioplasty.

Results: Between 2008 and 2017, Only 7 patient had significant narrowing of SCPA, and underwent balloon angioplasty. All SCPA stenosis that required balloon angioplasty were BDG. Age at BDG surgery was 3.5 – 11 months, and weight was 5.5 – 8.4 kg. Indications for cardiac catheterizations included persistent pleural effusion, hypoxemia, echocardiographic evidence of BDG stenosis or routine pre-Fontan cardiac catheterization. Stenotic BDG was left sided in 4 and right sided in 3 patients. BDG angioplasty

was done at 6 weeks to 23 months from BDG surgery with patient weight ranging between 7.7 and 13.7 kg. Procedure was successful in all cases with increase in the stenotic diameter from mean of 2.9mm (range; 1.2mm -4.7mm) to mean 4.9mm (range; 2.6mm -7.8mm). All cases had at least 1 follow up cardiac catheterization. Only one case of recurrent stenosis requiring re-angioplasty at 2.3 month follow up with no further recurrence. Sustained results were noted in all other cases up to 29 months of follow up cardiac catheterization. There were increase in average Qp:Qs from 0.5 to 0.6 (before Fontan completion). No adverse events encountered with the angioplasty.

Conclusion: Balloon angioplasty of BDG stenosis is feasible and provide sustained results with rare recurrence of stenosis. Such procedure improves pulmonary blood flow, and help minimizing run off via azygos/hemi-azygos vein and/or veno-venous collaterals.

27. ATHEROSCLEROSIS

Purusharth Kumar Sharma, Ruhs, Jaipur, India

Object: Atherosclerosis is a disease state of heart which act as the base of other disease of heart. so my research work is to dissolve this plaque more efficiently with less side effect and more effectively.

Method: This plaque is majorly formed by cholesterol (LDL) so to dissolve this first we need to decrease the formation this LDL so there is composition of chemical which lead to decrease or stop the formation of LDL in liver after the mevolanate formation as we all know mevalonate is important for us. All receptor will accept this composition first it decrease the formation of vldl and then it start removing the plaque which is already present in the artery wall. It can be given to a patient also who are at the border of having atherosclerosis. also given to a patient who are having sedentary life style.

Observation: The plaque is dissolved with very less side effect like urine colour will change into yellow if given then prescribed dose constipation can occur. Dizziness may occur if dose interval is not maintain.

Cannot given to a patient suffering from asthma and liver cirrhosis

Result: If given in prescribed amount then it will reduce plaque as it is a good lipid lowering agent as it is better than beta blocker and calcium channel blocker and increase synthesis of HDL.

Conclusion: So my research can be used in clinical practice.

28. CLOSURE OF ANACQUIRED IATROGENIC LEFT VENTRICULAR-RIGHT ATRIUM COMMUNICATION WITH AMPLATZER VASCULAR PLUG II DEVICE. CASE REPORT.

Roberto Mijangos Vázquez, Rogelio Hernández Reyes, José Ramiro López Jiménez

Pediatric Specialties Hospital, Tuxtla Gutiérrez, Mexico

Gerbode defect is defined as an abnormal left ventricle-right atrium shunting which may have congenital or acquired origin, representing 0.08% of intracardiac shunts and <1% of the congenital heart diseases. It is classified depending on its position with respect to the tricuspid valve in supra-avalvular, infra-avalvular or intermediate. We report a rare case of a iatrogenic and acquired Gerbode defect in a patient following surgical correction of a partial anomalous pulmonary venous return of the right pulmonary veins to the right atrium. The defect was successfully closed percutaneously with an Amplatzer Vascular Plug II (AVP II) device.

29. CURRENT STATUS OF THE INFRASTRUCTURE OF CARDIAC CATHETERIZATION LABORATORIES IN LOW- AND MIDDLE-INCOME COUNTRIES: DATA FROM THE INTERNATIONAL QUALITY IMPROVEMENT COLLABORATIVE FOR CONGENITAL HEART DISEASE

Nikhil Thatte¹, Isaac Wamala², Lisa Bergersen¹, Mehmet Saluvan¹, Kimberlee Gauvreau¹, Babar Hasan³, Raman Krishna Kumar⁴, Miguel Ronderos⁵, Kathy Jenkins¹

¹Boston Children's Hospital, Boston, USA. ²German Heart Center Berlin, Berlin, Germany. ³Aga Khan University, Karachi, Pakistan. ⁴Amrita Institute of Medical Sciences, Cochin, India. ⁵Institute for Congenital Heart Disease, Fundación Cardioinfantil-Instituto de Cardiología, Bogota, Colombia

Background: Lack of benchmarking data is one of many challenges faced by healthcare professionals in low- and middle-income countries (LMICs) delivering care for children with congenital heart disease (CHD). The International Quality Improvement Collaborative for Congenital Heart Disease (IQIC) has been collecting data for outcomes after surgery for CHD in LMICs since 2007. Attention has not yet been paid towards cardiac catheterization laboratories (CCLs) in LMICs. IQIC has collected data on CCL infrastructure at its participating sites.

Methods: An online survey was administered to all sites participating in IQIC in 2015. Data collection was completed in May 2017. The survey contained dichotomous questions, multiple choice questions, numerical responses and

open-ended free text responses. Sites provided responses about their CCLs regarding general program characteristics including case volumes and type, laboratory space and fixed equipment, image acquisition, storage and retrieval, disposable supplies, manpower and staffing patterns, cost of care as well as perceived limitations faced by the catheterization programs.

Results: 37 out of 42 sites enrolled in IQIC in 2015 responded to the survey. Sites were spread across the Americas (13), Eastern Europe (6) and Asia (18). Median annual case volume was 250 cases [interquartile range 105-328]. 27 sites (73%) used CCLs that they shared with adult acquired catheterization or vascular catheterization teams. Only 9 sites (24%) used biplane fluoroscopy. Re-sterilization and re-use of disposable supplies is common. Although cost of care was a fraction of that in developed countries, financial constraints remained the major hurdle faced by most programs.

Conclusions: Cardiac catheterization for CHD is growing in volume in LMICs. Due to differences in infrastructure availability, improvisations are needed to allow cases to be performed. Benchmarking outcomes data are needed to study CCLs in LMICs systematically, which can then guide quality improvement initiatives addressing needs specific and unique to these settings.

30. GIANT CORONARY ARTERY FISTULA: PRENATAL DIAGNOSIS, NEWBORN MANIFESTATION, PERCUTANEOUS TREATMENT AND ONE YEAR FOLLOW UP

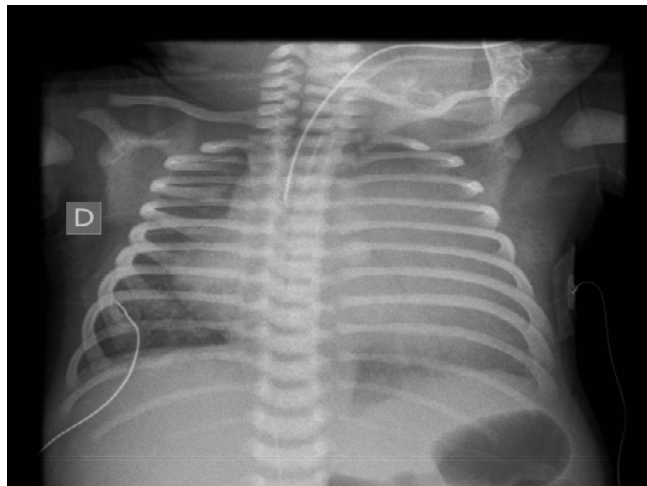
José Luis Alonso^{1,2,3}, Alberto Miguel Sciegata¹, José Luis Pibernus¹, Francisco Comas¹, Tony David Sancan Moran¹

¹Garrahan Hospital, Caba, Argentina. ²J.D. Peron Hospital, Formosa, Argentina. ³Madariaga Hospital, Posadas, Argentina

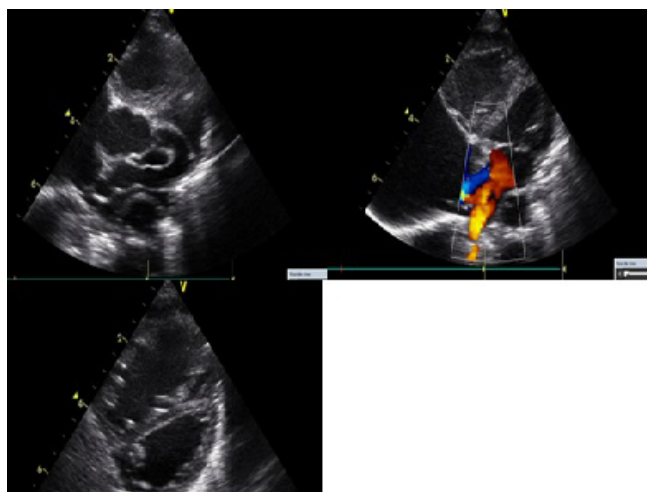
Coronary artery fistulas (CAF) may originate from left, right or both coronary arteries and may drain into any heart chamber.

These are rare forms of congenital heart disease with an incidence of one in 50000 live births. It is postulated that the connection between the coronary system, and a cardiac chamber would be due to the persistence of inter-trabecular spaces, embryonic sinusoids or sometimes coronary artery stenosis. Spontaneous remission rarely occurs (7 to 15%).

A case of a large CAF is presented.



30. Figure 1. X Ray shows severe cardiac enlargement with high pulmonary flow.

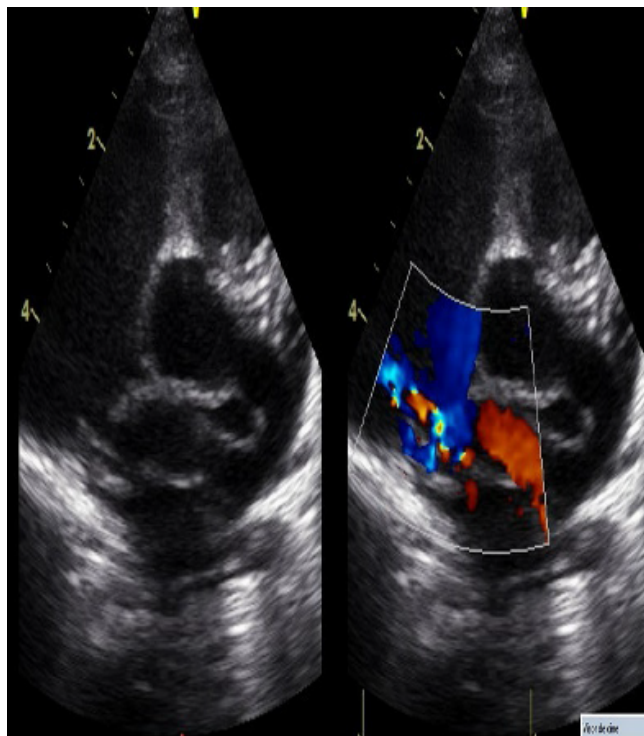


30. Figure 2. Postnatal echocardiography confirmed the diagnosis. Right atrium, and ventricular dilatation with ventricular dysfunction.

Prenatal echocardiography at 27 week of gestation detected an atypical diastolic high flow communication from the ascending aorta (Ao asc) to the right atrium (RA) without signs of ventricular dysfunction during prenatal follow-up.

A female neonate was delivered at 38 weeks of gestation. During first hours of life progressive tachy-/dyspnea developed requiring noninvasive ventilation, oxygen supplementation, diuretics and milrinone.

X Ray shows severe cardiac enlargement with high pulmonary flow (Figure 1).



30. Figure 3. The procedure was done, performing A-V loop through a 4 Fr. Torq Vue catheter (NR), releasing one ADO II 6/4 device from the right side of the CAF.

Postnatal echocardiography confirmed the diagnosis. Right atrium, and ventricular dilatation with ventricular dysfunction (Figure 2).

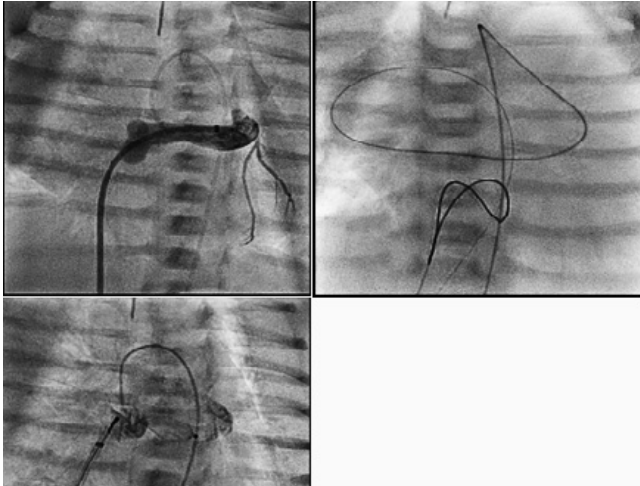
Due to progressive respiratory failure, consequence of a large left-to-right shunt, refractory to medical treatment cardiac catheterization was indicated.

Angiography was performed under general anesthesia at 7 days of life showing a giant CAF arising from the dilated left coronary artery origin. A tunnel-like structure 7- 9 mm diameter, draining into the right atrium, was found amenable for percutaneous closure.

The procedure was done, performing A-V loop through a 4 Fr. Torq Vue catheter (NR), releasing one ADO II 6/4 device from the right side of the CAF (Figure 3).

Anticoagulation and antiplatelet therapy were started immediately after the procedure.

The patient evolved favorably, without cardiac insufficiency, rising normal weight and height in a few months.



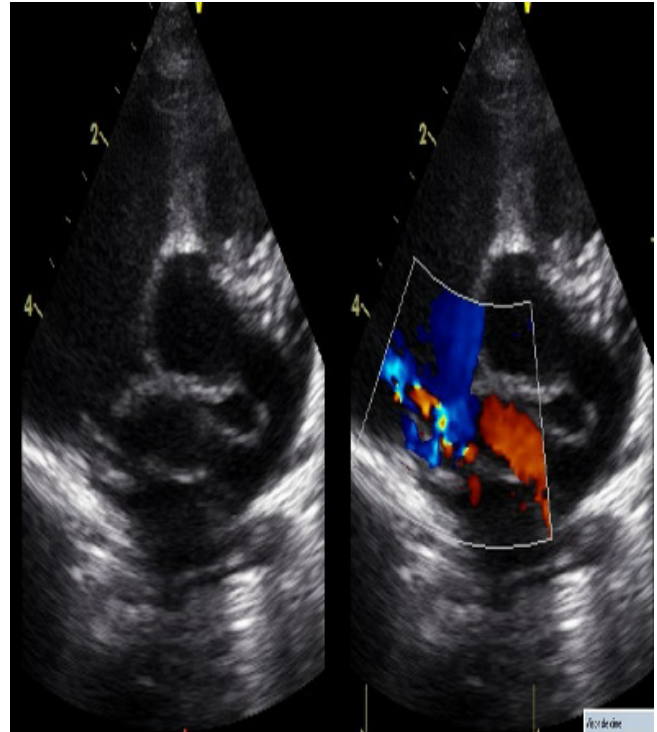
30. Figure 4. The procedure was done, performing A-V loop through a 4 Fr. Torq Vue catheter (NR), releasing one ADO II 6/4 device from the right side of the CAF.

X ray show normal pulmonary blood flow and a better cardiothoracic ratio (Figure 4).

Echocardiogram demonstrated a tiny residual shunt, smaller cardiac chambers and no signs of pulmonary hypertension (Figure 5).

At one year follow up the patient was re- catheterized founding left coronary trunk dilated, CAF totally occluded and normal flow in DA and CX (Figure 6).

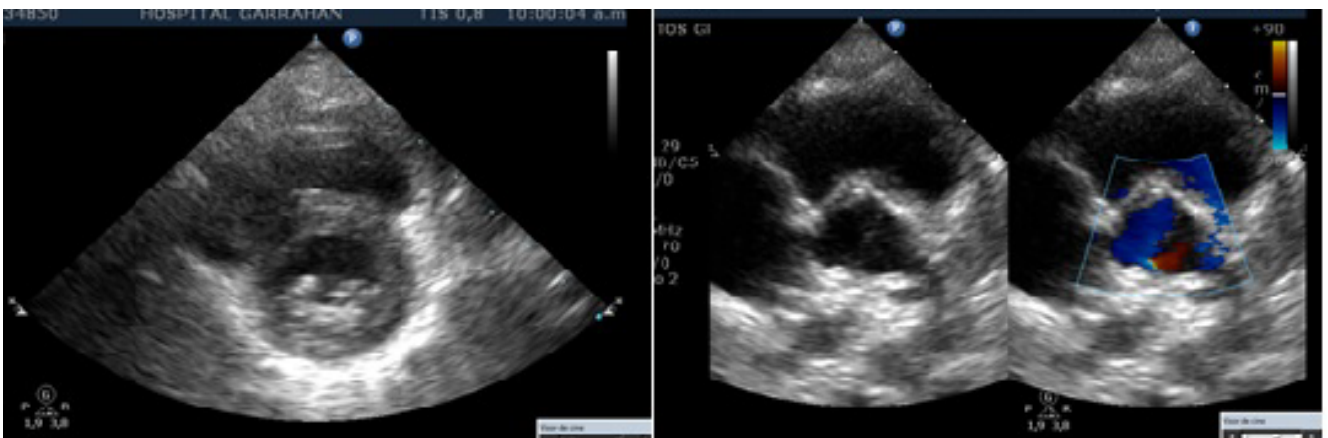
Clinically CAF could manifest with myocardial ischemia resulting from coronary steal or with congestive heart failure due to substantial systemic-to pulmonary shunt. Such early postnatal presentation, due to hemodynamic compromise is extremely rare.



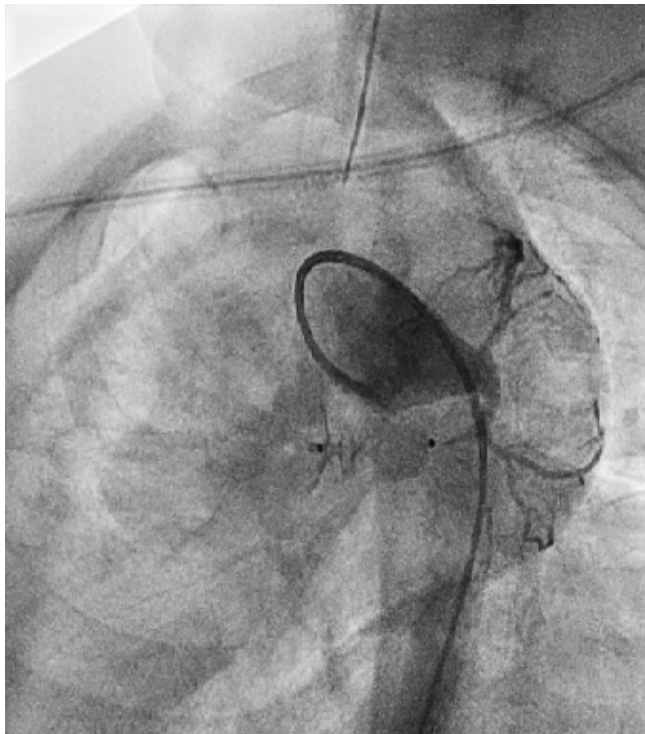
30. Figure 5. Echocardiogram demonstrated a tiny residual shunt, smaller cardiac chambers and no signs of pulmonary hypertension.

Symptomatic patients with CAF must be treated surgically or by transcatheter embolization. In the present case the absence of major coronary collateral vessels arising within the CAF, the unique course of it and the absence of multiple drains favoured percutaneous closure.

The correct prenatal diagnosis by fetal echocardiography, enabled close perinatal follow-up, prompt clinical



30. Figure 6. At one year follow up the patient was re- catheterized founding left coronary trunk dilated, CAF totally occluded and normal flow in DA and CX.



30. Figure 7.

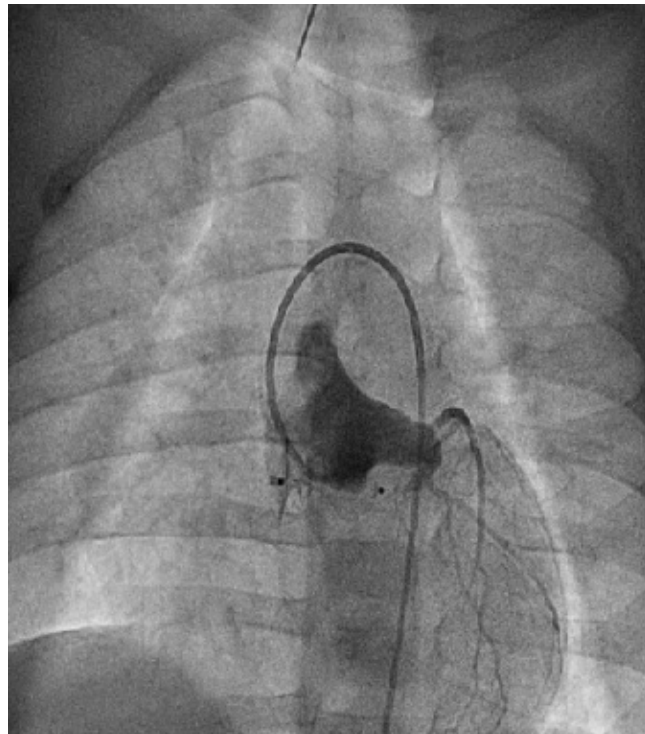
evaluation without delay and optimal management, including early intervention. Percutaneous closure is a valid alternative treatment when the anatomy is adequate.

31. HYBRID TRANSCATHETER PULMONARY VALVE REPLACEMENT WITH A SAPIEN S3 VALVE AFTER PULMONARY ARTERY BANDING VIA LEFT MINI-INTERCOSTAL INCISION

John Serfas, Joe Turek, Gregory Fleming
Duke University, Durham, USA

Background: Many patients with right ventricular outflow tract (RVOT) dysfunction are not candidates for transcatheter pulmonary valve replacement (TPVR) due to dilated RVOT's. Hybrid approaches to TPVR have emerged as an option for patients that are poor candidates for surgical PVR due to comorbidities. We report a hybrid approach to TPVR using a SAPIEN S3 valve through a left anterior mini-intercostal incision.

Case descriptions: Both procedures were performed in a single plane hybrid operating room with trans-esophageal echocardiogram and cardiopulmonary bypass on standby. A 5cm left anterior mini-intercostal incision was performed in the left third interspace to expose the RVOT, and a 14mm wide PTFE band was placed around the proximal



30. Figure 8.

main pulmonary artery (MPA), connected anteriorly with radiopaque hemoclips, and secured to the MPA with two 4-0 prolene sutures. TPVR was performed with an Edwards Lifesciences SAPIEN S3 valve from the femoral vein without pre-stenting.

Case 1: A 58 year old male with Tetralogy of Fallot and history of transannular patch repair presented with severe pulmonary insufficiency and severe exertional dyspnea. He was considered a poor surgical candidate due to severe biventricular dysfunction, and his RVOT was too dilated for TPVR. Following surgical PA banding as described above, balloon sizing with a 25mmx4cm Tyshak II balloon revealed a waist measuring 22mmx24mm. A 26mm SAPIEN S3 valve was implanted without complications with no evidence of insufficiency or stenosis by TEE. He was extubated in the OR, chest tube was removed postoperative day (POD) 2, and he was discharged home on POD 4. At one month follow, he had no significant stenosis or insufficiency of his valve by echocardiogram and dramatic improvement in his symptoms.

Case 2: A 65 year old women with history of congenital pulmonary stenosis status-post surgical valvotomy and subsequent RVOT muscle bundle resection for subpulmonary stenosis presented with severe pulmonary insufficiency and

exertional dyspnea. She was not considered a candidate for surgical PVR due to multiple comorbidities including oxygen dependent obstructive lung disease, pulmonary hypertension, and chronic kidney disease. Her RVOT was too dilated for TPVR and she was referred for hybrid TPVR as described above. A 30mm PTS-X sizing balloon following PA banding revealed a waist measuring 25mmx24mm, and a 29mm SAPIEN S3 valve was implanted with no regurgitation or stenosis by TEE following implant. She was extubated in the OR and discharged home on POD 5 without any complications or adverse events.

Conclusion: Hybrid TPVR with a SAPIEN S3 valve can be performed safely without pre-stenting following PA banding through a left anterior mini-intercostal incision, and can be considered as an alternative to surgical PVR in high risk patients.

32. FIRST CLINICAL IMPLANTATION OF MED-ZENITH PT-VALVE™ IN RIGHT VENTRICULAR OUTFLOW TRACT.

Shu Chen, Xiaoke Shang, Changdong Zhang, Nianguo Dong
Department of Cardiovascular Surgery, Union Hospital, Tongji Medical College of Huazhong University of Science and Technology, Wuhan, China

Background: Transcatheter pulmonary valve replacement (TPVR) is a new, less invasive alternative to surgical valve replacement. We report four successful implantations, first in man, using Med-Zenith PT Valve for patients with severe PR in native right ventricular out flow tract(RVOT).

Method: Patients with native RVOT and severe residual PR were selected on a case-by-case basis according to the anatomical features of the patient and design of the valve. Patient demographics and pre-procedural, intra-procedural, and follow-up data were reviewed.

Result: Four patients(all males) with severe PR (grade 4+) were enrolled in this study with mean age of 31.50 ± 4.43 years. All patients had previous surgery for tetralogy of Fallot (TOF). 3 patients were symptomatic with New York Heart Association(NYHA) heart function III and the other one was NYHA II at baseline. The distal and proximal landing zone in these four patients was 35.5/33.4mm, 23.6/33.4mm, 28.3/33.5mm and 29.4/20.6mm, 4 devices(44mm/36mm/36mm/32mm) were used for these patients respectively. Successful valve implantation was achieved in all four patients. No device malposition, coronary obstruction, reduced flow to the PA branches, or paravalvular leak were noted during the procedures. Mean pulmonary artery diastolic pressure increased from 4.3 ± 1.7 mmHg to 13.5 ± 3.1 mm Hg ($P < 0.05$). In one month's

follow-up, Magnetic Resonance Imaging (MRI) revealed positive RV remodeling with RVEDV volume decreased from 160.8 ± 8.5 ml to 88.0 ± 3.2 ml after intervention ($P < 0.05$) and the mean RVOT pressure gradient was 6.8 ± 1.3 mmHg.

Conclusion: This first in man study demonstrates the initial safety and feasibility of the Med-Zenith PT Valve in the treatment of severe PR.

33. LARGER DEVICES IN SMALL CHILDREN - IS THERE ANY ADVANTAGE? EXPERIENCE IN DEVICE CLOSURE OF ASD IN LESS THAN 2 YEARS OF AGE

Kalyanasundaram Muthusamy
GKNM Hospital, Coimbatore, India

Herein we report successful device closure of large atrial septal defect (ASD) in 115 children with less than 2 years of age over the period of 9 years. The study population age ranged from 8 months to 24 months and the weight ranges from 5.7 to 13.7 kg. Symptomatic children with dilated right heart were taken as criteria for the device closure. The device sizes used in our study group were from 10 mm to 24 mm. We had high rate of successful deployment (98%). All patients who underwent successful device closure tolerated the procedure well without any major complications

Introduction: Device closure of ASD in younger children with larger defects is a challenging one in view of requiring larger sized sheaths and devices and thin pliable rims compare to older children. The size of the defect in young children less than 3 mm, 3 to 8 mm and more than 8 mm are categorized as small, moderate and large sized defects respectively. In our study group we included symptomatic younger children of less than 2 years of age and the ASD size of more than 8 mm for device closure. There were 41 children under 1 year of age. Largest size of 22 mm ASD device was deployed in 1 year old child with weight of 8.6 kg.

Result: Out of 118 younger children taken for the device closure of ASD, 4 children did not undergo the procedure due to failure to position the device. 115 patients had successful device closure

Discussion: We noticed some of the younger children with larger ASDs with adequate rims suitable for device initially progressed to much larger in size than initial size and also rims became inadequate for device closure during the follow up period. Hence we decided to take up younger children with larger ASDs for the device closure. Our initial concern was the haemodynamic instability and vascular complications. But all of our patients tolerated the

procedure well and there were no complications. All the children were followed over the period of 4 years and beyond that if any complication noticed by the parents or family physician.

Conclusion: Device closure of larger ASDs in younger children are feasible, safe and can avoid surgery in the later stage since some of the larger ASDs became unsuitable for the device closure during follow up period.

34. ENDOVASCULAR TREATMENT OF HYPOPLASTIC GOTHIC AORTIC ARCH IN COMBINATION WITH CONGENITAL ABSENCE OF THE LEFT COMMON CAROTID ARTERY

Manolis Pursanov, Mikhail Abramyan, Yurii Shamrin, Aleksei Bedin, Davronbek Pardaev, Ekaterina Kabanova, Elena Petryaykina

Morozov Children's City Clinical Hospital, Russian Federation, Moscow, Russian Federation

Background: A rare clinical case of endovascular treatment of a hypoplastic Gothic aortic arch (AA) with congenital absence of the left common carotid artery (CCA) in combination with ventricular septal defect (VSD) is presented. At the age of 1 year and 1.5 months, transcatheter VSD closure was done using a 8mm Amplatzer Perimembranous Ventricular septal occluder along with balloon dilatation of the AA and the aortic isthmus (AI).

Methods: Retrograde catheterization of the aorta through the left femoral artery with installation of a 9Fr introducer sheath. Through the right internal jugular vein a 5Fr introducer sheath was introduced and an intracardiac electrode placed in the right ventricle for pacing. An exchange length, Amplatz super stiff guidewire (Boston Scientific-City, State) was placed in the aortic root. Over this guidewire 9Fr Mullins sheath (Cook) was advanced to the AA. Then, a Z-med balloon dilatation catheter (NuMED, Inc., Hopkinton, NY) 12x40 mm and was advanced and placed at the aortic hypoplasia zone. Under right ventricular pacing at 200 beats/minute, balloon dilatation was performed in order to determine the localization of its "waist" and to predict stent deployment. At a pressure of 7 atm. the "waist" in the inflated balloon disappeared, and its walls were firmly attached to the walls of the aorta. Subsequently AA stenting was performed. A 36 mm long stent "Intrastent LD Mega" (Bard, city, State) was manually mounted on the same balloon catheter Z-med (12x40 mm). Then, the entire assembly (balloon with the stent mounted on it) was advanced to the area of stenosis. The correct stent position in the AA obstruction area was monitored by contrast injection via side port of the sheath. When the proper stent

position was confirmed, the balloon was manually inflated during rapid right ventricular pacing at 200 beats/minute. At a pressure of 10 atm. complete deployment of the stent was achieved with normalization of the AA geometry. Repeat aortogram showed good result, the stent was fully opened in the AA, with no signs of complications (vessel wall injury). Repeat pressure gradient revealed presence of only 6 mmHg across the area.

Results: The postoperative period was uneventful. A day after the surgery, the arterial pulse in the lower extremities was distinct, the difference in systolic blood pressure between the right hand and leg did not exceed 10 mmHg. Doppler ultrasound after stenting showed restoration of normal blood flow in the abdominal aorta, the SPG across the stent was of 20 mmHg.

Conclusion: We present the first case of successful staged endovascular treatment of complex congenital heart disease – AA anomaly in combination with the absence of the left CCA and VSD. In a number of complex AA anomalies, such as the Gothic arch, stenting is still possible.

35. THE POSTTRAUMATIC DEBAKEY TYPE III AORTIC DISSECTION WITH THE ANEURYSM ISTHMUS DEVELOPMENT: THE FIRST CASE OF SUCCESSFUL ENDOVASCULAR TREATMENT USING THE STENT GRAFT IN TEENAGER.

Manolis Pursanov¹, Mikhail Abramyan^{1,2}, Narek Zakaryan³, Aleksei Bedin¹, Yurii Shamrin¹, Davron Pardaev¹, Ekaterina Kabanova¹, Sofya Purkina¹, Elena Petryaykina¹

¹State Budgetary Healthcare Institution of Moscow "Morozov Children's City Clinical Hospital of Health Department of Moscow", Moscow, Russian Federation. ²Peoples Friendship University of Russia, Moscow, Russian Federation. ³Volynskaya Clinical Hospital, Moscow, Russian Federation

Background: to present the immediate results of a rare clinical case of successful endovascular treatment of acute post-traumatic aortic dissection type III according to DeBakey with development of false aneurysm in the aortic isthmus using Valiant stent graft (Medtronic) in the 15-year-old teenager.

The girl of 15 years old was knocked down by a car. Primary care was provided in the regional children's hospital where the child was taken in serious condition due to multiple fractures and injuries of internal organs and the brain. In a CT scan, the rupture of the thoracic aorta was suspected. The patient was transferred to our clinics on the 10th day after the accident. In repeated CT, pathological dilation of

the aortic isthmus with signs of fenestration and aneurysm formation is visualized in the aortic isthmus area.

Methods: The puncture of the right radial artery (Introducer 5F) and an open section of the left common femoral artery were performed. When aortography revealed aneurysm of the thoracic aorta located at the left subclavian artery outlet level with extension to the descending part of the thoracic aorta. The Captivia delivery system of 22F in diameter was introduced through the femoral artery. The positioning and opening of the Valiant stent graft 22x152 mm was performed with its subsequent dilatation by a Reliant latex balloon. In control aortography, the stent-graft is completely adjacent to the aortic walls, there is no endoleak.

Results: The postoperative period was unremarkable. In echocardiography, the gradient on the aortic isthmus was 13 mmHg. The pulsation on the lower extremity arteries is distinct. Before discharge, a control CT scan was performed: the aneurysm is not detected; there are no signs of dissection. The left subclavian artery is passable however there is a narrowing of its entrance. Extravasal location of contrast was not found.

Conclusion: The rare clinical case about repair of post-traumatic aortic dissection type III with aneurysm development as a result of the road traffic accident using the Valiant stent graft is presented. This is the first case of such surgery performed in the 15 years old teenager.

36. COMPARISON OF ECHOCARDIOGRAPHIC AND ANGIOGRAPHIC MEASUREMENTS USED FOR GUIDING OCCLUSION OF THE DUCTUS ARTERIOSUS: FOCUS ON PRETERM INFANTS

Brian Boe¹, Evan Zahn², Darren Berman¹, Aimee Armstrong¹, Corey Stiver¹, Ruchira Garg²

¹Nationwide Children's Hospital, Columbus, USA. ²Cedars Sinai Medical Center, Los Angeles, USA

Background: Percutaneous occlusion of the patent ductus arteriosus (PDA) has historically been performed using angiographic measurements (aortography) as the primary source for procedural guidance. With the advent of PDA closure in preterm infants and desire to avoid arterial access, there has been an increased reliance on transthoracic echocardiographic (TTE) assessment of PDA in terms of patient selection and procedural guidance. TTE measurements of PDA have not been validated in this setting, i.e. directly compared to angiography.

Methods: The Amplatzer Piccolo™ Occluder clinical study provided for echocardiographic and angiographic

guidance during PDA closure allowing for direct comparison between the imaging modalities. Clinically relevant PDA measurements included ductal length, minimum diameter, and maximum diameter. All enrolled patients who had both an intra-procedural TTE and angiogram were included in this analysis. Patients were separated into cohorts based upon factors such as admission to the neonatal intensive care unit (NICU). PDA measurements were compared between imaging modalities using paired t-test and Bland-Altman analysis for the entire patient population, and for individual cohorts.

Results: The study population consisted of 170 patients, divided into NICU cohort (n=117) and non-NICU cohort (n=53). At the time of PDA closure the NICU cohort had a median (range) age and weight of 5.6 weeks (1.3 - 25.6) and 1.4 kg (0.7 - 5.5), respectively. The non-NICU cohort had a median age and weight of 50.1 weeks (2.1 - 942.1) and 9.1 kg (2.3 - 68.5), respectively. In the NICU cohort, there was good agreement between echocardiographic and angiographic measurements of PDA minimal diameter (mean difference = -0.08 mm, p=0.09). There was less agreement between the two modalities for maximum diameter (mean difference = -0.50 mm, p<0.0001) and length (mean difference = -1.36 mm, p<0.0001). This led to a 2.9% difference in the minimum PDA diameter measurements by TTE and angiography, while the mean TTE ductal length was 12.5% shorter compared to the angiographic measurement. In the non-NICU cohort, there was good agreement between the two modalities for measurements of PDA minimal diameter (mean difference = 0.12 mm, p=0.09) and length (mean difference = -0.78 mm, p=0.06), however, there was less agreement between the two modalities for the maximum diameter (mean difference = -0.88, p=0.002).

Conclusions: On average, TTE measurements of PDA are similar to angiographic measurements but there are some important differences which may be clinically relevant. Notably, in NICU patients, there is good agreement for minimal PDA diameter. However, there is less agreement between the two modalities for ductal length. This may be increasingly important as percutaneous closure becomes more common place in preterm infants as it pertains to both patient selection and procedural guidance. Understanding the relationship between these measurements will be useful in the planning and execution of percutaneous PDA occlusion, particularly in preterm infants.

37. EFFECT OF INTERVENTIONIST'S EXPERIENCE AND VARIATION OF PRACTICE ON LEVEL OF RADIATION EXPOSURE DURING TRANSCATHETER ATRIAL SEPTAL DEFECT CLOSURE.

Younes Boudjemline, Hesham Al-Saloos, Muhammad Dilawar, Reema Kamal, Ziyad M. Hijazi
Sidra Medecine, Doha, Qatar

Background: Radiation exposure during transcatheter ASD/PFO closure has been recently studied. Variations in level of dose had been advocate to be related to multiple factors including patient, x-ray equipment(brand, settings), and interventionist(experience and skills, technical aspects...) factors. Our center has the particularity of having multiple interventionists using a single dedicated cardiac catheterization laboratory. This peculiarity provides a unique opportunity to analyze the effect of interventionist's experience and variation of practice on level of radiation exposure.

Methods: ASD/PFO cases performed between January 2013 and 2019 were respectively reviewed and analyzed. Fluoroscopic time(FT), dose area product(DAP, cGy.cm2), DAP/kg(cGy.cm2/kg), and total air kerma(mGy) were collected .

Results: 237 consecutive patients had attempted of ASD/PFO closure. 15 patients were excluded because level of exposure was not recorded leaving a total of 222 patients for analysis(194 ASD, 28 PFO). 32 patients experienced 39 complications including 19 device missizing(15 successfully closed after changing the device), 9 failures, 8 transient arrhythmias, 2 device embolizations(retrieved by catheterization, 1 ASD successfully closed), one pericardial

effusion (device removed surgically). 10 patients(9 failure, 1 pericardial effusion/erosion) were referred to surgery.

Procedural time (PT), FT, DAP/kg and complications rate were higher in the ASD group(PFO and ASD respectively: 41.3 vs 76.3-min, 6.5 vs 12.5-min, 21.9 vs 62.6-cGy.cm2/kg, and 0 vs 16.6%). There was a great variation in collected parameters amongst interventionists (see table). More experienced interventionists had lower PT, FT, DAP/kg and complication rates. Among two interventionists with the higher experience, the one having focus on keeping level of radiation low had the lowest PT, FT and DAP/kg for both groups (ASD group: mean PT, FT, DAP/kg respectively: 22.3 vs 64.6-min, 1.7 vs 11.5-min, and 0.31 vs 47.46-cGy.cm2/kg). Reasons for lower radiation exposure were: use of low frame rate (4fps), avoidance of cineangiogram, no use of lateral view, no systematic right heart catheterization, limited use of balloon sizing, and use of echo to guide the procedure. Such approach did not negatively impact the success and complication rates.

Conclusions: Interventionist's experience and variation of practice have a major impact on level of radiation exposure. More experienced interventionists have lower PT, FT, DAP/kg and complication rates. At similar experience, interventionists considering radiation as key performance indicator beside success and complication rates had lower level of radiation.

37. Table 1.

	Procedural time(min)	Fluoro time(min)	Air kerma (mG)	DAP cGycm2	DAP/KG cGycm2/kg	Success	Complication	Failure
Interventionist 1 -ASD	113,8	21,9	434,6	6752,0	92,7	90,6%	31,3%	9,4%
Interventionist 2 - ASD	82,5	12,7	402,7	4249,8	72,1	96,3%	9,8%	3,7%
Interventionist 3 - ASD	64,6	11,5	332,1	2990,3	47,5	95,3%	23,3%	4,7%
Interventionist 4 - ASD	22,3	1,7	2,5	11,1	0,3	100,0%	4,0%	0,0%
Interventionist 1 - PFO	56,5	11,4	328,2	3294,3	41,0	100%	0%	0%
Interventionist 2 - PFO	42,1	4,4	235,1	2446,7	31,7	100%	0%	0%
Interventionist 3 - PFO	40,8	6,3	84,6	650,4	8,8	100%	0%	0%
Interventionist 4 - PFO	15,8	1,9	4,0	7,3	0,1	100%	0%	0%

38. ASSESSING THE VALUE OF CORONARY ARTERY COMPUTED TOMOGRAPHY AS THE FIRST-LINE ANATOMICAL TEST FOR STABLE PATIENTS WITH INDICATIONS FOR INVASIVE ANGIOGRAPHY DUE TO SUSPECTED CORONARY ARTERY DISEASE. ECONOMIC OUTCOMES OF THE CAT-CAD RANDOMIZED TRIAL.

Piotr Nikodem Rudziński¹, Mariusz Kruk¹, Cezary Kępa¹, U. Joseph Schoepf², Katharina Otani³, Mariusz Dębski¹, Zofia Dzielińska¹, Jerzy Pręgowski¹, Adam Witkowski¹, Witold Rużyłło¹, Marcin Demkow¹

¹Institute of Cardiology, Warsaw, Poland. ²Division of Cardiology, Department of Medicine, Medical University of South Carolina, Charleston, USA. ³Siemens Healthineers, Tokyo, Japan

Background: Clinical and safety outcomes of the strategy employing coronary computed tomography angiography (CCTA) as the first-choice imaging test in this population have been recently shown in the published CAT-CAD randomized, prospective, single-center study. Based on prospectively collected data we aimed to evaluate economic outcomes and cost-effectiveness of such innovative approach.

Methods: 120 participants of the CAT-CAD trial (age: 60.6±7.9 years, 35% female) were included in the economic analysis. During the diagnostic and therapeutic period we counted crucial medical resources. We prospectively estimated the cumulative cost for each strategy by multiplying the number of resources by standardized costs with accordance to medical database and 2015 Procedural Reimbursement Payment Guide.

Results: The total cost of coronary artery disease (CAD) diagnosis was significantly lower in the CCTA group as compared to the direct invasive coronary angiography (ICA) group (\$50,176 vs \$137,032) with corresponding per-patient cost of \$836 vs \$2,284, respectively. Similarly, the entire diagnostic and therapeutic course was significantly less expensive in the CCTA group (\$227,622 vs \$502,827) with corresponding per-patient cost of \$4,630 vs \$8,380, respectively. Overall, the application of CCTA as the first-line diagnostic test in stable patients with indications to ICA resulted in 63% reduction of CAD diagnosis costs and 55% reduction of the composite of diagnosis and treatment costs.

Conclusions: Application of CCTA as the first-line anatomic test in patients with suspected significant CAD decreased the total costs of diagnosis. This benefit can be achieved by reducing the number of invasive tests and hospitalisations. Economic analysis of the CAT-CAD randomized trial suggests that this approach is cost-effective and

may provide significant cost savings for the entire health systems.

39. PERCUTANEOUS CLOSURE OF PROSTHETIC PARAVALVULAR LEAK : SINGLE CENTER EXPERIENCE

Sitaraman Radhakrishnan, Sushil Azad, Vikas Arya
Fortis Escorts Heart Institute, New delhi, India

Background: Clinically significant Paravalvular Leak (PVL) is an uncommon complication occurring up to 1-3% of patients following surgical valve replacement. Percutaneous device closure represents an alternative to high risk redo surgery which is associated with high mortality of up to 18%.

Aim: To evaluate clinical outcome of patients treated with Percutaneous closure of PVL at an Indian tertiary care center.

Methods: A retrospective analysis of patients who underwent PVL device closure during period of year 2011-2018.

Results: A total of 15 percutaneous closure of PVL procedures were performed in 12 patients. Age range varied from 18- 70 years with 75% male patients. Heart failure was presenting symptom in majority (66%) and palpitation in 8.3% and combination of both in 25%. None of our patients presented with hemolysis. PVL in Mitral position was present in 6 patients and 5 patients had Aortic PVL. One patient was a case of Corrected Transposition of great arteries who had Prosthetic valve in Left AV valve position and presented with PVL. In the entire cohort clinical success was achieved in 91.6%. There was one patient in whom the procedure was unsuccessful and this patient died. There was no significant adverse procedure complication.

Conclusion: Patients with PVL represents a high risk Cohort. Percutaneous PVL closure offers a safe alternative to surgical PVL closure and is associated with less morbidity and mortality.

40. INTERMEDIATE AND LONG TERM FOLLOW UP OF PERCUTANEOUS DEVICE CLOSURE OF FOSSA OVALIS ATRIAL SEPTAL DEFECT BY LIFETECH (HEART R/CERATM) ASD OCCLUDER IN A COHORT OF 302 PATIENTS: OUR EXPERIENCE

Vikas Arya, Sitaraman Radhakrishnan, Sushil Azad
Fortis Escorts Heart Institute, New Delhi, India

Objectives: The aim of present study is to analyze the intermediate and long-term follow up results of percutaneous closure of fossa ovalis atrial septal defect (ASD)

with Lifetech (Heart R/Cera™) ASD occluder in a large cohort of patients including children and adults.

Methods: This was a retrospective review of patients who underwent ASD closure using Lifetech Cera™/Heart R septal occluder between 2007 to March 2019 from a northern Indian cardiac referral center. There were total 302 patients of which 109 (36%) were males and 193 (64%) were females. The median age was 24 years (range 1 - 74 years). Success rate was 100%. The mean device to defect ratio was 1.2 (range 1 to 1.4). There were 18 patients with 2 atrial septal defects and 1 patient with 3 atrial septal defect, of which 10 patients had closure using single device and 8 patients required implantation of 2 separate devices. One patient had 3 defects and complete closure was achieved using 2 device. Immediate closure was obtained in all patients. There were 2 patient with incidence of advanced heart block, one with preexisting bigeminy and other with long Qtc syndrome and after device placement underwent Permanent pacemaker insertion (DDDD), 1 patient had device embolization in immediate post procedure period at day 1 of procedure. 1 patient had anaphylactic reaction at day 2, had ARDS and had to be ventilated for 13days. 1 patient had additional procedure of Balloon pulmonary valvotomy and 10 patients needed elective/post procedure DC cardioversion. Five patients were managed medically for Atrial flutter.

Results: Follow-up data is available for 276 patients (91.3%). Follow up period is from 03 months to 120 months (median 56 months). On follow up, device was in position in all patients, 02 had residual shunt, one additional tiny defect that persisted after 1 year of follow up and other closed off after 3 months of follow up and no evidence of thrombosis. Interventricular septal motion normalized on day of procedure in 79% patients, in 16% over 3 months while flat septal motion persisted in 5% (n=14, all in age group > 35 years) of cases. Symptom-free survival was 92% (254/276) in patients who came for follow up. 5 of 10 patients were in atrial fibrillation (AF) before the procedure and remained in AF on follow up.

Conclusions: Our study showed that percutaneous closure of fossa ovalis ASD with Lifetech (Heart R/Cera™) ASD occluder is a safe and effective procedure on intermediate and long-term follow up in both the children as well as adults. Technical factors during the procedure and proper follow up are important. Our single center intermediate and long term experience in a large number of patients support the use of device closure as an alternative to surgery

41. TRANSCATHETER RETRIEVAL OF THE AMPLATZER VASCULAR PLUG II USED FOR CLOSING PATENT DUCTUS ARTERIOSUS: WHAT IS THE TURNING POINT TO DECIDE THE RETRIEVAL OF THE DEVICE

Naomi Nakagawa, Masahiro Kamada, Yukiko Ishiguchi, Yuji Moritoh, Kengo Okamoto, Noriko Kawata, Tomoya Tsuchihashi

Hiroshima City Hospital, Hiroshima, Japan

Introduction: Use of Amplatzer vascular plug II (AVPII) is feasible for closing certain types of patent ductus arteriosus (PDA). Although flexibility and low profile on account of a thin wire and lack of polyester fabric are benefits of AVPII, it is associated with a higher possibility of instability and migration than Amplatzer duct occluder I (ADOI).

Case 1: A 7-day-old boy weighing 2.6 kg with critical pulmonary stenosis was transferred after an unsuccessful percutaneous transcatheter pulmonary valvuloplasty (PTPV). Systemic circulation had collapsed due to excessive pulmonary flow from a huge PDA. We performed PTPV, PDA closure was also attempted at the same time with an 8-mm, 10-mm, and 12-mm AVPII, respectively. The 12-mm of AVPII caused left pulmonary artery (PA) obstruction, and the 10- mm AVPII caused right PA obstruction; however, a repeated angiography revealed that the PDA size was reduced owing to several attempts to close it and the 8-mm AVPII was successfully deployed without obstructing the right or left PA. A wiggle verified its stability and it was then detached. Although his blood pressure and systemic circulation had stabilized following the PDA closure, his blood pressure suddenly dropped after ten 10 minutes. Fluoroscopy confirmed the dislocation of AVPII into the left PA with the screw located distally. A Berman balloon catheter was used to reverse the direction of the device and the screw was captured by with a 10-mm Goose Neck snare after multiple attempts, and withdrawn into a 5-Fr long sheath.

Case 2: A 12-month-old boy weighing 9.7 kg with tubular PDA (6.6 mm of minimal diameter) was referred. The retention disk of a 10-mm ADOI was too large for his descending aorta. A 12-mm AVPII was deployed because a 10-mm AVPII slipped into the aorta. Although a wiggle verified its stability, the position and the shape of the body changed gradually after detachment. It appeared to be "squeezed out of the PDA." We decided to retrieve the 12-mm AVPII. The screw was immediately captured with a 10-mm Goose Neck snare through the original 5-Fr sheath to prevent embolization. Another Goose Neck snare was inserted through the 8-Fr long sheath into the contralateral femoral artery. The AVPII was released and recaptured through

the 8-Fr sheath. As the screw was hooked at the tip of the sheath, the tip of the sheath was beveled to facilitate screw. The AVPII was retrieved into the sheath at last.

Discussion: As reported, obtaining a better position of the screw using other catheters or wires, switching to the larger sheath, and beveling the tip of the sheath are important tips for retrieval of the device. Moreover, a careful observation of the position and form of the AVPII is essential even after its successful deployment, especially in infants because their PDAs have large extensibility and can expand easily. Its retrieval before the embolization is recommended even if the sign of the deformity and/or displacement is not evident.

42. STENT IMPLANTATION FOR AORTIC COARCTATION IN CHILDREN LESS THAN 6 YEARS OF AGE: INITIAL AND 10 YEARS RESULTS

Basil (Vasileios) Thanopoulos¹, George Tsaousis², Andreas Giannopoulos³, Petros Dardas¹, Vlasios Ninios¹

¹Agios Loukas Clinic, Thessaloniki, Greece. ²Agia Sophia Childrens Hospital, Athens, Greece. ³AHEPA University Hospital, Thessaloniki, Greece

Background: Although stenting has been used as a treatment option for CoA at increasingly younger ages, there is limited information on the long-term follow-up of stent implantation for native CoA in small pediatric patients. This study reports initial and 10-years results following stent implantation for coarctation of the aorta (CoA) in children less than 6-years of age.

Methods: Sixty-three patients with native CoA (NaCoA) (median age 3 years, range 1–5.5 years) underwent stent implantation (SI) using PG2910B and ev3 stents. Bench testing of the stents was performed to determine the smallest sheath diameter that is required for their use. Patients with hypoplasia of the proximal aortic isthmus or transverse aortic arch were excluded from the study.

Results: The PG2910B (51–81%) stents were crimped on a 6–8 mm balloon (PTA, Bard, USA) and implanted through a 6 sheath. The stents were further dilated to a larger diameter using 10–12 mm balloons that were introduced through a 7 sheath. The ev3 stents (12–6.3%) (patients \geq 5 years of age) were crimped on a 10–12 mm balloon and introduced through a 8 sheath. Immediately after stenting the peak systolic pressure gradient fell from 68 ± 16 mmHg to 8 ± 5 mmHg ($p < 0.05$), while CoA diameter increased from 5 ± 3 mm to $16. \pm 3$ mm ($p < 0.05$). 21 (31%) patients with an arm/leg pressure gradient \geq 20 mm Hg underwent successful stent re-dilation 4 to 8 years after the initial procedure for

a relative to growth stenosis. After re-dilation peak systolic pressure gradient was reduced from 30 ± 5 mm Hg (25 to 38 mm Hg) to 5 ± 3 mmHg (range 0 to 8 mmHg). There were no major procedural complications. Late aneurysm formation and stent fracture that required a new stent implantation were observed in 2 and 3 patients, respectively. At the end of follow-up no cases of coarctation were identified on angiography, or MSCT. Fifty – eight (92%) of the patients were normotensive at the end of follow – up period.

Conclusions: Stent implantation is an effective and safe alternative to conventional surgical management for the treatment of selected pediatric patients with CoA.

43. FEASIBILITY OF THREE-DIMENSIONAL ROTATIONAL ANGIOGRAPHY IN INFANTS AND CHILDREN LESS THAN 10KG

Marisha McClean, Konstantin Averin, Yashu Coe, Cameron Seaman

University of Alberta, Edmonton, Canada

Background: Cardiac catheterization is an important tool in the management of congenital heart disease (CHD) with angiography being essential for diagnosing and treating cardiovascular lesions. Fixed plane 2-dimensional conventional angiography (CA) has traditionally been the main modality of image acquisition. CA has limitations when applied to complex 3-dimensional structures. 3-Dimensional Rotational Angiography (3DRA) can more accurately define cardiac anatomy through multiplanar reformatting and help determine optimal angles for subsequent CA. Rapid ventricular pacing during acquisition allows for reduced contrast volume and improves image quality but for right heart imaging 3DRA has traditionally required a second venous sheath for placement of a pacing catheter. Due to the known risk of vascular injury in small children we modified our approach to require the use of only 1 venous sheath. The aim of this study was to review and describe our institutional experience with 3DRA in infants and children less than 10kg.

Methods: Retrospective review of pediatric patients less than 10 kg who underwent 3DRA at our institution between 2016 - 2018. In cases where right heart 3DRA was performed, a single 5 or 6 Fr venous long sheath was advanced to the right ventricle (RV), through which a 4 Fr pacing catheter was positioned in the RV apex. 3DRA was performed with a 5 second injection of contrast via the sheath into the RV and simultaneous RV pacing.

Results: Fifty-one patients underwent successful 3DRA. There were 21 males (41%), mean age 8.9 ± 6.5 months and

mean weight 6.9 ± 2.0 kg. Eleven (21%) had single ventricle anatomy. Eight patients had left sided lesions and required venous access for pacing only. Forty-three patients had 3DRA for right sided lesions; 2 venous sheaths were placed in 11 (26%) while the rest (32, 74%) had one venous sheath. The mean contrast volume for 3DRA was 1.6 ± 0.5 mL/kg, while total procedural contrast volume was 4.9 ± 1.9 mL/kg. The mean DAP to acquire a 3DRA was 64.1 ± 40.2 uGy. m2. Total mean DAP per case was 1041.8 ± 796.1 uGy. m2. Thirty-six (71%) cases were interventional: LPA stent/angioplasty in 13 (36%), RPA stent/angioplasty in 8 (22%), conduit stent in 5 (14%), coarctation angioplasty in 5 (14%), 1 (3%) pulmonary valvuloplasty and 4 (11%) underwent multiple interventions (combined conduit and branch PA angioplasty, SVC and RPA angioplasty and combined LPA and BT-shunt stents). There were no complications related to 3DRA acquisition and no evidence of peripheral access complications. There were 5 (10%) complications related to intervention which were all managed conservatively (3 pulmonary hemorrhages, 1 RPA aneurysm and 1 intrastent thrombus).

Conclusion: To our knowledge, this is the first report describing the safety and feasibility of 3DRA in small children less than 10kg. 3DRA for right sided lesions can be performed using a single venous long sheath for both simultaneous angiography and RV pacing to minimize the risk of peripheral venous thrombosis.

44. THREE-YEAR OUTCOMES FROM THE HARMONY NATIVE OUTFLOW TRACT EARLY FEASIBILITY STUDY

Lee Benson¹, Lisa Bergersen², Matthew Gillespie³, Brian McHenry⁴, John Cheatham⁵

¹Hospital for Sick Children, Toronto, Canada. ²Boston Children's Hospital, Boston, MA, USA. ³Children's Hospital of Philadelphia, Philadelphia, PA, USA. ⁴Medtronic, Mounds View, MN, USA. ⁵Nationwide Children's Hospital, Columbus, OH, USA

Background: The Harmony transcatheter pulmonary valve (TPV) was designed to treat pulmonary valve regurgitation (PR) occurring during follow-up after surgical repair of right ventricular outflow tracts (RVOT).

Methods: The Native TPV Early Feasibility Study (EFS) is a prospective, multicenter, non-randomized feasibility study designed to evaluate the Harmony TPV device in 20 patients. Here we report 3-year follow-up clinical, echocardiographic, and CT outcomes.

Results: Of 20 implanted patients, 17 completed 3-year follow-up (max: 4.1 y). There were no deaths but 2 early explants (previously reported). One patient did not

complete a 3-year visit. In remaining patients with available 3-year echo data, paravalvular leak (PVL) was mild in 1 patient and no/trace in the remainder; PR was mild in 1 patient and no/trace in the remainder. The 3-year mean RVOT gradient was 15.7 ± 5.5 mm Hg. No significant frame fractures were identified via radiography. Two patients required catheter reintervention due to development of significant outflow tract obstruction; subsequently, a follow-up CT scan was obtained (n=16) 3.2 ± 1.5 months after the index procedure. The degree of luminal loss (intraluminal in-growth) was compared to the immediate post-implant scan at 3 predesignated frame locations and averaged (median [Q1,Q3] of 20% [11,34] inflow, 9% [-1, 14] valve housing, and 19% [12, 31] outflow), excluding the 2 patients with catheter reintervention.

Conclusions: The 3-year results from the Native TPV EFS demonstrate consistent valve function without moderate/severe PVL, PR or valve stenosis, and a stable Harmony TPV frame without significant frame fractures. (as presented at SCAI.2019)

45. PERCUTANEOUS TREATMENT OF ASCENDING AORTA OBSTRUCTION AFTER ORTHOTOPIC HEART TRANSPLANTATION USING A PRE-MOUNTED STENT

Konstantin Averin, Paula Holinski, Darren Freed, Jennifer Conway, Simon Urschel, Angela Bates, Cameron Seaman
Stollery Children's Hospital, Edmonton, Canada

Background: Treatment of typical juxtaductal coarctation and/or aortic arch hypoplasia is often undertaken via a percutaneous approach. Lesions involving the ascending aorta (AAo) have traditionally required surgical repair.

Objective: To describe a novel percutaneous approach to AAo obstruction via stent angioplasty.

Methods: 14 month old male with Shone's complex status post multiple surgical palliations who underwent orthotopic heart transplantation 4 weeks prior for persistent left heart obstruction and secondary pulmonary arterial hypertension. Post-transplant he had a persistent inotropic requirement and needed high-dose diuretics to maintain euvolemia. An echocardiogram raised suspicion for AAo obstruction. He underwent cardiac catheterization and was found to have severe AAo obstruction with a peak systolic ejection gradient (PSEG) of 45mmHg and angiographic narrowing to 6mm (normal aortic dimensions 8-9mm). He was deemed to be a poor surgical candidate given the previous 5 sternotomies so a percutaneous approach was undertaken. A 0.018" Steelcore guidewire was positioned in the LV apex. Balloon stability was extremely challenging

so right ventricular (RV) pacing was utilized during angioplasty. Balloon angioplasty was performed with a 9mm x 3cm Sterling balloon. Angioplasty was technically successful but did not result in any improvement in the lesion. Stent implantation was undertaken. The Steelcore wire was exchanged for a 0.018" SV5 guidewire for additional support. The 4 Fr short sheath was exchanged for a 5 Fr x 45 cm Flexor sheath which was positioned in the transverse arch. A test inflation with an 8mm x 2cm Sterling balloon was performed to ensure system stability prior to stent deployment. An 8mm x 12mm Formula 418 stent was then deployed in good position. The stent was post-dilated with a 9mm Sterling balloon to match the normal aortic diameter.

Results: The residual PSEG was 14mmHg. Post-procedure the patient weaned off all support and was discharged home 4 weeks later. He is on aspirin for 6 months.

Conclusion: To our knowledge this is the first report of percutaneous treatment of AAO obstruction via stent implantation in pediatrics. Percutaneous relief of AAO obstruction may be feasible utilizing rapid RV pacing to optimize stent stability.

46. INTENTIONAL BIOPROSTHETIC TRICUSPID VALVE FRACTURE TO FACILITATE TRANSCATHETER VALVE IN VALVE DEPLOYMENT

Brian Karahalios¹, John Breinholt², Stephen Little³, Chun Lin³

¹Houston Methodist, Houston, USA. ²Memorial Hermann Hospital, Houston, USA. ³Houston Methodist DeBakey Heart and Vascular Center, Houston, USA

While transcatheter valve-in-valve implantation may reduce the number of lifetime surgical reinterventions in some patients with congenital heart disease, in other patients the bioprosthetic valve ring can lead to patient-prosthesis mismatch due to reduction of internal diameter if a transcatheter valve is implanted. Intentional valve ring fracture during valve-in-valve implant has emerged as a solution for these patients, however, use of this technique in a bioprosthetic tricuspid valve has not been reported in adult patients. We report successful bioprosthetic tricuspid valve fracture and valve-in-valve implant in a 49 year old woman who presented with stenosis of a #29 valve. At the time of intervention, initial predilation valvuloplasty demonstrated an internal diameter of 22mm, suggesting that a conventional valve-in-valve implant would induce patient-prosthesis mismatch. As a result, the valve ring was intentionally fractured with a 28mm non-compliant balloon at high pressure followed by implantation of a 29mm transcatheter valve. Final imaging demonstrated

successful expansion of the valve stent frame between 26.5-28mm in diameter and no AV block or compression of the coronaries. To our knowledge this is the first report of successful intentional tricuspid bioprosthetic valve fracture and valve-in-valve implant in an adult patient.

47. TORQUE DEVICE SUTURE TECHNIQUE TO ACHIEVE HEMOSTASIS IN LARGE-BORE VENOUS ACCESS

Brian Karahalios¹, Stephanie Fuentes Rojas¹, Rahul Singh¹, Miguel Chavez Cavazos¹, Ponraj Chinnadurai², Chun Lin³

¹Houston Methodist Hospital, Houston, USA. ²Siemens Medical Solutions, Hoffman Estates, USA. ³Houston Methodist DeBakey Heart and Vascular Center, Houston, USA

Objectives: To describe and compare a novel technique using a torque device to manage figure-of-eight suture tension for venous access hemostasis in patients who have undergone atrial septal defect (ASD) or patent foramen ovale (PFO) closure.

Background: Large bore venous access has become increasingly important in transcatheter procedures, but management of hemostasis can be time-consuming and/or resource intensive. As such, various techniques have sought to provide cost effective and safe alternatives to manual compression. We describe a modification of the figure-of-eight suture technique wherein we apply a torque device to manage variable suture tension instead of tying a knot and compare it to the standard figure-of-eight suture technique.

Methods: We performed a retrospective study of 40 consecutive patients who underwent ASD or PFO closure, 20 of whom underwent standard figure-of-eight technique and 20 of whom underwent figure-of-eight with torque device modification. Bleeding Academic Research Consortium (BARC) definitions were used to categorize bleeding events.

Results: The groups were similar in age, gender, weight, aspirin use, platelet count, and INR. Standard figure-of-eight suture had seven patients with bleeding, with six classified as BARC II and one as BARC I. Figure-of-eight plus torque device had three patients with bleeding, with two classified BARC II and one as BARC I. There were no incidences of hematoma in either group.

Conclusion: The torque device suture technique is a safe and effective modification of the figure-of-eight suture technique. In addition, the modification allows secure and variable suture tension as well as easy removal by nursing staff

48. PERCUTANEOUS TRANSCATHETER CLOSURE OF A MASSIVE PULMONARY ARTERIOVENOUS FISTULA IN A NEWBORN.

Alberto Zarate, Iñaki Navarro, Ramon Minguet, Jorge Robles Izsste, Mexico, Mexico

Pulmonary arteriovenous fistulas (PAVFs) is a rare cause of cyanosis in the newborn. Only 17 cases of newborn pulmonary arteriovenous fistula have been reported. The etiology of this disorder is unknown. Typical signs at presentation include cyanosis, murmur, and congestive heart failure. Large PAVFs produce symptoms and predispose to serious complications and hence require early treatment. Imaging plays a very major role in the pre-operative diagnosis of these conditions, included chest x-ray in which are common findings: cardiomegaly, oligemia, and focal pulmonary density. Surgical resection was the only treatment available till the introduction of interventional procedures. Since then, transcatheter embolotherapy with coils and vascular plugs have become the treatment of choice in most of the centers

The patient was a 38-week product of a pregnancy complicated by intrauterine growth retardation. He was delivered by emergency Cesarean section for fetal distress. Was admitted to the NICU because of antenatal diagnosis of a pulmonary arteriovenous fistula. After 24 hrs the patient revealed profound desaturation, 75% and respiratory distress, phase II ventilation mode was needed. Deep cyanosis and a harsh grade 6/6

Initial chest x ray showed mild vascular oligemia. An opacity in the left upper lobe. The initial echocardiographic examination confirm a large pulmonary arteriovenous fistula near the descending aorta. CT revealed an aneurysmal fistula emerging from the left pulmonary artery. Cardiac catheterisation was performed, Cardiac catheterization showed normal pressures except for a low diastolic pressure in the pulmonary artery. Selective pulmonary angiograms confirmed the diagnosis, showing a direct communication

from the left pulmonary artery to the left atrium, an the aneurysmal pouch size was 2 x 1.9cm. Through 4 Fr catheter we delivered an Amplatzer PDA II-AS 3-4 to occlude the fistula. An angiogram subsequent to release of the occluder revealed the complete closure of the fistula, with disappearance of the aneurysmal pouch. The newborn was discharged home four days after the procedure. Six months after the procedure, he is in perfect condition, with normal echocardiographic findings

49. STENT IMPLANTATION FOR TREATMENT OF BRANCH PULMONARY ARTERY AND ANASTOMOSIS STENOSIS IN CHILDREN WITH UNIVENTRICULAR HEARTS

Lei Yang, Ying Guo, Tingliang Liu, Wei Gao, Meirong Huang, Yibei Wu, Xinyi Xu, Xu Zhang

Department of Cardiology, School of Medicine, Shanghai Jiao Tong University, Shanghai, China

Objective: Patients with single-ventricle physiology pose a wide variety of therapeutic challenges. Pulmonary artery or anastomosis stenosis in single-ventricle physiology will have only subtle hemodynamic derangements due to the lack of the pumping chamber to force blood across the stenosis. This study aimed to evaluate the feasibility and usefulness of the stent implantation for treatment of branch pulmonary artery and anastomosis stenosis in children with univentricular hearts.

Methods: Retrospective analysis of 8 implanted stents between March 2014 and January 2015 in Shanghai Children's Medical Center. Transthoracic echocardiography, chest roentgenography and electrocardiography were carried out as follow-up studies at the second day after operation and 1, 3, 6, 12 months after the procedure.

Results: In all of eight patients (6 males and 2 females), 5 cases were post-Glenn operation and 3 cases were post-Fontan operation. The median age was 6.6 years (range 4.0-8.5 years). The median weight was 19.5 kg (range 13.8-25.6 kg). 9 stents were implanted successfully in all patient, 6 in left pulmonary arteries, 2 in right pulmonary arteries and 1 in anastomosis. All stents were placed in the target lesion without any complication. The diameter of the narrowed segment improved from (3.63 ± 2.06) mm to (7.89 ± 1.62) mm ($P < 0.01$). During follow-up, no other complication occurred except thrombus in one patient because of discontinuation anticoagulation.

Conclusion: Branch pulmonary arterial stenosis in single-ventricle patients may often be underestimated due to the low pressure venous system and/or the development of venovenous collaterals bypassing and decompressing the pulmonary circuit. In these patients, even mild stenosis should be treated aggressively, especially in the presence of pleural effusions, pericardial effusions, protein-losing enteropathy and low-output states. Stent implantation is an effective method of treating branch pulmonary artery stenosis.

50. THREE CASES OF SUCCESSFUL TRANSCATHETER REHABILITATION TO PULMONARY ARTERIES IN MAJOR AORTOPULMONARY COLLATERAL ARTERIES WITH DIMINUTIVE PULMONARY ANTEGRADE FLOW

Mizuhiko Ishigaki, Sung-Hae Kim, Keisuke Sato, Jun Yoshimoto, Norie Mistushita, Masaki Nii, Yasuhiko Tanaka
Shizuoka Children's Hospital, Shizuoka, Japan

Background: Major aortopulmonary collateral artery (MAPCA) with diminutive pulmonary artery (PA) is a complex and rare form of congenital heart disease. The most important consideration in this disease is how to facilitate pulmonary arterial growth. Generally, a surgical strategy involving unifocalization of the MAPCAs or rehabilitation of the native PA by systemic-pulmonary artery shunt is used. We report three rare cases of complete transcatheter rehabilitation of the native PA without surgery in patients with MAPCAs and diminutive pulmonary antegrade flow, using balloon valvuloplasty (BVP) for pulmonary valve or right ventricular outflow tract (RVOT) stenting and embolization of MAPCAs.

Case Series

Case 1: The patient was a three-month-old boy weighing 5.1kg diagnosed with double outlet right ventricle, subarterial (doubly-committed) ventricular septal defect, pulmonary valve stenosis involving a diminutive tethered pulmonary valve (diameter: 3.7 mm, z score: -6.4), right aortic arch, and 5 MAPCAs.

Case 2: The patient was an one-month-old boy weighing 3.0kg diagnosed with tetralogy of Fallot, subarterial ventricular septal defect, pulmonary valve stenosis involving a diminutive tethered pulmonary valve (diameter: 3.7 mm, z score: -5.5), and 4 MAPCAs.

Case 3: The patient was a two-month-old girl weighing 3.9kg diagnosed with double outlet right ventricle, perimembranous ventricular septal defect, pulmonary valve and subpulmonary stenosis involving a diminutive tethered pulmonary valve (diameter: 3.5 mm, z score: -7.4), right aortic arch, and 4 MAPCAs.

All patients required intervention for severe cyanosis in early infancy. To increase pulmonary blood flow, we selected BVP in former 2 cases of subarterial ventricular septal defect and RVOT stenting in latter 1 case of perimembranous ventricular septal defect. A series of interventions with BVP or RVOT stenting and embolization of MAPCAs were performed to promote native PA

growth and maintain SaO_2 without any complications. After growth from a diminutive PA to an appropriately sized PA (Nakata index; Case1:49→137, Case2:49→229, Case3:154→352 mm^2/m^2), all patients received complete repair without any surgical PA rehabilitation strategies. The postoperative courses were uneventful, and echocardiography indicated acceptable right ventricular pressure.

Conclusion: This strategy can be a useful option as a bridge to definitive repair for this particular patient group, and therefore palliative surgery in early infancy, which is associated with a relatively high mortality, can be avoided. The important factor in this strategy is a sufficient dual supply from the native PA and the MAPCAs.

51. PATENT DUCTUS ARTERIOSUS CLOSURE USING OCCLUTECH DUCT OCCLUDER ;SOHAG UNIVERSITY HOSPITAL EXPERIENCE, EGYPT

Safaa Ahmed¹, Amal EL Sisi²

¹Sohag University Hospital, Sohag, Egypt. ²Cairo-university, Cairo, Egypt

Aim: To evaluate our experience in percutaneous transcatheter closure of patent ductus arteriosus (PDA) with the Occlutech duct occluder (ODO) .

Methods: It was a prospective study to evaluate efficacy and safety of the Occlutech duct occluder as a new device in our hospital for transcatheter closure of PDA in 43 patients. All consecutive patients receiving an Occlutech® PDA occluder for closure of PDA from May 2017 to April 2019 were included in the study. Occluders were implanted using a conventional technique. Residual shunting, adverse events and mid-term outcomes were assessed and reported.

Results: All patients (43) underwent to successful ODO implantation. The median patient age was 2 years (range, 5months-25 years). The patient weight was 10 Kg (range,6-65Kg) . PDAs were of type A (n = 37), type E (n = 8) . The median narrowest PDA diameter was 3.4mm (1.9-8mm). Median procedure time was 65 min (range, 47-110 min). Median fluoroscopy time was 6.9 min (range, 4.5-16 min). The device diameter (pulmonary end) was 7mm (range,6-15mm). The standard shank length was used in 36 cases, and the long shank was used in 7 cases. Median follow-up period was 18 months. All devices were successfully implanted. Total occlusion was achieved the following day in 40 /43 (93%), but three patients (7%), in whom it was confirmed one week later on echocardiography . No major adverse events occurred. Mild Aortic disc bulging occurred in one patient without hemodynamic consequences.

Conclusion: Our results with the ODO show that transcatheter closure of PDA is safe and effective with good mid-term outcomes. Long shank device should be evaluated in large series of patients with large and long PDA

Keywords: Patent Ductus arteriosus. Closure, Occlutech Duct Occluder.

52. SUCCESSFUL IMPLANTATION OF A PULMONARY ARTERY CONDUIT ENGINEERED WITH WHARTON'S JELLY-DERIVED MESENCHYMAL STEM CELLS IN A PRE-CLINICAL PORCINE MODEL OF TETRALOGY OF FALLOT CORRECTION.

Dominga Iacobazzi, Ambra Albertario, Filippo Rapetto, Mohamed Ghorbel, Massimo Caputo

University of Bristol, Bristol, United Kingdom

The material available for pulmonary valve and RVOT reconstruction in paediatric Tetralogy of Fallot repair come with the severe limitation of long-term degeneration, causing right ventricular dysfunction, aneurysm formation and arrhythmias, thus necessitating several high-risk reoperations throughout patients' life. Hence, alternative approaches for the RVOT reconstruction, which meet the requirements of biocompatibility, non-immunogenicity and ready availability of an ideal scaffold, are needed.

By combining the use of autologous Mesenchymal Stem Cells (MSCs) derived from the inner gelatinous portion -Wharton's Jelly (WJ_MSCs)- of the umbilical cord, and naturally occurring scaffold, we aimed to create WJ_MSCs-engineered pulmonary artery conduit that could potentially remodel, repair and grow alongside the children's growth, eradicating the current limitation of the need for additional surgeries.

WJ_MSCs were phenotypically and functionally characterised by flow cytometry and their multipotency capacity respectively. We confirmed that the typical MSCs immunophenotype and genetic stability is retained throughout passages.

In addition, we have optimized the cell culture and growth onto a naturally occurring extracellular matrix (ECM) scaffold (CorMatrix®), where WJ_MSCs exhibit a great capacity to engraft and synthesize their own extracellular matrix, under static and dynamic (bioreactor) culture systems.

The obtained WJ_MSCs engineered conduit has been safely implanted into a new piglet model lately developed by our group, in order to reproduce the clinical scenario of Tetralogy of Fallot/pulmonary atresia surgical correction

in infants, consisting of pulmonary artery and RVOT reconstruction. Preliminary data show that at 6 months follow up, the cellularised conduit was patent with no stenosis, rupture, or deformation. Echocardiography revealed a normal blood flow through the main pulmonary artery, and comparable blood velocity was detected via Doppler before the graft implantation and at the time of explant. Post mortem histological assessment shows a good integration of the conduit, which has been completely repopulated by autologous cells and newly synthesized extracellular matrix component, with no detected sign of calcification.

Our study indicates that the addition of WJ_MSCs to the ECM scaffold can upgrade the material, converting it into a living tissue, with the potential to grow, repair and remodel the youngest hearts. These results might pave the way to new modalities for effective surgical restoration of pulmonary artery and RVOT function in TOF patients.

53. PILOT STUDY ON IRON BIOABSORBABLE STENT (IBS) IMPLANTATION IN DUCT-DEPENDENT PULMONARY CIRCULATION

Marhisham Che Mood¹, Mazeni Alwi¹, Hasri Samion¹, Koh Gee Thiong²

¹National Heart Institute, Kuala Lumpur, Malaysia. ²Hospital Serdang, Serdang, Malaysia

Palliation with Blalock Taussig shunt (BTS) in complex cyanotic congenital heart disease (CHD) has significant morbidity and mortality. Patent ductus arteriosus (PDA) stenting has advantage in term of morbidity and ICU stay. Branch pulmonary artery (PA) stenosis is common in these patients because of the site of PDA connection. Use of Bare Metal Stent (BMS) in the PDA may aggravate this stenosis and pose challenges at surgical repair.

Objective: Pilot study to investigate the feasibility, safety and efficacy of iron bioabsorbable stent (IBS, Lifetech inc.) implantation in PDA.

Methods: Inclusion criteria- only patients with simple PDA morphology (straight and relatively short), weight > 2.5kg and age < 3 months and no family history of iron disorders. Preliminary echocardiography, serum iron study and angiography were performed. Ductal stenting was performed by femoral artery route or transvenous route following balloon dilation. Ease of implant and X-ray visibility was compared to BMS. Aspirin and later clopidogrel were started before discharge. Assessment by clinical examination, echocardiography, CXR and iron studies were performed at 1 month and later 3 monthly follow-ups. End points were death or re-interventions before 9 months.

Results: Between September 2018 to April 2019, 7 patients were recruited till date, 5 with pulmonary atresia intact ventricular septum (PAIVS) and 2 with critical pulmonary stenosis. The mean age was 29 days and mean weight was 3.2 kg. No procedural related mortality. The X-ray visibility and ease to implant was similar to cobalt-chromium BMS. Patients generally demonstrated features of overshunting early post procedure with 1 requiring surgery for necrotizing enterocolitis but all were discharged well. 1 mortality at 1 month post discharge for viral illness. Normal serum iron study was documented before procedure and on regular follow-ups. The longest follow up was 7 months in a patient with PAIVS, where surgery was performed for severe residual right ventricular outflow obstruction and occluded IBS stent.

Conclusion: Early results showed that IBS implantation is safe, feasible and efficacious in simple PDA. Longer term results await study completion. Positive results would encourage wider study with application to more complex PDA morphology.

54. A NOVEL COMPLETELY BIODEGRADABLE OCCLUDER FOR VENTRICULAR SEPTAL DEFECT CLOSURE: INITIAL EXPERIENCE AND EARLY FOLLOW-UP RESULTS

Xiangbin Pan, Long Chen, Wenbin Ouyang, Fengwen Zhang
Department of Cardiovascular Surgery, National Center for Cardiovascular Disease, China & Fuwai Cardiovascular Hospital, Chinese Academy of Medical Sciences & Peking Union Medical College, Beijing, China

Background: Bioabsorbable occluders may circumvent the long-term complications associated with metallic occluders for VSD closure. Thus far, some partial bioabsorbable occluders have been studied in vivo, and the non-absorbable parts yielded new complications.

Objectives: To assess effectiveness and safety of a novel completely bioabsorbable VSD occluder before endothelialization.

Methods: From February to June 2018, five patients were recruited (mean age 8.74 ± 3.02 years) for periventricular VSD closure under echocardiography guidance with a completely bioabsorbable occluder. The occluder consists of a "double-umbrella" polydioxanone (PDO) framework, poly-L-lactic acid (PLLA) fabric and a built-in shape line designed to improve shaping problem. Patients were followed up at 1 months, 3 months, and 6 months after closure. The degradation of occluder was measured using QLAB quantitative analysis software and Integrated backscatter technique.

Results: All patients underwent successful VSD closure in 59 ± 11 minutes and had postoperative hospital stay of 3 ± 1.41 days, without residual shunt, hemolysis, aortic valve regurgitation, or arrhythmia occurrence. After 6 months follow-up, the density of left disc decreased from 170.96 ± 19.78 db to 34.02 ± 16.91 db and the density of right disc decreased from 167.95 ± 24.67 db to 45.42 ± 9.13 db (both $p < 0.01$). The area of left disc decreased from 73.33 ± 8.44 mm² to 18.18 ± 7.42 mm² and area of right disc decreased from 87.67 ± 5.46 mm² (both $p < 0.01$). The decrease rate of left disc area (0.76 ± 0.08) was significantly higher than that of right disc area (0.57 ± 0.13) ($p < 0.01$).

Conclusions: The completely bioabsorbable occluder made up of PDO and PLLA with a built-in shape line effectively closed VSDs under echocardiography guidance and was absorbed gradually without residual shunt and malposition before endothelialization.

55. INFLUENCE OF RESTRICTIVE RIGHT VENTRICULAR PHYSIOLOGY IN OUTCOMES AFTER TRANSCATHETER PULMONARY VALVE IMPLANTATION IN ADULT PATIENTS

Clement karsenty¹, Ana rita Francisco², Sophie Malekzadeh-Milani³

¹CHU, Toulouse, France. ²Hospital, Lisbonne, Portugal. ³Necker, Paris, France

Background: A restrictive right ventricular (RV) physiology (r-RVP) is present in almost half of the patients with repaired tetralogy of Fallot (ToF), but its effect on later patients' clinical status is controversial.

Objectives: Evaluate the outcomes after transcatheter pulmonary valve implantation (TPVI) in patients with restrictive versus non-restrictive RV.

Methods: Single-center retrospective study of patients who underwent TPVI for pulmonary regurgitation between 2008 and 2017. Electrocardiogram, transthoracic echocardiogram, cardiac magnetic resonance and cardio-pulmonary exercise test were performed previous to TPVI and repeated 12 months after. For statistical analysis we defined restrictive physiology as the presence of end-diastolic forward flow (EDFF) and RVEDVi < 150 ml/m².

Results: Fifty-nine patients (including 55 tetralogy of fallot) were included and r-RVP was present in 23 patients (39.0%). At the baseline, the majority of the patients were symptomatic, in NYHA functional class II-III (n=48, 81.4%) with reduced cardiopulmonary performance (VO₂max = 20.5mL/min/kg) both worse among patients with r-RVP (p

= 0.018 and $p = 0.018$). During a mean follow-up of 446.4 ± 226.1 days after TPVI one patient died. BNP levels were not significantly different from baseline. Despite self-reported functional capacity and exercise capacity improvement after TPVI ($p < 0.001$), all parameters remained lower in r-RVP group. One year after TPVI, pulmonary and tricuspid regurgitation decrease significantly, as well as RVEDV, in both groups. However, RV systolic function remained unchanged. Regarding to the dysrhythmic profile, all patients with need for an implantable cardiac defibrillator and seven of the eight patients requiring radiofrequency ablation for sustained supraventricular arrhythmias during follow-up were in the group without r-RVP. In multivariate analysis only non r-RVP predicted rhythmic events ($p = 0.038$).

Conclusion: TPVI had a positive impact in clinical status in a cohort of patients with predominant PR regardless the presence of restrictive physiology. Moreover, besides higher VO_2 max and anaerobic threshold in the non-restrictive group, the magnitude of the improvement was not statistically different between the two groups. We question about the benefit of treating non r-RVP patients with $RVEDV < 150 \text{ mL/m}^2$, in order to improve symptoms and prevent progression of RV dysfunction and dysrhythmic events.

56. PERCUTANEOUS INTERVENTIONS IN PATIENTS AFTER THE GLENN PROCEDURE: OUR EXPERIENCE.

Jacek Kusa^{1,2}, Pawel Czesniewicz²

¹Medical University of Silesia, Katowice, Poland. ²Regional Specialist Hospital in Wroclaw, Research and Development Centre, Wroclaw, Poland

Objectives: A routine, diagnostic cardiac catheterization before Fontan procedure is nowadays usually combined with catheter intervention. Modern interventional procedures improved the prognosis in this challenging group of patients and in some circumstance can replace the surgical treatment.

This paper summarises our experience of interventional treatment of patients after the Glenn procedure.

Methods: We analyzed data of 77 patient with single ventricle anatomy after Glenn shunt (age 8 months - 17 years, mean 4 years) who underwent percutaneous interventions during cardiac catheterization from 2013 to 2016 at our institutions.

The clinical characteristics of the study population were described. The complete hemodynamic data, type of catheter interventions and complications were defined.

Patients were divided into two groups: with the right ($n = 49$) and left ($n = 28$) ventricular morphology.

Results: A total of 205 interventions were performed in 77 patients (1-4 interventions per patient). These include: the closure of major aortopulmonary collateral artery ($n = 70$), balloon angioplasty ($n = 47$) and stent implantation ($n = 20$) of stenosed pulmonary arteries, balloon angioplasty of stenosed cavopulmonary anastomosis ($n = 27$), balloon angioplasty ($n = 25$) and stent implantation ($n = 4$) of coarctation of the aorta and others.

Patients with right ventricular morphology had smaller pulmonary arterial sizes with less favorable McGoon ratio (1,56 vs. 2,01 $p < 0,05$) and for this reason, those patients required a larger number of percutaneous interventions (3,18 vs. 1,79 $p < 0,05$).

There were no catheter-related deaths. The frequency of procedure-related complications was low and in the majority were related to vascular complications on puncture site (bleeding in 5 patients, loss of pulse in 3 patients). The occurrence of serious complications such as implant migration ($n = 1$), vessel rupture ($n = 1$) and thromboembolic event ($n = 2$) was rare at our institutions.

Conclusion: Percutaneous interventions in patients after Glenn procedure are a safe and effective treatment for residual lesions and may help to avoid extensive surgery during the last stage of Fontan palliation.

57. PERCUTANEOUS CLOSURE OF VENTRICLE-PULMONARY CONNECTIONS IN PATIENTS AFTER GLENN PROCEDURE: IF IT IS FEASIBLE SHOULD IT BE PERFORMED?

Pawel Czesniewicz¹, Jacek Kusa^{2,1}

¹Regional Specialist Hospital in Wroclaw, Research and Development Centre, Wroclaw, Poland. ²Medical University of Silesia, Katowice, Poland

Background: The anterograde pulmonary blood flow (through pulmonary artery banding or recanalization of surgically sutured pulmonary trunk) after Glenn procedures can lead to elevated mean pulmonary artery blood pressure (MPAP) and volume overload resulting in a reduction in ventricular function.

Objective: We analyzed our patients after Glenn procedure, who had undergone a routine cardiac catheterization, regarding the incidence of maintained anterograde pulmonary blood flow as well as the therapeutic options.

Material and methods: Between 2013 and 2017, a total of 89 patients underwent a routine cardiac catheterization before the Fontan procedure. In 4 patients (4,4%) in the age group 2-13 years, the anterograde pulmonary blood flow was detected (including two patients with tricuspid atresia, one with an unbalanced atrioventricular septal defect and one with double outlet right ventricle). 3 patients had elevated MPAP (respectively 19 to 22 mmHg) and were treated percutaneously with different types of occluder devices: Amplatzer Muscular VSD Occluder (MuscVSD) (n=1), Amplatzer Duct Occluder II (ADOII) (n=1), CP cover stent (n=1).

In another patient with normal MPAP and recanalization of the surgically sutured pulmonary trunk, the procedure was performed using ADOII.

Results and Complications: Procedural success was achieved in all patients.

All three patients with elevated MPAP had thromboembolic incidences. Two patients had thrombus formation in the pulmonary trunk below the device. In one case thrombus formation was detected immediately after the procedure and was successfully treated with anticoagulation therapy. The second patient, who was lost in follow up for 10 months, was administered to our institution with thrombus and severe stroke. This patient died a month later. Patient, who was treated with CP cover stent due to significant anterograde pulmonary blood flow and left pulmonary artery stenosis had a thrombosis of the previously implanted stent. Only one patient with elevated MPAP six months later was qualified and scheduled for completion of Fontan circulation due to a normalization of MPAP.

Summary: Percutaneous closure of ventricle-pulmonary connections is technically possible but in our experience is associated with a high incidence of complications. This intervention might be considered only in the circumstance of appropriate anticoagulation.

58. CATASTROPHIC COMPLICATION ENCOUNTERED DURING TRANS-CATHETER CORONARY FISTULA CLOSURE.

Sanjay Khatri, Kanupriya Chaturvedi, Sunil Kaushal, Rajiv Lochan Tiwari, Sanjeeb Roy
Fortis Hospital, Jaipur, India

An 11 month old baby, weighing 6.8 kg was evaluated for poor weight gain and recurrent respiratory tract infections.

Physical examination was suggestive of a patent ductus arteriosus (PDA) and echocardiography confirmed the diagnosis of 3.2 mm PDA, shunting left to right and no additional significant findings. The patient underwent successful and uneventful device closure of the PDA. Follow up echocardiogram after a month revealed the PDA device in a good position with no residual shunt, however, a new finding of a coronary fistula connecting a dilated and tortuous left main coronary artery to the right atrium was evident. Subsequent echocardiograms suggested the fistula to be hemodynamically significant and the decision to close the fistula was taken.

Aortic root angiogram demonstrated a tortuous fistulous tract with multiple bends which required multiple difficult attempts to cross. A 12 mm vascular plug II was deployed distally and selective coronary angiography showed no coronary compression and the device was released. After a few seconds of device release, the patient developed hypotension and bradycardia, CPR was performed and patient was intubated. An echocardiogram showed severely diminished left ventricular function.

No flow was demonstrated in the anomalous right coronary and circumflex arteries in the coronary angiogram. The differentials at the time included device embolization, thromboembolism or coronary artery vasospasm.

The occluded coronaries were crossed with a 0.14x 190 cm BMW wire and thrombosuction was done followed by balloon dilatation with 1.2 x 8mm and 2.0 x 12 mm balloons sequentially and a temporary pacing lead was positioned in the right ventricle. The patient became hemodynamically stable and was shifted to ICU on mechanical ventilation. GP2b /3a inhibitor bolus was given followed by its infusion and Heparin infusion also started. The myocardial enzymes (Trop T 9705 and CPK-MB -204) were markedly elevated.

After review of angiograms we concluded that due to the tortuosity of the fistulous tract, multiple bends and multiple attempts to cross this, the procedure time was prolonged which resulted in clot formation within the sheath, which embolized, during a power angiogram after the deployment of the device and lead to this catastrophe.

After 3 days the inotropes were tapered and stopped, pacing lead was removed and the patient was extubated. He was discharged on day 6 with LVEF 35%. On the last follow up after 6 months LVEF was 45-50%.

Our case highlights a few significant issues which are liable to be missed at times and can lead to catastrophic consequences. The first and foremost would be to keep a watch on the procedure time, check ACT and infuse heparin accordingly. As we saw, closure of a PDA may rarely manifest as a latent coronary fistula and hence meticulous follow up is required at least for a few months after device closure of a PDA. The above case also opens up the discussion on performing CT angiograms for every case of coronary artery fistula in resource limited countries.

59. PERVENTRICULAR DEVICE CLOSURE OF LARGE MUSCULAR VSIDS; SINGLE CENTRE EXPERIENCE

Ahmet Celebi, Emine Hekim Yilmaz, Ilker Kemal Yucel, Husnu Firat Altin, Numan Ali Aydemir

Dr Siyami Ersek Hospital for Cardiology and Cardiovascular Surgery, Istanbul, Turkey

Introduction: Surgical repair of VSIDs ensures direct visual access but for muscular ventricular septal defects (mVSIDs) exposure may be limited due to coarse trabeculations of right ventricle(RV) and postoperative residual shunt continues to be of concern. Left ventriculotomy may provide better exposure but not preferred in small infants due to potential long term complications. Palliative pulmonary artery banding (PAB) is associated with RV hypertrophy and myocardial remodeling and necessitate reinterventions in long term. Percutaneous closure of mVSD avoids sternotomy and CPB and has been an alternative technique in selected patients but its application is limited in small infants <8kg. Periventricular device closure (PVDC) of mVSIDs is a hybrid procedure involving a limited sternotomy and direct RV puncture to introduce a sheath to deploy the device. We herein describe our single center experience on the feasibility and outcome of PDVC of isolated large mVSD.

Patients and Method: Between 2008-2019, 25 infants who had either single or multiple large mVSIDs with evidence of nonrestrictive left to right shuntson transthoracic echocardiography (TTE) examinations, and who were symptomatic with failure to thrive due to congestive heart failure (CHF) and had significant pulmonary hypertension (PH) underwent PVDC procedure. All interventions performed in operating theatre under general anesthesia with the guidance of continuous transesophageal echocardiography (TEE). Sixteen (64%) were female, 9 (36%) were male in gender with a mean age of $4,1 \pm 1,3$ months (1 - 6 months) and a mean body weight of $4,22 \pm 0,75$ kg (3.5 - 5.3 kg). Fifteen (60 %) children had single mVSD while ten (40 %) children had multiple mVSD which was large and required additional device usage in two case. According

to anatomic type of defect eighteen patient had mid muscular, three patient had apical muscular, two patient had muscular inlet, two patient had large multiple defects. Five patients had previous preoperative procedures.

Results: Mean diameter of defects measured on TTE was 8.06 ± 1.5 mm (5–11 mm) while measurements on TEE was 8.88 ± 1.46 mm (5.8-12 mm). In all cases muscular VSD occluders used in sizes ranging from 8 to 16 mm, resulting in a device to defect ratio of 1.29 ± 0.11 (1.1-1.5). Twenty five successful device deployment procedures performed in 23 patients, as double device used in two cases. Among three procedures which was deemed as unsuccessful, two underwent PAB and one expired. Thirteen case had residual shunts but it was significant only in 1. During mean $58,71 \pm 38,62$ (0,25-120, median 63) month follow up without need for any other intervention, without any ventricular dysfunction and rhythm problem, nineteen patients are attending to outpatient clinic visits regularly.

Conclusion: Low body weight remains a strong predictor of higher mortality and morbidity for surgical correction and percutaneous route may be complicated in small infants. For early correction of large interventricular shunts PVDC may be a safe and effective option either substituting or complementing the conventional surgical closure. Although combines the advantages and reduces the invasiveness of cardiac surgery and transcatheter interventions, it is not free from complications entirely.

60. OUTCOMES AFTER TRANSCATHETER REINTERVENTION FOR DYSFUNCTION OF A PREVIOUSLY IMPLANTED TRANSCATHETER PULMONARY VALVE

Shabana Shahanavaz¹, Felix Berger², Thomas Jones³, Jacqueline Kreutzer⁴, Julie Vincent⁵, Andreas Eicken⁶, Lisa Bergersen⁷, Jonathan Rome⁸, Evan Zahn⁹, Lars Sondergaard¹⁰, John Cheatham¹¹, David Balzer¹, Doff McElhinney¹²

¹Washington University SOM, St. Louis, MO, USA. ²German Heart Institute Berlin, Berlin, Germany. ³Seattle Children's Hospital, Seattle, WA, USA. ⁴Children's Hospital of Pittsburgh UPMC, Pittsburgh, PA, USA. ⁵Children's Hospital of NY, New York, NY, USA. ⁶German Heart Center Munich, Munich, Germany. ⁷Boston Children's Hospital, Boston, MA, USA. ⁸Children's Hospital of Philadelphia, Philadelphia, PA, USA. ⁹Cedars-Sinai Heart Institute, Los Angeles, CA, USA. ¹⁰The Heart Center, Rigshospitalet, University of Copenhagen, Copenhagen, Denmark. ¹¹Nationwide Children's Hospital, Columbus, OH, USA. ¹²Lucile Packard Children's Hospital Stanford, Palo Alto, CA, USA

Background: Transcatheter pulmonary valve replacement (TPVR) with the Melody valve has demonstrated sustained

relief of right ventricular outflow tract (RVOT) obstruction and pulmonary regurgitation (PR) with high rates of procedural success, few procedural complications, and improved quality of life. Some patients subsequently require RVOT reintervention, often for recurrent obstruction associated with stent fracture (SF) or endocarditis. This analysis evaluates the technical/procedural factors and outcomes following post-TPVR transcatheter RVOT reinterventions, with the primary objective of characterizing the acute and time-related function of the second Melody valve or re-expanded original TPV.

Methods: All patients who underwent TPVR with a Melody valve as part of three Medtronic-sponsored prospective multicenter studies were included. Transcatheter reinterventions included balloon dilation of the previously implanted Melody valve, placement of a bare metal stent within the implanted TPV, or placement of a new TPV in the RVOT (TPV-in-TPV). Indications for reintervention, decisions to reintervene, and the method of reintervention were at the discretion of the implanting physician.

Results: A total of 309 patients underwent TPVR in three prospective Melody valve trials and were discharged from the implant hospitalization with a Melody valve in place. Patients were followed for a median of 5.1 (min-max: 0.2-9.3) years. Transcatheter reintervention on the TPV was performed in 46 patients, who are the focus of this report. The first transcatheter reintervention consisted of TPV-in-TPV in 28/46 patients (median 6.9 years [0.4-8.8] after TPVR), simple balloon dilation of the implanted Melody valve in 17/46 (median 4.9 years [2.5-9.3] years after TPVR), and bare metal stent placement alone in 1/46 (4.4 years after TPVR). Indications for the first reintervention included stenosis associated with Melody valve SF in 27 patients, stenosis without documented SF in 12, and endocarditis with TPV dysfunction in 7 (2 with and 5 without SF). Patients were followed for a median of 3.4 years (0-7.9 years) after the initial reintervention, during which 19 patients underwent another RVOT reintervention. Overall, 5-year freedom from explant and from any later RVOT reintervention after the first reintervention were 85% and 69%, respectively. Notably, freedom from repeat RVOT reintervention was longer in patients undergoing TPV-in-TPV than balloon dilation (78% vs 38% at 5 years, $p=0.01$).

Conclusions: TPV-in-TPV can be an effective and durable treatment for Melody valve dysfunction. Although balloon dilation of the Melody valve was also acutely effective at reducing RVOT obstruction, the durability of this therapy was limited in this cohort compared to TPV-in-TPV.

61. BRANCH PULMONARY ARTERY REHABILITATION USING DRUG ELUTING STENTS: EARLY RESULTS

Daniel Duarte, Patcharapong Suntharos, Lourdes Prieto
Nicklaus Children's Hospital, Miami, USA

Background: Patients with congenital or post-operative pulmonary artery stenosis and small pulmonary arteries often require multiple catheterizations for pulmonary artery rehabilitation. Frequently, balloon angioplasty results in only temporary improvement. Conventional pre-mounted stents are easier to advance given the lower profile, however the smaller sizes are limited in their post-dilation potential to keep up with vessel growth. Additionally, in-stent restenosis is common in very small stents. Drug-eluting stents (DES) are pre-mounted stents that can be deployed in smaller vessels, theoretically reduce the rate of in-stent restenosis, and can be fractured longitudinally to potentially insert a larger size stent. We report the early results of DES for pulmonary artery stenosis in infants and small children.

Methods: We performed a retrospective chart review from 5/2018-4/2019 of all patients who had implantation of a DES in a stenotic pulmonary artery at Nicklaus Children's Hospital. Patient age, weight, reference vessel diameter, stenosis diameter and % stenosis pre and post stent implantation, and complications were recorded. In patients who had follow up catheterizations degree of in-stent restenosis was assessed, and stent diameter was measured to evaluate for recoil.

Results: A total 9 patients underwent placement of 20 DES over 13 different procedures at a mean age of 23 months (1-98 months), and weight of 10.4 Kg (3.8-25.5Kg). All stents were Resolute Onyx (Medtronic, Santa Rosa, CA). The most common diagnosis was tetralogy of Fallot with pulmonary atresia and aortopulmonary collaterals (67%). The mean reference vessel diameter was 4.4mm (2.9-4.6mm) with a mean stenosis diameter of 2.2mm (range 0.6-3.1mm). Implanted stent diameters were 4 mm in six, 4.5 mm in two, and 5 mm in nine vessels. Following stenting, there was a mean 221% (146 -750%) increase in the minimal vessel diameter to 4mm (1.8-5.2mm). Four stents were post-dilated with higher pressure balloons. Post dilation of one stent resulted in lengthening of the stent with increase in the distance between struts, and no further improvement of the stenosis than accomplished immediately post stent implantation (81% pre to 56% post). There were no complications. Follow up catheterizations were performed in 4/9 (44%) patients at a mean of 3 months (1-4 months), and none showed in-stent restenosis or stent fractures.

However, the stents showed some degree of recoil (mean recoil 10.4%, range 0 – 21%).

Conclusions: The use of DES for branch pulmonary artery stenosis in small vessels is a safe alternative with potential for further expansion and fracture to achieve larger diameters. DES showed no in-stent restenosis at a mean follow-up of 3 months, however, some degree of stent recoil was common. Longer follow-up is needed to better assess restenosis rates and vessel growth.

62. TRANSCATHETER INTERVENTION IN A PRE-TERM CHILD WITH SCIMITAR SYNDROME.

Iñaki Navarro Castellanos^{1,2}, Alberto Zárate Fuentes¹, Pedro Ivan Barrera Martínez², Leslie Solano Ibarra², Manuel Soriano²

¹h.R.L.A.L.M Issste, Mexico City, Mexico. ²hip, Mexico City, Mexico

Background: Scimitar syndrome is a rare congenital heart disease. Surgical correction remains the gold-standard therapy. However, the non-surgical intervention has been reported as effective in selected cases with scimitar syndrome.

Pulmonary sequestration is a condition in which a segment or lobe of dysplastic lung tissue exists with no communication with the rest of the tracheobronchial tree and receives an anomalous systemic vascular supply, separated from the rest of the lung.

Arterial supply is from systemic vessels—most commonly descending thoracic aorta (73%), and the remaining 27% from these other arteries: the cranial portion of the abdominal aorta, celiac trunk, splenic artery, as well as intercostal arteries.

Case presentation: We report on a 15 days-old boy, of 1.6 Kg with scimitar syndrome who underwent stepwise transcatheter intervention as an alternative treatment. Embolization of the aortopulmonary collateral and occlusion of the Patent Ductus Arteriosus were performed using Amplatzer PDA AS, in both defects, without arterial access. First the aortopulmonary collateral crossing the PDA and finally de PDA.

The patient post-catheterization course was uneventful. The right cardiac chamber and pulmonary arterial pressure returned to normal during follow up.

Conclusions: This report highlights the role of minimal invasive approach in the management of Scimitar syndrome in pediatric patients to diminish the morbidity and

mortality associated with more invasive procedures or late management.

63. A SINGLE CENTER REVIEW OF DIAGNOSTIC AND THERAPEUTIC STRATEGIES OF PATIENTS WITH UNILATERAL PULMONARY ARTERY AGENESIS

Ah Young Kim, Han Ki Park, Jae Young Choi

Yonsei university health system, Seoul, Korea, Republic of

Unilateral pulmonary artery agenesis (UPAA) is a rare congenital anomaly due to a malformation of the sixth aortic arch of the affected side during embryogenesis. It can present as an isolated lesion or with other congenital heart diseases. The diagnosis is usually set at adolescence while being asymptomatic, however with the development of various imaging modalities, the importance of early diagnosis and revascularization is emerging.

This retrospective review study included cases of UPAA in the single tertiary center from March. 2005 through March. 2019. Of the 15 patients identified, 13 had isolated UPAA (5 with Patent ductus arteriosus).

Median age of diagnosis was 5.3 (0.0 – 43.0) years old and 4 were asymptomatic at that time but incidentally found by chest x-ray. Symptoms including dyspnea, desaturation, chronic cough, frequent pulmonary infections and hemoptysis were found in majority of patients (12/15) during follow up periods. Patients who have delayed diagnosis were not encouraged or feasible because the intrapulmonary arteries had been found to be severely narrowed or completely obstructed. 5 (33%) patients were undertaken staged repair to promote distal PA growth and lung development. The first stage was PDA stenting, followed by surgical anastomosis in the second stage. They all stable during mid-term follow-up (7.1 ± 5.3 years) and results in remarkable growth of the affected pulmonary artery from -4.7 ± 2.5 of z-score at 1st palliation to -1.5 ± 1.2 at last follow up point. There was 1 case of mortality who was suffered from tracheal stenosis which is known as associated with unilateral lung hypoplasia.

Although there is no consensus on treatment of UPAA, it is getting important to establish an early diagnosis and provide adequate treatment for this disease. Careful awareness of diagnosis and early search for the occult PA will help.

64. USE CHEATHAM PLATINUM STENT TO RESOLVE SUPRAVALVAR PULMONARY STENOSIS IN A 13-YEAR-OLD BOY LATE AFTER ARTERIAL SWITCH OPERATION FOR TRANSPOSITION OF GREAT ARTERY

Jeng-Sheng Chang^{1,2}, Yun-Ching Fu^{1,2}, Yi-Chin Peng¹, Ping-Yun Chiou¹

¹Children's Hospital, China Medical University, Taichung, Taiwan.

²College of Medicine, China Medical University, Taichung, Taiwan

A 13-year-old boy of d-TGA had arterial switch operation with Lecompt maneuver soon after birth. Follow up echocardiographic studies revealed a supra-valvar PS of 50 mmHg gradient. Balloon angioplasty one year ago did not resolve the gradient. The narrowest segment, 'waist', was 9.0mm in diameter, while the sinus valsalva portion of the MPA was 17.7mm in diameter. The distance between the tips of pulmonary valve (PV) at opening and the roof of the MPA was 31.1mm. The waist was closer to the PV tips than to the PA roof. We chose to use a Cheatham Platinum (CP) bare stent of 34 mm long (CP8Z34). At first, we use aortic root angiogram to confirm that the coronary arteries were not compressed by a fully inflated 18mm x 4cm XXL balloon catheter in the RV outflow tract. With a stiff wire remained in the LPA, we then advanced the 16mm-4cm balloon-in-balloon catheter-mounted stent combination set to the 'waist'. The inner balloon dilation began to open the stent to 8 mm in diameter. Assisted with bouts of contrast injection from the long sheath, we made fine adjustment on the stent location to make sure it had neither interfered to the movements of PV, nor to leave a too short proximal portion of stent to anchor stably on the waist. Finally, the outer balloon-and-stent was slowly and fully inflated up to 5 atm pressure. To make the stent an ampulla shape, we re-dilated its proximal end with the same balloon catheter. The full stent length was shortened from 34 mm to 28.4mm. The waist and the proximal end were 14.3 and 16.6 mm in diameter, respectively. The stent appeared stable on the waist, though shorter in its proximal side than that of the distal side. The pressure gradient dropped to 20mmHg. The systolic pressure gradient ratio between RV and AO dropped from 61/97(0.63) to 54/141(0.38) mmHg. Contrast media flew to bilateral PA smoothly.

65. BENCH TESTING OF MECHANICAL PROPERTIES OF LOW-DIAMETER BALLOON EXPANDABLE COVERED STENTS CURRENTLY AVAILABLE FOR USE IN PEDIATRIC PATIENTS.

Benjamin Blais¹, Karen Carr¹, Sanjay Sinha^{1,2}, Daniel Levi¹

¹UCLA Mattel Children's Hospital, Los Angeles, USA. ²CHOC Children's Hospital, Orange, USA

Objective: To determine post dilation potential and cover integrity of 5-12mm Atrium, VBX, and Lifestream balloon expandable covered stents.

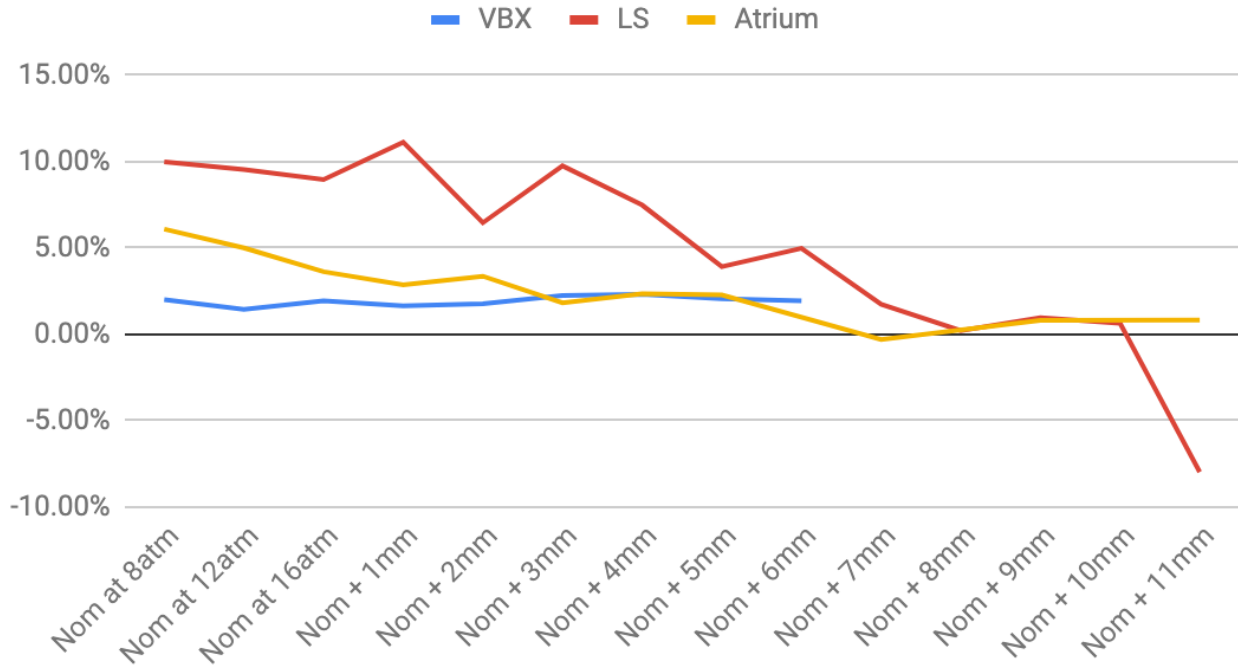
Background: Covered stents can treat ruptures and aneurysms in patients with congenital heart disease and are often dilated well beyond their implant diameters. The foreshortening, recoil, and covering/stent integrity with serial dilations is clinically important information for interventionalists.

Methods: Serial dilations of the 5-10mm Atrium, VBX, and Lifestream covered stents were performed in 1-2 mm increments from 5mm to 20mm with measurements of foreshortening, recoil and stent/cover integrity, both with nominal balloon expansion and post-dilation. Additional data characterizing fabric coating tears, strut narrowing, and stent fracture were collected for all three types of stents.

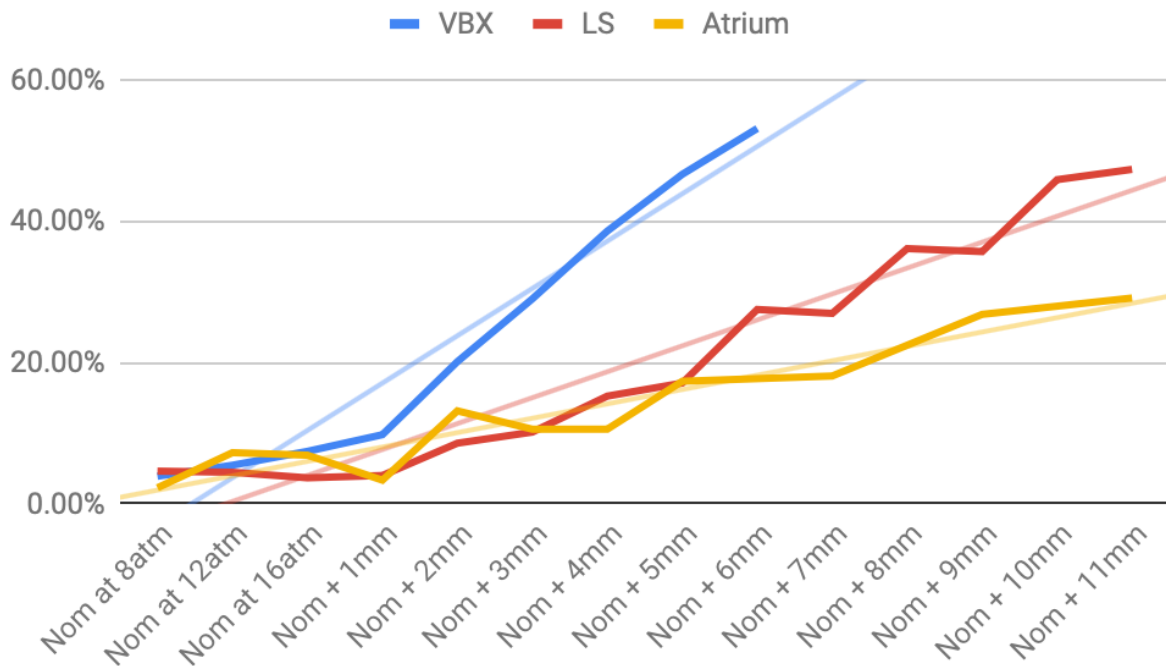
Results: All stents met expected labeled performance for their intended delivery balloon. Average foreshortening was most significant with VBX stents at 40-50% when dilated with balloons 4-5mm above crimped labeled diameter (CLD). Lifestream stents did not reach 40-50% foreshortening until dilated with balloons 10-11mm above the CLD, followed by Atrium stents which reached maximum foreshortening of 20-30% when over-dilated by 10-11mm. The VBX stents tended to foreshorten from the outside inward, eventually forming a short ring. Average recoil was most notable for Lifestream stents at 8-10% on dilation with the nominal delivery balloon, and similarly on over-dilation with balloons 1-4mm above (compared with average recoil of 3-6% for Atrium stents and 1-2% for VBX stents under the same circumstances). After 5-7mm of over-dilation from nominal the recoil was roughly the same at <3% for all stent types. Excluding an outlier (the 5mm Atrium collapsed into a tight ring), fabric covering tore earliest with the Atrium stents, reaching an average of 5mm above nominal before tearing. The VBX and Lifestream stents maintained cover integrity until dilations greater than 8-9mm above nominal. The Lifestream stents tended to fracture at an average of 10-11mm greater than nominal, whereas the VBX and Atrium stents fractured at 8-9mm and 6-7mm above nominal respectively.

Conclusions: Both the VBX and Lifestream stents maintained cover integrity until dilations greater than 8-9mm above nominal. The Atrium stent lost fabric integrity at the lowest and the VBX stent had the greatest foreshortening diameters. The Lifestream stents had the greatest post dilation potential and were able to be fractured at >10 mm above nominal.













Average Recoil Per mm Dilation (All Stents)



Average Foreshortening Per mm Dilated (All Stents)



65. Figure 1.

	10mm Balloon	12mm Balloon	14mm Balloon	Fracture
Gore VBX 10x29				 A
Atrium iCast 10x38		 *		 B
Lifestream 10x38				 C

65. Figure 2. Over-inflation of the 10mm stents. The columns show each stent inflated to 12 atm with the intended delivery balloon and 14mm balloon. The fourth column shows stent appearance at time of fracture. *The iCast 10mm stent is shown during inflation; a photograph was not taken after deflation.

- A) The 10mm VBX stent fractured at inflation to 18 atm on the 14 balloon
- B) The 10mm iCast stent fractured at inflation to 18 atm on the 14 balloon
- C) The 10mm Lifestream stent fractured at 12 atm on the 20 balloon

66. RADIATION EXPOSURE OF CHILDREN UNDERGOING CARDIAC CATHETERIZATION -COMPARISON OF DOSE AREA PRODUCT BY BODY WEIGHT-

Kazuya Sanada, Sung-Hae Kim, Mizuhiko Ishigaki, Keisuke Sato, Jun Yoshimoto, Norie Mitsushita, Masaki Nii, Yasuhiko Tanaka

Shizuoka Children's Hospital,Cardiology, Shizuoka, Japan

Background: Because of the higher radiosensitivity of infants and children compared with adults, consideration of radiation exposure is important for children with congenital heart disease. However, it is difficult to estimate effective dose in pediatric cardiac catheterization. Dose area product by body weight (DAP / BW) correlate with the effective dose and is useful as an indicator of radiation exposure in pediatric cardiac catheterization. The objective of this study is to determine the difference of DAP/BW by procedure and age.

Methods: 2,095 patients (age< 15 years) who underwent cardiac catheterization in our institute between January 2008 and September 2017 were included in this study. The procedures consisted of diagnostic (Group D; n=1,690), coil embolization for aortopulmonary collateral arteries (Group C; n=311), balloon dilatation for pulmonary stenosis

(Group B; n=94), respectively. Data on radiation exposure [Air Karma (AK), fluoroscopy time (FT), DAP, DAP / BW] were shown by median and compared with procedure groups and age groups.

Results: The levels of AK, DAP and DAP / BW were significantly higher in Group B [AK(mGy): D; 71 , B;97,C;190,respectively ,p<0.05 , DAP(μGym^2): D; 475 ,B;590 ,C; 1,136,respectively ,p<0.05 , DAP/BW($\mu\text{Gym}^2/\text{kg}$): D; 42.9 ,B;67.6 ,C;101.3, respectively, p<0.05], whereas FT was no significant difference between Group C and B [38.4 vs 42.2, respectively, p=0.21]. In Group B, there is no significant difference in DAP/BW between patients who underwent three-dimensional rotational angiography and those who did not [n=14,84.1vs n=80, 103.1, respectively, p=0.18]. DAP/BW was no significant difference between age groups in Group C and B [C: 0-1y; 70.8, 1-4y; 62.8, 5-9y; 71.4, 10-15y; 87.4, respectively, p=0.374, B: 0-1y; 82.9, 1-4y; 106.0, 5-9y; 104.5, 10-15y; 86.9 ,respectively, p=0.255].

Conclusions: In this study, the effective dose of cardiac catheter intervention has more than 1.5-2 times higher than diagnosis. There is a possibility of receiving a higher radiation exposure in same procedure because the lower age group is more sensitive to radiation. DAP / BW may

be useful as indicator of radiation exposure in pediatric catheterization.

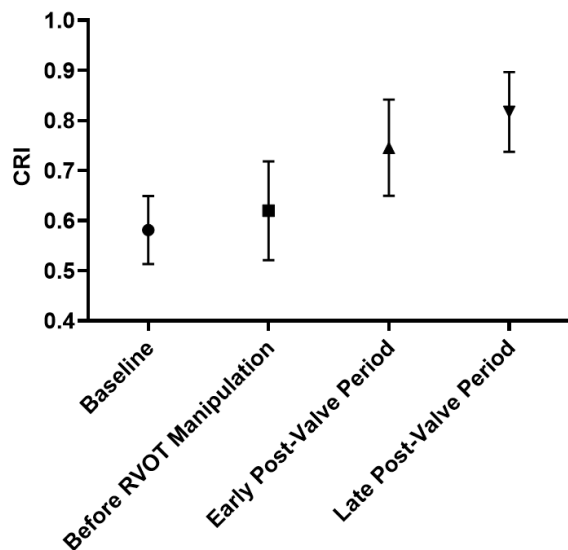
67. THE COMPENSATORY RESERVE INDEX INCREASES AFTER TRANSCATHETER PULMONARY VALVE REPLACEMENT IN PATIENTS WITH CONGENITAL HEART DISEASE

Daniel Ehrmann, David Leopold, Ryan Phillips, Niti Shahi, Steven Moulton, Kristen Campbell, Michael Ross, Jenny Zablah, John Kim, Gareth Morgan

University of Colorado/Children's Hospital Colorado, Aurora, USA

Background: Early physiological changes in circulatory volume after successful surgical or transcatheter valve replacement (TcPVR) have not been characterized using non-invasive measures of compensation. Moreover, in contrast to patients undergoing surgical pulmonary valve replacement who must first recover from the effects of cardiopulmonary bypass, those undergoing TcPVR may experience immediate improvements in cardiac efficiency, left ventricular preload, and ultimately stroke volume. The Compensatory Reserve Index (CRI) is an FDA-cleared monitoring technology that trends real-time changes in circulatory volume by analyzing compensatory changes in pulse oximetry waveforms. The CRI ranges from 1 (normovolemia) to 0 (life-threatening decompensation, systolic blood pressure < 80mmHg). Since patients undergoing successful TcPVR may experience immediate improvements to their haemodynamics, we hypothesized that CRI would immediately increase after successful TcPVR.

Methods: A prospective cohort of subjects undergoing TcPVR was studied. CRI was continuously measured using a

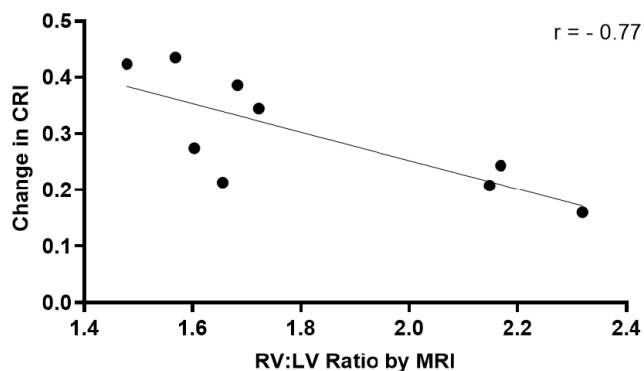


67. Figure 1. Mean CRI by Procedural Phase

CipherOx® CRI M1 device. Data were analyzed during four procedural phases: pre-anesthesia baseline, after anesthesia induction but before right ventricular outflow tract (RVOT) manipulation, immediately after TcPVR placement while still under anesthesia ("early post-valve period"), and during anesthesia recovery ("late post-valve period"). Clinical, catheterization, and imaging data were also collected. Data are presented as medians with interquartile ranges (IQR), means and 95% confidence intervals (CI), or counts and proportions as appropriate. Descriptive data only are presented in this interim analysis halfway through target enrollment.

Results: Thirteen subjects have been enrolled to date. The median age was 13 years (IQR: 12 – 26) and 6 (46%) were status post Tetralogy of Fallot repair. The primary indication for TcPVR was pulmonary stenosis (n = 5, 38%), pulmonary insufficiency (n = 3, 23%), or combination of both (n = 5, 38%). Nine patients had pre-operative MRIs with a median RV:LV ratio of 1.68 (IQR: 1.59 – 2.16). Mean CRI values over the four procedural phases were (figure 1): pre-anesthesia baseline 0.58 (95% CI: 0.51 – 0.65), before RVOT manipulation 0.62 (95% CI: 0.52 – 0.72), early post-valve period 0.75 (95% CI: 0.65 – 0.84), and late post-valve period 0.82 (95% CI: 0.74 – 0.90). The correlation coefficient between change in CRI (late post-valve period – baseline) and MRI RV:LV ratio was -0.77 (figure 2).

Conclusions: In this pilot study of patients with CHD, CRI increased early after successful TcPVR. Improvement in CRI may correspond to improvements in cardiac efficiency and haemodynamics after successful TcPVR. Pre-operative RV:LV ratios by MRI were inversely related to post-TcPVR



67. Figure 2. Correlation between CRI change and RV:LV Ratio by MRI

changes in CRI, which suggests that the immediate benefits of TcPVR may be impacted by the contemporaneous state of ventricular remodeling. It also suggests that acute improvements in hemodynamic efficiency may be more tangible in patients with outflow stenosis rather than regurgitation-mediated dilation. CRI should be further studied in patients undergoing either surgical or transcatheter pulmonary valve replacement to quantify rapidly evolving changes in circulatory volume and compensatory reserve that are evident during the immediate post-procedural phase.

68. TRANSCATHETER PULMONARY VALVE REPLACEMENT: THE AUSTRALIAN AND NEW ZEALAND PERSPECTIVE

Claire Lawley^{1,2}, David Tanous³, Benjamin Anderson^{4,5}, Stephen Shipton⁶, William Wilson⁷, David Celermajer^{8,9}, Clare O'Donnell¹⁰, Philip Roberts¹

¹The Heart Centre for Children, The Children's Hospital at Westmead, Sydney Children's Hospital Network, Westmead, New South Wales, Australia. ²Discipline of Child & Adolescent Health, The Children's Hospital at Westmead Clinical School, Sydney Medical School, Westmead, New South Wales, Australia. ³Department of Cardiology, Westmead Hospital, Westmead, New South Wales, Australia. ⁴Queensland Paediatric Cardiac Service, Children's Health Queensland, South Brisbane, Queensland, Australia. ⁵The University of Queensland, St Lucia, Queensland, Australia. ⁶Children's Cardiac Centre, Perth Children's Hospital, Nedland, Western Australia, Australia. ⁷Department of Cardiology, The Royal Melbourne Hospital, Parkville, Victoria, Australia. ⁸Department of Cardiology, The Royal Prince Alfred Hospital, Camperdown, New South Wales, Australia. ⁹Sydney Medical School, The University of Sydney, Camperdown, New South Wales, Australia. ¹⁰Paediatric and Congenital Cardiology Service, Starship Children's Health, Auckland, New Zealand

Background: The Australian and New Zealand (ANZ) population undergoing transcatheter pulmonary valve replacement (TPV), with either a Medtronic Melody™ valve or Edwards SAPIEN valve, has not been fully characterised. This region faces particular geographic challenges and presents an opportunity to explore outcomes of TPV outside of the historically reported European and North American centres. In particular, there have been specific concerns raised about the rate of infective endocarditis in this cohort.

Methods: A multi-site retrospective cohort study across seven centres in ANZ was undertaken. TPV cases were identified through institutional databases. Relevant details including baseline demographics, procedural details and outcomes were collected. Key outcomes evaluated at follow-up included mortality, morbidity (repeat procedure,

infective endocarditis, device explantation) and echocardiographic data. Ethics approval was obtained.

Results: From June 2009-March 2018, 136 individuals (female = 63, 46%) underwent TPV utilising 124 Medtronic Melody™ valves and 12 Edwards SAPIEN valves (median age 18 years, range 9-60 years; median weight 58kg, range 24-137kg). The most common underlying diagnoses were tetralogy of Fallot (n=45, 33.1%) and pulmonary atresia +/- ventricular septal defect (n=28, 20%). The main sites for implantation were a homograft in 89 (65%) cases and a bioprosthesis in 39 (28.6%) cases. Five valves were implanted into the native right ventricular outflow tract. The indications for TPV were conduit/right ventricular outflow tract stenosis (n=75, 55%), regurgitation (n=12, 9%) or mixed disease (n=49, 36%). Immediate haemodynamic outcome was good; in the stenosis subgroup the mean peak conduit gradient prior to procedure was 40.6mmHg (std. dev. 15.8) and post procedure 11.4mmHg (std dev 7.1), $p < 0.001$. The mean peak RV-to-systemic pressure prior to TPV was 70.9% std. dev. 18.2), and post procedure 39.3% (std. dev. 9.36), $p < 0.001$. Major procedural complications were very rare. There was one early post procedural death, due to device embolisation within the right ventricular outflow tract. In follow-up (median 21 months, range 0-98 months) there were two further deaths unrelated to TPV. Thirteen individuals developed infective endocarditis (annualised incidence rate 4.6% per patient-year), 9 of these individuals required surgical valve explantation and replacement. Two further valves required explantation and replacement in individuals without infective endocarditis.

Conclusions: TPV as performed in selected ANZ centres provides a relatively safe and feasible method of rehabilitating the RVOT. A further three sites are expected to be included – encompassing all TPV across the region. An intention to treat analysis is planned.

69. TRANSCATHETER CLOSURE OF RIGHT PULMONARY ARTERY TO LEFT ATRIUM FISTULA UNDER TRANSESOPHAGEAL ECHOCARDIOGRAPHY GUIDANCE (A CASE REPORT)

Yasmin Ali, Heba Nossir, Amira Nour, Mahmoud Baraka, Maiy El sayed

Ain Shams university, Cairo, Egypt

We present a case of a 12-year-old student who complained of exertional dyspnea and easy fatigability over the past few months. His mother reported mild cyanosis since birth which increased with exertion. On examination, he had central cyanosis with grade II clubbing in both fingers and toes, silent precordium with no audible murmur

over his back). ECG showed normal sinus rhythm with no abnormality. CXR showed an abnormal shadow related to right cardiac border with prominent pulmonary artery and otherwise normal pulmonary vasculature. His complete blood count showed erythrocytosis with hemoglobin concentration of 16.4 gm/dl and hematocrit value of 69.2%. Transthoracic echocardiography showed dilated left atrium with dilated right pulmonary artery. Patient was diagnosed to have a right pulmonary AV malformation. Invasive cardiac catheterization was done to identify size and number of this pulmonary AV malformation. Right pulmonary angiography showed a right pulmonary artery to left atrium fistula (type I) measuring 11 mm in its narrowest diameter with free shunting of blood. TEE guidance inside our cath. Lab. Showed normal pulmonary venous drainage into left atrium, dilated right pulmonary artery opening into left atrium through an opening 10 mm with systolic flow across of low gradient (15mmHg). A balloon was advanced across the fistula for sizing. Stretched diameter of fistula measured 13mm. An Amplatzer ventricular septal occluder 14 was successfully positioned across the fistula. Right pulmonary angiography assured patent right lower pulmonary artery. TEE assured normal pulmonary veins flow into left atrium. Patient saturation rose from 75% to 95%.

70. TRANSCATHETER ASD CLOSURE IN A PATIENT WITH DEXTROVERSION (A CASE REPORT)

Yasmin Ali¹, Alaa Roshdy¹, Khaled Shams², Noha Gama³

¹Ain Shams university, Cairo, Egypt. ²Helwan university, Cairo, Egypt. ³Assuit university, Assuit, Egypt

Cardiac dextroversion is location of the heart in the right chest with the left ventricle remaining in the normal position to the left but lying anterior to the right ventricle. We present a case of secundum atrial septal defect (ASD) in a patient with dextroversion, situs solitus, AV concordance and VA concordance. Patient was referred for transcatheter closure of ASD. Her transthoracic echocardiography showed a 7mm secundum ASD, Upper normal RV size, small restrictive VSD 2mm and a dilated main pulmonary artery. Transesophageal echocardiography showed an 11mm defect with abnormal orientation of inter atrial septum due to cardiac dextroversion. Usual technique for positioning of ASD Amplatzer device (ASO 11) failed with prolapsing of the device into right atrium. Failed right upper pulmonary vein technique. With successful positioning of the device across the interatrial septum using left upper pulmonary vein technique.

71. A NOVEL THREE DIMENSIONAL ECHOCARDIOGRAPHIC TECHNIQUE FOR DEVICE SIZE SELECTION

IN PATIENTS UNDERGOING ASD TRANS-CATHETER CLOSURE

Yasmin Ali, Alaa Roshdy, Aya EL sayegh, Hebattallah Attia, Azza EL fiky, Maiy Elsayed

Ain Shams university, Cardiology Departement, Cairo, Egypt

Objective: To establish a simple and accurate method for device size selection using three-dimensional echocardiographic interrogation of the ASD.

Background: Proper device size selection is a crucial step for successful ASD device closure. The current gold standard for device size selection is balloon sizing. Balloon sizing can be tedious, time consuming and increase fluoroscopy and procedure times as well as risk of complications.

Methods: This is a prospective observational study conducted over a period of 12 months. All patients underwent 2D TTE, three dimensional echocardiographic assessment of the IAS and transoesophageal echocardiogram. Comparison between echocardiographic variables was done using independent sample t test. Linear correlation was established between three dimensional echocardiographic variables and respective variables of device size and 2D TTE and TEE measurements.

Results: The study included 50 patients who underwent successful ASD device closure. There was no significant difference between 3D ASD maximum diameter and all diameters measured by TTE and TEE. There was a strong positive correlation between device size used for closure and both 3D measured ASD area ($r = 0.907, P < 0.0001$) and 3D measured ASD circumference ($r = 0.917, P < 0.0001$). Two regression equations were generated to determine proper device size where Device size = $10.8 + [3.95 \times 3D \text{ ASD area}]$ and Device size = $[3.85 \times 3D \text{ ASD circumference}] - 1.02$

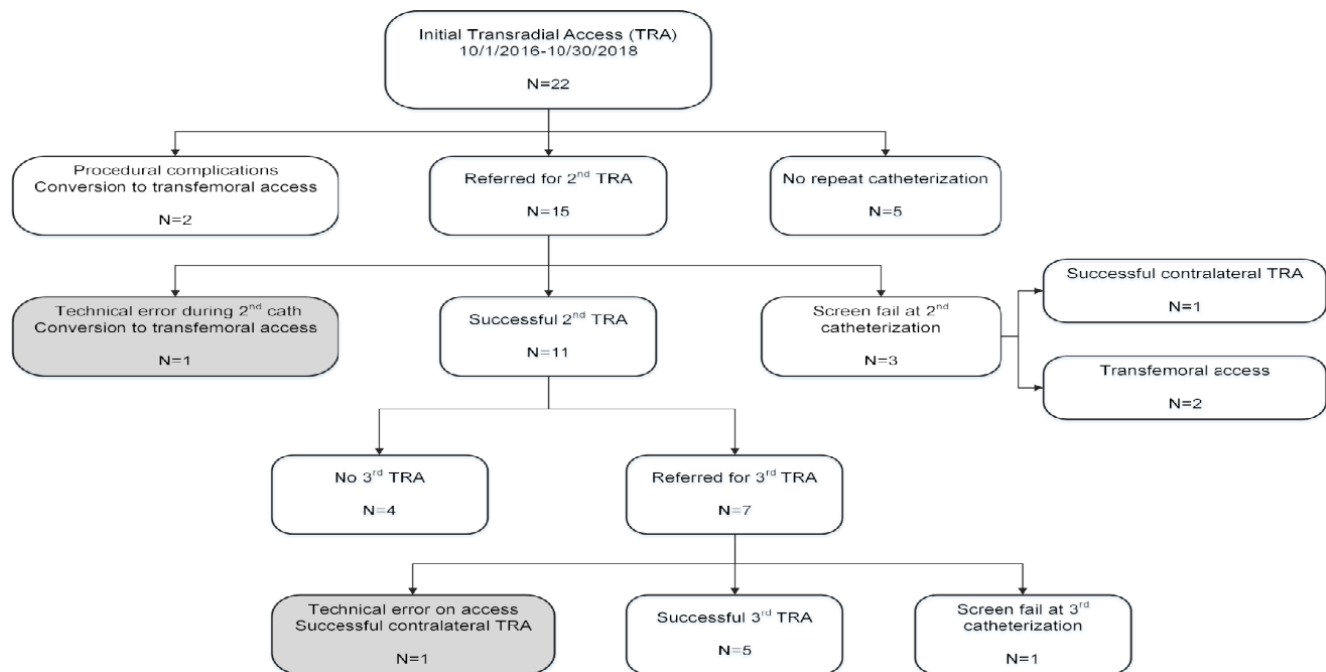
Conclusion: Three-dimensional echocardiogram can provide a simple and accurate method for device size selection in patients undergoing ASD device closure using either 3D derived ASD area or ASD circumference

72. TRANSRADIAL ACCESS IN THE CONGENITAL CARDIAC CATHETERIZATION LABORATORY

Arash Salavitabar¹, Darren Berman¹, Andrew Harrison¹, Randi Pfeffer¹, Shasha Bai², Aimee Armstrong¹, Brian Boe¹

¹Nationwide Children's Hospital, Columbus, USA. ²The Ohio State University Wexner Medical Center, Columbus, USA

Background: Transradial access (TRA) is the standard approach for coronary catheterization in adults, with improved outcomes and higher patient satisfaction



72. Figure 1.

compared to femoral access. The challenge of TRA in the congenital laboratory lies in variable patient age, size and anatomic abnormalities. TRA has been adopted by many congenital catheterization programs, though the safety and utility have not been studied in this setting.

Methods: Data were prospectively recorded for all patients considered for TRA in a congenital catheterization laboratory. All patients were screened using Allen and/or Barbeau test, and some had additional ultrasound visualization of the radial artery. Primary outcomes included successful TRA, intraprocedural complications, and successful repeat TRA catheterizations (TRACs). Univariable analyses were performed.

Results: From 2016-2018, 41 TRACs were performed in 22 patients (see Figure 1). At initial TRAC, median age and weight were 21.3yrs (range 13.2-53.5) and 77.6kg (49-136.1). Twenty (91%) patients had undergone heart transplantation and were referred for annual cardiac catheterization with coronary angiography. Initial TRAC was successful in 20 (91%) patients. Two patients had procedural complications during initial TRAC involving catheter entrapment from vasospasm, with one attributed to a brachial loop. Both resulted in conversion to transfemoral access. Fifteen (68.2%) patients had ≥ 1 repeat TRAC and 11/15 (73.3%) had ≥ 1 successful repeat TRAC. Four patients had abnormal radial artery screening during

subsequent catheterization and two patients had technical errors leading to radial artery spasm upon attempted radial artery access. When comparing patients with a composite outcome of a procedural complications or abnormal screening to those with successful repeat TRA, there was a clinically relevant difference in median radial sheath time at initial TRAC (69.5 minutes [59-146] vs. 52 [34-110], $p=0.098$). At the second TRAC, patients with a successful repeat TRA had a significantly larger median radial artery size as measured by ultrasound (2.5mm [1.8-2.6] vs. 1.55 [1.4-1.7], $p=0.031$). There was no significant difference in age, weight, mean procedural ACT, number of catheter exchanges via the radial sheath, or number of radial artery cocktails given between the two groups.

Conclusions: TRA is a viable option for the congenital catheterization laboratory. Operators should be attuned to ultrasound evaluation of the radial artery and reduced radial sheath time as potential means to avoid complications and future radial artery injury. Further study is needed to determine optimal patient selection and strategies to reduce risk profile of this approach.

73. UTILITY OF MULTIPLE HYBRID TECHNIQUES TO REPAIR COMPLEX CONGENITAL CARDIAC DEFECTS

Dennis VanLoozen¹, John Braucher², Anastasios Polimenakos¹, Zahid Amin¹

¹Augusta University, Augusta, USA. ²Medical College of Georgia, Augusta, USA

Background: Hybrid procedures are now widely accepted techniques to repair complex cardiac defects. We describe a series of 9 cases that were performed at our institution for varied cardiac pathology.

Case Series: Two patients with large omphaloceles and respiratory failure had large secundum ASDs with interrupted IVC. Internal jugular venous access was not feasible. Both patients had significant comorbidities. Both cases were closed via mini-sternotomy and 'per-atrial' approach, under TEE guidance with an Amplatzer Septal Occluder, with no complications.

Two patients under 10 Kg had recurrent coarctation of aorta. One patient had single ventricle physiology status post Glenn anastomosis and also had LPA stenosis. A 4F sheath was placed in the right femoral artery and a Glidewire was advanced to the right common carotid artery (RCCA). A surgical cutdown was performed and the wire was externalized. A sheath was placed over the wire into the RCCA. A stiff wire was advanced from the RCCA across the area of coarctation and an adult sized stent was placed. In the patient with LPA stenosis, the right internal jugular vein was accessed and used for LPA stenting. Both patients had their RCCA repaired.

A four month old patient with multiple VSDs, including a large muscular VSD below the moderator band, underwent hybrid repair. A sheath was placed into the RV and across the VSD. Under TEE guidance, an Amplatzer VSD Occluder was deployed without any complication and the remaining VSDs were closed surgically.

In two patients, perventricular approach was used to place Edwards and Melody pulmonary valves. A sub-xiphoid incision was performed, a sheath was placed in the RV and an extra stiff wire was advanced to the distal LPA. A 22F Cook Feloxr sheath was advanced over the wire, and a 20 mm Melody valve was placed. The 2nd patient had a 23mm Edwards XT valve implanted in a native RVOT s/p transannular patch repair, followed by hybrid branch pulmonary artery stenting.

Conclusion: Varied hybrid approaches can be applied successfully to address an array of complicated cases with successful outcomes.

74. USE OF INTRACARDIAC ECHOCARDIOGRAM TO DIFFERENTIATE POST-TAVR VALVE INSUFFICIENCY MASQUERADING AS PARAVALVULAR LEAK

Michael Bykhovsky¹, Kimberly Atianzar², Shvetank Agarwal², Pushpa Shivaram¹, Zahid Amin¹

¹Children's Hospital of Georgia, Augusta, USA. ²Augusta University, Augusta, USA

Introduction: Transcatheter aortic valve replacement (TAVR) has rapidly become a widespread treatment for severe aortic stenosis in adults. A common complication associated with this procedure is paravalvular leak (PVL) which is associated with increased mortality. Multimodal imaging techniques may be employed to accurately characterize post-TAVR aortic regurgitation.

Case Presentation: The patient was a 71-year-old man who underwent TAVR by transfemoral approach for severe symptomatic non-rheumatic aortic valve stenosis which was complicated by post-deployment aortic regurgitation. After post-implantation balloon dilation, the immediate post-TAVR transesophageal echocardiogram (TEE) as well as follow-up transthoracic echocardiograms (TTEs) demonstrated what appeared to be a significant paravalvular leak involving the non-coronary cusp. Since the patient remained symptomatic on medical management, he was set up for PVL closure. During subsequent catheterization, imaging modalities including TEE, *en face* angiography, and intracardiac echocardiography (ICE) were utilized to assess the aortic insufficiency with successful diagnosis of a frozen intra-TAVR cusp with central regurgitation by ICE.

Discussion: Current guidelines recommend quantitative and qualitative assessment of PVL using various imaging techniques including TTE, TEE, and fluoroscopic angiography. Imaging interrogation limitations of eccentric regurgitant jets post-TAVR can result in the misdiagnosis of intravalvular regurgitation for paravalvular leaks. Supplemental imaging with ICE has been shown to be effective in distinguishing TAVR characteristics while improving spatial resolution and providing immediate results.

75. PRINTING AND VALIDATING VASCULAR AND AIRWAY ANATOMIC 3D MODELS FROM 3D ROTATIONAL ANGIOGRAPHY.

Jenny E. Zablah¹, Alex Haak², Nicholas Jacobson³, Michael DiMaria¹, Gareth Morgan¹

¹University of Colorado, Aurora, USA. ²Philips Healthcare, Andover, USA. ³Inworks/University of Colorado, Aurora, USA

Background: Three-dimensional (3D) modeling can be used to transform cross-sectional imaging studies into physical models. The applications for these models are growing rapidly in treatment of congenital heart disease, such as surgical planning in the setting of complex cardiac anatomy. 3D Rotational angiography (3DRA) datasets are not routinely used for 3D printing, but the superior spatial resolution of these images makes them ideal for creating high-quality 3D models that include not just vascular structures but also their relationship with the airway. Our aim was to create and validate 3D heart models from 3DRA datasets in children with congenital heart disease.

Methods: 3DRA were performed, when clinically indicated, in children undergoing cardiac catheterization at Children's Hospital of Colorado using a Philips Azurion System between January-April 2019. 3DRA datasets were exported in DICOM format from the XtraVision workstation. The 3DRA datasets were imported into Materialise Mimics inPrint 3.0. Stereolithography files (STL) were created and post-processed for printing. The STL files were printed using either a Stratasys Connex3 Objet 260, Stratasys J750 or Dynamism Ultimaker S5 printers. For quality assurance, the internal lumen of printed models was coated with Isovue contrast, placed under fluoroscopic imaging and 3DRA was performed. Five key areas of interest were measured in the original and the model's 3DRA, measurements were also obtained using XperCT function in the XtraVision workstation; using a multi-slice 3D view of the vascular structures and the airway; and were compared using linear correlation and t-tests.

Results: Over a 4-month period, eight children (age 30 days-13 years) had a 3DRA that was used to create a 3D model; five models had airway and vascular structures segmented and printed. These included patients with: severe proximal right pulmonary artery stenosis, single ventricle patient status-post Fontan palliation, tetralogy of Fallot (TOF) and multiple aorto-pulmonary collaterals, and status-post Glenn operation both pre- and post-left pulmonary artery stent placement. In two cases, only vascular structures were segmented: patient with TOF and anomalous right coronary artery and patient with aortic arch re-coarctation. Measurements from the original and the 3D models' 3DRA showed excellent correlation ($R^2=0.99$, $p<0.05$). There was no statistical difference between both 3DRA measurements (paired t-test: $p=0.02$). The mean difference between the original and the model's 3DRA was 0.1 ± 0.4 mm. The segmentation time was 30-90 minutes. The printing time ranged from 3-8 hours/model. Using XperCT, the relationship of the airway and the blood vessels was measured with no statistical difference between

the airway/blood vessel relationship of the original and the 3D model's 3DRA (paired t test: $p=0.11$).

Conclusions: Using 3DRA datasets, we created a novel workflow for segmenting and printing 3D models in patients with complex congenital heart disease not just including vascular structures but also airway. We validated this approach by comparison of patient and model 3DRA datasets, demonstrating excellent correlation. 3DRA has been proven useful for diagnostic purposes, procedural guidance with overlay in live fluoroscopy and now for printing 3D models with quick turnaround to enhance surgical and interventional planning.

76. COMPARISON OF POST-OPERATIVE COURSE OF TETRALOGY OF FALLOT PATIENTS WITH AND WITHOUT EARLY RIGHT VENTRICULAR OUTFLOW TRACT (RVOT) BALLOONING

Caitlin Heyden¹, Jane Cerise², David Meyer¹, Shilpi Epstein¹

¹Cohen Children's Medical Center of New York, New Hyde Park, USA. ²Feinstein Institute for Medical Research, Manhasset, USA

Background: Tetralogy of Fallot (TOF) is the commonest cyanotic congenital heart disease with a continuum of severity depending on the degree of pulmonary outflow obstruction. Controversy exists still regarding the management of cyanotic patients in early infancy; specifically, a staged approach versus full repair at an earlier age. The sub-group of TOF patients with early cyanosis (higher morbidity and mortality) in whom single stage repair carries high risk, would benefit from planned delay. Studies have shown transcatheter pulmonary balloon dilation in the right ventricular outflow tract (RVOT) is an effective non surgical means of early palliation.

Objective: We investigated the post-operative course in TOF patients after full repair that underwent palliative RVOT intervention for early cyanosis (a higher risk group) with those that had no prior intervention and a saturation $> 85\%$. We hypothesize that the RVOT palliated patients did as well as lower risk patients in the early post-operative period.

Methods: A retrospective chart review of all patients who underwent full repair for tetralogy of Fallot from 1/2013-3/2018 was done. All patients with TOF who underwent single stage surgical repair < 1 year old with pulmonary valve present and functional at birth were included. Primary outcomes included duration of mechanical ventilation, junctional ectopic tachycardia (JET) and length of stay (LOS). Secondary outcomes included a variety of

post-procedural complications (including duration of inotropes, fluid requirements, effusions, residual defects).

Results: Total of 53 TOF patients during the above time frame. 38 patients met inclusion criteria of which, 32% (12 of 38) underwent cath pre-operatively and 68% (26 of 38) did not. The group that underwent RVOT ballooning were smaller and younger with lower oxygen saturations at time of full repair. Median LOS was 8 days (95% CI: 5 to 14) in patients who had cath, 6 days (95% CI: 5 to 10) in those who did not. Median duration of intubation was 2 days (95% CI: 0.5 to 4) in patients who underwent cath, and 1 day (95% CI: 0 to 1) in patients who did not. Overall, 24% (9 of 38) patients had JET post-op. No significant association was observed between cath status and LOS, duration of intubation or JET.

Conclusions: At time of full repair patients typically considered higher risk and underwent RVOT ballooning still had surgery at smaller size and younger age than those who did not. However we found no associations between cath status and longer LOS, duration of intubation or JET compared with patients who did not require cath interventions. We are able to delay surgery in patients who would have needed early single stage or even refrain from multi-stage surgical approach without increase in morbidity or mortality. While a limitation of this study is the sample size and our ability therefore to assess statistical significance, it provides helpful data in assessing our current approach of delaying surgical intervention in this TOF population.

77. PERCUTANEOUS CLOSURE OF PERSISTENT ARTERIOUS DUCTUS IN PREMATURE INFANTS WITH AMPLATZER DEVICE DUCT OCCLUDER II AS: EXPERIENCE IN COLOMBIAN INFANTS

Alonso Gómez^{1,2}, Laura Tatiana Gómez³, Andrés Marin^{1,2}

¹Clinica San Rafael Pereira, Pereira, Colombia. ²Hospital San Jorge - Imágenes Diagnosticas, Pereira, Colombia. ³Sociedad Cardiovascular del Eje Cafetero, Armenia, Colombia

Objective: To describe our experience with percutaneous closure of patent ductus arteriosus (PDA) in preterm infants using the Amplatzer Duct Occluder II Additional Size device (ADO II AS) in 7 centers in Colombia.

Methods: Retrospective analysis of data of 12 preterm infants with symptomatic PDA who underwent to percutaneous closure with the ADO II AS device, made by our team in 7 centers in Colombia from 2013 to 2019. Selection of cases was given by weight (g), ductus size, hemodynamic repercussion by clinical and ultrasound (US) and failure of pharmacological closure. Except for one case, the

approach was venous femoral in all patients, the position of the occluder was directed by X-ray and US, avoiding arterial injury.

Results: The percutaneous closure of PAD was performed in 12 premature infants with a gestational age between 27 and 35 weeks (median 27.5 weeks) and a median weight of 1927g (range of 1290 to 2800g). The ductus type C was the most frequent in this population (75%) with a median for ductal diameter of 3.8. The device was successfully implanted in all cases, frequently used the one with dimensions of 5x4mm (n=5), followed by 5x2mm (n=3). The median fluoroscopy was 8.8 minutes (range 2 to 16 minutes) and mean procedural time of 60 minute. Complete closure was achieved in all patients. Complications included were mild stenosis of the left pulmonary branch (n = 3), initial slight residual shunt (n = 1) and deterioration of the previous left ventricular dysfunction (n = 1). There were no deaths related to the procedure, embolization, or aortic obstruction.

Conclusion: According to our experience in preterm infants, percutaneous closure of DAP with ADO II AS is a safe and effective alternative to standard surgical treatment. The US guidance prevents arterial access and decreases the risk of arterial vascular injury in these population.

Keywords: Patent ductus arteriosus, premature infants, percutaneous intervention.

78. PERCUTANEOUS ANGIOPLASTY IN A RARE CASE OF PULMONARY ARTERY CALCIFICATION AFTER TWIN-TO-TWIN TRANSFUSION SYNDROME

Steven Healan, George Nicholson, Dana Janssen, Thomas Doyle

Vanderbilt Children's Hospital, Nashville, USA

Background: Twin-to-twin transfusion syndrome complicates 10-30% of monochorionic twin pregnancies, and is associated with various cardiac defects, primarily affecting the recipient twin. One rare complication is pulmonary artery calcification. Sporadic case reports have described this process with prognosis varying from spontaneous regression of calcification to progression resulting in death or requiring surgical pulmonary arterioplasty. Here we present a case of progressive pulmonary artery calcification in a recipient of twin-to-twin transfusion, which was successfully palliated with percutaneous angioplasty. This has not previously been described in the literature.

Case: A recipient of twin-twin transfusion had developed diffuse neonatal calcification of her pulmonary arteries.

Cardiac catheterization in early infancy demonstrated suprasystemic right ventricular pressure and severe branch pulmonary artery stenosis. Due to heavy calcification, angioplasty was not attempted and she was followed conservatively. At clinical follow up at 3 ½ years old, her parents reported that she was easily short of breath with any activity. Her echocardiogram showed a severely dilated right ventricle with depressed systolic function. Due to the risk of further right ventricular failure and potential life-threatening arrhythmias, she was referred for percutaneous evaluation and possible intervention. ECMO support was on standby, and a cardiothoracic surgeon was available to intervene emergently if necessary. At catheterization, right ventricular systolic pressure was 180% systemic. Heavy calcification was seen in the proximal segmental branches to both lungs. The proximal left lower lobe pulmonary artery branch narrowed dramatically to 1.3 to 2 mm. The vessel was cannulated with a 0.014" wire and serial dilation was performed first with a 4 mm cutting balloon and then a 5 mm cutting balloon. Angioplasty of the lingular branch was then performed with a 2.5 mm coronary balloon. Repeat angiography demonstrated relief of left-sided obstruction without any extravasation of contrast. There was a thread-like connection to the right lower lobe that measured approximately 1.3 mm in diameter. This was cannulated with one 0.014" wire, and a separate 0.014" wire was positioned in the anterior segment of the lower lobe. Balloon angioplasty was performed along the length of the narrowed vessel with a 4 mm cutting balloon. Final angiography showed relief of obstruction bilaterally without contrast extravasation. Pressure measurements showed that right ventricular pressure was reduced from 180% systemic to 80% systemic at the end of the case. The patient was admitted to the ICU to monitor for reperfusion injury and was discharged home after two days without incident. After five months in clinical outpatient follow-up, parents reported a sustained increase in her activity level and endurance.

Discussion: Our case is the first to demonstrate that a percutaneous approach can be safely and effectively employed for the rare patient with calcified pulmonary artery stenosis after twin-to-twin transfusion syndrome. Previous reports have only demonstrated relief of obstruction with surgical arterioplasty. Even with heavy calcification, a percutaneous approach could be considered as an alternative to surgery in patients with a poor prognosis and failing right ventricle.

79. OCCLUSION OF MULTIPLE PULMONARY ARTERIOVENOUS FISTULAS IN A GIRL WITH HEREDITARY HEMORRHAGIC TELANGIECTASIA

Marco Ruiz-Ontiveros, Alejandro Flores-Arizmendi, Antonio Salgado-Sandoval

National Medical Center "20 De Noviembre", Mexico City, Mexico

Hereditary hemorrhagic telangiectasia or Osler Weber Rendu syndrome is an autosomal dominant multiorgan disorder caused by a genetic defect in the protein transforming growth factor, resulting in a fibrovascular dysplasia with multiple arteriovenous malformations accompanied by telangiectasia also present with symptoms such as cyanosis, dyspnea, high output heart failure, hemoptysis and paradoxical embolization. Pulmonary arteriovenous fistula (PAVF) is abnormally dilated vessels that provide a right-to-left shunt between pulmonary artery and pulmonary vein. The fistula itself is typically a thin-walled aneurysmal vascular structure that tends to increase over time.

Case Report: A 9-year-old girl was referred to our institution due to chronic cyanosis, dizziness and headache during the last month. Her family history was negative for cardiac diseases. On physical examination, peripheral cyanosis (oxygen saturation: 70%). She had no murmurs. EKG showed cardiac axis to the right (150°). An echocardiogram reported heart without structural anomalies. CT scan reported a PAVF in the lower left lobe, a pulmonary sequestration of 8.4mm. The interventional catheterization was performed to occlude the fistula. Under general endotracheal anesthesia, the right femoral vein was cannulated. A 7 Fr Mullins sheath was positioned over a exchange guidewire in the left lower lobal artery. With the aid of a Head Hunter catheter the vessels were opacified with contrast injections. We start with the central one, using the same sheath a 10mm Amplatzer Vascular Plug was advanced and exteriorized, After confirmation of proper positioning, the device was released. The second one that was near for few millimeters, it was opacified and after measured a 12mm Amplatzer Vascular Plug was advanced and released after confirmation of proper positioning. This process was repeated with other two PAVFs, both close to the previous, using 6mm and 8mm Amplatzer Vascular Plug devices. A final angiogram demonstrated complete occlusion of the four vessels. The peripheral oxygen saturation on room air immediately increased from 70% to 95%

After 6 years the patient was asymptomatic, but the oxygen saturation decreased to 82%, so it was decided to perform a new diagnostic and interventional catheterization. Under general endotracheal anesthesia, the right femoral vein was cannulated. A 6Fr sheath was positioned over a exchange guidewire in the left lower lobal artery. With the aid of a 6Fr Judkin right catheter the vessel were opacified with contrast injections. It was a unique and large vessel.

An 8mm Amplatzer Vascular Plug was advanced and exteriorized, After confirmation of proper positioning, the device was released, a control angiogram was performed without evidence of another PAVF. The oxygen saturation increased to 92%.

We present a successful case of occlusion of multiple pulmonary arteriovenous fistulae in the same pulmonary lobe with five Amplatzer Vascular Plug devices in two different procedures with 6 years of difference. The patient is now asymptomatic with normal oxygen saturation, with a close monitoring for the risk of new fistulas.

80. TRANSCATHETER PDA CLOSURE USING THE AMPLATZER PICCOLO™ OCCLUDER IN INFANTS WEIGHING ≤ 1 KG

Shyam Sathanandam¹, Thomas Forbes², Matthew Gillespie³, Brian Morray⁴, Darren Berman⁵, Shabana Shahanavaz⁶, Thomas Jones⁷, Evan Zahn⁸

¹LeBonheur Children's Hospital, Memphis, USA. ²Children's Hospital of Michigan, Detroit, USA. ³Children's Hospital of Philadelphia, Philadelphia, USA. ⁴Seattle Children's Hospital, Seattle, USA. ⁵Nationwide Children's Hospital, Columbus, USA. ⁶St. Louis Children's Hospital, St Louis, USA. ⁷Seattle Children's Hospital, Seattle, United Kingdom. ⁸Cedars-Sinai Medical Center, Los Angeles, USA

Background: The presence of a hemodynamically significant patent ductus arteriosus (PDA) in extremely low birth weight (ELBW) infants has been associated with an increased risk of morbidity and mortality. Historically, transcatheter closure of PDA in ELBW infants has not been performed for a variety of reasons, including the fear of patient fragility, and the absence of a suitable PDA closure device.

Methods: A single arm, multicenter, prospective, investigational study was conducted in the United States to test the efficacy and safety of the Amplatzer Piccolo™ Occluder in infants ≥ 700 g with PDA ≤ 4 mm in diameter. The objective of this report is to describe the results of using the Amplatzer Piccolo™ Occluder for PDA occlusion in a subgroup of ELBW infants that weighed ≤ 1 kg at the time of the procedure.

Results: Transcatheter PDA closure was attempted in 33 patients weighing ≤ 1 kg at the time of the procedure. Implant success was 100%. All implants were performed via an antegrade approach without arterial access. There was 94% PDA closure post-procedure. Two patients had mild residual shunts that resolved on follow-up. There were no instances of device embolization or vascular access injury. Serious adverse events occurred

80. Table 1.

Demographics:

Gestational age at birth (weeks)	24.7 ± 1.3 (33)
Mean ± SD (n)	(22, 28)
Range (Min, Max)	
Birth Weight (gm)	696 ± 143 (33)
Mean ± SD (n)	(430, 1060)
Range (Min, Max)	

Comorbidities:

Mechanical Respiratory Support Required	100.0% (33/33)
Respiratory distress syndrome (RDS)	93.9% (31/33)
Intraventricular hemorrhage (IVH)	51.5% (17/33)
Sepsis	24.2% (8/33)
Necrotizing enterocolitis (NEC)	15.2% (5/33)
Inotropic Support Required	12.1% (4/33)

Baseline Characteristics:

Age at Implant (days)	25.4 ± 9.2 (33)
Mean ± SD (n)	(10, 51)
Range (Min, Max)	
Weight at Implant (grams)	869 ± 97.6 (33)
Mean ± SD (n)	(700, 1000)
Range (Min, Max)	
PDA minimal diameter (mm)	3.01 ± 0.59 (31)
Mean ± SD (n)	(1.8, 4.0)
Range (Min, Max)	
PDA length (mm)	10.33 ± 1.65 (31)
Mean ± SD (n)	(6.1, 14.0)
Range (Min, Max)	

Procedure Characteristics:

Procedure Time (min)	42.3 ± 19.3 (33)
Mean ± SD (n)	(14, 93)
Range (Min, Max)	
Fluoroscopy Time (min)	8.3 ± 6.2 (33)
Mean ± SD (n)	(3, 31)
Range (Min, Max)	
IV Contrast (mL/kg)	2.65 ± 1.48 (33)
Mean ± SD (n)	(0.00, 5.92)
Range (Min, Max)	
Femoral Arterial Access	0% (0/33)
Heparin Usage	9.1% (3/33)

in 2 patients (6%) including: hemolysis (1), and aortic arch obstruction requiring stent implantation (1). Survival was

97% at 30-days follow-up. All other results are summarized in the table below.

Conclusions: The high rate of implant success and the low rate of device and procedure related serious adverse events observed in this subset of patients supports the safety and effectiveness of transcatheter PDA closure using the Amplatzer Piccolo™ Occluder in ELBW infants.

81. THE AMPLATZER DUCT OCCLUDER [ADOII] AND AMPLATZER DUCT OCCLUDER ADDITIONAL SIZE DEVICES [ADOIIAS] FOR PATENT DUCTUS ARTERIOSUS CLOSURE: A RETROSPECTIVE COMPARATIVE SINGLE CENTER STUDY

Kristoffer Steiner^{1,2}, Elchanan Bruckheimer¹, Michael Levinzon³, Alexander Lowenthal¹, Tamir Dagan¹, Gabriel Amir⁴, Einat Birk¹

¹Section of Pediatric Cardiology, Schneider Children's Medical, Tel Aviv, Israel. ²Section of Pediatric Cardiology, Astrid Lindgren Children's Hospital, Stockholm, Sweden. ³Section of Pediatric Anesthesiology, Schneider Children's Medical, Tel Aviv, Israel. ⁴Section of Pediatric Cardiothoracic Surgery, Schneider Children's Medical, Tel Aviv, Israel

Aim: To Evaluate ADOII and ADOIIAS for transcatheter PDA closure. ADOIIAS has smaller retention discs reducing flow disturbance but residual leak and embolization may increase.

Methods: Retrospective review of all patients undergoing PDA closure with an Amplatzer device between January 2008 and June 2018 in our institution. Data from procedure and after 6 months were collected.

Results: 548 patients, median age 2.8 years [0.3-46.8] years and median weight 13 kg [3.5-82], were referred for PDA closure. 547 had successful implantation [269 ADOII, 250 ADOIIAS, 28 AVPII]. ADOII vs. ADOIIAS demonstrated smaller patients with larger PDA diameters [11.5 [5.2-79.0] vs 17.0 [4.0-82.0], $p < 0.001$, 2.3 mm vs 1.9 mm, $p < 0.001$, respectively]. Mean device diameter was similar for both groups. Closure rate at follow-up was similar for all devices. Complications and Follow Up: All patients were discharged the following day with normal distal pulses palpated and with no venous or arterial complications. ADOIIAS: There were four implantation failures, two in a type A PDA and two in a type C. In three of these cases, the ADOIIAS was demonstrated to be unstable before release. The device was retrieved in all cases and the PDA was closed successfully with an AVPII 6mm device. There was one device embolization to the right pulmonary artery which was successfully retrieved and the PDA closed with an AVPII 6mm

with no further complications. On mean follow up 8.4 ± 15.2 months, one patient had mild left pulmonary artery stenosis on echocardiography with a maximal velocity of 2.5 m/sec. There were no cases of aortic flow disturbance. ADOII: There were two cases of device embolization to the right pulmonary artery, one patient was treated with surgical PDA closure the same day. In the other patient the device was successfully retrieved and the PDA was closed using an ADOII 8-6 device. On mean follow up 11.9 ± 20.4 months, there were five cases of LPA stenosis, four mild and one significant who underwent balloon dilation four years later with good result. There were no cases of aortic flow disturbance. One patient suffered from endocarditis and a residual shunt after PDA closure with an ADOII 5-4mm device. The shunt eventually disappeared on echocardiographic follow up 14 months after implantation.

AVPII: On mean follow up of 7.4 ± 13.4 months there were no complications.

Conclusions: The lower profile ADOIIAS device was used in larger patients with smaller PDA diameters with an excellent closure rate and very few complications. The major concerns of embolization and residual leak due to its smaller retention disks were not supported when a device:PDA diameter of approximately 2:1 was maintained.

In our opinion, the ADOIIAS device is a safe and effective device for transcatheter PDA closure and is our preferred choice for transcatheter closure of small to moderate PDAs in all age groups. We prefer a retrograde approach through a 4Fr system with device waist-to- PDA diameter ratio of greater than 2:1 with a length that places the aortic disc inside the diverticulum.

82. PERCUTANEOUS TREATMENT OF CONGENITAL HEART DISEASES IN UNUSUAL SITUATIONS.

Edmundo Oliveira^{1,2}, Marco Antonio Moura^{1,2}, Jose Augusto Barbosa^{1,2}

¹Hospital Felício Rocho, Belo Horizonte, Brazil. ²Hospital Vila da Serra, Belo Horizonte, Brazil

Introduction: The number of patients treated through interventional catheterization has been increasing according to the experience of the interventionists and according to the availability of new tools. Some rare special situations may require the off-label use of materials or the accomplishment of the procedure through unusual vascular accesses.

Objective: To report a series of cases with favorable outcome where was necessary a off-label use of materials or unusual vascular accesses.

Cases: The procedures were performed in a premature baby, 980 grams with severe coarctation of aorta, where a istmoplasty was performed with coronary stent by axillary artery puncture; in a boy, 12 kg, left isomerism, dextrocardia, absence of right SVC where a atrial septal defect was closed by the left internal jugular vein; in a neonate, 2,8 kg, to performer a pulmonary vein stenting to treat a severe stenosis after a surgery to correction of total anomalous pulmonary venous return by hybrid procedure; in a girl for multiples pulmonary arteriovenous fistulas occlusion with coils and glue; in a patient to treat a pseudoaneurysm in a branch of the right hepatic vein with coils; in a patient with large atrial septal defect occlusion by trans hepatic puncture and in a patient for closing a anomalous artery from descendent aorta to lungs using PLUGs.

Results: All patients were treated successfully. All patients but one did not need any further intervention. The patient that had a stent implanted in pulmonary vein in a hybrid procedure was discharged and was being followed for the possibility of further dilation of the stent. No deaths or major complication occurred in this series.

Discussion and Conclusion: Although we do not have specific materials for the treatment of all congenital heart diseases that can be treated percutaneously and we can not always use the usual accesses for procedures, the use of alternative pathways must be considered. The off-label use of available materials, increasing experience among interventionist and the possibility to work with experts from different areas has been made possible the percutaneous treatment of rare and unusual congenital heart diseases.

83. SURGICAL PLACEMENT OF ADJUSTABLE PDA BAND FACILITATES DUCTAL STENTING IN STAGE 1 HYBRID PALLIATION PROCEDURE

Sharib Gaffar^{1,2,3}, Joanne Starr¹, Richard Gates¹, Michael Recto¹

¹CHOC Children's Hospital of Orange County, Orange, USA.

²University of California Irvine, Irvine, USA. ³Miller Children's and Women's Hospital Long Beach, Long Beach, USA

Background: The hybrid stage I procedure is an accepted alternative for high-risk patients with hypoplastic left heart syndrome (HLHS) facing increased mortality following the Norwood operation. The procedure involves bilateral pulmonary artery banding, atrial septostomy, and stenting of the patent ductus arteriosus (PDA). Prostaglandin infusion

(PGE) is required to maintain ductal patency, and most interventionalists discontinue PGE prior to the procedure to modulate PDA caliber. Although effective in maintaining ductal patency, dose adjustment of PGE cannot accurately predict ductal diameter, which is crucial in selection of appropriate stent size. The patients in this case series were maintained on PGE until just prior to placement of the adjustable PDA band. The adjustable PDA band was placed after bilateral pulmonary artery banding and prior to PDA stenting. When required, the PDA band was adjusted to desired diameter following angiographic review prior to PDA stent implantation.

Methods: Six patients (4 males, 2 female), 5 with HLHS and 1 with left ventricular hypoplasia, mean age 8 days (range 3-16), mean weight 2.72kg (range 2-3.2) underwent hybrid stage 1 palliation due to anatomic or weight concerns regarding viability of the Norwood procedure. In 5 cases, banding of the pulmonary arteries and stenting of the PDA were completed as a single procedure; in 1 case, a patient had bilateral pulmonary artery bands completed initially, followed by PDA stenting 11 days later. Umbilical tape was initially wrapped around a 6mm Hagar and cut to size. It was then encircled around the PDA and secured with two hemoclips. Following PDA banding, a 7F sheath (Cook) was positioned in the main pulmonary artery (MPA) above the pulmonary sinuses of Valsalva. An angiogram was then performed through the sheath and the PDA with ductal band was measured. The band was positioned in the midportion of the PDA with mild constriction. Based on the angiographic appearance, the band was loosened (removal of 1 clip) or tightened (addition of 1 clip). A follow-up angiogram was then performed. Once ideal ductal diameter was obtained, either a Cordis Genesis (Cardinal Health) premounted balloon-expandable stent, or EV3 Everflex (Medtronic) self-expandable stent was utilized for ductal stenting, with the hemoclips anchoring the PDA band in place used as a landmark. Angiography post-PDA-stenting confirmed proper stent placement. The sheath and wire were then removed, and MPA puncture site repaired. All 6 patients underwent successful PDA stenting without complication, and postoperative courses were uneventful.

Results: All patients had large PDAs echocardiographically, with average diameter 7.35mm (range 6.3-8.7). Post-banding average diameter angiographically was 4.9mm (range 4.2-5.8). Post-stenting average diameter angiographically was 6.2mm (range 5-7.4).

Conclusion: Adjustable PDA banding with umbilical tape in the stage 1 hybrid procedure for HLHS allows for PGE

infusion until the time of procedure, serves as a landmark for ductal stent implantation, and decreases the likelihood of stent embolization or migration by creating a mild constriction. More importantly, it allows both the surgeon and interventionalist the ability to determine the ideal ductal diameter prior to PDA stent implantation.

84. TRANSCATHETER CLOSURE OF MODERATE TO LARGE PERIMEMBRANOUS VENTRICULAR SEPTAL DEFECTS IN CHILDREN WEIGHING ≤ 10 KG

Ajith Ananthkrishna Pillai¹, Sasinthar Rangasamy¹, Vidhyakar Balasubramanian²

¹JIPMER Hospital, Pondicherry, India. ²PSG Hospital, Coimbatore, India

Background: Transcatheter device closure of ventricular septal defect (VSD) is an alternative to the gold standard surgical closure. Device closure of moderate to large perimembranous VSD (pm VSD) is considered technically challenging in smaller children weighing ≤ 10 kg. Very few studies are published on the outcomes of the same.

Methods: Descriptive single center retrospective study. Data of 49 children ≤ 10 kg with moderate to large pmVSDs taken up for trans-catheter device closure in our institute were analysed and their follow-up details were reviewed.

84. Table 1. Baseline patient characteristics

1. Total number of patients (n)	49
2. Females, n (%)	26 (53)
3. Median Age, months (IQR)	18 (13-22)
4. Age in months, n (%)	
a. <12 months (%)	5 (10)
b. 12-18 months (%)	19 (39)
c. 18-24 months (%)	14 (29)
d. 24-30 months (%)	11 (22)
5. Weight, kg (Mean \pm SD)	7.9 \pm 1.2
6. Mean size of the VSD, mm (Range)	5.98 (4-12)
7. Size of the aortic rim, mm (Mean \pm SD)	3.9 \pm 0.8
8. LVEDD, mm (Mean \pm SD)	35.45 \pm 8.8
Z score (Mean \pm SD)	+2.2 \pm 0.62
9. VSD Pressure gradient by doppler, mmHg (Mean \pm SD)	35.23 \pm 17.85
10. Pulmonary artery systolic pressure, mmHg (Mean \pm SD)	39.12 \pm 10.90
11. Mean pulmonary artery pressure, mmHg (Mean \pm SD)	15.34 \pm 4.82
12. Qp/Qs (Mean \pm SD)	2.54 \pm 1.78

84. Table 2. Procedure details

1. Successful deployment of the device, n (%)	42/49 (85.7)
2. Mean size of the device used, mm (Range)	8.26 (4-14)
3. Anesthesia used, n (%)	49 (100)
General anesthesia	
Techniques utilized, n (%)	
Antegrade with av loop	33 (78.6)
Antegrade without av loop	6 (14.3)
Retrograde	3 (7.1)
Types of devices used, n (%)	
1) Cera PDA occluder (LifeTech)	17 (40.5)
2) Cera VSD occluder (Lifetech)	8 (19)
3) Amplatzer duct occluder Type II	6 (14)
4) Cocoon duct occluder	6 (14)
5) SearCare PDA occluder	2 (5)
6) Amplatzer muscular VSD occluder	1 (2.5)
7) Amplatzer membranous VSD occluder	1 (2.5)
8) Amplatzer vascular plug II	1 (2.5)
Procedure duration in minutes (Mean \pm SD)	45.6 \pm 12.6
Hospital stay, days (Mean \pm SD)	2.1 \pm 0.4

Results: Out of the 87 patients referred for VSD closure, 49 patients qualified for the inclusion criteria. Median age was 18 months (IQR 13-22). Successful device deployment was achieved in 42 patients (85.7%). Mean size of the VSD by transthoracic echocardiography (TTE) was 5.98 mm (Range: 4-12). Mean waist size of the device used was 8.26 mm (Range: 4-14). There was one device embolization. Minor complications like device related persistent new aortic regurgitation was noted in one patient and mild tricuspid regurgitation and transient heart block occurred in two patients each. There was no mortality or CHB requiring permanent pacemaker implantation immediately or during mid-term follow-up (mean follow-up: 19 months; Range: 2.5 – 72.5).

Conclusion: Device closure of moderate to large pm VSDs in children weighing ≤ 10 kg is feasible and safe. We had a success rate of 85.7%. Careful selection of patients and avoidance of oversizing the defect makes the immediate and mid-term results acceptable.

85. LEFT ATRIAL DECOMPRESSION IN A PATIENT WITH COMPLEX CONGENITAL HEART DISEASE. CHALLENGES OF ATRIAL FLOW REGULATOR IMPLANTATION NEXT TO A PRE-EXISTING ATRIAL STENT

Robin Hay Son Chen^{1,2}, Simon Lam³, Pak Cheong Chow¹, Adolphus Kai Tung Chau¹, Tak Cheung Yung¹

¹Department of Paediatric Cardiology, Queen Mary Hospital, Hong Kong, Hong Kong. ²Department of Paediatrics and Adolescent Medicine, The University of Hong Kong, Hong Kong, Hong Kong. ³Department of Medicine, Hong Kong, Hong Kong

The atrial flow regulator (AFR) is currently under compassionate use for right ventricular failure due to pulmonary hypertension (PHT) or heart failure with left atrial (LA) hypertension. We report the challenge in implanting the AFR for LA decompression in a patient with palliated congenital heart disease with LA hypertension despite an existing atrial stent. The patient presented at 16 years old with worsening exercise tolerance. Diagnosis was atrioventricular discordance, double outlet systemic right ventricle, subpulmonary ventricular septal defect, severe tricuspid regurgitation and stenosis with PHT. Patient was palliated with mechanical tricuspid valve (TV) replacement and pulmonary artery (PA) banding. Physiological "total" repair was deemed impossible during intra-operative assessment. Despite initial improvement, the patient developed progressive LA hypertension secondary to a relatively small mechanical TV with recurrent symptomatic atrial tachycardia (AT) and was in NYHA class II. Catheterization at age of 18 showed pulmonary arterial wedge pressure (PAWP) of 15mmHg with mean PA pressure of 35mmHg hence atrial septostomy and stenting with 6x18mm Genesis stent was performed. However, recurrence of LA hypertension was evident subsequently, with LA dilatation, AT and worsening of symptoms. Catheterization at 22 years old showed LA pressure of 22mmHg and pulmonary hypertension despite a patent atrial stent. Further aggressive dilatation of the stent was deemed risky since the stent was located at the antero-inferior septum which was in close proximity to the mechanical TV. The heart team decision was to workup for a second transcatheter atrial communication creation. The AFR appear to be an ideal device to create such reliable and sizable atrial communication, yet the challenge was the positioning of the AFR in the presence of a pre-existing atrial stent. Detailed pre-procedural echocardiogram, CT and 3D model suggested that there would be adequate landing zone for the largest AFR. The procedure was then performed under general anaesthesia when patient was 23 years old. Trans-septal puncture using RF-trans-septal needle (CO curve, Baylis) and SL1 sheath was performed with trans-esophageal echocardiogram (TEE) guidance to ensure a posterior-superior location, target site being as far away as possible from the pre-existing atrial stent, to minimize the risk of device interaction, yet ensuring enough space for full deployment of the AFR. After successful trans-septal puncture, progressive balloon dilatation was performed using balloons up to 14x20mm. AFR (10mm fenestration/5mm height) was implanted via

a 14F Occlutech delivery sheath. TEE showed satisfactory device position and no interaction with the pre-existing atrial stent. The PAWP and mean PA pressure reduced from 27mmHg to 16mmHg and 42mmHg to 33mmHg respectively. Intriguingly the Qp/Qs decreased from 4.88 to 3.25 while cardiac index increased slightly. The device was released after confirmation of a favourable haemodynamics. Follow-up echocardiography 1 month post-procedure showed patent stent and AFR with stable position. The TV mean gradient reduced from 18mmHg to 7mmHg indicative of a significant LA decompression. This is the first reported case of AFR implantation in close proximity with another atrial decompressive device. The report highlighted the importance of pre-procedural planning and precision in trans-septal puncture in achieving good results.

86. PDA CLOSURE WITH A MFO

Jesús Damsky Barbosa¹, Liliana Ferrin², Victorio Lucini¹, Adelia Marques Vitorino¹, José Alonso³, Marcelo Rivarola⁴, Julio Biancolini¹, Fernanda Biancolini¹, Judith Ackerman¹, Ines Martinez¹, Ana María Susana de Dios⁵

¹Pedro de Elizalde, Hospital, Buenos Aires, Argentina. ²Instituto del Corazón, Corrientes, Argentina. ³High complexity "JUAN DOMINGO PERON" Hospital, Formosa, Argentina. ⁴University Austral Hospital, Pilar, Argentina. ⁵Mitre Institution, Buenos Aires, Argentina

Goal: Demonstrate the new Multifunctional Occluder (MFO) in the closure of the PDA

Materials and Method: Since 2018, the MFO is used in Argentina. 9 procedures were performed: 8 patients (p) pediatrics and 1p adult (p=9) with Median age: 3.75 yo and Median weight: 11.2 kg (See table 1)

2 p below 10kg. 2 p were treated with the new protocol (Eco guided without arterial approach)

Prosthesis description: Nitinol mesh with 2 equal diameter discs joined by a truncated cone shaped waist. The base of the cone is attached to the left disc or high pressure and the truncated vertex is attached to an arm that joins the right disc or low pressure. Both discs have a double sided screw for retrograde or antegrade approach. The denomination of the prosthesis is given by the 2 diameters of the waist (base and truncated vertex).

Statistical Analysis: The T-test method was used to compare the right and left diameters of the PDA with the right and left diameters of the prosthesis where $p < 0.05$.

Results: 9 p with complete occlusion during the immediate period (see table 2).

The follow-up mean time was: 9 m (1 to 13 m).

Pulmonary pressures: systolic mean: 26 mmHg (21 to 44 mmHg) and the diastolic mean: 24mmhg (7 to 25 mmHg).

The average QP / QS: 2.28 / 1 (1.8 to 3).

Diameters:

Entry: X: 3.67 (5 to 10 mm)

Right side: X: 3.90 (3 to 8 mm)

Left diameter of the waist: 6.06 mm (5 to 10 mm)

Right diameter of the waist: 3.90 mm (3 to 8 mm)

When the left and right PDA diameters are linked to the prosthesis diameters, the left diameter has a NON significant difference of 2.39 mm (p:0213) to the left prosthesis diameter and the difference of the right diameter of the prosthesis to the right diameter of the PDA was NON significant either (p:0.399).

Follow-up: there were no complications.

Discussion: The bibliography suggests using devices 2 to 4 mm greater than the right diameter.

If the waist diameter is strictly taken into account, there is a risk that the discs can generate some type of obstruction in the left pulmonary artery or descending aorta. Therefore when using a waist of the same diameter of the PDA, the risk of embolization or residual permeability are prevented by the presence of the 2 discs.

In the 2p of lower weight, a smaller waist diameter than the corresponding one was used. Nevertheless the goal was fulfilled by the 2 discs that worked closely in the occlusion.

Conclusions:

1. MFO allows the endovascular treatment, observing complete occlusion in the immediate period.
2. As the discs collaborate in the occlusion of the PDA, there is no need to overdilatation of the PDA for final occlusion.
3. During the follow up, no residual gradients were observed in descending aorta and LPA.
4. No displacements or deformities of the prosthesis

were observed either.

5. A greater number of cases are needed to establish meaningful **Conclusions**.

87. USE OF REAL-TIME THREE-DIMENSIONAL TRANSESOPHAGEAL ECHOCARDIOGRAPHY IN CLOSURE OF MULTI-FENESTRATED ATRIAL SEPTAL DEFECTS

James Kuo, Lisa Roten, Steve Muyskens

Cook Children's Medical Center, Fort Worth, USA

The use of real-time three-dimensional (3D) transesophageal echocardiography (TEE) has emerged as an important imaging modality to assist with interventional catheterizations. We describe two cases where 3D TEE delineated anatomy integral to guiding transcatheter device occlusion of multi-fenestrated atrial septal defects (ASDs) not identified by two-dimensional (2D) TEE.

Patient 1 was a 16 year old with large secundum ASD and moderately dilated right ventricle on transthoracic echocardiogram (TTE). 2D TEE demonstrated a large defect measuring 22x20 mm with short 2 mm posterior rim, and a separate anterior defect measuring 5 mm. However, 3D TEE demonstrated a thin band of septal tissue running through the middle of the larger defect, effectively separating it into two defects, one anterior measuring 8x8 mm and the other posterior measuring 10x12. It was felt that this band of tissue was very thin and would be significantly displaced or torn with a sizing balloon. The smaller inferior, anterior defect was crossed under 3D TEE guidance. Inflating the sizing balloon resulted in a significant waist measuring 11.5x11.4 mm without any disruption in the band of tissue. The superior, posterior defect was crossed and the sizing balloon had a waist measuring 16x17.6 mm. Because there was no apparent disruption of the thin band of tissue, it was felt that the tissue would safely support device placement. Initially, a 30 mm Cardioform Septal Occluder was placed in this larger posterior defect, but it did not cover the smallest separate most anterior defect and there was a significant amount of residual shunting posteriorly. A 35 mm Amplatzer Cribriform device was then placed in this defect. The device occluded the most anterior defect and it only left a tiny 2mm residual shunt posteriorly. This device was released. Transthoracic echocardiogram at 4 month follow-up showed no evidence of residual shunting.

Patient 2 was a 19 year old with multi-fenestrated ASD with an inferior defect, separate patent foramen ovale (PFO), and right atrial enlargement seen on TTE. By 2D TEE, the inferior defect measuring 5x11 mm and PFO were confirmed. The

septum primum was redundant and mobile with several poorly localized areas of additional shunting. On 3D TEE, a central defect in the aneurysmal septum was identified having a "fish mouth" appearance, along with multiple peripheral small fenestrations. The entire area of shunting in the septum was measured at 22x22 mm. Under 3D TEE, the central "fish mouth" defect was crossed and an SL1 sheath was placed. A 30 mm Cardioform Septal Occluder was placed through this sheath. The device completely occluded all defects successfully. Transthoracic echocardiogram at 3 month follow-up did not demonstrate residual shunting.

Real-time 3D TEE is an essential imaging modality in the anatomic evaluation of complex multi-fenestrated ASDs. Comprehensive understanding of anatomy is key to guiding catheter course and ensuring optimal device placement. As care teams become more comfortable with real-time image generation and interpretation, 3D TEE has the potential to improve the approach to complex anatomy and shorten procedure times.

88. ACUTE AND MID-TERM OUTCOMES OF TRANSCATHETER PULMONARY VALVE IMPLANTATION IN PATIENTS OLDER THAN 40 YEARS

Osamah Aldoss¹, Kaitlin Carr¹, Shabana Shahanavaz², David Balzer², Daniel Levi³, Jamil Aboulhosn³

¹University of Iowa, Iowa City, USA. ²Washington University in St. Louis, St Louis, USA. ³UCLA Adult Congenital Heart Disease Center, Los Angeles, USA

Objective: Evaluate short and mid-term outcomes of transcatheter pulmonary valve implantation (TPV) in patients older than 40 years of age at time of implant.

Background: TPV is a widely used option for patients with dysfunctional right ventricular outflow tracks (RVOT). Although there are numerous studies detailing acute and intermediate term outcomes of TPV in adolescent and young adult patients, there is a paucity of data on the outcomes of TPV in older patients with more comorbidities. This study seeks to describe the outcome of TPV in patients older than 40 years at three adult congenital interventional programs.

Methods: Retrospective multicenter study of patients older than 40 years at the time of TPV from January 2010 to February 2018. Demographics, procedure details, procedure related complications and follow up data were collected.

Results: A total 75 subjects presented for TPVR with median age of 49.8 (IQ 45-60). Half of the patients 39 (52%) had evidence of NYHA class III or IV heart failure symptoms at time of presentation. The types of substrate included native RVOT in 32 (43%), conduit in 20 (27%) and bioprosthetic valve (BPV) in 23 (30%). Indications for TPV included pulmonary insufficiency (PI) in 37 (49%), stenosis (PS) in 16 (21%) and combined PS/PI in 22 (30%). A total of 65 (87%) had successful TPV. The remaining 10 patients were not able to receive the valve due to non-suitable RVOT in 7 and coronary compression upon balloon testing in 3. The transcatheter valve types used were the Medtronic Melody in 42 (65%), Edwards Sapien S3 in 21 (32%) and Edwards Sapien XT in 2(3%). The Melody valve was the most common used valve in conduits (78%) and BPV (86%) and the Sapien valve in native RVOT (62%). Patients with severe PI had immediate resolution of PI (no patients with more than mild central PI and only one patient with moderate para-valvar leak). Patients presented with PS and PS/PI had significant improvement in peak-to-peak gradient from median of 25.5 to 5.5 mmHg ($p < 0.0001$). There were no procedure related deaths. Adverse procedural events occurred in 4 (5%) as 2 procedure related arrhythmias and 2 peripheral vascular injuries. The median follow up was 2 years (IQ 0.74-3.13). Functional capacity has significantly improved after PVR in the majority of patients (Class III and IV were in 33 (51%) dropped to 10 (15%), $p < 0.001$). There was 4 (6%) total later non-procedure related mortality, 2 (3%) TVR replacement (1 post endocarditis and 1 for re-stenosis of distal conduit beyond the valve), and 1 (2%) listed for heart transplant. Five patients (8%) experienced an episode of infective endocarditis (4 Melody valve (2 conduits, 1 BPV, 1 native) and 1 Sapien S3 valve (native)).

Conclusion: TPV implantation is safe and provides an effective treatment of dysfunctional RVOT in patient older than 40 years of age. Mid-term follow up demonstrates improvement in functional capacity with stable valvular function, however, infective endocarditis occurred in 8% of patients.

89. HYBRID APPROACH TO ESTABLISH RIGHT VENTRICLE TO MAIN PULMONARY ARTERY CONTINUITY IN A NEONATE WITH MUSCULAR PULMONARY ATRESIA, INTACT VENTRICULAR SEPTUM, AND SEVERE TRICUSPID REGURGITATION

Bassel Mohammad Nijres¹, Yasser Al-Khatib^{1,2}, E. Oliver Aregullin^{1,2}, Giedrius Baliulis^{1,2}, Neal Hillman^{1,2}, Yashesh Savan^{3,2}, Jessica Guiles¹, Paul Nelson¹, Dalton Jacobs¹, Bennett Samuel¹, Joseph Vettukattil^{1,2}

¹Spectrum Health Helen DeVos Children's Hospital, Grand Rapids, USA. ²Michigan State University College of Human

Medicine, Grand Rapids, USA. ³West Michigan Anesthesia, Grand Rapids, USA

Introduction: Neonates with muscular pulmonary atresia with intact ventricular septum (PA/IVS) are traditionally managed by surgical intervention. We describe hybrid approach for decompressing the right ventricle (RV) in a neonate with muscular PA/IVS, and severe tricuspid regurgitation (TR).

Case Description: A 3-day-old male was born with muscular PA/IVS, dysplastic tricuspid valve, severe TR, secundum atrial septal defect (ASD), adequate RV size, and tortuous patent ductus arteriosus (PDA) with left-to-right shunt. Prostaglandin E-2 (PGE-2) was initiated to maintain patency of the ductus arteriosus. A multidisciplinary team recommended diagnostic cardiac catheterization for hemodynamic assessment, rule out RV-dependent coronary circulation (RV-DCC), and attempt decompressing the RV via hybrid approach.

Intervention: Hemodynamic assessment showed supra-systemic RV systolic pressure with no angiographic evidence of RV-DCC. However, a large area of the anterior RVOT wall and RV free wall were stained by contrast with small amount of contrast spread in the pericardium. To avoid further trauma to the RV, we elected not to perform simultaneous RV and main pulmonary artery (MPA) angiogram, and proceeded with the planned median sternotomy. Spreading RVOT hematoma was noticed. A purse string suture was placed in the RV free wall below the hematoma. A 7 cm 21-gauge One-Part Percutaneous Entry Needle was attached to the pressure tracing, advanced via the purse-string suture, and directed towards the atretic pulmonary valve. Once a pulmonary artery tracing was obtained, a 0.014" mailman guidewire was inserted inside the 21-gauge needle with the tip in the distal left pulmonary artery. To facilitate stenting the atretic pulmonary valve, a 6-Fr sheath was placed in the RV free wall. The RV wall and atretic valve were dilated with the inner dilator of a 3-Fr sheath. The positioning of the tip of the inner dilator in the MPA was confirmed by angiogram. A 6-Fr vascular sheath was then exchanged for the 3-Fr inner dilator over the mailman guidewire. Subsequently, an 8mm x 12mm transhepatic biliary stent was deployed. RV angiogram showed only the proximal row of the stent was across the atretic valve. To maximize the stability of the stent, a 6mm x 12mm Herculink Elite stent was deployed. The distal 1/3 of the second stent was deployed inside the first stent with the proximal 2/3 inside the RV across the atretic pulmonary valve. Subsequently, this stent was dilated with an 8mm x 12mm balloon. RV angiogram showed the stents in

a stable position with good expansion. At the end of case, systolic RV pressure was near systemic. PGE-2 was turned off. Transthoracic echocardiogram 2 days later revealed mild TR with gradient of 28mmHg, predominantly left-to-right shunt across the ASD, good stent configuration with no obstruction to the flow, normal cardiac systolic function, and small PDA.

Conclusion: Hybrid approach for decompression of the hypertensive RV in patients with muscular PA/IVD is feasible and safe in selective cases. In order to avoid cardiopulmonary bypass in neonates, hybrid approach must be considered as a treatment option.

90. AORTIC REMODELING IN PATIENTS TREATED WITH INTRAVASCULAR STENT THERAPY FOR COARCTATION: A LONG-TERM FOLLOW-UP SINGLE CENTRE EXPERIENCE

Louise Pei¹, Annamalar Muthuppalaniappan², Ricardo Romero², Mark Osten², Jaime Sklar¹, Eric Horlick²

¹University of Toronto, Toronto, Canada. ²UHN, Toronto, Canada

Background: It is generally perceived that repaired aortic coarctation no longer requires further surveillance, hence asymptomatic patients are discharged without long-term follow up. However, complications are still seen in this population post-repair. To understand the development of these abnormalities, analysis of serial catheterizations and other cross-sectional imaging as well as defining the long-term outcomes is crucial.

Objective: We wished to define long-term clinical and procedural outcomes after stent implantation in a single center population with a focus on serial imaging.

Methods: We analyzed paired serial cross-sectional imaging of patients post stent therapy and compare this to baseline data. Volumetric and cross-sectional aortic remodeling on CT/MR images and catheterizations were measured using medical imaging programs and indexed to patient BSA.

Results: 133 patients underwent transcatheter coarctation closure in a single center. 32% of patients underwent at least 1 follow-up MR/CT, and 78% of patients underwent at least 1 follow-up post-op catheterization. Total mean follow-up time was 2.16 years. 5% of patients underwent re-intervention due to complications. 3% of the cohort developed aneurysms and 3% saw stent fractures during FU. An approximate 40% reduction in hypertensive states was seen when comparing baseline to post-stent therapy reports. There was significant cross-sectional negative

remodeling seen in the aorta immediately proximal to the left carotid artery, left subclavian artery, and the aorta distal to the stent ($p < 0.05$). There was also significant volumetric reduction in the ascending aorta, the aortic arch, and the aortic segment most proximal to the top of the stent ($p < 0.05$).

Conclusion: There has been no prior literature in regards to aortic remodeling in coarctation patients with a focus on serial imaging. We have reported negative remodeling in multiple areas of the aorta with regards to the aortic cross-sectional area and volumetric measurements, and have additionally reported the long-term outcomes of this population.

91. SINGLE CENTER EXPERIENCE OF 100 CONSECUTIVE PERCUTANEOUS CARDIAC INTERVENTIONS IN INFANTS \leq 1000 GRAMS

Neil Taylor, Shyam Sathanandam, Leah Apalodimas, Hitesh Agrawal, Benjamin Waller

Le Bonheur Children's Hospital, Memphis, USA

Background: For a long time, percutaneous cardiac interventions (PCI) in infants born premature, age < 30 days and weight < 2.5 kg were considered to be associated with an increased incidence of serious adverse events. Recent advancements of imaging and device technologies has allowed for an extended application of PCI to very small infants. We describe a large single-center experience of performing PCI in infants weighing ≤ 1000 grams at the time of the procedure.

Methods: A retrospective review of 100 consecutive PCI performed on infants weighing ≤ 1000 grams at the time of the procedure between June 2015 to May 2019 was performed. Procedure success rate was determined by the proportion of patients in whom the intended intervention was performed irrespective of the outcome. A major adverse event (AE) was defined as hemodynamic compromise resulting from the PCI requiring an additional procedure. A minor AE was defined as any AE that did not require additional treatment.

Results: The average age and weight at the time of the procedure was 25 days (range 1-70 days) and 863 grams (range 490-1000 grams) respectively. The median gestational age was 24 weeks (range 22-28 weeks). The interventions consisted of 81 transcatheter device closures of patent ductus arteriosus (PDA), pulmonary valvuloplasties ($n=7$), foreign body retrievals ($n=6$), pericardiocentesis ($n=4$), stent implantation for coarctation of aorta ($n=1$), and pulmonary artery angioplasty ($n=1$). The procedure

success rate was 99%. The one procedural failure was a PDA occlusion in which the device had to be snared and retrieved secondary to left pulmonary artery stenosis. However, the PDA spontaneously closed immediately after retrieval. The major AE rate was 6% including one procedure related mortality secondary to vascular injury. The minor AE rate was 4%. Re-interventions have been necessary only for the patients with pulmonary valve stenosis with a rate of 100%, but not for other procedures. At the time of latest follow-up (median 15 months), the survival rate was 95%.

Conclusions: It is feasible to perform PCIs in infants weighing ≤ 1000 grams using currently available technologies. There is a learning curve with these interventions with most AE happening earlier in the experience. Extreme care must be taken while performing interventions in such small human beings. Further miniaturization of equipment would facilitate better outcomes.

92. LATERAL THORACOTOMY WITH PULMONARY ARTERY MODIFICATION PROVIDES A LESS INVASIVE HYBRID APPROACH FOR PULMONARY VALVE PLACEMENT

Kaitlin Carr PA-C¹, Yuki Nakamura MD², Marco Ricci MD², Manish Bansal MD¹, Osamah Aldoss MD¹

Objective: To review our experience of a hybrid approach to pulmonary valve replacement (PVR)

Background: To date there are no FDA approved devices that can be placed in a large right ventricular outflow tract (RVOT) nor is there a small enough delivery system to accommodate transcatheter PVR in smaller patients. Hybrid approach for PVR can provide a less invasive way to replace the valve by avoiding cardiopulmonary bypass (CPB) and, in some cases, a full sternotomy.

Methods: Retrospective review of our experience in hybrid approach PVR starting in 2014.

Results: Total of 10 patients underwent attempted hybrid PVR. The mean age and weight were 22.2 years (± 20.3) and 49.1 kg (± 29.8) respectively, of which 5 were less than 18 years of age. The average fluoroscopy time was 34.7 min (± 29.9), average contrast volume of 220.7 ml (± 148.9) and average hospital stay was 4.4 days (± 2.6), and for the ones receiving a successful valve through thoracotomy 3.3 days (± 1.1).

Seven of the ten patients with known RVOT dilation underwent surgical pulmonary artery modification before

attempting valve placement. Five of these patients underwent lateral thoracotomy with PA plication and three subsequently had successful transcatheter placement of a Sapien S3 valve via femoral access. One patient ended up with unstable valve position after transcatheter deployment and underwent sternotomy, valve removal and successful surgical valve placement. The last patient had poor exposure via the lateral sternotomy so the hybrid approach was aborted and patient underwent a successful surgical PVR. The other two patients underwent sternotomy with main pulmonary artery banding with subsequent successful Sapien S3 valve placement via direct RV access.

The remaining 3 patients were small in size with multiple venous occlusions and underwent sub-xyphoid incision with RV access. Two had successful Melody valve placement and the last one had coronary artery compression upon balloon testing and the procedure was aborted.

PA plication provides a less invasive way for PVR by avoiding a full sternotomy. Nonetheless, it is less predictable in terms of reduction in PA and landing zone location when compared to direct PA banding and required repeated angiography and balloon sizing before being able to place the valve.

Conclusion: Hybrid approach PVR and PA plication through lateral thoracotomy in particular provides a good solution for patients who are deemed high risk for surgery and/or who are not a candidate for regular transcatheter approach. It is less invasive with the advantage of avoiding CPB and, in some cases, full sternotomy and often results in a shorter hospital stay.

93. TRENDS IN UTILIZATION OF THREE DIMENSIONAL GUIDANCE FOR CARDIAC CATHETERIZATIONS IN PATIENTS WITH CONGENITAL HEART DEFECTS

Sebastian Góreczny^{1,2}, Tomasz Moszura¹, Jadwiga Moll³, Alexander Haak^{4,5}, Hanne Håkonsen^{6,1}, Edit Mathisen^{6,1}, Paweł Dryżek³

¹Polish Mother's Memorial Hospital, Research Institute, Lodz, Poland. ²Children's Hospital of Colorado, Aurora, Colorado, USA. ³Polish Mother's Memorial Hospital, Research Institute, Lodz, USA. ⁴University of Colorado, Aurora, Colorado, USA. ⁵Philips Healthcare, Andover, Massachusetts, USA. ⁶Medical University of Lodz, Lodz, Poland

Background: Modern angiographic imaging platforms allow three-dimensional (3D) guidance of cardiac catheterization utilizing techniques such as 3D rotational angiography (3DRA) or fusion of pre-operative computed

tomography (CT) or magnetic resonance imaging (MRI) datasets.

Objectives: We report our eight years' experience with 3D guidance for cardiac catheterizations in patients with congenital heart defects (CHD). The data was analyzed with emphasis on frequency of utilization of 3D guidance and regard to the type of patient's anatomy, type of catheterization (diagnostic or interventional), specific intervention, imaging technique, operator and time frame.

Methods: A retrospective review of institutional database was performed to identify all procedures performed since the installation of an angiographic system enabling 3D guidance: 3DRA since 2010 and fusion of CT/MRI since 2015. Patients deemed not suitable for 3D guided catheterization were excluded from further analysis. The reasons for exclusion were: type of intervention (septal defect or arterial duct closure, atrial septostomy, isolated balloon valvoplasty, hybrid intervention or a procedure performed on extracorporeal membrane oxygenation), type of angiography (peripheral or cerebral angiography), hemodynamic study (evaluation of pulmonary hypertension or shunt defect) or non-CHD intervention (airway, esophageal, electrophysiology procedure).

Results: Between 03/2010 and 01/2018, a total of 2459 procedures were performed including 1660 (67.5%) that were deemed eligible for 3D guidance. We used 3D guidance in 562 cases (34%) with a yearly utilization ranging from 28% to 43%. Fusion of CT/MRI was utilized in 14.5% of all 3D guided procedures with increasing yearly share from 3.5% to 43%. Three-dimensional guidance was more commonly used for interventional than diagnostic catheterizations (45% vs. 21%; $p < .0001$) with similar frequency in patients with bi-ventricular and single-ventricular physiology (33% vs. 35%; $p = .4$). There was a significant difference in utilization of any type of 3D guidance between three operators (13% vs. 42% vs. 53%; $p < .00001$). Three-dimensional image guidance was most commonly used for treatment of pulmonary artery stenosis (37% of all 3D guided interventions), collaterals (16%), coarctation of the aorta (14%), right ventricular outflow tract stenosis (12%) or Fontan fenestration (12%).

More than half of the right ventricular outflow tract procedures involved 3D guidance (52/84; 61.9%) followed by collateral procedures (71/123; 58%), ductus arteriosus stenting (13/23; 56.5%) and Fontan fenestration closure (51/102; 50%). Three-dimensional guidance was utilized in almost every second case of pulmonary artery (165/352;

47%), systemic vein or Fontan tunnel dilation (20/46; 43.5%) or coarctation treatment (62/149; 42%).

Conclusions: A substantial percentage of cardiac procedures in patients with CHD may benefit from 3D guidance. In our eight years experience we noticed increasing frequency of utilization of any 3D guidance; including a tendency for more frequent fusion of pre-operative CT/MRI datasets. Three-dimensional imaging was significantly more commonly used during interventional procedures; with similar frequency among single and biventricular patients. Utilization of 3D guidance was operator dependent.

94. SUCCESSFUL COIL EMBOLIZATION FOR MASSIVE PULMONARY ARTERIOVENOUS FISTULA IMMEDIATELY AFTER ELECTIVE CAESAREAN SECTION ON THE BASIS OF PRENATAL DIAGNOSIS

Satoshi Yasukochi, Kiyohiro Takigiku, Kouta Takei, Ryusuke Numata, Kimiyo Takagi

Nagano Children's Hospital, Azumino, Japan

Massive pulmonary arterio-venous fistula (PAVF) is a life-threatening disease especially in a fetus developing heart failure prenatally. Case was referred to us because of fetal distress and cardiomegaly at 36 weeks of gestation. Fetal echocardiogram showed a cardiomegaly (CTAR of 52%) with huge PAVF occupied more than 80% space of left lung. The origin of PAVF was near the proximal left pulmonary artery and running tortuously to huge vascular sac (14-16mm in diameter) via multiple channels then draining through marked dilated venous vessel to left lower pulmonary vein.

Because of its high risk of severe desaturation, low output syndrome, and pulmonary hypertensive crisis, we underwent an emergent coil embolization immediately after the elective caesarean section. She was born by C-section at 37 weeks of gestation with SpO₂ of 45% and transferred to cath-lab immediately after intubation. 6F Wedge balloon catheter was introduced to left PAVF and occluded by balloon inflation, which improved her SpO₂ up to 97% and maintained BP of 60mmHg in systole. After balloon occlusion, PAVF was embolized by coils (Target™) including packing coil. After coil embolization, blood pressure could be maintained as 70-80/40mmHg and SpO₂ as 95-97% under 100% oxygen and 20ppm nitric oxide inhalation.

Strategic and team approach of catheter intervention on the basis of exact fetal diagnosis for critical heart disease is essential to rescue a life-threatening case.

95. SUCCESSFUL SEQUENTIAL CLOSURE OF CONGENITAL AND IATROGENIC ASDS FOLLOWING MITRACLIP: A CASE REPORT

Margaret Mary Steele, Jignesh Bhavsar, Gene Chang

Penn Medicine, Philadelphia, USA

Background: Symptomatic patients with congenital atrial septal defects (ASDs) and severe degenerative mitral regurgitation have traditionally been referred for surgical closure of ASD and repair or replacement of mitral valve. When lung disease is present, increasing the risk of surgical morbidity and mortality, these patients may instead be referred for transcatheter intervention with Mitraclip and ASD occluder device placement. However, the large sheaths required for transseptal puncture with the Mitraclip system create iatrogenic ASDs. Patients undergoing Mitraclip procedure are at risk for persistent iatrogenic ASDs and associated interatrial shunting, leading to worse clinical outcomes and higher mortality rates.[1]

Case Summary: We present the unusual case of a 73-year-old gentleman with 1 cm ostium secundum ASD and severe degenerative mitral regurgitation. He was deemed not a surgical candidate due to his advanced age, severe COPD and moderate pulmonary hypertension. The Mitraclip 24 Fr steerable guide required creation of a second ASD for optimal system positioning. Following placement of 2 Mitraclips, mitral regurgitation and left atrial pressure were markedly reduced. 10 mm Amplatzer septal occluder device was placed across the congenital ASD under transesophageal guidance. The patient tolerated this procedure well and was discharged to home the following day. Follow-up echocardiogram revealed persistent iatrogenic ASD with a large left-to-right shunt. He subsequently underwent placement of overlapping 10 mm Amplatzer septal occluder device 3 months following initial intervention. Echocardiogram revealed mild mitral regurgitation, no residual interatrial shunting, decreased pulmonary arterial pressure and decreased right ventricular dilation. He was discharged to home the following day and reported improvement in heart failure symptoms.

Discussion: This case offers a novel approach to persistent iatrogenic ASD in a patient with a history of previous Mitraclip and congenital ASD closure with Amplatzer occluder device. As indications for Mitraclip interventions extend from degenerative to functional mitral regurgitation, increasing numbers of patients will present for Mitraclip intervention with pre-existing structural heart disease. Additionally, incidence of persistent iatrogenic ASDs may also rise. More research is needed to optimize transcatheter intervention management in these patients

due to elevated risk of pulmonary hypertension with systemic desaturation, low output syndrome, cardio-respiratory compromise and right heart failure.

[1] Robert Schueler, C. O. (2015). Persistence of Iatrogenic Atrial Septal Defect After Interventional Mitral Valve Repair with the Mitraclip System. *JACC: Cardiovascular Interventions Vol. 8 No. 3*, March 2015: 450-9.

96. FONTAN PATHWAY AND FONTAN FENESTRATION TEST OCCLUSION EVALUATION IN THE ICMR SUITE

Yousef Arar¹, Tarique Hussain¹, Vasu Gooty¹, Riad Abou Zahr², Joshua Greer¹, Jennifer Hernandez¹, Gerald Greil¹, Prathyusha Mahasamudram³, Surendranath R. Veeram Reddy¹

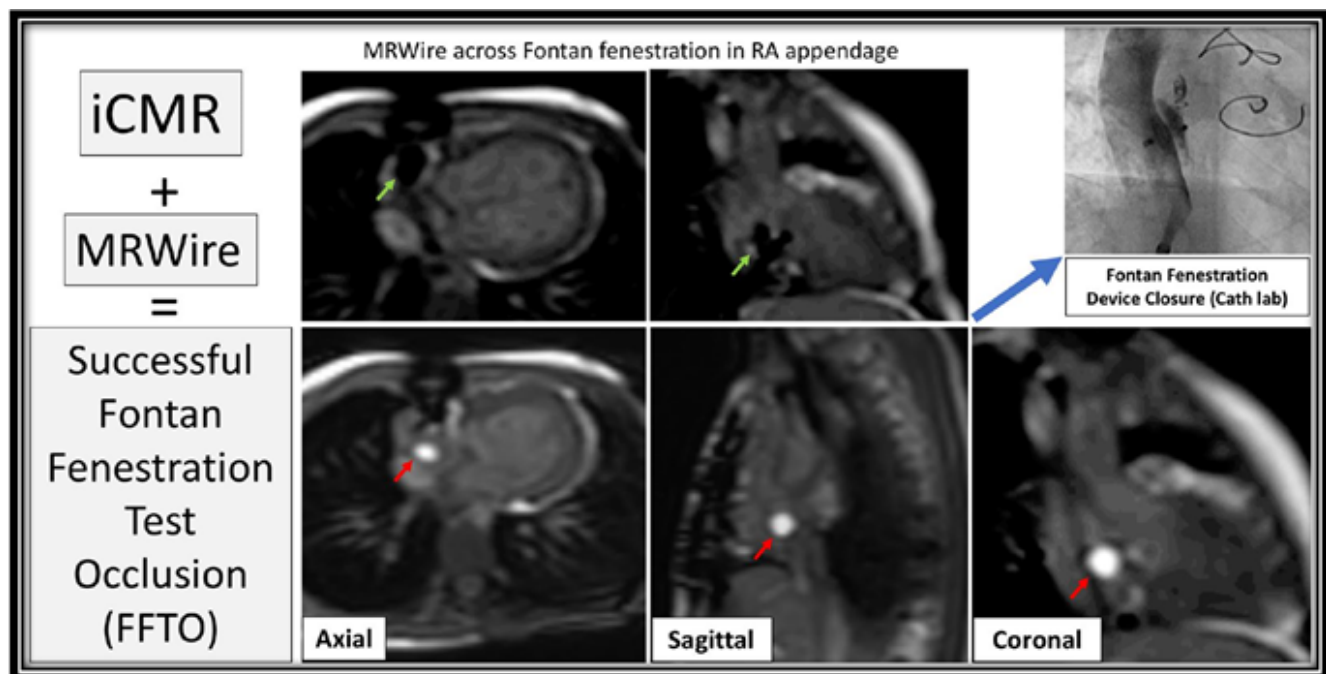
¹UT Southwestern Medical Center, Dallas, USA. ²King Faisal Specialist Hospital, Riyadh, Saudi Arabia. ³University of Texas, Dallas, Dallas, USA

Introduction: Fontan pathway and Fontan fenestration test occlusion (FFTO) evaluation is traditionally performed in the cardiac catheterization laboratory. Transcatheter closure of Fontan fenestration has been shown to be safe and effective in raising arterial oxygen saturations. However, the optimal timing and indications for such closure remain a matter of debate. In addition, there are concerns regarding the validity of the data (cardiac flows/output) obtained during traditional FFTO evaluation in the cath lab.

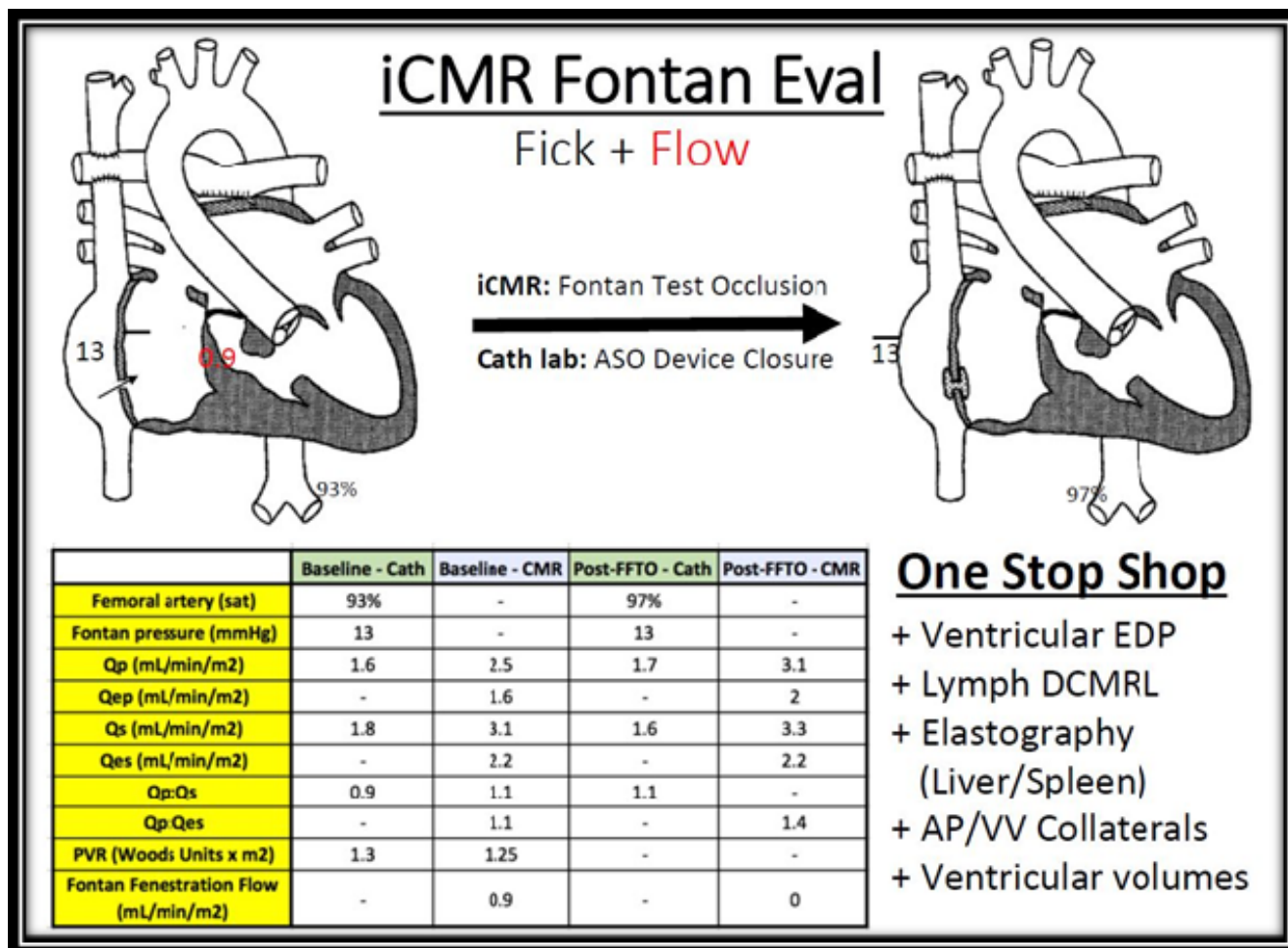
In this study, we explore the feasibility and safety of performing radiation-free interventional cardiac magnetic resonance (iCMR) catheterization in the Fontan population. We also describe our initial experience with FFTO evaluation in the iCMR suite, which allows for simultaneous measurement of catheter-based hemodynamics and CMR-derived flows to more accurately quantify pulmonary (Qp) and systemic (Qs) blood flow. FFTO evaluation in the iCMR suite also allows for quantification of the Fontan fenestration flow and thereby its contribution to the overall cardiac output which in turn aids in making critical decisions regarding candidacy for Fontan fenestration device closure (FFDC).

Methods: Fontan patients underwent iCMR RHC and LHC procedure using dilute gadolinium-filled balloon-tip catheter in combination with the MRI compatible EmergeGlide guidewire (Nano4Imaging, Aachen, Germany) for Fontan pathway/RHC, LHC, and FFTO under real-time MRI visualization. A recently developed partial saturation (pSAT) passive catheter tracking technique was used for simultaneous visualization of the gadolinium-filled balloon, EmergeGlide guidewire, and cardiac structures.

Once baseline hemodynamics and cardiac flows were measured, the Fontan fenestration is crossed using the 0.035" EmergeGlide guidewire under MR guidance. The



96. Figure 1. Successful Fontan Fenestration Test Occlusion (FFTO) followed by successful Fontan Fenestration Device Closure in the Cath Lab. **Red Arrow** - Gadolinium-filled balloon; **Green Arrow** - MRWire.



96. Figure 2.

gadolinium-filled balloon inflated in the right/pulmonary venous atrium and then pulled back to perform FFTO. Hemodynamics were repeated after 10 minutes of occlusion. A decision for FFDC is made based on iCMR-derived hemodynamics.

Results: Thirteen Fontan patients underwent iCMR evaluation at our institution between January 2018 to January 2019. Median age and weight were 8.3yrs and 25.3kg, respectively (range: 5-33yrs and 16.4-80kg). Of the 13 Fontan patients who underwent PLE/cyanosis evaluation 9 were fenestrated and 4 non-fenestrated. The MRWire was successfully used to cross the Fontan fenestration in all 6 attempted patients.

Real-time MRI-guided RHC (n = 6), LHC/aortic pull back (n = 6), and FFTO (successful, n = 5; not tolerated, n =1) was successfully performed in the majority of patients when

the MRWire was used. An atrial arrhythmia complication was encountered in one patient after Fontan fenestration crossing with the wire that required cardioversion with no other complications. Time taken for first pass RHC, LHC/aortic pull back, and crossing a Fontan fenestration was 5.2, 3.2, and 6.1 minutes, respectively. Patients were transferred to the fluoroscopy lab if further intervention was required including FFDC, balloon angioplasty, and/or coiling of collaterals when indicated.

Conclusions: The feasibility and safety of performing Fontan pathway including FFTO evaluation in the iCMR suite has been established. These cases describe a more critical evaluation of Fontan pressures and cardiac output before FFDC by using accurate flow and cardiac output measurements from real-time MRI with simultaneous catheter based pressure measurements.

97. TRANSCATHETER MECHANICAL MANIPULATION OF OBSTRUCTED ST. JUDE PROSTHETIC MITRAL VALVE IN AN INFANT

Yousef Arar, Jeff Hong, Thomas Zellers, Surendranath R. Veeram Reddy

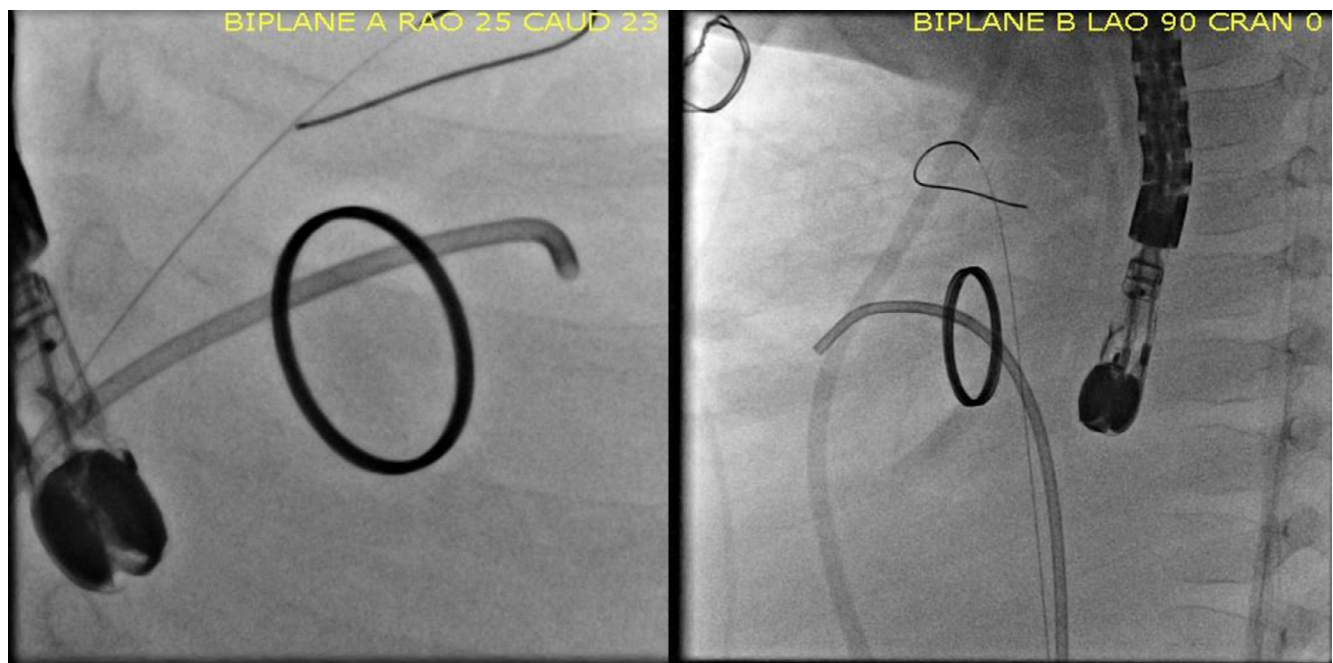
University of Texas Southwestern, DALLAS, USA

Prosthetic valve thrombosis (PVT) is a serious complication of prosthetic heart valves that leads to leaflet immobility and ultimately valve dysfunction. Management of PVT is with either surgical intervention or systemic thrombolysis, but in patients with contraindications to both treatment modalities, options can be limited. We describe a novel approach to treat prosthetic valve obstruction and leaflet immobility in an infant who was a very poor candidate for both surgery and systemic thrombolysis. To our knowledge, this is the youngest patient to undergo prosthetic mitral manipulation.

Case Report: An ex-35 weeks gestational age male with congenital arcade mitral valve underwent a surgical mitral valve replacement with a 17 mm St. Jude aortic mechanical prosthesis at 9 months of age. At 13 months of age he presented with acute respiratory distress and hemoptysis, with bronchoscopy showing active bleeding in his right lower lung. Bedside fluoroscopy confirmed that the medial mitral valve leaflet was completely immobile, most likely secondary to obstruction by adherent fibrinous and

inflammatory material. In the setting of his life-threatening pulmonary hemorrhage, all anticoagulation was held. After interdisciplinary discussions, the patient was deemed a very poor candidate for systemic thrombolysis and cardiac surgical therapies.

From a right femoral vein approach and 6-French (Fr) percutaneous access, a transseptal puncture was performed to gain access to the left atrium. Attention was focused on using catheters to manipulate the immobile leaflet of the mechanical mitral valve. Using TEE and fluoroscopic guidance, the medial leaflet was struck repeatedly with multiple catheters (4 Fr angled glide, 4 Fr 3.0 curve Judkins Right (JR), and 5 Fr 4.0 curve JR catheters) with no significant improvement in leaflet excursion. The 4.0 curve of the 5 Fr JR catheter was then reinforced with a 0.035" tip deflecting wire (TDW) that enabled the catheter to eventually be advanced across the immobile leaflet from the left atrium into the left ventricle. The catheter with the TDW in situ was then withdrawn from the left ventricle to position it across the medial hinge points of the valve leaflet and gentle force was applied to push open the valve completely. Post-intervention, there was no residual gradient across the mitral valve (LAP = 17, LVEDP = 18). A catheter was then placed in the left atrium for local tPA infusion to prevent further thrombosis.



97. **Figure 1.** Catheter tip across the St. Jude valve into the left ventricle status post catheter manipulation.

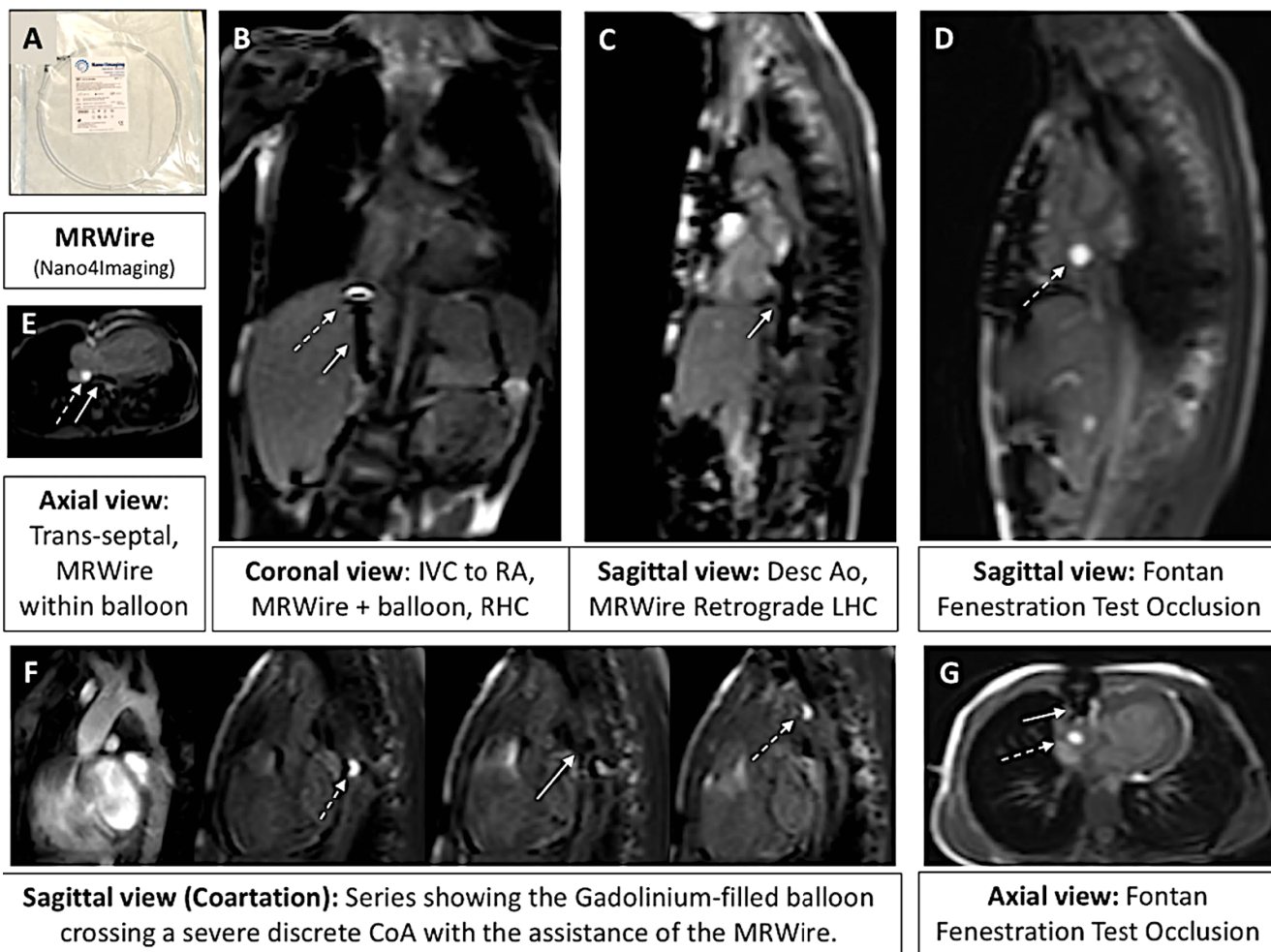
No complications were encountered during or immediately after the procedures. Total contrast was 21 mL (2.8 mL/kg), total fluoroscopy time was 62.6 minutes, and dose area product (DAP) was 6.97 Gy·cm².

Thrombosis of prosthetic valves leads to leaflet immobility and valve dysfunction and requires urgent management. Percutaneous manipulation of prosthetic valves is feasible and can be used as an alternative to surgery in selected patients who do not respond to or have contraindications to thrombolytic therapy. Further studies are necessary to demonstrate the safety and risks of this treatment across different patient subgroups and different types of prosthetic valves.

98. ICMR SINGLE VENTRICLE EVALUATION - FICK VERSUS FLOW: A REAL-TIME INTERVENTIONAL CMR REPRODUCIBILITY STUDY.

Yousef Arar, Tarique Hussain, Riad Abou Zahr, Vasu Gooty, Joshua S. Greer, Rong Huang, Jennifer Hernandez, Gerald Greil, Surendranath R. Veeram Reddy
University of Texas Southwestern, Dallas, USA

Background/Introduction: Accurate Pulmonary Vascular Resistance (PVR) measurements are critical for clinical decision making in single ventricle (SV) congenital heart disease (CHD) patients. In this study, we describe the test-retest reliability of CMR and cardiac catheter (Fick principle) derived measurements of pulmonary (Qp) and systemic (Qs) blood flows. Real-time CMR imaging was used to guide catheters/wires and all measurements were obtained without the use of ionizing radiation.



98. Figure 1. Interventional Cardiac Magnetic Resonance (iCMR) case examples including right and left heart catheterizations. **Dashed White Arrow** - Gadolinium-filled balloon; **Solid White Arrow**-MRWire.

Methods: Patients with SV CHD underwent real-time interventional CMR (iCMR) at 1.5 T. The MRWire (angled-tip Emeryglide MRWire, Nano4Imaging, Aachen, Germany) was used to aid completion of RHC and LHC. A dilute gadolinium-filled balloon-tip catheter was used for RHC and LHC/aortic pull back under real-time MRI visualization. A recently developed passive catheter tracking technique with a real-time single-shot balanced steady-state free precession (bSSFP), partial saturation (pSAT) pulse of 40° with flip angle of 35-45° was used to visualize the gadolinium-filled balloon, MRWire and cardiac structures simultaneously. A series of 4 conditions were performed to evaluate for test-retest reliability. The first and second conditions were catheterization and CMR data obtained at baseline and the third and fourth conditions were retest catheter and CMR data respectively. Pearson correlation coefficients (PCC) was used to measure test-retest reliability.

Results: A total of 18 SV CHD (14 Male) patients participated in the iCMR reproducibility study at our institution. Median age and weight were 8.6 years and 27.3 kg (range: 3-33 years and 14.7-80.7 kgs). SV patient were split evenly with 9 referred for pre-Fontan evaluation, and 9 post-Fontan patients for PLE/cyanosis evaluation. Real-time MRI-guided RHC (18/18 patients, 100%), retrograde and prograde LHC/aortic pull back (18/18 patients, 100%) were successfully performed when the MRWire was utilized. No catheter related complications were encountered. Time taken for first pass RHC and LHC/aortic pull back was 5.2, and 2.7, respectively. Patients were transferred to the fluoroscopy lab if further intervention was required including Fontan fenestration device closure, balloon angioplasty of pulmonary arteries, CoA stenting, and/or coiling of aortopulmonary (AP) collaterals.

The PCC for Cath derived Qp (0.71) and Qs (0.6) was significantly lower than MRI derived Qp (0.91) and Qs (0.92).

Conclusion: Feasibility for diagnostic RHC and LHC iCMR procedures in SV patients with CHD is demonstrated. MRWire was used to successfully complete detailed RHC and LHC iCMR procedures in complex CHD. A novel real-time pSAT sequence with optimized FA-pSAT angle has facilitated simultaneous visualization of the catheter balloon tip, MRWire, and cardiac/vessel

MRI-derived flows have higher test-retest reliability than the catheterization-derived Fick method. This is most evident when comparing the cardiac output between each modality. With more accurate iCMR Qp assessment, our PVR measurements will become more reliable to appropriately triage SV patients for their next stage of palliation,

Fontan fenestration device closure etc. In addition, using the iCMR technique, we can more reliably obtain information about important cardiac output states.

99. BUILDING OPERATOR DEPTH FOR A SUSTAINABLE PEDIATRIC CARDIAC CATHETERIZATION PROGRAM: UGANDA HEART INSTITUTE'S EXPERIENCE

Twalib Aliku¹, Kanishka Ratnayaka², Sanjay Daluvoy³, Krishna Kumar⁴, Shakeel Qureshi⁵, Sulaiman Lubega¹

¹Uganda Heart Institute, Kampala, Uganda. ²Rady Children's Hospital / UCSD, San Diego, USA. ³World Children's Initiative, Palo Alto, USA. ⁴Amrita, Kochi, India. ⁵Evelina Children's Hospital, London, United Kingdom

Background: The Uganda Heart Institute (UHI) cardiac catheterization program was started in February 2012. The first primary operator (SL) was trained with a combination of the following: visiting team clinical service and training trips, out-of-country training fellowships, and weekly telemedicine case discussion/mentorship. With one operator (SL), UHI achieved its aim of developing independent operation after five years (2012-2016) of international mentorship, performing over 100 independent cases per year in 2017 and 2018, and is on track to perform 140 cases in 2019.

Methods: With an eye toward a sustainable practice, a prospective plan to build depth was instituted focused on in-country training of a second primary operator. In year two of operation (2013), dedicated in-country training of a junior attending pediatric cardiology physician was initiated. The goal was, in successive years, progression from tertiary to secondary to primary operator performing in-country UHI pediatric cardiac catheterization cases.

Results: Since 2012, UHI has performed 561 congenital heart disease catheterization procedures. 392 (70%) are independent UHI procedures (no international provider presence). Procedures are patent ductus arteriosus (PDA) device closure (278), diagnostic catheterization (164), balloon pulmonary valvuloplasty (69), and other (50)].

Of the 561 UHI cases, the new operator (TA) has participated in 454 (81%). TA performed as tertiary operator in 56 (86% of those were in years 2013-2014), as secondary operator in 310 (96% of those were in 2015-2018), and as primary operator in 61 (98% of those were in 2018-2019). TA has been the primary operator in (50), 94% of all cases done so far this year (2019).

Cases performed by TA as primary operator include PDA device closure (38), diagnostic catheterization (13), balloon

pulmonary valvuloplasty (8), balloon atrial septostomy (1), and pericardiocentesis (1).

Conclusion: Through in-country training, Uganda Heart Institute is building operator depth toward a sustainable pediatric cardiac catheterization program.

100. PULMONARY VEIN ATRESIA: TRANS-CATHETER INTERVENTIONS AND LONG TERM OUTCOMES

Varun Aggarwal, Gary E Stapleton, Henri Justino

Texas Children's Hospital and Baylor College of Medicine, Houston, USA

Background: Outcomes for congenital or acquired pulmonary vein atresia (PVA) have historically been poor, often leading to progressive pulmonary hypertension, cardiac failure and death. Furthermore, transcatheter or surgical treatment options had been limited by high failure rates. We describe our single center outcomes of transcatheter management of PVA.

Methods: Retrospective chart review of all patients (pts) who were diagnosed with PVA and underwent cardiac catheterization (cath) from 1995 to 2019 at a single tertiary center.

Results: 50 pts with 83 atretic veins underwent cath from April 1995 to May 2019 for evaluation/management of PVA. The median (IQR) age at cath was 1.6 (0.7, 6.45) years. Most common diagnosis was PVA associated with complex congenital heart disease (n=22 pts), followed by isolated congenital PVA (11), total or partial anomalous pulmonary venous return post-surgical repair (8), and prematurity (6). One pt each had fibrosing mediastinitis, Adams Oliver syndrome, and PVA following atrial fibrillation ablation. 37 pts had biventricular circulation and 13 patients had undergone single ventricle palliation. 25 pts (50%) did not undergo any intervention, the other 25 pts received transcatheter interventions on 41 atretic veins. Only 4 pts underwent recanalization attempts prior to 2015; 21/25 pts received attempted interventions after January 2015. 16/25 (64%) pts had successful PV recanalizations. All recanalization attempts were performed from the left atrium to the atretic PV except in 2 pts (one with unsuccessful attempted recanalization via the collateral vessel from the other ipsilateral PV and one with transthoracic PV access and successful recanalization). 21/25 attempted recanalizations were performed using 0.014" chronic total occlusion (CTO) wires [most commonly used wires include Victory wire (Boston Scientific), Pilot wire (Abbott Vascular)]. Radiofrequency (RF) perforation with a Nykanen 0.024" RF Wire (Baylis Medical) or by electrifying

a 0.014" guidewire was used in 4 pts. The atretic length of the recanalized vein in the successful cases varied from 4-22mm. 3/16 pts underwent balloon angioplasty alone and 13/16 (81.3%) pts had drug eluting stents (DES) placed. 12/13 pts received 4mm diameter DES (Promus Premier, Boston Scientific), and one received a 5mm DES (Resolute Onyx, Medtronic). 3 pts had complications during the recanalization procedure (1 pulmonary hemorrhage, 1 pericardial effusion and 1 with intimal injury of recanalized vein). 10/16 pts had subsequent reinterventions at last follow up. The median time from PVA recanalization to last angiographic evaluation among the 10 pts was 0.6 (0.25, 1.6) years. One patient had recurrent atresia of a stented PV which was successfully recanalized, while the recanalized PVs in other 9 pts (90%) remained patent but needed further angioplasty for either in-stent restenosis or to account for pulmonary vein growth.

Conclusions: We describe the largest cohort of PVA undergoing transcatheter interventions, the majority of which were performed after 2015. Success of recanalization has remarkably improved over the years with the use of CTO wires and RF. We describe the first transthoracic PV recanalization in one pt. The long-term outcomes for this challenging lesion are encouraging but continued surveillance and frequent reinterventions are needed in these pts.

101. PERCUTANEOUS CLOSURE OF PATENT FORAMEN OVALE AND ITS IMPLICATION IN THE DEVELOPMENT OF NEW-ONSET ATRIAL FIBRILLATION

Laura Oliva¹, Claudia Frankfurter¹, Madeleine Barker¹, Lusine Abrahamyan^{1,2}, Eric Horlick^{3,1}

¹University of Toronto, Toronto, Canada. ²Toronto Health Economics and Technology Assessment (THETA) Collaborative, Toronto, Canada. ³Peter Munk Cardiac Centre, Toronto, Canada

Objectives: This systematic review and meta-analysis synthesized evidence on the effect of transcatheter patent foramen ovale (PFO) closure on the risk and predictors of atrial fibrillation (AF) development.

Background: Affecting approximately 20% adults, PFO increases the risk of cardiovascular complications such as cryptogenic stroke. The transcatheter closure of PFO is the current standard of care but has recently been implicated in post-closure, new-onset atrial fibrillation (AF).

Methods: Randomized controlled trials, cohort, and case/control studies were retrieved from electronic databases and selected according to the inclusion criteria of adults with PFO (> age 18) without a history of AF that underwent a transcatheter closure surgery. Baseline characteristics

and time to AF onset were evaluated with descriptive analyses. A Freeman-Tukey arcsine transformation was performed for meta-analysis of AF incidence.

Results: From 765 records, 68 full text studies were included in data synthesis. Study sample sizes ranged between 20 and 1887 individuals, average study duration between 3.6 months and 18.5 years, and average age between 37 to 67 years across all studies. The meta-analysis found an average incidence of AF after PFO closure of approximately 3.0%. Of those who developed AF, the majority developed it within the short-term, about a few weeks to a year after closure. There was no consistency in reported predictors of AF development.

Conclusions: Incidence of AF post-closure was relatively low across studies, with a high level of between-study heterogeneity. Until a concerted effort is made to improve accurate AF diagnosis, it will be difficult to gauge the true risks associated with transcatheter PFO closure.

102. PERCUTANEOUS IMPELLA RP USE FOR REFRACTORY RIGHT HEART FAILURE IN ADOLESCENTS- RESULTS FROM A MULTICENTER U.S. EXPERIENCE

Athar M. Qureshi¹, Mariel E. Turner², William O'Neill³, Susan W. Denfield¹, Nima Aghili⁴, Amit Badiye⁵, Radhakrishnan Gandhi⁶, Behnam Tehrani⁷, George Chang⁸, Jared K. Oyama⁹, Shashank Sinha⁷, Nicolas Brozzi⁵, Brian Morray¹⁰

¹Texas Children's Hospital, Baylor College of Medicine, Houston, TX, USA. ²Morgan Stanley Children's Hospital of New York-Presbyterian, Columbia University Medical Center, New York, New York, USA. ³Henry Ford Hospital, Detroit, MI, USA. ⁴St. Anthony Hospital, Lakewood, CO, USA. ⁵Jackson Memorial Hospital, Miami, FL, USA. ⁶Hoag Memorial Hospital, Newport Beach, CA, USA. ⁷Inova Fairfax Hospital, Annandale, VA, USA. ⁸Emory, St. Joseph's Hospital, Atlanta, GA, USA. ⁹The Queen's Medical Center, Honolulu, HI, USA. ¹⁰Division of Pediatric Cardiology, Seattle Children's Hospital, University of Washington School of Medicine, Seattle, WA, USA

Background: Percutaneous right ventricular assist device support with the Impella RP device (Abiomed, Danvers, MA) has been reported in adults, but a multicenter experience in children has yet to be reported.

Methods: We included patients < 21 years of age who underwent implantation of an Impella RP device for refractory right heart failure from 6/2016 - 4/2018 at 9 U.S. (7 adult and 2 pediatric) Centers.

Results: A total of 12 adolescents with a median age of 18 (14 - 21) years, median weight 74.4 (49-112.4) kg. underwent Impella RP implantation. The underlying diagnosis

was post-heart transplant rejection in 5, primary myocarditis in 3, cardiogenic shock in 2, cardiomyopathy in 1, and arrhythmogenic right ventricular dysplasia in 1 patient (INTERMACS profile -cardiogenic shock in 9 and slow progressive decline in 3 patients). The central venous pressure decreased significantly from a median of 20 (16 - 35) mmHg to 12 (7 - 17) mmHg post Impella RP implantation, ($p = 0.001$). One patient was supported with an intra-aortic balloon pump (IABP) and the rest were concomitantly supported with a percutaneous or surgically placed left ventricular assist device. There were 2 procedural adverse events- 1 patient suffered a retroperitoneal hemorrhage from simultaneous Impella CP implantation and 1 patient underwent leg amputation due to arterial thrombosis from an IABP. There was 1 adverse event related to the Impella RP device (thrombosis resulting in explant). The average support duration was 6.5 days (4.8 hours - 18.4 days) and survival to hospital discharge was 83 %. At a median follow up of 11 months (5 days - 2.5 years), 8/12 (67%) patients are alive with complete recovery.

Conclusions: In this multicenter experience, use of the Impella RP device was found to be efficacious and safe when used in adolescents. The Impella RP device should be considered as a treatment modality in select adolescents with severe right heart failure refractory to medical therapy. Further studies are warranted to identify suitable candidates for Impella RP therapy for right heart failure.

103. PREVALENCE AND CLINICAL OUTCOMES IN PATIENTS WITH PULMONARY HYPERTENSION UNDERGOING TRANSCUTANEOUS CLOSURE OF ATRIAL SEPTAL DEFECTS

Selai Akseer¹, Lusine Abrahamyan¹, Eric Horlick²

¹The University of Toronto, Toronto, Canada. ²The University Health Network (UHN), Toronto, Canada

Background: Atrial septal defect (ASD) is the second most common congenital heart disease (CHD) accounting for 8-10% of all heart defects, with an estimated prevalence of 1.64 per 1000 live births. The left to right shunt causes a volume overload in the right side of the heart resulting in structural abnormalities. The volume overload triggers right atrium hypertrophy which pulls apart the leaflets of the tricuspid valve causing leakage and overflow into the right ventricle and subsequently through the pulmonary arteries.

The lungs respond to hyperkinetic blood flow by narrowing its blood vessels to reduce the volume of blood that enters it. This constriction however increases the blood pressure

against the walls of the vessels in the lungs manifesting as a condition known as pulmonary hypertension (PH).

If left untreated, PH in patients with ASD can be associated with poor prognosis including: atrial arrhythmias, heart failure, heart functional limitations, and other increased morbidity and mortality. The role of ASD closure and its effects on PH are unclear. While closure of significant sized ASDs should result in a lowering of mPAP, there is a subset of patients in which ASD closure increases mPAP. Information regarding the relationship between ASDs and PH and the mechanisms by which they operate is limited. Research is needed on the reduction or development of PH post ASD closure, changes in mPAP, and important clinical features in patients undergoing ASD closure to address this gap.

Objective: The purpose of this review is to report the prevalence of PH, report changes in mean pulmonary pressure, and report clinical outcomes in patients undergoing transcatheter ASD closure. In addition, this study aims to report key patient characteristics and the identify PH cut offs used in the literature.

Methods: EMBASE and MEDLINE were searched for peer reviewed literature until February 2019. All studies including PH prevalence and outcomes before and after closure in an adult population were included. Papers were assessed and data was summarized.

Results: Prevalence of PAH ranged from 5% to 27% following ASD closure. The pooled mean pulmonary artery pressures (mPAP) were 51.88 mmHg before closure and 36.63 mmHg after closure. Prevalence of PH and mPAP decreased before and after ASD closure in all studies.

Conclusions: This review has found a reported prevalence of PH among patients that have undergone ASD closure to be between 5% and 27%. Because of this substantial proportion of patients that still have PH following closure, long term follow-up is necessitated. All studies included in this review reported declines in mean pulmonary arterial pressure following transcatheter closure in their study populations. The observed reduction in mPAP, was correlated with pre-closure mPAP levels. Patients with higher mPAP before ASD closure, experienced a greater decline post closure in comparison with those with lower initial mPAP.

104. COMPARISON OF FUSION IMAGING AND TWO-DIMENSIONAL ANGIOGRAPHY FOR GUIDANCE OF PERCUTANEOUS PULMONARY VEIN INTERVENTIONS

Sebastian Goreczny^{1,2}, Jenny Zablah², Gareth Morgan^{2,3}, Daniel McLennan⁴, Rizwan Rehman⁵, Michal Schafer², Michael Ross²

¹Polish Mother's Memorial Hospital, Research Institute, Lodz, Poland. ²Children's Hospital Colorado, Aurora, Colorado, USA. ³University of Colorado Hospital, Aurora, Colorado, USA.

⁴University of Iowa, Stead Family Children's Hospital, Iowa City, Iowa, USA. ⁵Birmingham Children's Hospital, Birmingham, United Kingdom

Background: Congenital and acquired pulmonary vein (PV) stenoses comprise a group of complex conditions often requiring numerous interventions in early childhood. Balloon dilation has demonstrated limited long-term efficacy, whereas stent implantation requires repeat dilations to match somatic growth or in-stent restenosis. Modern angiographic imaging platforms allow three-dimensional (3D) guidance with fusion of pre-operative computed tomography (CT) or magnetic resonance imaging (MRI) datasets promising reductions in contrast and radiation dose, fluoroscopy and study time.

Objectives: We report our initial experience with fusion imaging (FI) for guidance of percutaneous PV interventions and compare this with patients undergoing PV intervention using traditional 2D angiography.

Methods: A retrospective review of our institutional database was performed to identify all patients who underwent percutaneous PV interventions. Patients demographics, pre-procedural cross-sectional imaging and catheterization data were collected. Patients who underwent fusion of pre-catheter scans (VesselNavigator, Philips Healthcare; available for the last 9 months of the studied period) for procedural guidance were matched (1:1) to those with standard 2D angiography. The following parameters were used for matching: body surface area, type of intervention (balloon dilation \pm stent implantation), number of treated veins. Statistical analysis was performed using Wilcoxon-matched pairs signed rank test.

Results: Between 12/2017 and 5/2019, 24 patients with PV stenosis underwent 64 catheterizations: 8 diagnostic and 56 interventional. Fusion imaging was utilized during 7 interventional catheterizations. One case of radiofrequency PV perforation with FI was excluded from further analysis due to lack of a matching example in the 2D group. There were no significant differences between those with 2D guidance (n=6) and FI (n=6) in terms of body surface area (median 0.38 vs. 0.4 m², p=.812), weight (7.5 vs. 7.8 kg, p=0.999) and age (13.5 vs. 19 months, p=.625). Similarly, there were no differences in CRISP score (11 vs. 10 points,

$p=0.562$) and risk for severe adverse events (14.2 vs. 14.2 %, $p=0.999$). All patients in each group underwent balloon dilation with 3 patients in each group having additional stent implantation. Utilization of FI resulted in lower contrast utilization (3.7 vs. 2.4 ml/kg, decrease of 31.5%; $p=0.219$) and radiation exposure (Air kerma: 288 vs. 53 mGy, decrease of 82%; $p=0.219$; Dose area product: 8852 vs. 1020 mGy*cm, decrease of 88.5%; $p=0.312$). Finally, fluoroscopy (71 vs. 52 min, decrease of 27%; $p=0.437$) and total study times (256 vs. 165 min, decrease of 35.5%; $p=0.219$) were also shorter in cases guided with FI. However, none of these favorable trends reached statistical significance.

Conclusions: Our initial, limited experience shows a trend for lower contrast utilization and radiation exposure and shorter fluoroscopy and study times with FI for guidance of percutaneous PV interventions when compared to 2D angiography. A larger patient groups may allow us to determine if these differences are statistically significant.

105. PATENT DUCTUS ARTERIOSUS CATHETERIZATION CLOSURE IN PRETERM INFANTS: A DESCRIPTIVE STUDY OF OUR INSTITUTIONAL EXPERIENCE

Heidi Kim, MD, Surendranath Veeram Reddy, MD, Sushmita Yallapragada, MD

The University of Texas Southwestern Medical Center, Dallas, TX, USA

Introduction: A patent ductus arteriosus (PDA), i.e. the failure of the ductus arteriosus to close within 72 hours of life, can result in excessive shunting from the arterial to pulmonary circulation, causing pulmonary edema and pulmonary hypertension. In preterm infants (<32 weeks) the PDA may subsequently lead to respiratory insufficiency and chronic lung disease as well as necrotizing enterocolitis due to systemic hypoperfusion. Recently, catheter-based PDA closure has emerged as a potential alternative to invasive surgical ligation in preterm infants. However, evidence to support this procedure in infancy, particularly in the premature population, is limited. The purpose of this study is to describe our preterm patient population and outcomes of their catheter-based PDA closures at our institution.

Methods: We will conduct a retrospective chart review to collect information regarding demographic data and clinical characteristics including antenatal, postnatal, and post-catheterization time frames (e.g. gestational age, pregnancy/delivery complications, level of required respiratory support, chronic lung disease, ventilator outcomes, etc.). The study will include infants <32 weeks gestational age with a PDA from January 2017 to present at Children's Medical Center in Dallas, TX. Exclusion criteria are any

infants with congenital heart disease and/or lethal congenital anomalies. Data will be analyzed with counts and percentages following the appropriate skip patterns.

Results: There are currently 24 neonates in our study who have received catheter-based PDA closures from January 2017 to present. At the time of intervention, infants ranged from a post-menstrual age of 27 1/7 weeks to 47 1/7 weeks. Weights ranged from 910 to 3600 grams. We will describe demographic data in Table 1. Comparative antenatal data (such as gestational age, maternal complications, etc.) will be listed in Table 2. All catheter/interventional data per patient will be listed in Table 3. All comparative outcomes and/or postnatal data will be listed in Table 4 and/or Table 5.

Conclusions: This study describes our institution's experience with catheter-based PDA closures since the beginning of our program (January 2017) to current. The next steps will be to compare long-term outcomes such as chronic lung disease, length of stay, ventilator days, etc. in age and weight-matched infants whose PDAs were closed percutaneously vs. surgically.

106. TRANSCATHETER CLOSURE OF A PARAVALVULAR AORTIC LEAK AFTER MECHANICAL AORTIC VALVE REPLACEMENT WITH AN OCCLUTECH PARAVALVULAR LEAK DEVICE

Heike Schneider, Thomas Paul, Claudius Jacobshagen, Matthias Mueller

University Medical Center, Goettingen, Germany

Transcatheter closure of paravalvular leaks (PVL) by plug implantation has emerged as an alternative treatment option to surgical correction, which is associated with high mortality rates for re-operation. We present the case of a 75-year-old male patient who had received mechanical aortic valve replacement (27 mm SJM prosthesis) 11 years prior to intervention. At that time, he had developed aortic valve endocarditis that had resulted in severe aortic valve insufficiency. For post-operative AV block, he had received a dual chamber pacemaker in addition. At his last follow-up, a large paravalvular aortic leak was noted in addition to moderate-severe mitral valve regurgitation and left ventricular dilatation. He had pedal edema and was assessed to be in heart failure NYHA III despite medical management. After evaluation of the PVL by TEE, it was decided to close the aortic PVL interventionaly. Cardiac catheterization was performed under general anesthesia, heparin was given to keep the ACT above 200 ms and Cephazolin was administered intravenously as prophylaxis. Evaluation of the PVL by aortography, TEE including

3-dimensional assessment revealed a crescent shaped PVL mainly along the previous right coronary cusp measuring 4 x 8 mm in dimension. It was decided for optimal fitting to utilize a rectangular Occlutech paravalvular leak device (PDL) with a waist for closure (61PLD10W). The dimensions of the waist of the device are 10 x 4 mm. The PVL could be crossed with a straight Terumo Glide wire through a regular Judkins right coronary catheter. The wire was exchanged for a Safari stiff (small) guidewire in the left ventricle. A 7F Occlutech delivery sheath could be advanced with some rotations over the stiff guide wire. The PDL was step-wise developed along the tunnel of the PVL. There were intermittent ST-segment changes that subsided after slight repositioning of the device. Angiography and TTE showed good position of the PLD and minimal residual shunting. The device was released and remained in stable position. There was no interference with the leaflets of the mechanical aortic valve, the diastolic blood pressure rose from 38 to 60 mmHg. The femoral arterial access site was close using an 8F AngioSeal. Post-intervention the patient was advised to take ASS and clopidogrel for 6/12 months, respectively, in addition to phenprocoumon. On day one after the procedure there was mild hemolysis that subsided the next day. By transthoracic echocardiography (TEE), there was no residual paravalvular leak detectable on day two post intervention. At his 4-week follow-up visit, his edema had almost resolved and there was no residual PVL aortic leak by TTE. In 6 months, we plan a TEE to evaluate his mitral valve regurgitation to assess whether an intervention of the mitral valve can be avoided after reduction of the volume load due to the aortic PVL. The Occlutech PDL is available in 4 different shapes and a variety of sizes that may represent an additional tool to the Amplatzer Vascular Plug III and other devices for percutaneous closure of the variety of PVL.

107. PERCUTANEOUS CLOSURE OF A LEFT VENTRICULAR PSEUDOANEURYSM AFTER TRANSCATHETER VENTRICULAR SEPTAL DEFECT CLOSURE

Selman GOKALP¹, Sezen Ugan ATIK², Irfan Levent SALTIK¹

¹Istanbul University Cerrahpasa, Cerrahpasa Medical Faculty, Department of Pediatrics, Division of Pediatric Cardiology, Istanbul, Turkey. ²Istanbul Mehmet Akif Ersoy Research and Training Hospital, Department of Pediatric Cardiology, Istanbul, Turkey

Left ventricular (LV) pseudoaneurysm is very rare in children. Untreated pseudoaneurysms lead to sudden cardiac death due to rupture. Although open surgery is conventional treatment, recently, percutaneous closure of LV pseudoaneurysms has been described. Here, we present

the case of a child who underwent transcatheter ventricular septal defect (VSD) closure at 8 months who then developed a LV pseudoaneurysm, detected 16 months later, which was percutaneously closed.

Case Report: A 3-month-old boy with Down syndrome diagnosed with a 5-mm apical VSD, 7-mm atrial septal defect (ASD), and patent ductus arteriosus (PDA). Five months later VSD and PDA were closed percutaneously by Amplatzer® Duct Occluder II (ADO II) device. To prevent arterial injury, an antegrade approach was performed. His postoperative course was unremarkable, echocardiography showed minimal residual shunt from the VSD. At 16 months after the initial procedure, echocardiography revealed a LV pseudoaneurysm immediately next to the ADOII device. Because the pseudoaneurysm was very close to the device, open surgery carried a high risk, so we decided on percutaneous closure. Left ventriculography demonstrated a pseudoaneurysm in the posterolateral aspect of the LV, measured 21× 17-mm with an 8-mm connecting neck. A 9-mm Amplatzer® septal occluder (ASO), was deployed in the standard manner across the LV myocardial wall. To prevent device embolization, both discs were embedded in the pseudoaneurysm cavity. Left ventriculography confirmed total occlusion of the pseudoaneurysm. The following day, echocardiography was uneventful with complete closure of pseudoaneurysm. Three days after the procedure, pericardial effusion started and increased up to 24 mm on postoperative day 10 despite anti-inflammatory treatment. The diagnostic pericardiocentesis was unrevealing; microbiological cultures were negative. After starting steroid the patient was discharged without any effusion. An echocardiogram 2 months later showed closed VSD and pseudoaneurysm without any residual shunt.

Discussion: To the best of our knowledge, this is the first case report of percutaneous LV pseudoaneurysm closure after transcatheter device closure of VSD. Even there is no direct perforation during the procedure, damage to the LV free wall by the manipulations may predisposes for pseudoaneurysm development. Time lapse between the procedure and development of pseudoaneurysm might be related with this factor. Fortunately, the patient was asymptomatic and the pseudoaneurysm was recognized incidentally. Nevertheless, we could not determine the exact time for development of pseudoaneurysm. It would likely become recognizable when large enough to be visualized on echocardiography. The rarity of this condition in children poses a challenge for treatment. Although surgery is an option, there is limited experience with high mortality rates. Transcatheter treatment is less prevalent. Device

selection needs to be individualized depending on the location and size of the pseudoaneurysm.

Conclusion: LV pseudoaneurysm may be seen as a late complication of percutaneous VSD closure, which has not been previously reported. It is associated with a very high mortality rate if left untreated. Transcatheter occlusion might be an alternative option to conventional surgery in selected cases.

108. SAFETY AND FEASIBILITY OF SAPIEN VALVE TRANSCATHETER PULMONARY VALVE REPLACEMENT IN THE NATIVE OR PATCHED RIGHT VENTRICULAR OUTFLOW TRACT

Shabana Shahanavaz¹, Evan Zahn², Mary Hunt Martin³, Daniel Levi⁴, Jamil Aboulhosn⁵, Holly Bauser Heaton⁶, Athar Qureshi⁷, Britton Keeshon⁸, Jeremy Ringwald⁹, Brian Morray¹⁰, Darren Berman¹¹, Jeffrey Zampi¹², Sebastien Hascoet¹³, Pleiss Julien¹⁴, Patrice Guerin¹⁴, Diego Porras¹⁵, Bryan Goldstein¹⁶, Clement Karsenty¹⁷, Doff McElhinney¹⁸

¹Division of Cardiology, Department of Pediatrics, Washington University in St. Louis School of Medicine, St. Louis, USA.

²Guerin Family Congenital Heart Program, The Heart Institute and Department of Pediatrics Cedars-Sinai Medical Center, Los Angeles, USA.

³Division of Pediatric Cardiology, Primary Children's Hospital, Salt Lake City, USA.

⁴Department of Pediatrics, Division of Cardiology, UCLA Mattel Children's Hospital, Los Angeles, USA.

⁵Ahmanson Adult Congenital Heart Disease Center, David Geffen School of Medicine at UCLA, Los Angeles, USA.

⁶Department of Pediatrics, Emory University School of Medicine, Atlanta, USA.

⁷The Lillie Frank Abercrombie Section of Cardiology, Texas Children's Hospital, Baylor College of Medicine, Houston, USA.

⁸Yale University, New Haven, USA.

⁹St Joseph's Children's Hospital, Tampa, USA.

¹⁰Division of Pediatric Cardiology, Seattle Children's Hospital, University of Washington School of Medicine, Seattle, USA.

¹¹The Heart Center, Nationwide Children's Hospital, Columbus, USA.

¹²University of Michigan C.S. Mott Children's Hospital, Ann Arbor, USA.

¹³Hôpital Marie Lannelongue, Le Plessis-Robinson, France.

¹⁴Centre Hospitalier Universitaire de Nantes, Institut du Thorax, Fédération des Cardiopathies Congénitales, Service de Cardiologie, Nantes, France.

¹⁵Department of Cardiology, Boston Children's Hospital, Boston, USA.

¹⁶The Heart Institute, Cincinnati Children's Hospital Medical Center, University of Cincinnati College of Medicine, Cincinnati, USA.

¹⁷Hopital des enfants CHU, Toulouse, France.

¹⁸Lucile Packard Children's Hospital Stanford, Palo Alto, USA

Background: Transcatheter pulmonary valve replacement (TPVR) has gained acceptance as a non-surgical alternative in patients with a dysfunctional RV-PA conduit or bioprosthetic valve. However, current transcatheter valve technology is only approved to treat a minority of patients with right ventricular outflow tract (RVOT) dysfunction who merit intervention. A majority of patients referred for pulmonary

valve replacement have a history of surgical repair with an RVOT patch or transcatheter valvuloplasty without placement of a pulmonary conduit or prosthesis, and have regurgitation through this patched or native RVOT. The primary aims of this large multicenter study were to evaluate the efficacy and safety of TPVR in the native or patched RVOT.

Methods: An international multicenter retrospective study was performed of all patients who underwent TPVR with a Sapien XT or S3 valve in a native or patched RVOT from 2014-2018. Demographic, diagnostic, procedural, and outcome data were collected after local IRB approval.

Results: A total of 240 patients underwent placement of a Sapien XT (n=43) or S3 (n=197) valve in the native RVOT, through either a femoral venous (87%), jugular venous (3%), or hybrid periventricular (10%) approach. The median age was 21 yrs (Q1-Q3 4-77 kg) and the median weight was 61 kg (Q1-Q3 15-159 kg). Baseline anatomy was predominantly tetralogy of Fallot (n=190) followed by valvar pulmonary stenosis (n=30). RVOT dysfunction consisted predominantly of severe pulmonary regurgitation (PR) in 202 patients (84%), pulmonary stenosis in 2, and mixed disease in 36. Sapien valve size was 29 mm in 167 patients (70%), 26 mm in 60 (25%), and 23 mm in 13 (5%). Pre-stent implantation was performed in 70% of patients. There was no procedural mortality. Procedural complications were identified in 13% of patients, including tricuspid valve injury (n=12, 5%), valve embolization (n=9, 4%), arrhythmia (n=8, 3%), pre-stent embolization (n=2, 1%), and coronary/aortic compression from the device (n=2, 1%). Valve embolization was more common in pre-stented pts (78%). On post-procedure echocardiography, 5 patients had moderate PR (all others had mild or less PR), 8 had mild paravalvular leak, and none had significant RVOT obstruction. During follow-up (median 1.7 years), endocarditis was diagnosed in 5 patients. Surgical interventions resulting from complications included tricuspid valve repair in 5 patients and pulmonary valve replacement in 6 (2 valve embolization, 2 aortic/coronary compression, 1 primary valve failure, 1 endocarditis). There were 3 deaths during follow-up, 1 from heart failure, 1 from progressive respiratory failure, and 1 of unknown cause.

Conclusions: In this international multicenter study, Sapien valve placement in the native or patched RVOT was found to be feasible with good hemodynamic outcomes and acceptable short-term results. Tricuspid valve injury and valve embolization during the procedure were notable complications. Long-term valve function is yet to be determined

109. PERICARDIAC MASS CAUSING RIGHT VENTRICULAR OUTFLOW TRACT OBSTRUCTION FOLLOWING BALLOON DILATION OF A RIGHT VENTRICLE TO PULMONARY ARTERY HOMOGRAFT.

Shanique Sterling¹, Rachel Manalo¹, Robert Toussant¹, Satinder Sandhu²

¹Jackson Memorial Hospital, Miami, USA. ²University of Miami, Miami, USA

Contained and uncontained disruption of the homograft has been described in patients undergoing transcatheter dilatation or stent placement in a stenotic or regurgitant right ventricle (RV) to pulmonary artery (PA) homograft. Disruption of the homograft can be asymptomatic or can cause hemodynamic compromise during the procedure or within hours. We describe the presentation of hemodynamically significant right ventricular outflow tract (RVOT) obstruction by external compression more than 11 months after the procedure.

A 26 year old male with Type II truncus arteriosus previously underwent ventricular septal defect closure and multiple right ventricle to pulmonary artery conduit revisions. At 15 years of age a 24 mm RV to PA aortic homograft was placed and a bovine pericardial patch was used to extend the homograft. In addition a gortex pericardial membrane (Gore, Flagstaff, Az) was placed to cover the homograft. At 26 years of age he presented with a heavily calcified, stenotic and regurgitant homograft. He underwent balloon dilation with a high pressure balloon followed by pretesting of the homograft with a Palmaz XL 3110 (Cordis, Milpitas, Ca) into which a 22 mm Melody valve (Medtronic Inc, Minneapolis, MN) was placed on a 20 mm Ensemble. There was a decrease in the right ventricular pressure from 65% systemic to 38% of systemic. At 1 year follow up post procedure an increasing gradient was noted across the RVOT below the melody valve from external compression. An MRI done revealed a pericardiac lesion compressing the RV free wall and the RVOT. There was no communication noted between the RVOT and the compressing lesion. A CXR done showed no narrowing or fracture of the melody valve. A cardiac catheterization was done 17 months post Melody valve placement and on balloon dilation of the RVOT there was no residual waist. A covered CP stent was placed across the valve and the RVOT and a 22mm Melody valve was placed within it. There was restenosis noted at the 1 month follow up. He underwent surgery and on removal of the gortex pericardium it was noted that there was a large amount of old clot that had accumulated under the gortex membrane which was compressing the RVOT. The second stent and melody valve were removed. The original melody valve was functional

and was left in place and a new pericardial patch was placed to extend the homograft.

Conclusion: Disruption of RV to PA homograft is an established yet relatively infrequent complication with most cases presenting in the periprocedure period. In this patient the gortex membrane placed to cover the homograft became a pocket in which the bleeding from the procedure resulted in clot formation that remained contained over an extended period of time eventually resulting in compression of the RVOT.

110. COIL EMBOLIZATION OF MAJOR AORTOPULMONARY COLLATERALS IN A CRITICALLY ILL INFANT WITH SCIMITAR SYNDROME

Raymond Morales¹, Aya El Jerbi², Joshua Murphy¹

¹Rush University Medical Center, Chicago, USA. ²Southern Illinois University, Springfield, USA

Scimitar syndrome is a rare congenital heart anomaly, consisting of abnormal partial anomalous pulmonary venous drainage to the inferior vena cava and right lung hypoplasia in association with dextroposition of the heart. Patients may have variable presentation ranging from a lack of symptoms to florid congestive heart failure. We report on a rare case of a 2 month old infant with Scimitar syndrome who developed acute cardiopulmonary compromise secondary to a viral infection that only improved after coil occlusion of two aortopulmonary collaterals. This report provides further evidence that early identification and percutaneous treatment of these collaterals may have significant clinical benefit prior to any surgical intervention.

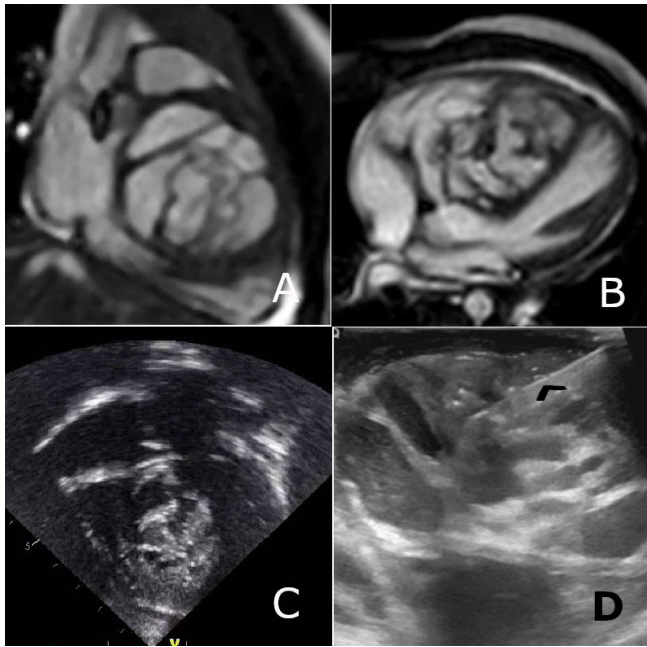
111. NOVEL ULTRASOUND GUIDED INTRAOPERATIVE NEEDLE BIOPSY OF INTRACARDIAC TUMOR

Subhrajit Lahiri, Henri Justino, Jeffrey Heinle, Jeffrey Kim, Santiago Valdes, Jose Hernandez, Christina Miyake

Texas Children's Hospital, Houston, USA

Background: This is a case report of a patient with intracardiac teratoma and ventricular tachycardia. In this case report we describe the use of a novel hybrid approach to histopathologic diagnosis of a ventricular septal teratoma using ultrasound guided intraoperative biopsy without need for cardiopulmonary bypass.

Case Report: Patient was born with a prenatal diagnosis of an intracardiac tumor in the interventricular septum which was confirmed post-fatally. An open surgical biopsy of the mass was considered after birth but was deferred because the mass was deemed unresectable due to the size and location of the tumor occupying the entire interventricular



111. Figure 1.

septum. Over next two years tumor was progressively increasing in size with increasing atrioventricular conduction delay and ventricular tachycardia. At 25 months of age when she was 13 Kg, she underwent median sternotomy. An epicardial echocardiogram was then used to visualize the mass. Multiple biopsies were obtained with 16F trocar needle, Cook Quick-Core™ biopsy needle (Cook, Bloomington, Indian) as well as aspiration of tumor content with a 22G Chiba™ needle (Cook, Bloomington, Indiana) under ultrasound guidance. (Fig.) A pacemaker was implanted after biopsy; histopathology from the biopsy sample confirmed the diagnosis of teratoma.

Conclusion: We suggest that this novel technique may be an option in specific cases of cardiac tumors where tissue diagnosis is important but surgical resection is deemed too risky or impossible. This is also the first report of ventricular tachycardia and use of a pacemaker placement for an intracardiac teratoma. A&B. MRI of the teratoma in ventricular septum. C. Echocardiogram of the tumor. D. Intra-operative needle biopsy of the tumor by ultrasound guidance. Needle marked by black arrow head.

112. TRANSCATHETER AORTIC VALVE REPLACEMENT (TAVR) VS SURGICAL AORTIC VALVE REPLACEMENT (SAVR) IN PATIENTS WITH PREVIOUS CARDIAC SURGERY.

Janine Anita Miranda¹, Joseph Chen², Elizabeth Wilson¹, Sanjeevan Pasupati¹, Rajesh Nair¹

¹Waikato Hospital, Hamilton, New Zealand. ²University of Auckland, Auckland, New Zealand

Background: Despite higher risks of redo cardiac surgery, “low risk” patients are still offered SAVR using bioprosthesis in the era of TAVR. This retrospective study set out to determine differences in clinical outcomes between SAVR and TAVR in patients who have had previous cardiac surgery in a tertiary centre.

Method: Patients who received SAVR and TAVR between July 2008 – July 2018 with previous history of cardiac surgery were identified from the hospital database. Mortality, length of stay in intensive care unit (ICU), duration of hospital stay, stroke and pacemaker implantation prior to discharge were studied.

Results: With the history of prior cardiac surgery, 67 patients underwent SAVR and TAVR was performed on 53 patients. There was one patient who received a SAVR followed by TAVR and was included in both categories. 1 further patient had two redo SAVRs within the study time.

“Valve-in-valve” TAVR was performed for previous bio-prosthetic valve failure in 12 (23%) patients. 30 (45%) patients underwent redo SAVR with no other concomitant surgical procedure.

Results: 30-day mortality was 7/67 (10%) for patients undergoing SAVR vs 1/53 (2%) in TAVR arm ($p=0.104$). 1-year mortality was 8/67 (12%) in SAVR compared to 2/53 (4%) in those with TAVR ($p=0.134$). All SAVR patients stayed in ICU whereas only 1 patient who received TAVR stayed in ICU for 4 days. Average ICU stay was 2.96 days in patients with SAVR. Average length of hospital stay was 15 ± 1.72 days for SAVR vs 7 ± 0.76 days after TAVR ($p < 0.0001$). Pacemaker implantation prior to discharge was 2/67 (3%) and 6/53 (11%) patients post-procedure in SAVR and TAVR respectively ($p=0.09$). Change in mean aortic valve gradient following SAVR was -21 ± 4.4 mmHg and following TAVR was -44.4 ± 3.52 ($p=0.00019$).

Average age of patients receiving redo SAVR was 59.5 ± 13 years. 30-day and 12-month mortality for redo SAVR were 2 (6.7%). Average age of patients undergoing “valve-in-valve” TAVR was 76 ± 7 years. There was 0% surgical and 1-year mortality.

5-year mortality was 4 (13%) for redo SAVR vs 3 (25%) for “valve-in-valve” TAVR; in line with TAVR being offered for the sicker patient group. This was confirmed with the

112. Table 1. Baseline Characteristics.

	TAVR n=53	SAVR n=67	
AVA cm ²	0.78±0.03	1.04±0.88 (n=38)	<i>p</i> =0.02
Mean Gradient (mmHg)	58±21	36.14±2.81 (n=46)	<i>p</i> =0.0000012
LVEF (%)	42±24	55.99±10.90 (n=46)	<i>p</i> =0.61
Age (years)	68.5±1.31	60.0±1.31	<i>p</i> =0.0003
Male	43 (81%)	44 (65.7%)	<i>p</i> =0.093
% Indigenous Maori	4 (7%)	13 (19%)	<i>p</i> =0.10
BMI	26.2±0.786	29.91±0.57	<i>p</i> =0.00035
EUROSCORE 2	13.8±3.80	8.71±1.29	<i>p</i> =0.0378
Plasma creatinine	131.1±13.8	99.8±4.63	<i>p</i> =0.017

average Euroscore II for redo SAVR being 5.3% vs 19.4% for “valve-in-valve” TAVR.

Conclusion: Despite small study numbers and difficulties in comparing two groups with different risk profiles, there is a trend towards reduced 30-day and 12-month mortality for TAVR in patients with previous cardiac surgery. Patients who received TAVR spent less time in hospital and had improved valve haemodynamic profiles.

113. PATIENT-SPECIFIC COMPUTATIONAL FLUID DYNAMIC MODELING ACCURATELY PREDICTS PRESSURE GRADIENTS ACROSS STENOTIC RIGHT VENTRICULAR OUTFLOW TRACTS

Michael Shorofsky, Xuanming Zhao, Michael Spaeder, Haibo Dong, Michael Hainstock

University of Virginia, Charlottesville, USA

Computational fluid dynamics (CFD) is a well-studied field of engineering whose principles have been applied to modeling of the human circulatory system and complex blood flow patterns. This has allowed for a better understanding of flow dynamics, shear stresses, and device testing by using patient specific models to perform *in silico* trials of surgical and interventional techniques¹. CFD has also been applied to a small portion of congenital heart defects. It has been used to accurately predict pressure gradients across areas of coarctation of the aorta² and surgical planning of patients prior to Glenn³ and Fontan⁴ operations. To our knowledge CFD has not been used in the setting of transcatheter pulmonary valve replacement (TPVR) planning.

Our aim in this study is to validate a modeling technique that accurately predicts pressure gradients when

compared to in vivo cardiac catheterization measurements across a stenotic right ventricle outflow tract.

We performed a retrospective chart review of patients who underwent TPVR at our institution. Five patients who underwent TPVR and had a CT scan prior to intervention were identified for this study. Each CT was processed using 3D Slicer^{5,6} to build a 3-dimensional model. The model was then processed via ANSYS ICEM software to construct a mesh model for CFD testing. ANSYS Solver was then used to model the fluid dynamics through the heart model.

CFD was performed on the five patient specific models. Results were obtained for the models and compared to the catheterization data for the patient (Table 1). We performed linear regression to assess the ability of our model to predict pressures that were obtained during cardiac catheterization. Linear regression demonstrated a very strong correlation between our model gradients and the catheterization gradients with an adjusted R² of 0.99. Model coefficient values were b₁=0.93 and b₀=3.29 (p=0.001).

This validation study has shown that taking 3D images and building a CFD model can accurately predict the change in pressure across the right ventricular outflow tracts. This model can subsequently be applied to the pre-catheterization planning prior to patients that require a PVR. In the future, we hope to expand on this modeling technique and begin to apply it to more complicated congenital heart defects in addition to simulating surgical and transcatheter interventions.

114. HYBRID SUBXIPHOID APPROACH AS AN ALTERNATIVE ACCESS IN CHILDREN UNDERGOING COMPLEX CONGENITAL HEART INTERVENTIONS

Li Yen Ng, Khalid Al-Alwi, Jonathon McGuinness, Lars Nölke, Mark Redmond, Brian McCrossan, Paul Oslizlok, Kevin Walsh, Damien Kenny

Our Lady Children Hospital Crumlin, Dublin, Ireland

Background: Hybrid periventricular approach provides direct access through the heart and may alleviate the technical limitations of complex percutaneous interventions particularly in infants with low body weight. We present our single centre experience and outcomes using this approach.

Method: Retrospective review of patients less than 15kg who underwent a hybrid periventricular approach via a small subxiphoid incision. Medical records were reviewed to obtain clinical, demographic and outcome data.

Results: 12 patients underwent 13 hybrid periventricular procedures using a subxiphoid approach. Median age at time of procedure was 5.5 months (9 days to 39 months) and median weight was 6.9kg (2-10.7). Procedure success rate was 100% none of the cases reverted to open surgical repair. Five patients underwent hybrid pulmonary valve replacement with three of these undergoing supplemental pulmonary artery stenting. Three patients underwent pulmonary outflow stenting and 2 infants underwent hybrid VSD device closure. One patient with a single ventricle who did not tolerate a percutaneous approach underwent LPA stenting for severe LPA coarctation with subsequent RVOT stenting. One further patient underwent implantation of a larger diameter stent for pulmonary artery bifurcation stenosis. There were no intra-procedural complications however one patient died within 72 hours. Minor adverse events occurred in 2 patients including a wound infection in one patient with an immunodeficiency syndrome.

Conclusion: Hybrid subxiphoid approach provides excellent alternative access to the heart especially in low birth weight infants to prevent hemodynamic instability or in small children requiring large delivery sheaths.

115. TRANSCATHETER THERAPY OF CONGENITAL AND POSTOPERATIVE PULMONARY VEIN STENOSIS.

Tatiana Molina-Sánchez, José García-Montes, Juan Pablo Sandoval-Jones, Carlos Zabal-Cerdeira, Juan Calderón-Colmenero

Ignacio Chavez National Institute of Cardiology, Mexico City, Mexico

Background: Pulmonary vein stenosis (PVS) either congenital or acquired (i.e. postoperative, post-radiofrequency ablation procedures) is associated with significant morbidity and poor outcome. Grim prognosis remains in patients affected with pulmonary vein stenosis and are often subject to repeated interventions.

Methods: Single center retrospective review including all children (0-18 years) who underwent transcatheter pulmonary vein intervention (balloon angioplasty or stent implantation) for congenital or postoperative PVS between January 2009 and January 2019.

Results: Fifteen patients underwent pulmonary vein intervention (balloon angioplasty (n=4,27%); stent implantation (n=11, 73%) at a median age of 16 months (1 month-16 years). Intervention was consequence of postoperative PVS for total pulmonary venous return repair in 86% of cases. Single vein intervention was performed in 5 children, two veins in nine and one patient required intervention in all 4 pulmonary veins. For patients undergoing stent placement only one had two placitaxel-coated stents deployed, the rest were performed using appropriately sized standard bare metal coronary stents. Acute relief of obstruction (from a technical standpoint) was considered successful according to luminal gain determined on repeat angiography in all cases. Pullback pulmonary vein gradient post stent delivery was only recorded in 9 (52%) patients. A gradient decrease of $\geq 75\%$ was achieved in 6 (66%) of these 9 patients. Major complications included stent embolization in one patient and pulmonary vein perforation in another. Early 30-day mortality occurred in 20% despite intervention. In addition, early catheter reintervention was high in our series (up to 20%).

Conclusions: A percutaneous approach for secondary PVS may be considered an alternative in selected candidates. However, despite technical success (if considering luminal gain after balloon or stent angioplasty), frustration is frequently met when dealing with this complex intervention due to considerable mortality and high rate of restenosis leading to reintervention in this often extremely fragile population.

References:

1. *Circ Cardiovasc Interv.* 2012;5:109-117.
2. *J Am Coll Cardiol Intv* 2017; 10; 17: 1788 - 1798

116. PREVALENCE AND PREDICTORS OF ATRIAL ARRHYTHMIAS IN CLINICALLY SIGNIFICANT SECUNDUM ATRIAL SEPTAL DEFECT

Abhishek Chakraborty¹, Mohanageetha Ardhanari¹, Satinder Sandhu^{2,1}

¹Jackson Memorial Hospital, Miami, USA. ²University of Miami, Miami, USA

Background: Hemodynamically significant secundum atrial septal defect (ASD) can be associated with atrial arrhythmias.

Objectives: The objectives of this study were to observe the prevalence of atrial arrhythmias in patients who underwent transcatheter/surgical closure of ASD and to identify factors predictive of the occurrence of atrial arrhythmias.

Methodology: Patients older than 4 years who underwent transcatheter or surgical closure of ASD from January 1998 to December 2018 were identified. Patients with concomitant congenital heart disease and with no follow-up after ASD closure were excluded from our study. Basic demographics, co-morbidities, age of closure, type of closure, presence of atrial arrhythmias before, immediately after and 1 year after closure were identified through retrospective chart review. Factors predictive of the prevalence of atrial arrhythmias: hemodynamic and other cardiovascular characteristics of the patients were identified before closure, immediately after and 1 year after ASD closure. Univariate analysis of risk factors predicting the prevalence of atrial arrhythmias were done using Chi-square test. Binary logistic equation was used to identify independent factors predictive of atrial arrhythmias.

Results: There were 82 patients with age range 4-77 years (25.5±18.4; mean ±SD); ASD diameter range 5-44 mm (22.7±10.2). The age at ASD closure was 4-77 years (35±20.5). There were 45 (54.9%) patients with ASD closure before 40 years and 37 (45.1%) had closure after 40 years of age. Comparing the patient characteristics and arrhythmias in the surgically corrected group (n=41) vs device closure group (n=41) the only significant difference was the size of the ASD: 20.3 ± 8.5 mm in the device closure group vs 27.2 ± 10.7 in the surgical closure group. There were no statistically significant differences in the prevalence of arrhythmias or other patient characteristics between the two groups. Atrial flutter /fibrillation (AFF) was present in 23.2% of patients before closure. Size of the ASD, presence of mitral regurgitation (MR) or tricuspid regurgitation (TR), right atrial (RA) dilatation, right ventricular (RV) dilation, left atrial (LA) dilatation and presence of right heart (RH) failure were associated with increased prevalence of AFF in this group of patients. RV dilatation was found to be an independent predictor of AFF. AFF was present in 14.6% of patients in immediate post-closure period, and in 14.6%

of patients at 1 year-follow up. Age > 40 years, presence of residual moderate to severe RA dilatation, RV dilatation, LA dilatation, RH failure, MR and TR immediately after the procedure and at 1 year follow up were associated with increased prevalence of arrhythmias at 1-year follow-up. TR in the immediate post-procedure period was predictive of AFF 1-year post closure. At 1 year follow up there were 7 patients (transcatheter closure in 2 and surgical closure in 5) with new onset arrhythmias.

Conclusions: There is significant prevalence of AFF in hemodynamically significant ASD both before and after ASD closure. RV dilatation before closure is a significant predictor of AFF before closure, whereas, presence of moderate to severe TR is a significant predictor of AFF post closure.

117. REACHING BEYOND MANUFACTURER RECOMMENDED EXPANSION DIAMETER: SERIAL STENT DILATION FOR SOMATIC GROWTH IN CHILDREN

Peter Guyon^{1,2}, Bryan Mosher^{1,2}, Kanishka Ratnayaka^{1,2}, John Moore^{1,2}, Howaida El-Said^{1,2}

¹University of California San Diego, San Diego, USA. ²Rady Children's Hospital, San Diego, USA

Background: Stenting to relieve vessel stenosis in small patients requires use of small, low-profile stents. Subsequent vessel growth presents a problem since the small stents are not designed or recommended to expand to the size of a mature vessel.

Our primary aim is to examine a cohort of small stents which underwent serial dilation for patient growth. In all cases the stents were expanded beyond the nominal expansion diameter (manufacturer recommendation); in some cases they were expanded near or beyond the experimentally reported maximal expansion diameter; and in some cases they were intentionally fractured with re-stenting inside the fractured stent. This is the first such study in humans.

Methods: Retrospective review of all cases between 2004 and 2019 in which small diameter Formula, Visi-Pro, and Genesis stents were placed in the aorta or pulmonary arteries and then subsequently dilated for patient growth. Demographic data and procedure data are reported for each stent in the cohort. Key metrics are reported, including the presence of spontaneous fractures and any serious complications, as well as planned fractures and re-stenting.

Results: A total of 25 stents were implanted in 23 patients. The average age at original stent implantation was 14

months (range 79 days to 5.5 years); average weight was 8.4kg (range 4.3kg-12.6kg). Eight stents (32%) developed a spontaneous circumferential fracture without hemodynamic or clinical implications. Three stents (12%) were fractured intentionally with re-stenting within the fractured stent. The Cook Formula stents (n = 15) were expanded on average to 169% of their original diameter (OD), 151% of the (manufacturer recommended) nominal expansion diameter (NED), and 82% of the experimentally reported maximal expansion diameter (MED). Genesis stents (n = 6) were expanded on average to 145% of their OD, 145% NED, and 82% MED. VisiPro stents (n = 4) were expanded on average to 170% OD, 151% NED, and 106% MED. There were no major adverse events (stent embolization, vessel disruption with hemorrhage, stent thrombosis) in the cohort.

Discussion: Small, low-profile stents have a capacity for safe expansion far beyond what is recommended by the manufacturer. Dilation to or beyond the reported maximal expansion diameter and even fracture of the stent with re-stenting did not result in significant adverse events in this cohort. This data suggests that use of small stents with serial dilations over the course of months and years is a safe and effective strategy. Additionally, the technique of expanding small stents to or near the point of fracture, then deploying a larger stent within the smaller stent while intentionally fracturing the original small stent, which was utilized in a few cases, shows promise and will be the focus of further study in this cohort as patient growth continues.

Conclusion: Serial balloon dilation of small stents beyond the manufacturer recommended expansion diameter to or near the true maximal expansion diameter appears safe in this cohort of children. Intentional stent fracture with re-stenting also appears safe, although the number of patients is small. Further study is needed to confirm these initial observations.

118. USE OF DEFLECTABLE SHEATHS TO GUIDE COMPLEX CONGENITAL HEART INTERVENTIONS

Khalid Al-Alawi, Li Yen Ng, Paul Oslizlock, Kevin Walsh, Damien Kenny

Our Lady's Children's Hospital, Crumlin, Dublin, Ireland

Introduction: As the complexity of transcatheter interventions have increased, so has the requirement for adjuncts to assist in catheter support and precise catheter positioning. Deflectable sheaths have been used in electrophysiology studies for many years to optimize precise catheter placement and are becoming more commonplace particularly in complex anatomy to assist with stent and device

placement. We present our single centre experience using deflectable sheaths in pediatric patients undergoing complex interventions.

Methods: We conducted a retrospective review of all pediatric patients who required a deflectable steerable sheath during cardiac catheterization in our center. Medical records were reviewed to obtain clinical, demographic and outcome data.

Results: Deflectable sheaths were used in 15 patients. The median IQR age was 8 years (2yr 11 months – 13 yrs) with median IQR weight 18.7kg (14.9– 47). Six patients underwent pulmonary artery bifurcation stenting, four requiring Y stent technique. Three patients underwent successful closure of either complex membranous (n=2), or supracristal (n=1) VSD's. Two patients underwent Fontan fenestration interventions. One child underwent ovalisation of a LPA stent and another had occlusion of a complex collateral with two previous unsuccessful attempts using a fixed curve sheath. One teenager with severe idiopathic pulmonary hypertension underwent a reverse Potts shunt. One further child underwent distal RPA stenting with ballooning into a side branch assisted by a deflectable sheath. All procedures were successful with no complications related to the use of the deflectable sheaths.

Conclusion: Deflectable sheaths assist in optimizing access to complex congenital heart lesions and provide support for device and stent delivery. In particular pulmonary artery bifurcation stenting and hybrid subxiphoid VSD closure in smaller children may benefit from this approach.

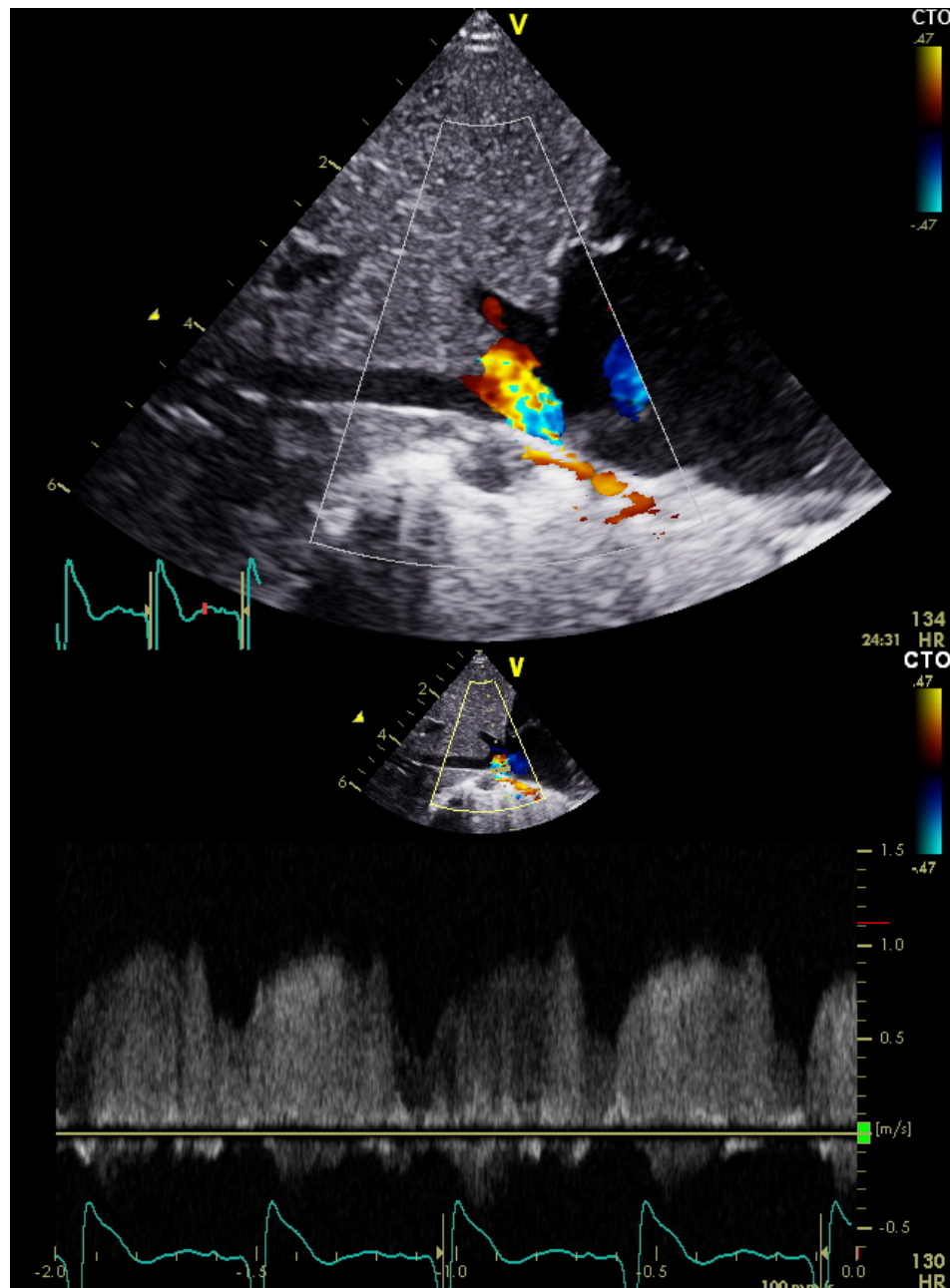
119. ANOMALOUS ORIGIN OF LEFT CORONARY ARTERY FROM RIGHT PULMONARY ARTERY IN ASSOCIATION WITH SCIMITAR SYNDROME

Safwat Aly^{1,2}, Ramiro Lizano Santamaria¹, Shi-Joon Yoo^{1,2}

¹The Hospital For Sick Children, Toronto, Canada. ²University of Toronto, Toronto, Canada

Clinical Presentation: A full-term neonate was referred to our institution because of respiratory distress requiring respiratory support. Chest x-ray was significant for right lung hypoplasia and mild cardiomegaly. Electrocardiogram showed normal sinus rhythm, right atrial enlargement, and right ventricular hypertrophy with no signs of ischemia. Genetic testing revealed *FRAS1* gene mutation.

Imaging Findings: The initial echocardiogram demonstrated a partial anomalous pulmonary venous drainage with the right upper pulmonary vein draining into inferior vena cava /right atrium (IVC/RA) junction with flow

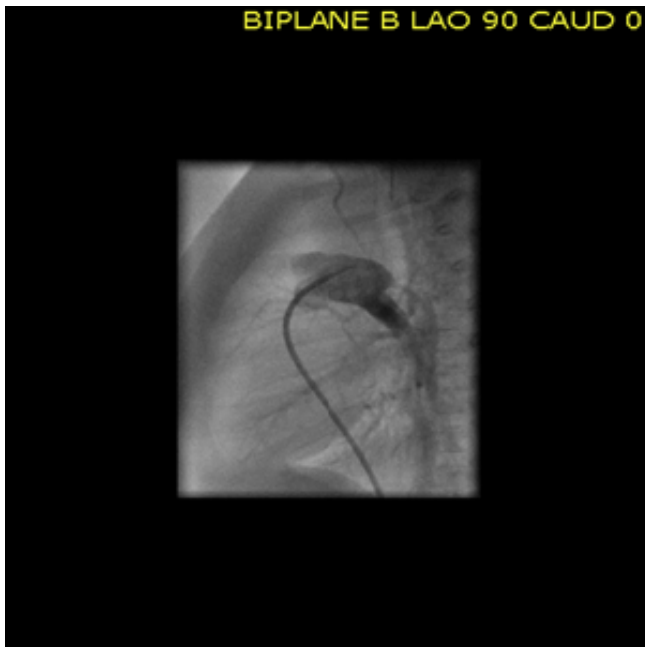


119. Figure 1 (Image 1A & 1B). Color Doppler showing scimitar vein draining into IVC/RA junction with flow acceleration.

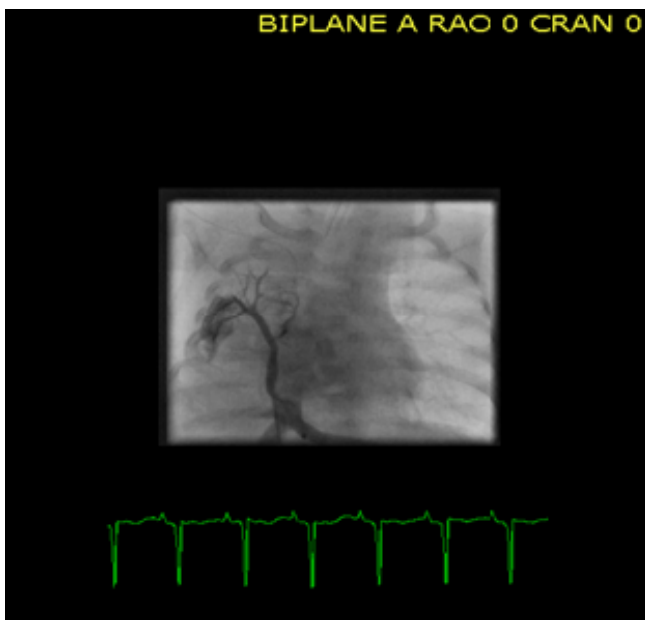
acceleration (mean gradient=7mmHg) (**Figure 1A & 1B**), moderate secundum atrial septal defect, small muscular ventricular septal defect with left-right shunting, moderate patent ductus arteriosus with bidirectional shunting. The right ventricular (RV) systolic pressure was supra-systemic with a qualitatively moderately reduced RV systolic function and normal LV systolic function. The patient was taken to the catheterization lab where the main pulmonary artery angiography revealed an antegrade flow from the right

pulmonary artery (RPA) into the left main coronary artery (LMCA) supplying both the anterior descending and the circumflex arteries (**Figure 2**). A selective injection within the anomalous scimitar vein showed drainage of the right lung into a curvilinear vertical vein connecting with stenosis to IVC at the level of the diaphragm (**Figure 3**).

Role of Imaging in Patient Care: Imaging of the coronary origin in patients with ALCAPA can be challenging



119. Figure 2. Injection into MPA showing LMCA origin from RPA.



119. Figure 3. Injection into a stenotic scimitar vein connecting into IVC/RA junction.

especially if the LMCA originates from RPA. Also, the presence of pulmonary hypertension might contribute to maintain coronary perfusion and lead to misinterpretation of the antegrade flow in LMCA and its branches.

Cardiac catheterization remains the best imaging modality to evaluate the coronary arteries preventing a potentially catastrophic outcome as demonstrated in this case. Catheter intervention with a series of balloon dilations of the stenotic scimitar vein was successful in relieving the stenosis. Moreover, coil embolization of two major collaterals arising from the aorta and supplying the right lower posterior lung was performed. Then, the patient underwent reimplantation of LMCA into the aorta with a favorable outcome.

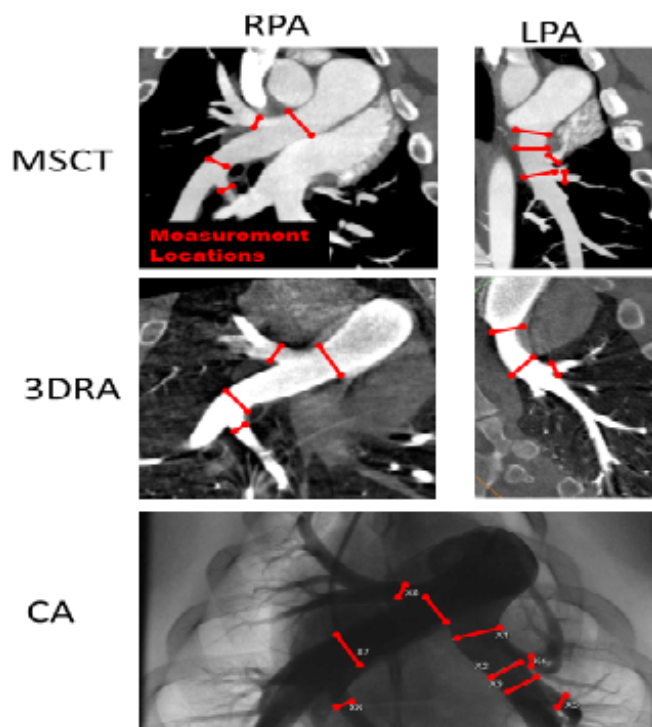
Summary/Discussion Points:

- An extensive review of the available literature revealed only few cases of Scimitar syndrome associated with ALCAPA. In all of these cases, the LMCA originated from the posterior sinus of MPA. Our case is the first to report ALCAPA from RPA in association with Scimitar syndrome. This presentation might have led to the initial misinterpretation of the echocardiography images.
- The presence of pulmonary hypertension in our patient maintained an adequate antegrade flow across the LMCA preventing significant coronary steal and signs of myocardial ischemia.
- The report highlights the essential role of cardiac catheterization not only assisting in the diagnosis and intervention on the scimitar vein but also to rule out potential coronary arteries anomalies in patients with Scimitar syndrome, as this a rare although a very significant association that may have important implications in their outcomes.

120. COMPARISON OF PULMONARY ARTERY DIMENSIONS OBTAINED FROM CONVENTIONAL ANGIOGRAPHY, 3D-ROTATIONAL ANGIOGRAPHY AND MULTI-SLICE COMPUTED TOMOGRAPHY

Ryan Pewowaruk, Alejandro ALZATE Roldan Alzate, Carolina Larrain, Christopher Francois, Luke Lamers
University of Wisconsin - Madison, Madison, USA

Introduction: Precise imaging of the pulmonary arteries (PA) is essential for management of patients with complex congenital heart disease (CHD). Conventional 2D angiography (CA) remains the gold standard for morphological and quantitative assessment of the PAs. Previous studies demonstrate strong correlations of measured PA diameters between CA and multi-slice computed tomography (MSCT). 3D rotational angiography (3DRA) has similar imaging capabilities to MSCT and has been used to guide PA interventions in CHD; yet no objective assessment of 3DRA image capabilities for PA anatomy exist and it is unclear how PA stenosis and PA stents influence 3DRA



120. Figure 1.

measures. The study purpose is to investigate the diagnostic reliability of 3DRA compared to CA and MSCT for quantification of PA morphology in a swine model of PA stenosis \pm PA stent interventions.

Methods: Sixteen anesthetized 20-week old swine (55 ± 9 Kg - 4 sham controls, 4 untreated proximal LPA stenosis and 8 stented proximal LPA) had CA, MSCT and 3DRA. MSCT was performed using a 64-slice CT scanner (GE 750 CT, GE Healthcare, Waukesha, WI) using retrospective cardiac gating. Scan variables included: collimation 40mm, slice thickness 0.625 mm, 140 kV (peak), tube current 570 mA, acquisition diameter 29cm and 512x512 reconstruction matrix. CA and 3DRA was performed on a single plane Artis Z system (Siemens Healthcare, Forchheim, Germany). CA was acquired with caudal and LAO angulation to profile the proximal LPA. 3DRA utilized a 200° rotation over 5 sec at 60 frames/sec with contrast injection preceding image acquisition by 1 sec with simultaneous IVC balloon occlusion.

Quantification of PA measurements were evaluated independently in the following locations: Proximal LPA, RPA, LPA/RPA adjacent to two first order branches and diameters of two proximal RPA/LPA first order branches (Figure 1). CA measurement was performed on the Siemens workstation. Orthogonal planes of the areas

120. **Table 1.** Representative locations for 2D and 3D measurements.

Results:

	Mean difference Stent [std] (mm)	Mean difference Stenosis [std] (mm)	Mean difference All PA segments [std] (mm)	R ² All PA segments
CA vs 3DRA	0.5 [0.8]	0.2 [0.4]	0.7 [1.4]	0.88
MSCT vs 3DRA	-0.3 [0.8]	0.0 [0.2]	0.7 [1.6]	0.85

of interest were generated from post processing multiplaner reformatting tools for MSCT (McKesson Technology Solutions, Alpharetta, GA) and 3DRA (Mimics Materialise Medical, Plymouth, MI) from which maximum PA dimensions were recorded. Differences in vessel diameters between modalities was assessed using a Bland-Altman difference analysis. There was excellent correlation between 3DRA to both CA and MSCT for quantification of mean differences in PA dimensions for all measured segments (Table 1) although systematically 3DRA trended toward smaller measures. Similar agreement in mean PA dimensions existed in stenotic (1.4 ± 0.1 , 1.6 ± 0.3 , 1.7 ± 0.1 mm) and stented (9.7 ± 1.0 , 10.2 ± 1.0 , 10.2 ± 0.8 mm) PA segments when comparing 3DRA to MSCT and CA.

Conclusion: These findings show strong correlation in vessel diameters between 3DRA, CA and MSCT in normal, stenotic and stented PAs. This study demonstrates the feasibility of 3DRA to accurately assess PA size and morphology in an animal model of CHD.

121. NATIVE RIGHT VENTRICULAR OUTFLOW TRACT (NRVOT) DYSFUNCTION TREATED WITH THE ALTEERRA ADAPTIVE PRESTENT AND SAPIEN 3: PATIENT SELECTION AND DEVICE SIZING

Shabana Shahanavaz¹, David Balzer², Vivian Dimas³, Vasilis C. Babaliaros⁴, Dennis Kim⁵, Kelly Han⁶, Philipp Blanke⁷, Jeremy Gorelick⁸, Evan Zahn⁹

¹Washington University in St. Louis School of Medicine, St. Louis, USA. ²Washington University in St. Louis School of Medicine, St. Louis, MO, USA. ³Children's Medical Center UT Southwestern Medical Center, Dallas, TX, USA. ⁴Emory University, Atlanta, GA, USA. ⁵Children's Healthcare of Atlanta, Atlanta, GA, USA. ⁶Minneapolis Heart Institute, Minneapolis, MN, USA. ⁷University of British Columbia and St. Paul's Hospital, Vancouver, BC,

Canada. ⁸Edwards Lifesciences, Irvine, CA, USA. ⁹Cedars-Sinai Medical Center, Los Angeles, CA, USA

Background: Many patients with right ventricular outflow tract (RVOT) dysfunction are not candidates for percutaneous valve replacement due to RVOT size and geometry. The Edwards self-expanding Alterra Adaptive PreStent internally reduces and reconfigures the RVOT to provide a landing zone for a 29 mm Edwards SAPIEN 3 (S3) transcatheter heart valve.

Methods: At 4 U.S. investigational sites, eligible patients weighing at least 20 kg, with moderate to severe pulmonary regurgitation (PR) were enrolled in an early feasibility study (EFS). Patients were considered suitable candidates for implant if systolic dimension of the RVOT was between 27–38 mm long, and the length of the RVOT from takeoff of the branch pulmonary artery to the contractile portion of the RV was >35 mm long. Anatomical analysis of the RVOT at baseline, including lengths, diameters, and circumference along the length of the potential deployment zone was performed using a gated CT that covered the entire RVOT and main pulmonary artery (MPA) throughout the entire cardiac cycle. Centerline-based measurements of the RVOT circumference were made from the raw data obtained during peak systole at the time of maximal MPA distension and diastole. The diameter and perimeter plots were created and analyzed in relation to the diameter and perimeter of the unconstrained device. Virtual implants of an unconstrained, fully expanded device were evaluated for device contact with vessel wall in both systole and diastole. Table top implants in polyjet models of the RVOT of each patient were performed at peak systole and diastole prior to actual patient implants.

Results: From August 2017 through June 2018, 29 patients were screened and 15 patients were implanted (52%). The primary reason for exclusion was anatomical unsuitability of the RVOT for the Alterra preStent. Of the 14 patients excluded, 4 had outflow tracts that were too narrow, with RVOT diameter measurements <27 mm (2 of these 4 patients underwent primary S3 implantation; treatment for the other 2 is unknown); 4 patients were excluded for RVOT length measurements <35 mm; 4 patients were excluded for lack of device engagement due to a large outflow tract distally or proximally (>38 mm); 1 patient was excluded due to concern about muscle bundles in the RVOT, which we thought might hinder advancement of the S3; and the final excluded patient consented to treatment, but did not receive the device due to pregnancy. The RVOT measurements of patients who did receive the Alterra device, including the minimum and maximum distal dimension

at device engagement, will be available at the time of the presentation. All 15 implantations of Alterra preStent and S3 were successful.

Conclusions: In this EFS of a novel device designed to allow transcatheter pulmonic valve replacement into larger RVOT anatomy, a multimodality screening process allowed identification of suitable candidates who underwent successful Alterra and S3 implant. All implants were successful.

122. CURRENT AND FUTURE APPLICATION OF INTERVENTIONAL CMR IN CONGENITAL HEART DISEASE - RESULTS OF AN ONLINE SURVEY.

Surendranath Veeram Reddy¹, Peter Ewert², Kanishka Ratnayaka³, Henry Halperin⁴, Jennifer Gotto⁵, Tarique Hussain¹, Gerald Greil¹, Paul J. A. Borm⁶

¹UT Southwestern Medical Center, Dallas, USA. ²German Heart Center (DHM), Munich, Germany. ³Rady Children's Hospital, San Diego, USA. ⁴John Hopkins Medical Institution, Baltimore, USA. ⁵B Braun Interventional Systems, Bethlehem, USA. ⁶Nano4Imaging, GmbH, Dusseldorf, Germany

Background: Although first use of cardiovascular magnetic resonance imaging (CMR) for interventional procedures in congenital heart disease (CHD) dates back to 2003, current use is mainly diagnostic, such as for accurate pressure/flow measurement in pulmonary hypertension and various forms of CHD.

Objectives: The first objective of the current worldwide survey was to describe current use of CMR in CHD and to further understand future use and application of interventional and diagnostic CMR by current and interested users. A second objective was to make an inventory of the main impediments that apply to interventional cardiovascular magnetic resonance imaging (iCMR) and the instrumental needs for further progression of the field.

Methods: The online survey was sent by email to all physician members of PICS-AICS, CCISC and SCMR community in December of 2018 and answers were gathered until March 5th 2019. All qualifying respondents were pediatric/adult congenital heart disease providers. A total of 188 responses were obtained, and a sub-group of 112 responders completed all questions, including 102 academic and 10 non-academic centers. Apart from 14 centers that are already active, 72 centers (55%) indicated that they are interested and want to start iCMR procedures at their centers in the near future. The major problems they envisage, or encounter are infrastructure (26%), lack of medical devices (18%), training (13%) and lack of key people on the team

(12%). Hands-on training and workshops are mentioned as the prime needs to get started, while medical devices are a good third. The wish list of needed devices is headed by guidewires (1), introducer sets (2), steerable catheters (3), balloon catheters (4) and biopptome (5). Current diagnostic procedures are mostly in pulmonary hypertension (n=11), post heart transplant (n=8) and post- and pre-Fontan procedures (n=8). Remarkably, those interested to start (completed by 56 responders) reported that their iCMR focus to be on single-ventricle patients (n=40) followed by coarctation (33), pulmonary hypertension (n=33) and TOF/RV-PA surgical reconstruction (n=29).

Conclusion: Pediatric and adult congenital interventional cardiologists are aware of and interested to start iCMR procedures and have a clear idea of what clinical indications can be handled now and in the near future with availability of much needed MRI compatible transcatheter devices. It is also apparent from the survey results that there is a need for additional hands on workshops, training and MR compatible devices, in that order.

123. PRACTICE VARIATION IN TRANSCATHETER ATRIAL SEPTAL DEFECT DEVICE CLOSURE: FACTORS INFLUENCING LOWER RADIATION EXPOSURE

Lauren Shirley¹, Brian Boe², Susan Foerster³, Todd Gudausky³, David Harrison¹, Nicola Maschietto¹, George Nicholson⁴, Brian Quinn¹, Sara Trucco⁵, Wendy Whiteside⁶, Lisa Bergersen¹

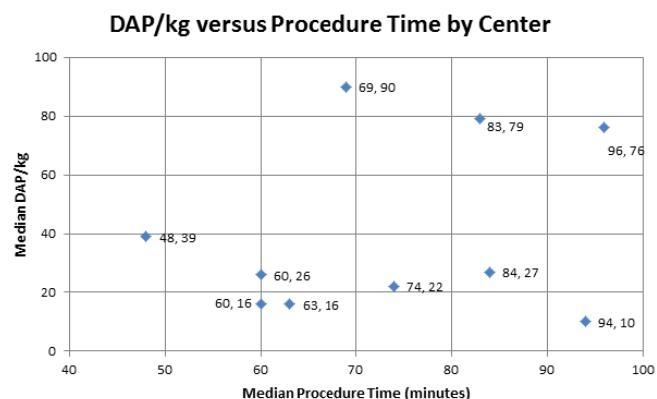
¹Boston Children's Hospital, Boston, USA. ²Nationwide Children's Hospital, Columbus, USA. ³Children's Hospital of Wisconsin, Milwaukee, USA. ⁴Monroe Carell Jr. Children's Hospital at Vanderbilt University Medical Center, Nashville, USA. ⁵Children's Hospital of Pittsburgh of UPMC, Pittsburgh, USA. ⁶University of Michigan Medical School, Ann Arbor, USA

Background: Transcatheter atrial septal defect (ASD) closure is a common congenital cardiac catheterization procedure subject to practice variation among different centers and providers, which introduces potential for variation in patient radiation exposure. This study sought to identify practice variation during transcatheter ASD closure related to differences in radiation dose using data from the multi-center registry Congenital Cardiac Catheterization Project on Outcomes (C3PO).

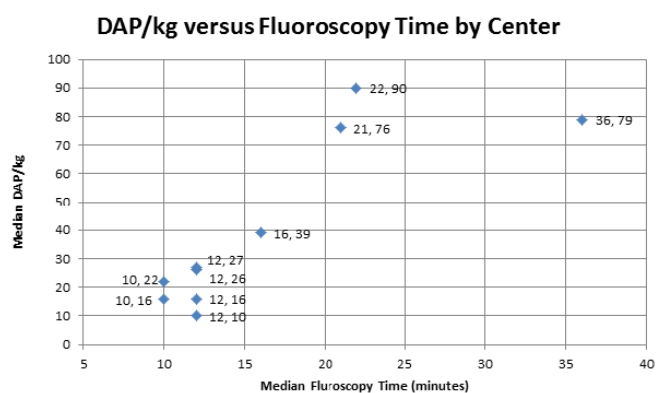
Methods: Data were recorded prospectively from 10 C3PO institutions over a two-year period. Patients noted to have had transcatheter ASD closure with complete data capture were included in this study. Cohort data included clinical and procedural information as well as radiation exposure, fluoroscopy time, procedure time, ASD procedural efficacy

data, and adverse events (AE) classified by severity on a five-level scale by previously established criteria. Radiation exposure was reported as median dose area product per kilogram (DAP/kg) ($\mu\text{Gy}\cdot\text{M}^2/\text{kg}$) by center. Lower-radiation centers were classified as having median radiation dose less than or equal to 40 DAP/kg and higher-radiation centers were designated as having median radiation doses greater than 40 DAP/kg based on empiric methods and expert opinion.

Results: A total of 421 transcatheter ASD closures from 10 centers were recorded between 1/1/2014 and 12/31/2015. The median and IQR for age was 6 years [4, 13] with a median weight of 21 kg [15, 49]. A single ASD was present in 88% of cases and 78% were successfully closed with the first device attempted. ASD sizes ranged up to 43 mm with a median diameter of 11 mm [8, 15]. An AMPLATZER® Septal Occluder was used as the initial closure device in 247 (62%) of defects, GORE® HELEX® Septal Occluder in 103 (26%), GORE® Septal Occluder in 39 (10%) and AMPLATZER Cribiform in 11 (3%). Lower-radiation centers (n=7) had a



123. Figure 1.



123. Figure 2.

median radiation dose of 20 DAP/kg [11, 43] while among the remaining centers (n=3) median radiation dose was 79 DAP/kg [47, 149]. The lower exposure group had a shorter median procedure time (66 min [48, 94] versus 87 min [67, 123]) and median fluoroscopy time (13 min [9, 18] versus 23 min [16, 41]). Percentage of cases with a fellow present did not differ between groups, 83% and 84%. Median ASD size was similar, 11 [8, 16] and 11 [9, 15]. High severity AE (level 3, 4 or 5) were recorded in 5.2% (n=22) of cases, with no mortality and a higher rate of AE among the higher-radiation group (9% versus 3%).

Conclusions: Differences in median radiation dose by center exist and are associated with differences in procedure and fluoroscopy time between lower- and higher-radiation centers, suggesting potential to modify practices during transcatheter ASD closure to decrease patient radiation exposure.

124. OVER-EXPANSION OF RIGHT VENTRICLE TO PULMONARY ARTERY CONDUITS DURING TRANSCATHETER PULMONARY VALVE PLACEMENT

Dana Boucek¹, Athar Qureshi², Varun Aggarwal², Michelle Riley¹, Joyce Johnson³, Robert Gray¹, Mary Hunt Martin¹

¹University of Utah/Primary Children's Hospital, Salt Lake City, USA. ²Texas Children's Hospital, Houston, USA. ³Ann and Robert H. Lurie Children's Hospital of Chicago, Chicago, USA

Objectives: To determine the safety and feasibility of over-expansion of right ventricle to pulmonary artery conduits (RV-PA) during transcatheter pulmonary valve placement (TPVR).

Background: TPVR has become an accepted alternative to surgical pulmonary valve replacement. Traditionally, it was thought to be unsafe to expand a conduit to >110% of its original size.

Methods: This is a retrospective cohort study from two centers of patients with RV-PA conduits who underwent attempted TPVR using the Medtronic Melody Valve from 2010-2017. Demographic data, procedural success, and complications were compared between control and over-dilation (expanded to >110% original conduit size) groups.

Results: A total of 172 patients (51 over-dilation and 121 control) had attempted TPVR with a success rate of 98% in both groups. The over-dilation group was younger (11.2 vs 16.7 years, $p < 0.001$) and smaller (32.8 vs. 57.8 kg, $p < 0.001$) with smaller original conduit diameters (15 vs. 22 mm, $P < 0.001$), however, the final valve size was

no different between groups (19.7 over-dilation vs. 20.2 mm control, $P = 0.2$). Procedural complications were more frequent in the over-dilation (18%) compared to the control (7%) groups (nearly all were able to be successfully addressed during the procedure). Only one patient from each group required urgent surgical intervention. There was no mortality in either group.

Conclusions: Over-expansion of RV-PA conduits during TPVR can be safely and effectively performed. Procedural complications are more frequent with RV-PA conduit over-dilation, but there was no difference in the rate of life-threatening complications. The long term outcomes of TPVR with conduit over-expansion requires further study.

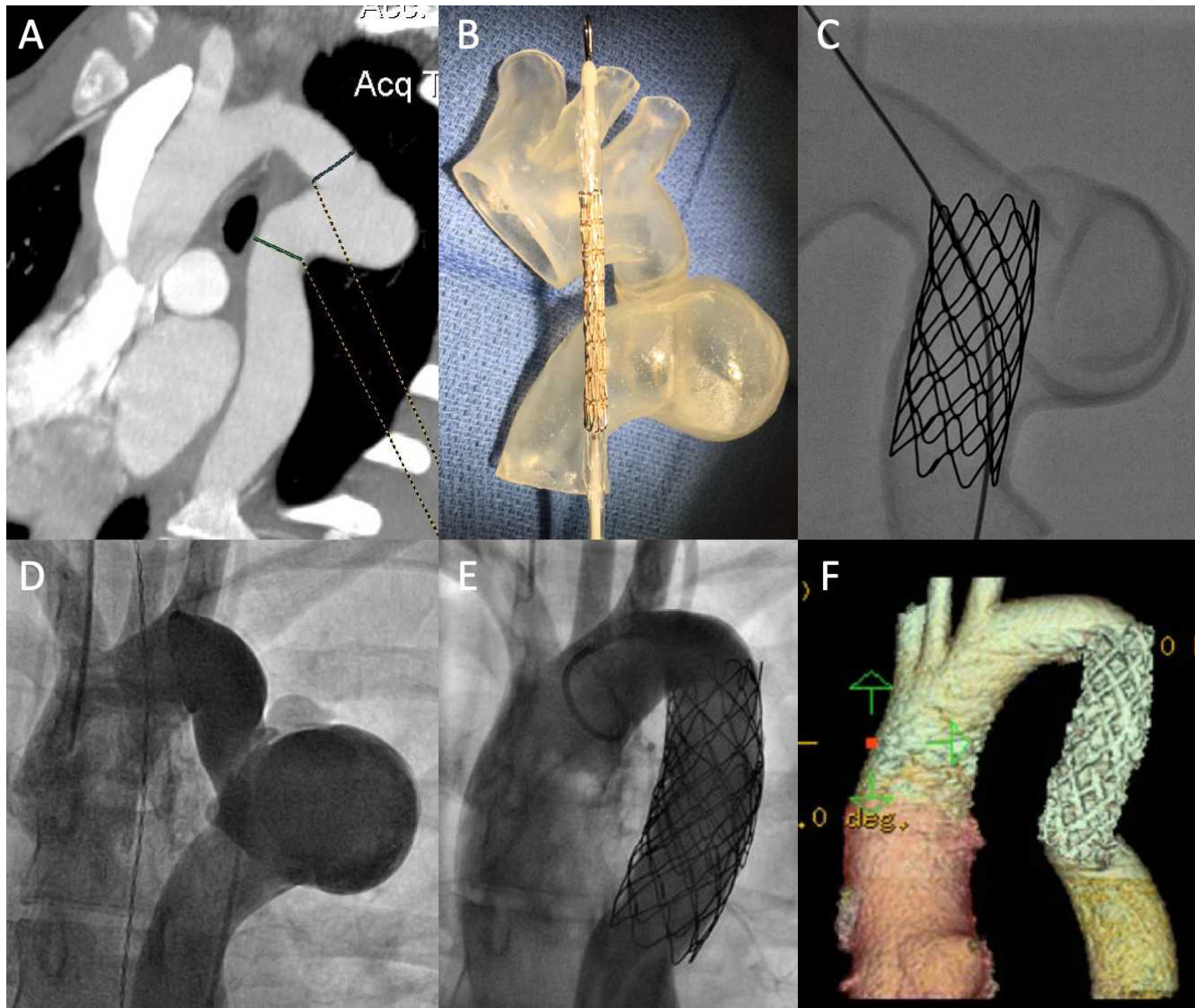
125. ENDOVASCULAR TREATMENT OF COMPLEX AORTIC ANEURYSM – PRE-PROCEDURAL USE OF 3D PRINTED MODEL

Rachel Taylor, Thomas Forbes, Daisuke Kobayashi

Children's Hospital of Michigan, Detroit, USA

Introduction: Pre-procedural planning is crucial for complex transcatheter intervention. Three-dimensional printed model is an emerging modality for congenital and structural heart disease. We report a pediatric case of native complex aortic aneurysm. Pre-procedural planning and case simulation was performed using the life-sized 3D printed model. Transcatheter covered stent placement was successfully performed.

Case: A 17-year old girl was found to have aortic aneurysm on echocardiography from a heart murmur evaluation. Chest computed tomography with contrast showed a large complex aneurysm of the proximal descending aorta (**Figure 1A**). This complex lesion appeared to take a very tortuous course with stenosis component. The largest diameter of aneurysm measured 33 x 37 mm. The feasibility of transcatheter therapeutic option was discussed but deemed challenging due to its complex anatomy. The life-sized 3D Printed Model (**Figure 1B**) was used to help understanding of the anatomy. Furthermore, the model was used for procedural case simulation (**Figure 1C**). After these exercise, she was taken to the catheterization laboratory and underwent endovascular treatment of this complex aortic lesion. There was 20 mmHg of systolic pressure gradient across the aortic lesion, consistent with coarctation component. Angiography showed a very large and tortuous complex aortic aneurysm (**Figure 1D**). Using a 14-Fr Flexor sheath, two covered stents (45 mm NuMed Covered CP stents) were delivered serially by 18 and 20 mm x 5 cm BIB balloon catheters during right ventricular pacing. Further stent dilation was performed by 22 mm



125. Figure 1.

x 3 cm Z-Med II balloon catheter. Post-stent angiography showed a satisfactory position of stents with exclusion of aortic aneurysm (**Figure 1E**). At 4-year follow-up, she has been doing well without re-intervention. Chest computed tomography showed a well reconstructed descending aorta without aortic wall injury (**Figure 1F**).

Conclusion: This case demonstrates the use of 3D printed model for complex endovascular approach in the case of complicated aortic aneurysm. The life-sized 3D model was useful for the discussion among the multi-disciplinary group, pre-procedural planning, and family/patient counseling.

126. TRANSCATHETER VALVE REPLACEMENT IN PATIENTS WITH CARCINOID HEART DISEASE

Iman Naimi¹, Jamil Aboulhosn², Nathaniel Taggart³, Susan Foerster⁴, Mary Hunt Martin⁵, Thomas Jones¹, Brian Morray¹

¹Seattle Children's Hospital, Seattle, USA. ²UCLA Medical Center, Los Angeles, USA. ³The Mayo Clinic, Rochester, USA. ⁴Children's Hospital of Wisconsin, Milwaukee, USA. ⁵Primary Children's Hospital, Salt Lake City, USA

Background: Carcinoid tumors are rare neuroendocrine tumors that primarily involve the gastrointestinal tract. A third of patients develop carcinoid syndrome and 40-50% of patients with carcinoid syndrome develop carcinoid heart disease (CHD) characterized by development of

fibrous plaques and endocardial thickening primarily of the right-sided heart valves. In advanced CHD, surgical valve replacement may be required. There are limited data on transcatheter valve replacement (TVR) in patients with CHD.

Objective: This study describes the performance of TVR within native or surgically implanted valves in patients with CHD.

Methods: Multicenter, retrospective study CHD patients who underwent TVR in any position between Jan 2007-Feb 2018. Results are presented as median (interquartile range) or mean. Continuous variables were compared using paired t-test.

Results: Ten patients (6 female) were included from five centers. Median age at TVR was 63.5 years (IQR 59.8-68.5 years), and median weight was 76.5 kg (IQR 61.3-82 kg). All patients were treated with a somatostatin analogue prior to the procedure. Seven patients had undergone prior surgical pulmonary valve replacement (PVR). Median time from surgical PVR to transcatheter (TC) intervention was 2.5 years (1.8-4.5 years). Moderate to severe pulmonary regurgitation was present in 8 patients. Ten patients had undergone prior surgical tricuspid valve replacement. Median time from surgical tricuspid valve replacement to TC intervention was 3.3 years (2.1-4.3 years). Seven patients had significant tricuspid valve stenosis (mean inflow gradient 6 mmHg [IQR 5-7.4]) and 4 had moderate to severe regurgitation. All patients underwent successful TVR (7 Melody, 3 Sapien) in the pulmonary position (3 native, 1 homograft, 6 bioprosthetic). Peak-to-peak catheter gradient decreased from 22.5 mmHg (IQR 8.5-36.50) to 4 mmHg (IQR 2-10.3) ($P = 0.01$). Four patients also underwent successful tricuspid TVR (2 Melody, 2 Sapien) within surgical bioprosthetic valves. All pulmonary and tricuspid TVR were performed during the same procedure. There were no procedural deaths. On follow-up, five patients were alive (time from implant to death 1.3 years [IQR 0.3-4.1]) with median ($n=10$) follow-up of 2.5 years (IQR 0.5-5). All patients had trivial to mild pulmonary valve stenosis (peak gradient 16.5 mmHg [IQR 5.2-28] compared to 28 mmHg [21-63] ($p=0.03$) pre-procedure) with no more than mild pulmonary valve regurgitation. No patient had more than mild tricuspid valve insufficiency following tricuspid TVR. The median tricuspid inflow gradient at follow-up was 2.5 mmHg (IQR 1.8-3.3) compared to 6 mmHg (IQR 5.8-6.8) ($P=0.01$) pre-procedure. There were no valve re-interventions prior to death or at the time of most recent follow up.

Discussion: There is limited data on durability of surgical or TC bioprosthetic valves in patients with CHD. The results of this small, multicenter study demonstrate that patients required subsequent valve replacement within 2.5 (IQR 1.8-4.5) and 3.3 (IQR 2.1-4.3) years after surgical pulmonary and tricuspid valve replacement, respectively. Successful TVR was performed with maintenance of valvar function at up to 6 years post procedure (median 2.5 [IQR 0.5-5]). Although additional data and longer follow-up are needed, these results suggest that TVR can be performed safely in these high surgical risk patients.

127. EARLY PULMONARY HYPERTENSION AFFECTING CARDIAC INTERVENTION IN PATIENTS WITH TRISOMY 18

Robert Petersen¹, Beth Price², Renuka Peterson¹

¹Saint Louis University, St. Louis, USA. ²SSM Health Cardinal Glennon Children's Hospital, St. Louis, USA

Introduction: Pulmonary hypertension (PH) associated with congenital heart disease (CHD) increases the risk of morbidity and mortality in pediatric patients. In the subset of patients with chromosomal disorders, including trisomies, studies have shown early development of severe PH which plays a significant role in the management of these patients and which can lead to premature death. This study introduces a series of cases in which pediatric patients with trisomy 18 were diagnosed with severe PH earlier than is expected for their degree of CHD, which has thus guided their management and precluded some patients from further cardiac intervention.

Methods: A retrospective review was performed initially on eleven patients with Trisomy 18 who presented for cardiac intervention and were suspected of having PH based on bidirectional intracardiac shunting and desaturation. Hemodynamic data were obtained from cardiac catheterization or in the operating room. To measure the degree of PH, parameters such as pulmonary vascular resistance index (PVRI), the ratio of right ventricular pressure to left ventricular pressures (RV/LV), and the ratio of total pulmonary blood flow to total systemic blood flow (Qp/Qs) were compared.

Results: From 2001 to 2018, 22 patients with Trisomy 18 presented to our institution for cardiac intervention. Our eleven cases with significant PH represented 50% of these patients. Heart defects included ventricular septal defect, patent ductus arteriosus, aortic arch hypoplasia, aortic stenosis, double outlet right ventricle, and atrial septal defect. For patients undergoing cardiac catheterization, the median PVRI was 9.2 WU x m² with a range of 2 to 28 WU x m². Reactivity of PH to medical interventions was

evaluated by increase in Qp/Qs or decrease in RV/LV ratio with the addition of supplemental oxygen and/or inhaled nitric oxide (iNO). Only 4 (36%) of the patients showed significant reactivity of PH with either 100% FiO₂ oxygen or iNO. In five of the eleven cases (45%), the severity of PH precluded further cardiac intervention and repair of cardiac defects. Three of these patients were placed on Bosentan and Sildenafil, one was on Sildenafil then transitioned to Tadalafil, but all ultimately died. The six patients with significant reactivity were able to undergo complete repair pulmonary vasodilators post operatively. Of these six patients who were able to undergo complete repair four are currently alive with a median length of survival of 3.9 years old.

Conclusion: The degree of PH is important in determining the management of patients with Trisomy 18 and CHD. A subgroup of these patients appear to have more severe PH at an earlier age than children without Trisomy 18 with comparable congenital heart defects. The severity of the PH and absence of reactivity may limit the ability to offer cardiac intervention in some patients and may contribute to mortality. In the most severe patients of our small series, pulmonary vasodilators did not seem to improve survival. Given the complex decision-making for cardiac intervention in this population of patients, preoperative cardiac catheterization may need to be considered for risk stratification prior to intervention.

128. INITIAL LATINAMERICAN EXPERIENCE WITH THE NEW KONAR-MF OCCLUDER IN CONGENITAL HEART DISEASE

Liliana Ferrin^{1,2}, Jesus Damsky Barboza³, Marcelo Rivarola⁴, Victorio Luccini⁵, Teresa Escudero¹, Fernanda Biancolini³

¹instituto De Cardiologia De Corrientes, Corrientes, Argentina.

²colegio Argentino De Cardioangiologos Intervencionista, Buenos Aires, Argentina. ³hospital De Ninos "Pedro De Elizalde", Buenos Aires, Argentina. ⁴hospital Universitario Austral, Buenos Aires, Argentina. ⁵hospital De Ninos Pedro De Elizalde, Buenos Aires, Argentina

Background: Device closure is now an accepted modality of treatment for cardiac septal defects, patent ductus arteriosus and other non septal defects with well accepted indications. Devices used for these defects have usually not been specifically designed for use in them. The Konar MF occluder is a woven nitinol mesh self center device with two discs joined by an articulated arm which let that the device adapt to any anatomical defect. Our purpose is to assess the feasibility use of this device as well as the short and mid-term results in cardiac diseases and other cardiac

and vascular defects although it has not initially for use in such conditions

Methods: From October 2017, 40 patients from 1 month to 37yr, were treated percutaneously with the MFO device for various conditions. All patients were > 2,5 kg and had clinical defect closure indication. The cardiac diseases were divided in 3 anatomical groups: Ventricular septal defects (VSD) n=27, patent ductus arteriosus (PDA) n=11, and Miscellaneous as OTRVF occlusion n=1, Blalock Taussig shunt n=1 and Total Cavo-pulmonary bypass fenestration n=1. Successful results graduated as none or minimal shunt immediately and 24 hours pos intervention, moderate or large shunt unsuccessful. Follow up at a week, 1 month, 3, 6 and 12 month. A t-test or student test has been used for statistical analysis

Results: Successful occlusion without shunt immediately or till 24 hours was achieved in all but one patient. VSD closure has been performed in 26 of 27 patients. Three patients weighed less than 5 kg and had associated complex congenital heart disease. VSD type were 17 perimembranous and 9 muscular, one of these infundibular subpulmonary VSD was closed by retrograde way. Gerbode type were 4 of them, 3 residual post surgical closure in Tetralogy of Fallot. The average of right waist was 5.07 mm(+1,52), the left waist was 7.07mm(+1,52). Procedures were successful in 26 of 27 pt with trivial or not residual shunt (97%). The failed procedure was in a large muscular VSD but transient AV Block was present.

The patent ductus arteriosus procedures were successful with complete closure immediately. Krischenko type A ductus in 6, type C in 3, D and E 1 pt each one. Anterogradely approach was used in 8 and retrogradely in 3. The OTRVF occlusion has been done in a Tricuspid Atresia with non functional Glenn anastomosis because of antegrade pulmonary flow. A 14-12 mm MFO device was deployed through the Pulmonary Valve with normalized pulmonary pressures after occlusion. There were no complications related to device in any patient in short to mid term follow-up.

Conclusion: It is feasible in patients with cardiac septal and non septal defects, patent ductus arteriosus and other selected defects to treat successfully with the Konar-MF device occluder without significant complication. The low profile allows closure of large defects even in low weight patients. There will be necessary long term follow up to let us know more details

129. UTILIZATION OF 3D RECONSTRUCTION OF CT OVERLAID ON FLUOROSCOPY FOR AORTOPULMONARY COLLATERALS EMBOLIZATION IN COMPLEX ANATOMY

Rahul Singh¹, Zhongyu Li², Ponraj Chinnadurai³, Brian Karahalios¹, Miguel Chavez¹, Stephanie Fuentes¹, John Breinholt⁴, C. Huie Lin²

¹Houston Methodist Hospital, Houston, USA. ²Houston Methodist DeBakey Heart & Vascular, Houston, USA. ³Siemens Medical Solutions USA, Inc., Hoffman Estates, USA. ⁴Memorial Hermann, Houston, USA

Introduction: Pre-procedure cardiac CT overlaid on live 2D fluoroscopy provides real-time guidance for complex cases such as aortopulmonary collateral embolization. 3D regions of interest generated on CT mark collateral takeoffs and nearby landmarks and optimal projection angle can be determined for maximum visualization of collaterals. We present two cases in which we used this tool for embolization of aortopulmonary collaterals.

Case 1: 34 yo F with PDA and Eisenmenger syndrome being treated medically for pulmonary hypertension presented with recurrent hemoptysis. Previous CMR showed large (~1.0 cm) PDA with bi-directional shunting (Qp:Qs = 0.8). CTA showed aortopulmonary collaterals in the anterior and inferior right upper lung lobe with surrounding residual hemorrhage.

In the cath lab, we obtained images from RAO 61 and LAO 30 to perform 2D/3D registration with the CTA, using the spine, a pigtail catheter in the aorta, a wire in the right atrium and the area of pulmonary hemorrhage as landmarks. This enhanced the efficient cannulation and successful embolization of RIMA, LIMA and bronchial artery collaterals.

Case 2: A 35 yo F with a h/o single chamber atrium, heterotaxy (right atrial isomerism) with interrupted IVC and pulmonary hypertension on 5L home oxygen presented with SOB on minimal exertion. Angiography showed Qp:Qs=2.2 and aortopulmonary collaterals from the RIMA, medial surface of the descending thoracic aorta and arch vessels. We decided to embolize the collaterals to prevent perioperative bleeding at the time of transplant.

We obtained images from RAO 1 and LAO 36 to perform 2D/3D registration. The spine, bronchial tree and a catheter coming from the descending aorta to the innominate artery worked as landmarks in X-ray. We embolized the right pectoral, RIMA, LIMA and bronchial artery collaterals.

We obtained closure of the proximal left bronchial artery with a vascular plug.

Discussion: 3D reconstruction of CT overlaid on fluoroscopy is a powerful method to maneuver within complex anatomy and identify optimal fluoroscopic projection for cannulation and embolization of aortopulmonary collaterals potentially reducing contrast and fluoroscopy time. Timely treatment of these collaterals is critical to prevent fatal hemoptysis and operative bleeding.

130. FIRST REPORTED CASE OF CLOSURE OF TYPE III INTRA HEPATIC PORTO-SYSTEMIC SHUNT WITH PORTAL ANEURYSM IN A NEONATE PRESENTED WITH SEVERE PULMONARY HYPERTENSION AND CARDIAC FAILURE

Sudeep Verma, Ananta Ram Gudipati, Gouthami V, Nanda Kishore V

Krishna Institute of Medical Sciences, HYDERABAD, India

INTRODUCTION: Congenital portosystemic shunt is a rare congenital abnormality. We are presenting here a case of persistent pulmonary hypertension (PPHN) and cardiac failure in a 8 days old neonate due to intrahepatic portosystemic shunt with communication between Left hepatic vein and left portal vein through an aneurysm (**Type III Park Portosystemic shunt**). Successful closure of the shunt was done with multiple coils deployed into an aneurysm with improved clinical status.

CASE DETAILS: One day old male late preterm neonate (35 weeks) delivered by caesarean section referred to our neonatal ICU in view of respiratory distress soon after birth. In view of increasing oxygen requirement and chest radiograph showing cardiomegaly with bilateral diffuse lung opacities, baby was intubated and surfactant was administered. Echocardiography showed dilated right ventricle with moderate tricuspid regurgitation and severe pulmonary artery hypertension (PAH) for which baby was started on intravenous Sildenafil infusion. In view of persistent oxygen requirement and PAH with poor response to medical and ventilatory management radiology opinion was taken to rule out secondary causes of PAH beyond heart and lungs. Ultrasound abdomen showed a **Park type 3 congenital intrahepatic portosystemic shunt** through an aneurysm with mild ascites and diffuse subcutaneous oedema. Persistent severe Pulmonary hypertension was attributed to intrahepatic shunt, which is a known complication of the shunt and percutaneous shunt closure was planned in view of deteriorated clinical status. CECT abdomen was acquired prior to shunt closure which confirmed a **tubular vascular channel measuring 4.5 mm**

connecting left branch of portal vein with left hepatic vein through an aneurysm. Liver function test was deranged and serum ammonia level was 175 micromol/litre. Septic profile was negative. In catheterisation lab after securing right internal jugular vein access left hepatic vein injection reconfirmed the diagnosis of intrahepatic portosystemic shunt arising from the summit of the aneurysm. Shunt was crossed with 0.014 PTCA but in spite of repeated attempts microcatheter was unable to track though the aneurysm across shunt into the portal vein. Hence **applying the principal of cerebral aneurysm closure**, portal aneurysm was closed applying basket principal using **multiple V Trek Microplex 18 coils (Terumo Corporation, Japan)**. Proximally the aneurysm connection with hepatic vein was sealed using three **0.035 4-4 Embolization coils (Cook Medical Indiana, USA)**. Developed femoral artery thrombosis after the procedure, treated with heparin infusion for 72 hours followed by LMWH for 10 weeks. Extubated on day four of procedure and off CPAP and oxygen on day 9 of procedure. Repeated echocardiography revealed normal PA pressure and preserved cardiac function. Discharged in a stable condition and 6 months follow up showed asymptomatic status with normal liver function and no evidence of pulmonary hypertension

Conclusion: This case highlights the importance of need to look beyond the heart and lung for persistent PAH and cardiomegaly. Intrahepatic portosystemic shunt is a rare congenital anomaly with type 3 being the rarest type reported in literature. **This is probably the only reported case for Type III portosystemic shunt which was diagnosed and treated in a neonatal period.**

131. EFFECT OF AIRWAY TYPE ON DIFFERENCES IN MEASURED VS LAFARGE VO₂ FOR PATIENTS IN THE PEDIATRIC CATHETERIZATION LABORATORY

Kari Erickson, Kathryn Soule, Gurumurthy Hiremath

University of Minnesota Masonic Children's Hospital, Minneapolis, USA

Background: Consumed oxygen (VO₂) is a critical component of determining cardiac index in pediatric patients during heart catheterization. Traditionally, VO₂ has been obtained from LaFarge tables that list standardized measurements of VO₂ obtained from awake patients aged 3 to 29 years. There are considerable differences between VO₂ estimations in these tables compared to actual measurements in sedated pediatric patients with congenital heart disease in multiple studies. This study sought to further examine the role of airway type in determining differences between measured and LaFarge VO₂.

Methods: 224 consecutive patients for whom VO₂ could be measured in our catheterization laboratory had measured VO₂ values compared with assumed VO₂ using the LaFarge method. Patients were not randomly assigned airway types. Correlational coefficients and Bland Altman plots were used to compare and to obtain baseline differences for measured vs assumed VO₂ for all patients. Correlational coefficients, Bland Altman plots, and one way ANOVA were also used to compare measured vs assumed VO₂ and to evaluate VO₂ differences in all patients in 3 airway sub groups: 1) native airway; 2) laryngeal-mask airway (LMA); and 3) endotracheal tube airway (ETT).

Results: Ages of patients ranged from 4.8 months to 34 years with a mean age of 9.8 years. There were 102 male and 122 female patients. There were 141 patients in the intubated airway group, 39 patients in the LMA group, and 44 patients in the native airway group. There were no significant differences in patient mean age, weight, height, or sex between airway types. By Pearson's correlational coefficients, and Bland Altman plots, this data confirmed previous work showing on average the LaFarge method statistically significantly overestimated VO₂ by 12% for all patients ($p < 0.001$). When these differences were further analyzed by airway type, all three groups showed statistically significant differences between assumed and measured VO₂ ($p < 0.005$). None of the airway groups had significant correlations between LaFarge and measured VO₂. Correlations between LaFarge and measured VO₂ were as follows: intubated patients $r^2 = 0.4$, native airway patients $r^2 = 0.2$, and LMA patients $r^2 = 0.1$. A one-way ANOVA with post hoc Tukey test revealed that the difference between measured and assumed VO₂ was less, although still significant, in patients with an ETT airway (5.2 ± 2.3 ml/min/m², $p = .016$) compared to an LMA airway (18 ± 3.6 ml/min/m², $p = .691$), or a native airway (13.8 ± 3.6 ml/min/m², $p = .138$).

Conclusions: While patients with an ETT airway may have shown a smaller difference between assumed and measured VO₂, the difference is still significant. The significant differences in LaFarge compared to measured VO₂ is not dependent on airway type. The small effect size for airway type and unequal number of patients in the three airway groups warrants further study with a larger sample size. This data further supports using measured VO₂ for patients in the cath lab in order to obtain the most accurate VO₂ for hemodynamic calculations regardless of their airway status.

132. HYBRID TRANSCATHETER AORTIC VALVE REPLACEMENT IN A 3-YEAR OLD WITH COMPLEX CONGENITAL HEART DISEASE

Juan Samayoa^{1,2}, Adil Husain^{1,2}, Dongngan Truong^{1,2}, Mary Hunt Martin^{1,2}, Robert Gray^{1,2}

¹University of Utah, Salt Lake City, USA. ²Primary Childrens Hospital, Salt Lake City, USA

Background: Transcatheter aortic valve replacement (TAVR), has revolutionized the treatment of aortic stenosis (AS), offering a less invasive alternative to surgery. The use of TAVR is rapidly extending to lower-risk patients expected to have longer survival, yet minimal data exist regarding its use in pediatric patients with congenital heart disease (CHD). TAVR is uniquely attractive for CHD patients, as most have increased surgical risks and are likely to require multiple future operations. This case report describes successful TAVR via a hybrid, trans-aortic approach in the setting of a young child with complex CHD requiring aortic valve replacement.

Case Presentation: A 3-year-old male with double outlet right ventricle, d-malposed great arteries, bicuspid pulmonary valve with valvar and sub-valvar pulmonary stenosis, and a large ventricular septal defect (VSD) initially underwent modified Blalock-Taussig shunt as a neonate, followed by an arterial switch operation, VSD closure and tricuspid valvotomy at 7 months old. Secondary to progressive mitral regurgitation (MR) and neo-AS, he underwent a third open-heart surgery with mitral and neo-aortic valvotomy at 10 months of age. He developed progressive neo-AS and underwent a balloon valvuloplasty at 2 years of age. In the year following balloon valvuloplasty, he developed severe neo-aortic insufficiency (AI), moderate neo-AS (mean gradient 33mmHg), and moderate-severe MR. Given his underlying complex CHD and three prior open-heart operations, he was deemed high risk for surgical aortic valve replacement, therefore a TAVR approach was considered. A CT scan demonstrated favorable anatomy for TAVR, with a neo-aortic valve annular area of 299mm², suitable for a 20mm SAPIEN 3 valve. Given his small size and inadequate vascular access, a hybrid approach was planned. In the cardiac catheterization lab, following median sternotomy, a suitable access site was located on the transverse aortic arch just proximal to the origin of the innominate artery allowing for sufficient distance between the access site and valve landing zone. A 20mm SAPIEN 3 valve was advanced to the neo-aortic annulus and deployed during rapid RV pacing. Post deployment angiography demonstrated appropriate valve position, no significant valvar or para-valvar AI, and normal flow through bilateral coronary arteries. His chest was closed in the catheterization lab and

the patient was extubated several hours later. He was discharged home 5 days after the procedure. At 6-month follow-up, he remains asymptomatic, with increased energy levels. Echocardiography shows trace AI, mild AS (mean gradient 15mmHg), and mild MR.

Conclusion: To our knowledge, this is the first report of TAVR performed in a young child with complex biventricular CHD. An alternative access approach via hybrid trans-aortic access to the aorta allows for TAVR in smaller patients with inadequate peripheral access. TAVR may be a reasonable alternative to surgical valve replacement in select pediatric patients, however long-term follow up remains paramount.

133. PROGRESSIVE AORTIC ROOT DILATATION MAY INDUCE FRUSTRATION OF THE FORAMEN OVALE; A CASE REPORT OF ANKYLOSING SPONDYLITIS PRESENTED WITH CRYPTOGENIC STROKE

Sahar Elshedoudy, Eman Eldokla, Reem Rashed

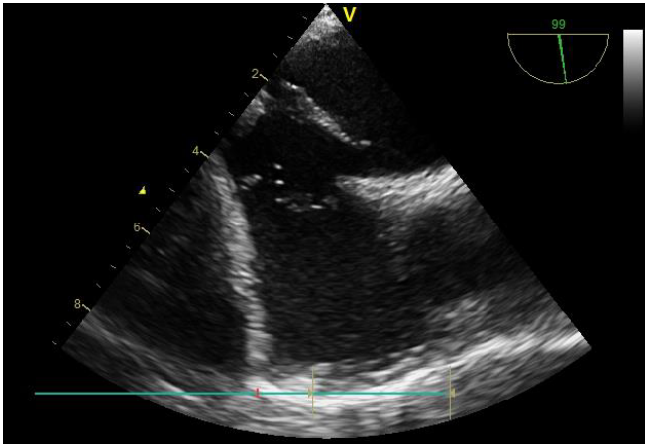
Tanta university, Tanta, Egypt

Introduction: PFO is a remnant of the fetal circulation, right to left shunt across it can be associated with different pathological conditions. PFO pathogenicity is possibly exacerbated by the dilated aortic root by increasing atrial septal mobility and potentiation of PFO shunting.⁽¹⁻⁴⁾

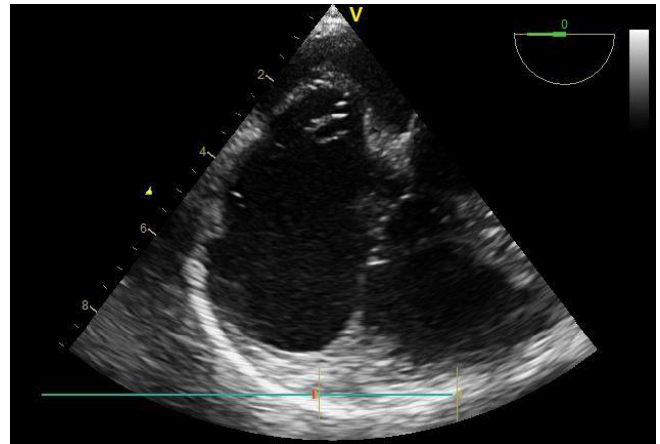
Case Presentation: A 33 year old female complaining of chronic back pain, was diagnosed as ankylosing spondylitis. Her first transthoracic echocardiography (TTE) 7 years ago, revealed mild aortic root dilation. She missed the follow up, then presented 2 months ago with cryptogenic stroke. TTE revealed dilated aortic root = 45 mm, with aneurysmal bouncing of inter-atrial septum. TEE revealed an inter-atrial septal aneurysm, PFO with right to left shunt by color Doppler confirmed by massive right to left shunt during contrast echocardiography. Associated Very prominent redundant whip like Eustachian valve. TCD confirm the TEE finding and revealed grade IV right to left shunt across the middle cerebral artery denoting huge intracardiac shunt.

The decision was to close PFO percutaneously

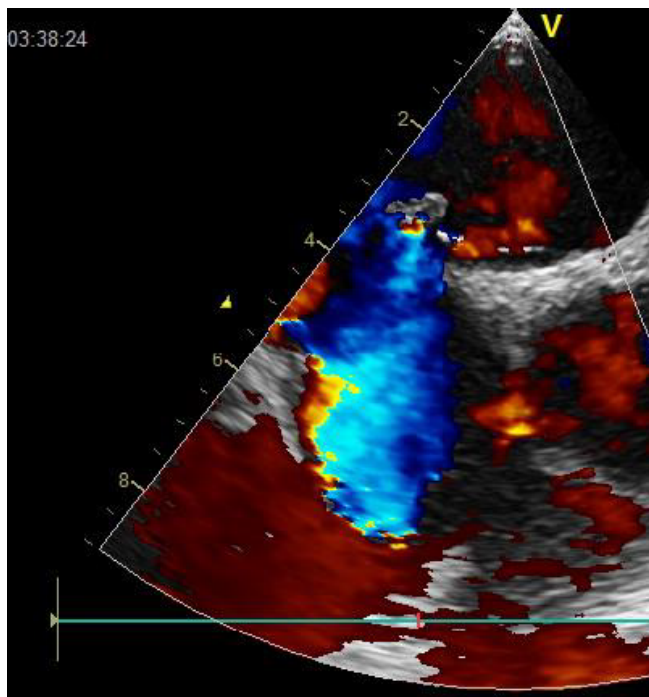
The procedure was done under general anesthesia, with TEE and fluoroscopic guidance. An Occlutech PFO occluder (23/25) was chosen, a 9 Fr long sheath was placed, from the femoral venous approach through the PFO in the left atrium, the implantation technique of PFO have already been described (). From the start the Eustachian valve was captured by a steerable ablation catheter introduced



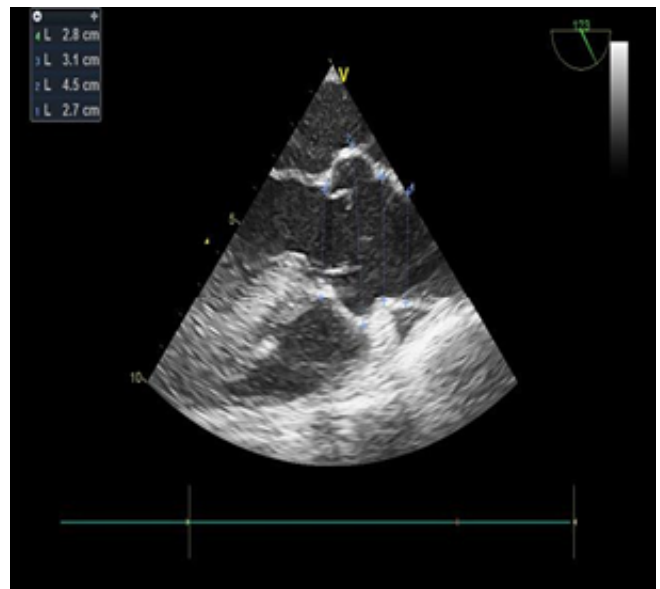133. Figure 1. TEE demonstrates PFO, redundant Eustachian valve.



133. Figure 3. Inter-atrial septal aneurysm.



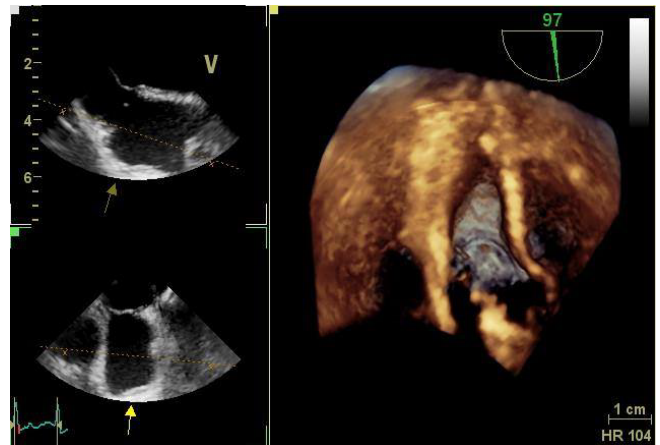
133. Figure 2. Rt. to Lt. shunt through PFO.



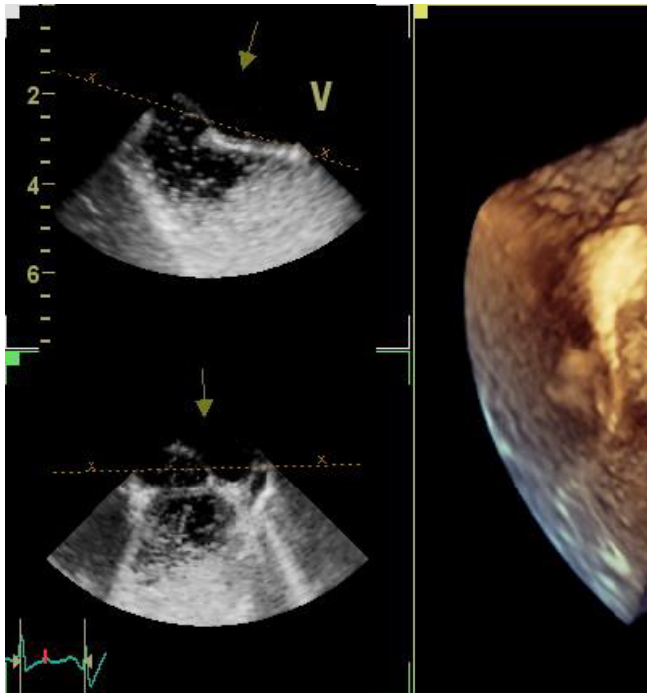
133. Figure 4. Dilated aortic root.

via an extravascular puncture to prevent its interference with the device. The PFO had been closed with no residual shunt and no complications. TCD repeated revealed absence of right to left shunt.

Discussion: Most cases of right to left shunting through a PFO are seen where right atrial pressure exceeds that of the left. But right to left shunt can be observed even if the pressure is equal, it had been reported that dilated ascending aorta may induce floppy aneurysmal septum. So, we suggest that aortic root dilatation may have a role in



133. Figure 5. Three dimensional TEE demonstrates PFO.



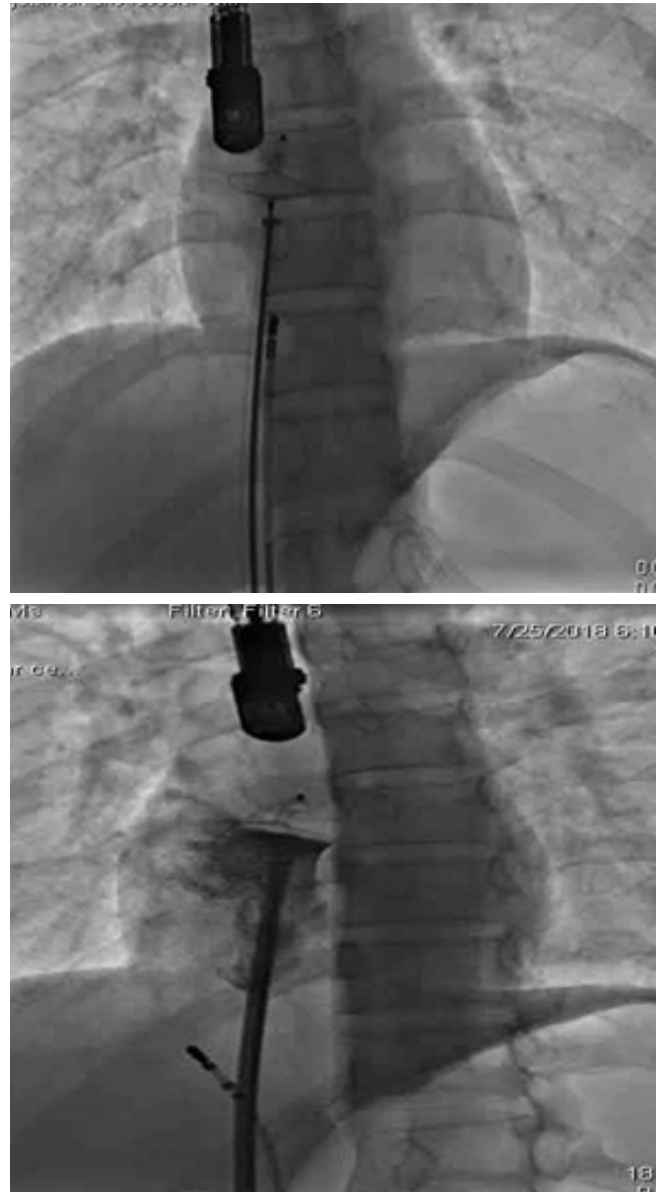
133. Figure 6. Massive Rt to Lt.shunt (agitated saline).

potentiation of right to left shunt across PFO by a mechanical effect on the inter atrial septum.

Conclusion: Aortic root dilatation may induce pathogenic PFO.

References:

1. Eicher J-C, Bonniaud P, Baudouin N, et al. Hypoxaemia associated with an enlarged aortic root. *Heart* 2005; 91:1030–1035: 10.1136.
2. Chopard R, Meneveau N. Right-to-left atrial shunting associated with aortic root aneurysm. *Heart, Lung and Circulation* 2013; 22:71–75.
3. Keenan NG, Brochet E, Juliard JM, et al. *Archives of Cardiovascular Disease* (2012) 105, 13—17.
4. Bertaux G, Eicher JC, Petit A, . Anatomic interaction between the aortic root and the atrial septum: a prospective echocardiographic study. *J Am Soc Echocardiography*. 2007; 20(4):409-414.
5. Carvalho M, Almeida J, Rocha G, Braz E, Urbano J, S. Platypnea-Orthodeoxia Syndrome With Atrial Septal Defect and Ectatic Aortic Root: *J Med Cases*. 2016;7(2):54-57 54-57



133. Figure 7. PFO device and steerable catheter. injection before release.

134. OUTCOMES FOLLOWING TRANSCATHETER CLOSURE OF PATENT DUCTUS ARTERIOSUS IN SMALL INFANTS: A FOCUS ON THE FATE OF DEVICE-RELATED LEFT PULMONARY ARTERY STENOSIS AND AORTIC COARCTATION

Catherine E Tomasulo, Matthew J Gillespie, David Munson, Taylor Demkin, Michael L O'Byrne, Yoav Dori, Jonathan J Rome, Andrew C Glatz

Children's Hospital of Philadelphia, Philadelphia, USA

Background: Surgical ligation was previously the traditional method of patent ductus arteriosus (PDA) closure in small infants, but recent studies have demonstrated successful transcatheter PDA closure to be equivalent in safety and efficacy, without the morbidities of surgical ligation. Early and midterm complications of transcatheter closure in this patient population have been reported, including left pulmonary artery (LPA) stenosis and coarctation of the aorta. The longer-term outcomes of PDA closure in this population, including whether LPA stenosis and aortic coarctation caused by the device persist or improve with time/growth have not been evaluated.

Methods: This is a single-center retrospective cohort study including all patients who underwent transcatheter PDA closure at weight ≤ 4 kg between February 2007 and September 2018. Patients with significant co-existing congenital heart disease were excluded. Patient and procedural characteristics were collected, as well as the long-term outcomes and complications, with a focus on post-procedural LPA and aortic obstruction.

Results: Forty-four patients were included. Median birth-weight, gestational age, and procedural weight and age were 0.89kg (0.49-3.25), 27.1 weeks (23-40), 2.8kg (1.2-4.0), and 2.9 months (0.5-6.6), respectively. Thirty patients underwent transcatheter PDA closure with an AVP2, ten with an ADOII-AS, three with an ADO1 and one with an AVP filled with three coils. All devices were placed using an antegrade approach. Arterial access was obtained in 26/44 patients, though in only 3/17 patients since 2017. Complete PDA closure occurred in all thirty-nine patients assessed with post-procedural echocardiograms at median follow-up 0.7 years (2 days-7 years). Thirty-eight patients had post-procedural echocardiograms assessing flow acceleration in the LPA and descending aorta. Seventeen (45%) had flow acceleration in the LPA, which resolved in seven by last follow-up, five had decreased flow acceleration, with only mild flow acceleration at last follow-up (1.51-2.0m/s), two had unchanged mild flow acceleration (1.8m/s) with only short-term follow-up and three had flow acceleration (1.54, 2.08, 2.5m/s) assessed only on one echocardiogram. Three patients developed mild flow acceleration in the descending aorta (1.75-1.8 m/s), which resolved by last follow-up. Four patients developed mild coarctation (2.3-3.0m/s), which improved in two (1.7, 2.3m/s), and the remaining two had only short-term follow-up. Seven patients developed femoral vascular thromboses and 6/7 resolved with medical therapy. One patient had respiratory decompensation prior to intervention; there were no other procedural complications. There was no procedural mortality or need for PDA related reintervention. 41/44 patients were

admitted to the ICU; seven remain inpatient, nine transferred to another NICU, four died prior to discharge and the other twenty-one had a median discharge time of fifty-one days (5-128) post-procedure. 38/44 patients returned to pre-procedure respiratory support at a median of nine hours (0-339.5). Thirty-one patients are known to be alive at the end of the study, four are followed by an outside cardiologist, three were lost to follow-up, and six had late mortality unrelated to the PDA.

Conclusion: Transcatheter PDA closure in small infants is effective, without significant long-term complications or need for reintervention. LPA and aortic obstruction caused by the device can improve with time/growth.

135. IMPLANTATION OF THE EDWARDS SAPIEN-XT AND S3 VALVE FOR PULMONARY POSITION IN NATIVE LARGE RIGHT VENTRICULAR OUTFLOW TRACT

Alper Guzeltas, Ibrahim Cansaran Tanidir, Murat Sahin

Mehmet Akif Ersoy Thoracic and Cardiovascular Surgery Center, Istanbul, Turkey

Introduction: Transcatheter Pulmonary Valve Replacement (tPVR) into the right ventricular to pulmonary artery conduits is being increasingly performed. But there are few options for patients with native and dilated right ventricular outflow tracts (RVOT). An option for these patients is off label use of Edwards Sapien® valve. We aimed to review the outcomes for the SAPIEN-XT and S3 valves for pulmonary position in patients with dilated and native RVOT.

Method: Between January 2015 and November 2018, totally 80-90 Edwards valve melodioler var tPVR procedures were performed. Among them 48 (%) had native RVOT. Retrospective analysis was performed for all patients to have undergone PPVI using the SAPIEN-XT or S3 valves with native RVOT.

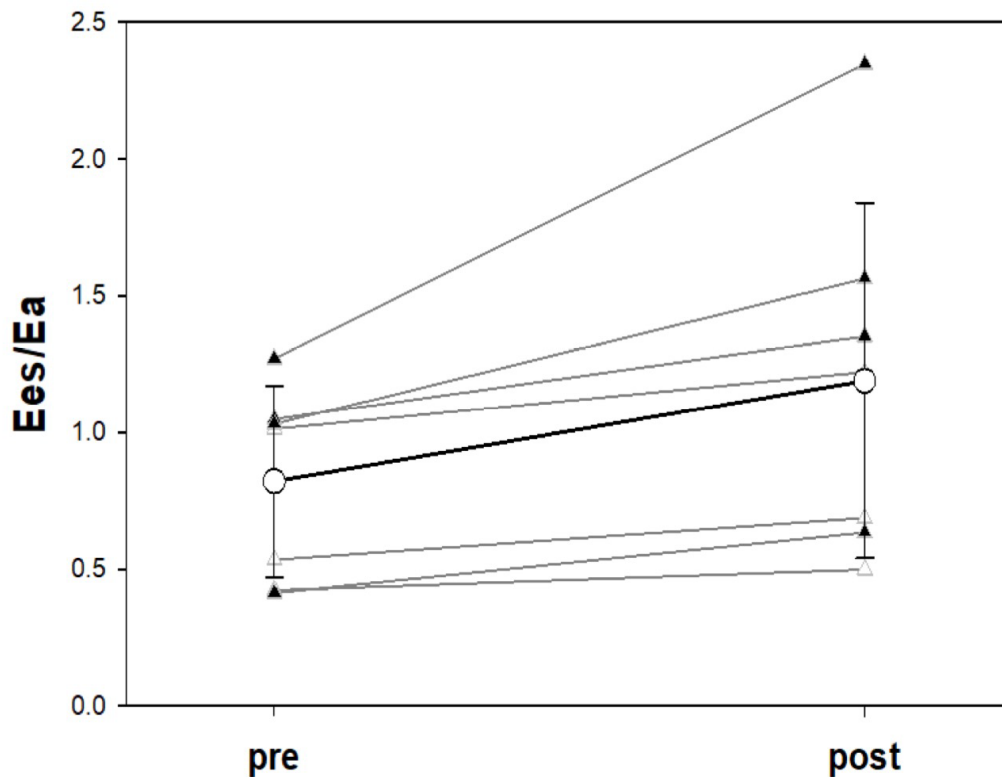
Results: The procedural success was 46/48 (96%). Median age and weight of the remaining patients were 19 (8-46 years) and 56 (22-102) kg, respectively. Primary underlying diagnosis was tetralogy of Fallot (n=40/46). Stenting was performed simultaneously with tPVR in 17/46 (37%) and 5 of them hybrid cases whereas pre-stenting was performed 4 to 14 weeks earlier in 29/46 patients. Before tPVR median antero-posterior and lateral sizes of the stents were 27.5(23-32) mm and 28(21-32) mm, respectively. Valve sizes were XT-26 mm (n=6), XT-29 mm (n=33) and S3-29mm (n= 7). In 27 patients additional 1-5 ml (median 3ml) volume was added to the valves' balloon for stabilization. Five of the patients underwent hybrid procedure. In all hybrid procedures stent and valve implanted in the

136. Table 1. Data directly measured, and derived from right ventricular pressure waveforms, at time of cardiac catheterization for controls (normal and pulmonary arterial hypertension) and patients with pulmonary insufficiency (before and after transcatheter pulmonary valve replacement).

Measured	normal		PAH		PI pre-TPVR		PI post-TPVR	
	MEAN	SD	MEAN	SD	MEAN	SD	MEAN	SD
HR	72	8	77	14	67	12	79	25
CI	3.1	0.9	2.7	0.3	3.4	0.5	4.2	1.3
SVI	43	8	36	5	52	11	55	15
EDP	6.5	2.5	7.6	2.2	11.5*	4.6	10.7	3.3
RVPpeak	28	11	60*	19	34	8	31	7
ESP	18	7	48*	15	26*	7	22♦	6
Pmax	48	22	88*	22	45	15	44	13
Ea	0.42	0.16	1.42*	0.45	0.50	0.14	0.44	0.17
Ees	0.70	0.31	1.21*	0.45	0.37	0.18	0.45	0.18
Ees/Ea	1.65	0.37	0.87*	0.30	0.75*	0.38	1.19♦	0.65

* p-value≤0.05 by ANOVA for normal vs. PAH, normal vs. PI pre-TPVR. ♦ p-value≤0.05 for paired t-test PI-pre vs. PI-post.

136. Figure 1. RV:PA coupling Index (Ees/Ea) before and after transcatheter pulmonary valve replacement for severe pulmonary insufficiency.



same session. Two patients had moderate tricuspid regurgitation related with the procedure. There were no deaths during a median follow-up of 14(2-47) months. Valve function was preserved in all patients during follow-up.

Conclusion: The Edwards SAPIEN-XT and S3 valves may be an alternative method for tPVR in patients with native and dilated RVOT.

136. ASSESSMENT OF RIGHT VENTRICULAR TO PULMONARY ARTERIAL COUPLING DURING TRANSCATHETER PULMONARY VALVE REPLACEMENT

Britton Keeshan, Sofia Charania, Jeremy Asnes, Paul Heerdt
Yale School of Medicine, New Haven, USA

Background: Severe pulmonary insufficiency leads to progressive right ventricular (RV) dilation and dysfunction with optimal timing of transcatheter pulmonary valve replacement (TPVR) remaining unclear. The degree of RV dysfunction, manifest as decreased ejection fraction (RVEF) on cardiac MRI (CMR), has been used to guide decision making. The right ventricular-pulmonary arterial (RV:PA) coupling index is the ratio of contractility/afterload—expressed as load-independent ventricular end-systolic elastance (Ees)/pulmonary arterial elastance (Ea)—and is a comprehensive index of RV adaptation to abnormal loading conditions. RV:PA coupling (Ees/Ea) has been shown to have prognostic significance in patients with pulmonary arterial hypertension (PAH) and recent data suggest that Ees/Ea is impaired in patients who have undergone surgical repair of Tetralogy of Fallot. While Ees/Ea has traditionally been assessed using CMR, novel techniques for measuring Ees/Ea with right ventricular pressure (RVP) waveforms have been reported. We sought to determine how the Ees/Ea was affected by TPVR using RVP tracings before and after successful TPVR.

Methods: Data obtained under IRB-approved protocols from 21 patients was analyzed including: 14 control patients (7 normal and 7 pulmonary arterial hypertension) that had undergone diagnostic right heart catheterization and 7 patients that had undergone CMR followed by TPVR for pulmonic insufficiency. Digital recordings of RVP waveforms were used to determine Ees, Ea, and RV:PA coupling index (Ees/Ea) in controls and patients before and after TPVR. Correlation between Ees/Ea and RVEF from CMR was performed to validate methodology.

Results: Ees/Ea at the time of TPVR was significantly correlated with preoperative RVEF measured by CMR ($r^2=0.84$, $p=0.009$). Data directly measured at time of catheterization are shown in Table 1. Notably, Ees/Ea is decreased at

baseline in patients undergoing TPVR when compared to normal controls. This is similar to patients with PAH despite a peak RV pressure about half that measured in the PAH cohort. TPVR had little overall hemodynamic effect and did not alter Ees and Ea as individual variables. However, following TPVR Ees/Ea tended to increase in all subjects (Figure 1) and this effect was significant.

Conclusions: RV:PA coupling index is impaired in patients with severe pulmonary insufficiency undergoing TPVR relative to normal controls. Immediately following TPVR, there is a significant increase in Ees/Ea despite only modest change in systemic hemodynamics. Further study is needed to determine if assessment of RV:PA coupling index may prove useful in determining optimal timing and efficacy of TPVR in patients with severe pulmonary insufficiency.

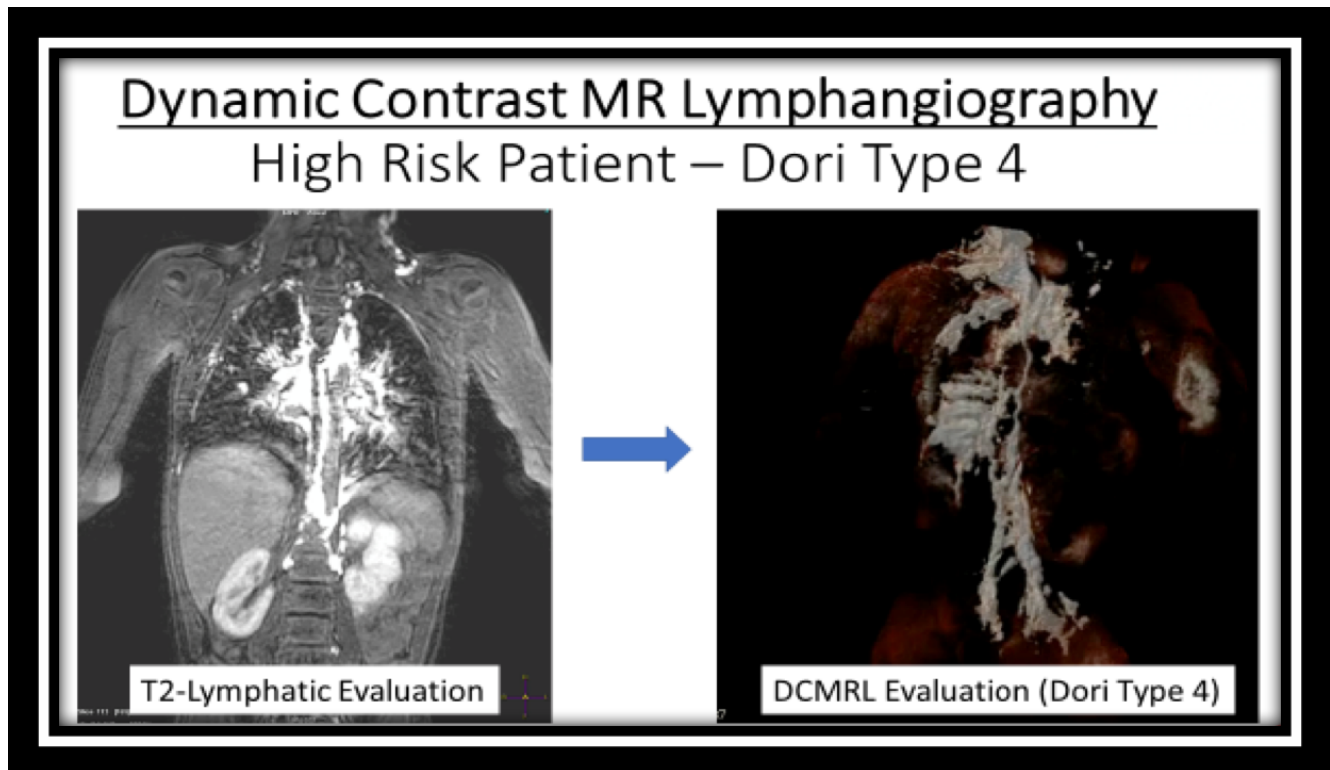
137. LYMPHATIC EVALUATION DURING ICMR PROCEDURES IN SINGLE VENTRICLE PATIENTS

Yousef Arar, Tarique Hussain, Vasu Gooty, Riad Abou Zahr, Sheena Pimpalwar, Jennifer Hernandez, Luis Zabala, Joshua S. Greer, Gerald Greil, Surendranath R. Veeram Reddy
UT Southwestern, Dallas, USA

Background: Lymphatic insufficiency evaluation in the single ventricle (SV) circulation remains an area of increasingly targeted clinical research. Elevated central venous pressures in post-Fontan patients leads to increased liver lymphatic production and impaired lymphatic drainage. This causes significant lymphatic system leak, resulting in numerous complications such as protein losing enteropathy (PLE), chylous effusions, and plastic bronchitis. Recent reports by Dori et al showed that greater MRI-based severity of lymphatic abnormalities (Type 4) in pre-Fontan patients was associated with failure of Fontan completion and a longer postoperative stay.

Objectives: We describe our institutional experience to assess lymphatic burden during real-time interventional cardiac magnetic resonance (iCMR) procedures performed to evaluate pre- and post-Fontan hemodynamics. The grade of lymphatic abnormality was evaluated in all SV patients by T2-weighted MR lymphangiography (T2W-MRL) and an invasive dynamic contrast magnetic resonance lymphangiography (DCMRL) in high risk patients.

Methods: Patients underwent an iCMR procedure using dilute gadolinium-filled balloon-tip catheter with the aid of EmeryGlide guidewire (Nano4Imaging Aachen, Germany) for Glenn/Fontan right heart catheterization (RHC) and left heart catheterization (LHC) under real-time MRI



137. Figure 1. Case examples showing severe lymphatic insufficiency by T2-weighted MR lymphangiography (T2W-MRL, left) and volume rendered dynamic contrast MR lymphangiography (DCMRL, right).

visualization. All patients initially underwent a non-contrast T2W-MRL. High risk patients were subsequently accessed via bilateral inguinal lymph nodes to allow for dilated contrast injection for the DCMRL. Based on lymphatic insufficiency burden, patients were classified into 4 types (Dori subtypes).

Results: T2W-MRL was performed in 16 patients followed by DCMRL in 3 high risk patients. Median age and weight were 6.25 y (range 1-15 y) and 20.0 kg (7.9-35.9 kg), respectively. Of the 16 evaluations, 9 were pre-Fontan and 7 were post-Fontan for PLE and/or cyanosis. Time taken for first pass RHC and LHC/aortic pull back was 4.9 and 2.9 minutes, respectively. Majority of patients were found to have Dori Types 1 and 2 [Type 1: n = 5 (33%); Type 2: n = 4 (27%)]. Three patients in the cohort were deemed high risk based on T2W-MRL imaging with four (27%) categorized as Dori Type 3 and two (13%) categorized as Dori Type 4. 15 patients had acceptable data on the T2W-MRL. Two of the three high risk DCMRL patients subsequently underwent transabdominal puncture to access the thoracic duct for coil/glue embolization.

Conclusions: This iCMR pilot study shows feasibility and safety for performing contrast and non-contrast lymphatic

imaging during routine SV evaluations. Cardiac catheterization of pre- and post-Fontan patients in the MRI suite combines the best of both modalities to obtain more accurate flow, cardiac output, MR-based ventricular function, and catheter-based pressures. In addition, iCMR adds incremental value for the SV population by allowing for lymphatic evaluations that cannot be obtained in the traditional cardiac catheterization laboratory. Using iCMR, the SV lymphatic circulation can be thoroughly studied alongside routine assessments. Further work is needed to optimize lymphatic scanning protocols and clinically correlate lymphatic findings to short and long term patient outcomes.

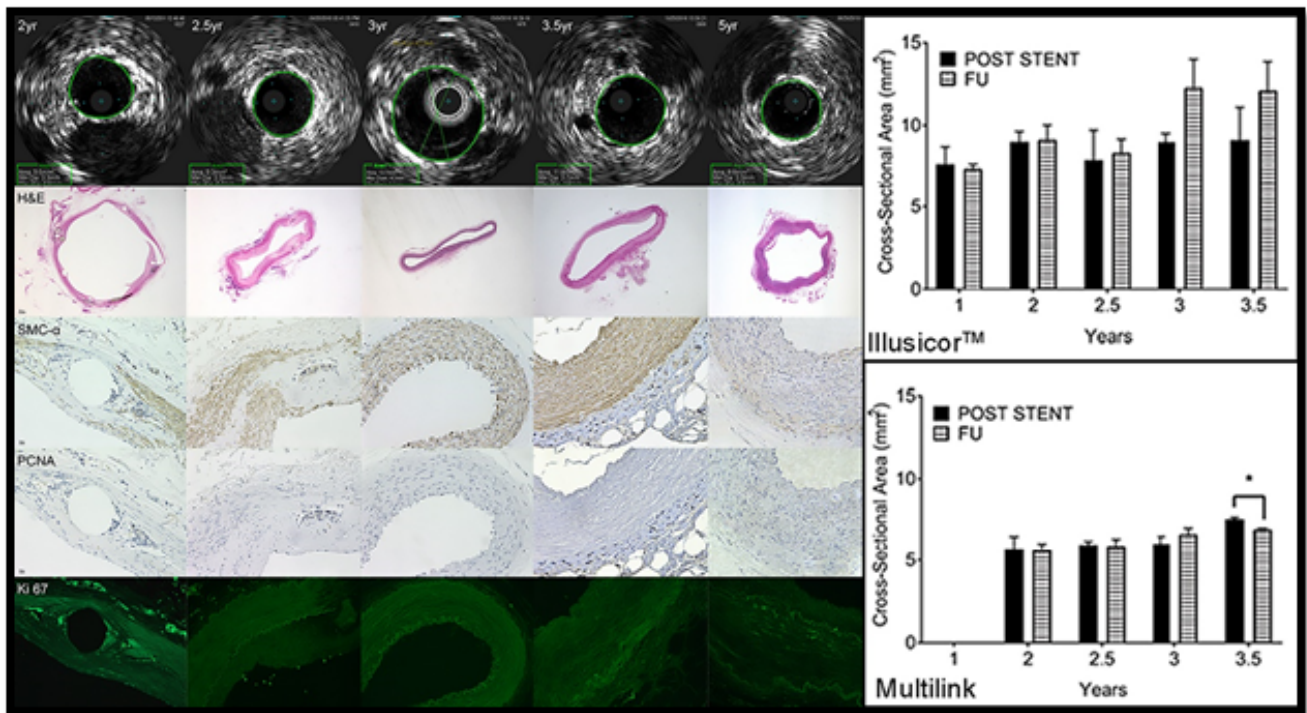
138. LONG TERM DEGRADATION STUDY OF A NOVEL BIORESORBABLE STENT FOR CONGENITAL HEART DISEASE – A 5 YEAR FOLLOW-UP STUDY.

Surendranath R. Veeram Reddy¹, Tre Welch¹, Jian Wang¹, Jamie Wright¹, Annie Nguyen¹, Matthew Riegel², James Richardson¹, Joseph Forbess³, Robert Jaquiss¹, Alan Nugent³
¹UT Southwestern Medical Center, Dallas, USA. ²Kansas University, Lawrence, USA. ³Northwestern University Feinberg School of Medicine/Lurie Childrens, Chicago, USA

Table 1. Rabbit Aorta stented with BDS. A negative Late Lumen Loss indicates vessel growth.

FU (Yr)	Wt (kg)	Stent Size, Diameter x length (mm)	Post Stent Diameter (mm)	Post Stent Area (mm ²)	FU Diameter (mm)	FU Area (mm ²)	Late Loss (mm)
1	3.6	4x19	3.10±0.30	7.66±1.05	3.06±0.16	7.40±0.26	0.033
2	3.9	4x18	3.41±0.18	9.10±0.79	3.26±0.20	8.46±0.41	0.15
2	4.6	4x18	3.36±0.25	8.93±0.57	3.51±0.19	9.83±0.58	-0.15
2.5	4.2	4x18	3.16±0.35	7.90±1.81	3.31±0.28	8.36±0.81	-0.15
3	4.2	4x18	3.45±0.24	9.00±0.51	3.95±0.30	12.30±1.70	-0.5
3.5	4.4	4x18	3.36±0.42	9.13±1.97	3.93±0.30	12.13±1.72	-0.56
3.5	3.9	4x18	3.35±0.35	8.66±1.26	-	-	-
4.5	4.4	4x18	3.80±0.26	-	-	-	-
5	3.8	4x18	3.07±0.15	-	3.53±0.21	9.33±1.01	-0.46

138. Table 1.



138. Figure 1.

Background: Our team has previously published results on short- and mid-term follow up of the novel double opposing helical (DH) design bioresorbable (BRS) in rabbits and porcine aorta and iliac arteries.

Objective: In this study, our aim was to examine the long term degradation over 5years of the DH BRS stent (Illusior™) in a rabbit model.

Methods: Twelve female adult New-Zealand white rabbits were used for longitudinal stent degradation testing. Via a 6 French sheath in the right carotid artery (RCA), all rabbits

underwent DH BRS stent implantation in the descending aorta (DAO) and iliac arteries. Premounted metal stents were placed in contralateral iliac arteries for comparison. Stents were sized and expanded to 110% of native vessel size. The BRS were examined for stent patency, vessel inflammation, stent degradation and late lumen loss at 2years, 2.5years, 3years, 3.5years and 5years following stent implantation. Imaging consisted of angiography and intravascular ultrasound (IVUS) prior to stenting (baseline), immediately post stenting and at subsequent follow up intervals. Long term histological evaluation through different phases of degradation from revascularization, resorption and restoration was examined.

Results: Nine of 12 rabbits (3.6-4.4 kgs) underwent successful stent implantation in the DAO and iliac arteries. 3 animals died during initial stent implantation procedure. All 9 animals following successful stent/s implantation survived to predetermined time points with no evidence of limb ischemia. Angiography and IVUS showed stent/vessel patency, trivial in stent restenosis and no evidence of thrombus. Late lumen loss analysis showed that there is vessel growth in arteries with BRS implantation (Table 1). There was no vessel growth in iliac arteries with metal stents (Table 2). Immunohistological stains, SMC- α , showed integration of smooth muscle cells from 1-5 years of implantation in BRS. Ki-67 staining of the BRS showed the smooth muscle cells being active with proliferation at years 1-2 during the resorption phase but not years 3-5 in the aorta and not after 2.5 years in the iliac vessel during the artery restoration phase. At 2.5 years the BRS was not visible in the aorta shown by surface examination using scanning electron microscopy. At years 3-5 (restoration phase) the BRS disappears showing some granuloma of the arterial vessel with no in-stent restenosis, no thrombus.

Conclusion: Long term results of the novel DH BRS specifically designed for CHD are promising. Overall this BRS has shown on angiograms and IVUS no thrombus formation, no stent migration, no significant in stent stenosis, no dissection, no aneurysm and no clinical events or deaths following successful stent placement. The BRS design demonstrated distinct slow resorption profiles in comparison to other degradable stents. These results indicate the importance of the resorption properties of the device on its vascular compatibility. In this study, this BDS has shown equivalence to metal stent in radial strength and low inflammation throughout the degradation process and ultimately leaving behind a native vessel. These results are consistent with others who have demonstrated the importance of controlling the rate of implant resorption within the initial critical vessel healing period.

139. CUTTING BALLOON ANGIOPLASTY ON BRANCH PULMONARY ARTERY STENOSIS IN CONGENITAL HEART DISEASE

Harrison Cobb^{1,2}, Joshua Daily^{1,2}, Amy Dossey^{1,2}, Michael Angtuaco^{1,2}

¹University of Arkansas for Medical Sciences, Little Rock, Arkansas, USA. ²Arkansas Children's Hospital, Little Rock, Arkansas, USA

Background: Cutting balloon angioplasty has emerged as an alternative therapy for pulmonary artery stenosis resistant to conventional balloon techniques with good short term results, but sparse data on long-term outcomes. We sought to determine if the initial increases in pulmonary arterial diameter following cutting balloon angioplasty are maintained in long-term follow-up.

Methods: This study is a descriptive, retrospective chart review of patients with congenital heart disease who underwent cutting balloon angioplasty for pulmonary artery stenosis at Arkansas Children's Hospital between January 2008 and February 2019. We reviewed patient demographics, cardiac and genetic diagnoses, anthropometrics, details of each catheter-based interventions, as well as 30 day complications. Each pulmonary artery segment which underwent cutting balloon angioplasty was treated individually. Follow-up was ended if the specific segment became atretic, or if the segment underwent an additional intervention surgical or catheter based intervention. Clinical records were reviewed to determine 30-day complications.

Results: Over the period of study, 47 patients underwent pulmonary artery cutting balloon angioplasty and were followed through 133 catheterization cases. Of the 47 patients, 40 underwent repeat catheterization. In total, 150 discrete cutting balloon events were performed on 112 pulmonary artery segments. The average age at initial intervention was 36 months. Average time to end of follow-up was 34 months with a range from zero to 142 months. At the time of initial cutting balloon angioplasty, there was an average immediate increase in minimal vessel diameter of 59%. At the end of follow-up, the average increase in minimal arterial diameter maintained from pre-cutting balloon was 79%. Seventy eight pulmonary artery segments underwent repeat intervention. Seven patients had 30-day complications including 1 death.

Conclusions: In this study reporting the longest follow-up to date of children and adolescents who underwent cutting balloon angioplasty for branch pulmonary artery stenosis, we found that cutting balloon angioplasty was

successful in increasing the minimal luminal diameter with lasting effect and acceptable associated comorbidities.

140. FEMORAL ARTERIAL THROMBOSIS FOLLOWING CARDIAC CATHETERIZATION: A PERFORMANCE IMPROVEMENT PROJECT

Saar Danon, Jennifer Peterson, Mark Redmond, Heather Adame, Christopher Tan

MemorialCare Long Beach Medical Center/Miller Children's and Women's Hospital, Long Beach, USA

Objective: Evaluate the outcome of a performance improvement project aimed to reduce femoral arterial thrombosis related to pediatric cardiac catheterization.

Background: Femoral arterial thrombosis is a common complication of pediatric cardiac catheterization, and rates may be up to 30% in infants less than 1 year of age. Risk factors include weight less than 5 kg, larger sheath French size, increased sheath length, final activated clotting time less than 250 seconds, and need for arterial sheath exchanges. Treatment of femoral arterial thrombosis requires anticoagulation and results in increased hospital length of stay and cost. From January 1, 2016 through June 30, 2017 our program's overall rate of femoral arterial thrombosis in pediatric patients was 12.7%, and 19.5% in patients weighing less than 15 kg. The purpose of this project was to reduce the rate of femoral arterial thrombosis in pediatric cardiac catheterization patients to less than 8%.

Methods: All procedures were performed at MemorialCare Long Beach Medical Center/Miller Children's and Women's Hospital, an academically affiliated adult and children's hospital in Southern California. Pediatric cardiac catheterizations are performed within a 5-room adult cardiac catheterization laboratory with multiple operators. We identified that all cases of femoral arterial thrombosis occurred in patients weighing less than 15 kg, so the target was adjusted to include only this smaller cohort. Procedure details were reviewed and it was found that patients received a variable dose of heparin ranging from 25-100 units/Kg, sheath removal was often deferred until the activated clotting time (ACT) was less than 200 seconds, and distal perfusion during access site compression was not routinely monitored. Three practice changes were incorporated. (1) Intraprocedural initial heparin dose minimum of 50 units/kg in all patients where arterial catheterization was performed. (2) Sheath removal policy was modified to allow sheath removal without an ACT threshold. (3) Pulse oximeter waveform monitoring of distal extremity during catheterization site compression, with hand pressure adjustment to maintain hemostasis while also maintaining

a visible pulse oximeter tracing distal to the access site as an indicator for adequate pulsatile distal perfusion.

Results: Following implementation of these changes in July 2017 through March 2019, there have been no cases of clinically significant femoral arterial thrombosis in patients less than 21 years of age, including all patients weighing less than 15 kg leading to a reduction from 12.7% to 0 ($p = <0.001$). Median initial heparin dose/kg increased from 44 units/kg to 55.1 units/kg ($p = 0.003$), although the peak and final activated clotting times were not significantly different from pre-to post-practice change. However, following these changes, there was a non-statistically significant increase in minor access site bleeding following these practice changes (8.3% to 10.4%), none of which required treatment.

Conclusions: Performance improvement project leading to practice changes resulted in a dramatic decrease in femoral arterial thrombosis following pediatric cardiac catheterization.

141. PULMONARY ARTERIOVENOUS MALFORMATION: A CASE REPORT

Celia Maria Camelo Silva, Nathalie Bravo-Valenzuela, Yan Sasaki, Gustavo Feitosa Santos, Ana Faccinnetto, Wallessa Mota, Wagner Granelli Junior, Juliana Taguchi
UNIFESP, São Paulo, Brazil

Background: Pulmonary arteriovenous malformations (PAVMs) can be spontaneous or be part of a hereditary hemorrhagic telangiectasia (HHT) or Rendu-Osler-Weber disease, which is an autosomic dominant disorder characterized by the development of multiple arteriovenous malformations in either the skin, mucous membranes, and/or visceral organs. The PAVMs may either rupture, and lead to life-threatening hemoptysis/hemothorax or be responsible for a right-to-left shunting leading to paradoxical embolism, causing stroke or cerebral abscess. PAVM diagnosis is mainly based upon transthoracic contrast echocardiography and CT scanner examination. The latter also allows the planification of treatments to adopt, which consists of percutaneous embolization, having replaced surgery in most of the cases.

Case Report: Infant with 10 months of age previously healthy according to parents, had his first respiratory event at such age. He was hospitalized in a general hospital due to pneumonia. After one day, oxygen saturation worsened, and he needed supplemental oxygen. After a week with antibiotic therapy, patient presented clear improvement of respiratory pattern, but without correlative improvement

of saturation, which was maintained around 65% in ambient air.

CT with contrast scanning was performed and revealed PAVMs in the lower and upper lobe of the lung. On 04/17/2019, he underwent coiling of the fistules in the lower lobe and plugging on fistules located in the upper right lobe, lower right lobe and the right middle.

After a percutaneous procedure, the child presented improvement of the symptoms, with oxygen saturation at 90% in ambient air.

Nowadays our patient maintains follow-up with pediatric pneumology, cardiology and neurology teams due to signs of cerebral arteriovenous malformations in angiogramography.

Discussion: Pulmonary arteriovenous malformations are abnormal direct communications between pulmonary arteries and pulmonary veins without interposition of a capillary bed. Approximately 80 to 90% of patients presenting with PAVMs eventually present HHT, whereas the remaining are sporadic cases. Conversely, 15 to 35% of HHT patients will present PAVMs. The PAVM consists of three different anatomical components: one or more than one feeding artery(ies), an aneurismal sac and one or more draining vein. Many infants are only diagnosed after a respiratory event with an odd evolution. TTCE and CT scanning is considered the gold standard diagnosis tool as it provides an easy patient screening, a high anatomical resolution, a precise location and type definition of the PAVM. Furthermore, this tool is useful for percutaneous embolization planification and follow-up. It's important to look for other malformations in other sites such as brain and abdominal. Percutaneous embolotherapy is nowadays preferable in most disease cases. The aim of transcatheter embolization is to occlude all the PAVM feeding arteries by a selective catheterization of pulmonary arteries by using a coaxial system, via a percutaneous femoral approach.

142. AUTOMATED ROBOTIC CONTROL OF VOLUME INTRACARDIAC ECHOCARDIOGRAPHY TO GUIDE CONGENITAL HEART INTERVENTIONS

Zhongyu Li¹, Jarrod Collins², Young-Ho Kim², Neal S. Kleiman³, Ponraj Chinna Durai², Tommaso Mansi², C. Huie Lin^{3,1}

¹Houston Methodist Research Institute, Houston, USA. ²Siemens Medical Solutions USA, Inc., Princeton, USA. ³Houston Methodist Hospital, Houston, USA

Background: Intracardiac echocardiography (ICE) is widely used to guide congenital and structural heart interventions. In contrast to transesophageal echo, ICE does not require general anesthesia and can be performed by the interventionalist. However, manipulation of the ICE catheter can divide the attention of the operator. We report the development of an automated robotic ICE catheter controller with the ability to successfully reobtain three defined views *in vivo* in a porcine model.

Method: A robotic controller was built to control linear translation, axial rotation, and A-P / L-R bending of an Acunav P6 volumetric ICE catheter (Acuson, Mountain View) from joystick or encoded inputs. Initial views of the mitral valve, aortic valve and tricuspid valve were acquired by operator-directed manipulation of the robotic system *in vivo* porcine model and electronically recorded and encoded. The same views were then re-directed by automated robotic manipulation based upon operator manipulation with five trials. Error in robotic reacquisition and reproduction of the same views was evaluated using a normalized cross-correlation similarity metric. Catheter pose and position were also recorded using cone-beam CT and EM tracking.

Result: The similarity metric for incorrect views revealed a mean of 43.4%. Evaluation of the automated-robotic reacquisition of ICE images demonstrated similarity metric of 76.7% for mitral valve view, 88.0% tricuspid valve view and 75.4% aortic valve view. Cone-beam CT revealed minimal differences in catheter pose and position between operator- and automated-robotic control.

Discussion: We report the first successful *in vivo* automated-robotic view-to-view ICE catheter manipulation. Additional work will be required to develop iterative image improvement and stabilization algorithms as well as safety boundaries.

143. MINIMALIST TRANSCATHETER PULMONARY VALVE REPLACEMENT: INITIAL EXPERIENCE

Joseph Venturini, AbdulRahman Dia, Isla McLelland, Daniel Gruenstein, Janet Friant, Diane Weibeler, Jonathan Paul, John Blair, Atman Shah

University of Chicago, Chicago, USA

Background: As more children with congenital heart disease are treated successfully and survive to adulthood, the number of adults requiring percutaneous approaches to their structural heart disease continues to rise. There is increasing demand for transcatheter pulmonary valve replacement (TPVR) techniques. The minimalist approach

(MA) to TAVR with conscious sedation rather than general anesthesia has gained widespread popularity due to its impact on safety, resource utilization, and patient satisfaction. Up to this point, there has not been reported experience with MA TPVR. We are reporting three TPVR cases performed with local anesthesia and conscious sedation.

Methods: This case series is a descriptive report of three consecutive TPVR cases performed at a single institution between September 2018 and May 2019. Cases were identified from a registry of TPVR cases. All MA cases were included. Demographic, comorbid, and procedural characteristics were recorded retrospectively.

Results: All cases were successful. The indications for TPVR were broad, including: prosthetic pulmonic stenosis (PS) in a patient with Tetralogy of Fallot, torrential pulmonic insufficiency and RV dysfunction in a patient with history of pulmonic valvectomy, and severe PS in the setting of carcinoid heart disease. All TPVR were performed with a SAPIEN 3 transcatheter valve (Edwards Lifesciences, Irvine, CA). Conscious sedation was used in all cases with a median dose of 100mcg (IQR 175mcg) of fentanyl and 4mg (IQR 7mg) of midazolam. The interventional cardiologist controlled sedation in all cases. There were no respiratory emergencies or intubations. Median procedure time and hospital length of stay were 119 minutes (IQR 90 min) and 3 days, respectively. We observed a 100% 30-day survival rate.

Conclusions: Our initial experience with MA TPVR in lieu of general anesthesia includes three successful procedures without complication. Further investigation in a larger cohort is needed to ensure safety.

144. CARDIAC PERFORATION IN CATHETER PROCEDURES FOR CONGENITAL HEART DISEASE; A 10 YEAR RETROSPECTIVE OBSERVATIONAL STUDY.

Steven Karayiannis¹, Brian McCrossan¹, Thomas Forbes², David Nykanen³, Daisuke Kobayashi³, Damien Kenny⁴

¹RBHSC, Belfast, United Kingdom. ²Detroit, Detroit, USA.

³Orlando, Orlando, USA. ⁴OLCHC, Dublin, Ireland

Objectives: The aim of this study is to determine the predictors and outcomes of cardiac perforation during catheter procedures (interventional, electrophysiological and diagnostic) in congenital heart disease (CHD).

Background: The continued evolution of cardiac catheterisation has increased the complexity of patients and frequency of high-risk procedures. The Congenital Cardiovascular Interventional Study Consortium (CCISC)

database is a global network of interventionalists with pooled procedural data input from 2007. Data on cardiac perforation in CHD is limited to anecdotal reports and studies of generic catheter-related complications.

Methods: A retrospective, observational study of 45,175 catheterisation procedures was undertaken. Cases were taken from the CCISC registry between 2008 and 2018. Parameters reviewed included patient demographics, procedure-specific data (including indication and type of procedure), as well as management and outcomes of cardiac perforation.

Results: Cardiac perforation occurred in n=58/45,175 cases (0.13%). Death post-perforation occurred in 7/58 (12%). Patients aged less than 1 year, 35/58 (60%), and less than 5 kilograms, 28/58 (48.2%) were most prevalent. Of those patients who died post perforation, 6/7 (85%) weighed <5kg. Intervention at the atrial septum (20/58, 34%) was most common in those cases of perforation (transseptal puncture, balloon septostomy and device procedure). Interventions at the RVOT/PV were also high risk for perforation (11/58, 19%). All those who died, (7/7) underwent procedures at the atrial septum or RVOT/PV. Gender, elective/emergency case-type, trainee-attendance and 'risk-scoring' did not seem to predict perforation. Medical or surgical choice of treatment and transfusion/no transfusion, did not seem to predict outcome post-perforation.

Conclusions: Cardiac perforation is rare. Predicting those patients most at risk can facilitate expedient management. High risk patients can be stratified by demographics including age and weight. Procedures most associated with perforation and subsequent death include intervention at the atrial septum and RVOT/pulmonary valve.

145. CORONARY ARTERY COMPRESSION DURING PERCUTANEOUS PULMONARY VALVE IMPLANTATION: IS IT NECESSARY FOR ALL PATIENTS?

Ahmet Çelebi, İlker Kemal Yücel, Mustafa Orhan Bulut, Emine Hekim Yılmaz

Siyami Ersek Hospital for Cardiology and Cardiovascular Surgery, Istanbul, Turkey

Introduction: Coronary compression (CC) is of particular concern because it may be fatal after transcatheter stent implantation to right ventricular outflow tract (RVOT) and/or pulmonary valve implantation (PPVI). We present our experience with CC during PPVI.

Method: Between 2012-2019, 194 patients underwent catheterization for RVOT stenting and PPVI. Among these

patients 96 had transannular patched large native RVOT without stenosis, 16 had patched native RVOT with stenosis and 82 had conduit dysfunction. In patients with conduits as well as native RVOT with stenosis a Z-Med balloon was used to assess the compression of the coronary arteries with simultaneous coronary angiogram. At the beginning of our experience, in patients with large native RVOT without stenosis also CCT test was performed in 46 patients, after that we have canceled the CCT in these patients.

Results: Mean age and weight of the patients were 15.5 ± 6.3 (5-50) years and 48 ± 16 (16-99) kg, respectively. There were no cases of coronary compression or abnormal coronary artery anatomy in patients with native RVOT with transannular patch (with or without stenosis). Among the patients with conduit dysfunction 16 (19.5%) had abnormal coronary artery anatomy. CCT occurred in five patients (6%) with conduit dysfunction, It involved the left anterior descending coronary artery in three and the right coronary artery in two patients. Four of five patients had abnormal coronary anatomy. In sixteen patients with coronary anomaly four patients had coronary compression after test (25%). Two patients with tetralogy of Fallot and two patients with transposition of the great arteries and one patient with truncus (patient with normal coronary anatomy) demonstrated compression. Conduit types were Contegra (3) and Labcor (2). Median conduit diameter was 16 (13–19) mm at surgical implantation. CCT resolved after deflation the balloon in all cases and patients sent to surgery. In 189 cases PPVI was successfully implanted (Sapien valve in 115 and Melody valve in 74). No patient developed CCT following stent and/or a valve implantation.

Conclusion: Patients with conduit dysfunction and abnormal coronary anatomy tend to be at increased risk of CCT, especially in patients with tetralogy of Fallot or transposition of the great arteries. In patients with transannular patched large native RVOT without stenosis, we believe that CCT is not necessary because the stent can barely be implanted without overexpansion. In addition in patients with transannular patched large native RVOT with stenosis we continue CCT because overexpansion is necessary to relieve the stenosis.

146. PERCUTANEOUS CLOSURE OF AN ANOMALOUS PERSISTENT LEVOATRIAL CARDINAL VEIN PRESENTING WITH SYSTEMIC HYPOXEMIA

Nicholas Ghiloni, Robert Cubeddu, Hans Koop, Hardik Bhansali

Cleveland Clinic Florida, Weston, USA

Background: Persistent levoatrial cardinal veins (LACV) represent an uncommon, yet benign form of partial anomalous pulmonary venous communications (PAPVC) between the left atrium or pulmonary veins and a systemic vein (i.e. the innominate vein). We report here an unusual presentation of severe systemic hypoxemia and profound dyspnea in an elderly patient with recurrent pulmonary venous thromboembolism. After a thorough clinical evaluation, the patient was diagnosed with a large paradoxical right-to-left shunt flow across an LACV that was subsequently closed percutaneously.

Case: An 87 year old male with chronic venous pulmonary thromboembolisms (PTE) was evaluated for severe unexplained systemic hypoxemia and dyspnea with aortic oxygen saturation of 78% on room air. He required continuous use of supplemental oxygen. Pulmonary work up did not reveal causation for his progressive symptoms. Initial TTE with bubbles injected into the left cubital vein (CV) revealed immediate opacification of both atriums. However, follow up TEE with bubbles injected in the right CV was negative for suspected interatrial septal defect. Subsequent contrast gated CT scan revealed a LACV extending between the left innominate vein and left upper pulmonary vein (LUPV). Cardiac catheterization demonstrated no oxygen step-up between the SVC and pulmonary arteries. The mean PA pressure was 26 mmHg. The innominate vein was cannulated and venography confirmed the LACV with right-to-left shunt reversal due to elevated PA pressures from PTE. The LACV was occluded with a 12 mm Amplatzer Vascular Plug II. This resulted in immediate normalization of systemic oxygen saturation to 98% with improvement in the symptoms. The patient no longer needed supplemental oxygen.

Discussion: The overall incidence of anomalous pulmonary venous communications is 0.4-0.7%. Multiple case reports present this incidental finding with signs and symptoms related to the degree of shunting and the presence or absence of other cardiopulmonary disease. Furthermore, hemodynamic abnormalities are not expected until 50% or more of the pulmonary blood flow is redirected to the systemic venous system. Typically these patients live normal asymptomatic lives. There are no guidelines or recommendations for the management of anomalous pulmonary venous communications, but those cases that have required definitive treatment have traditionally undergone surgical correction.

Our patient was an unusual presentation of LACV given that he was asymptomatic from this congenital malformation until his 80s when he subsequently developed

dyspnea. However, he also had significant hypoxemia which contradicts the left to right shunt physiology of usual LACV. In fact, the patient had developed pulmonary arterial hypertension secondary to recurrent pulmonary venous embolism which resulted in increased right atrial pressure that subsequently caused reversal of usual LACV hemodynamic physiology resulting in right-to-left shunt. After percutaneous closure described above, the patient's dyspnea and hypoxemia resolved.

Conclusion: Levoatrial cardinal veins are rare, but in the setting of pulmonary hypertension and elevated right sided pressures, can result in significant right to left shunt reversal with severe systemic hypoxemia. We demonstrated it is safe and effective to close LACV via transcatheter approach compared to traditional surgical approaches.

147. STENT IMPLANTATION FOR AORTIC COARCTATION: THE NEED FOR REINTERVENTIONS ON LONG TERM FOLLOW UP

Ahmet Çelebi, Mustafa Orhan Bulut, İlker Kemal Yücel, Emine Hekim Yılmaz

Siyami Ersek Hospital for Cardiology and Cardiovascular Surgery, Istanbul, Turkey

Introduction: Depending on patient size, transcatheter stent implantation has been the first line treatment option for patients with aortic coarctation (CoA). Nevertheless, reinterventions may be needed on follow-up due to restenosis, stent fracture or aneurysm formation. We presented our experience in patients with CoA who required a reintervention after stent implantation.

Methods: Between 2007 and 2019, 288 patients received a stent implantation for CoA. All patients were followed regularly with echocardiography and multisliced computed tomography. Twenty nine patients, who needed a reintervention upon clinical and laboratory findings, were enrolled. Patients with stenosis and/or with a stent fracture received a bare stent, while we preferred covered stents in those with aneurysm formations.

Results: Mean age and weight at the time of reinterventions were 13.2 ± 5.5 years and 54 ± 19 kg, respectively. The mean time to a reintervention was 60 ± 32 months following the initial procedure. Mean weight of patients at the index procedure was 32 ± 15 kg. All patients had stent restenosis. Stent redilation was sufficient in four patients with in-stent stenosis due to intimal proliferation, while restenting was needed in 25. Of 25 patients, 13 also had a stenosis at the proximal part of stents, while a stent fracture was detected in seven. 16 Andrastents, three bare and

six covered CP stents were used. Covered CP stents were implanted in patients who developed an aneurysm formation after initial CP stent (two covered, 3 bare) implantations. Andrastent implantation to the hypoplastic segment of transverse aortic arch was performed in three. Pressure gradients decreased from 31 ± 11 to 3.3 ± 2.2 mmHg. No procedure related complication occurred. During the median follow-up of 21 months (2-48), only one patient, who had received a covered CP stent due to aneurysm formation, required a reintervention and a third stent was placed.

Conclusion: Transcatheter stent implantation has evolved as an efficient procedure in patients with CoA. Nevertheless, regular screening with noninvasive imaging modalities for potential complications, such as restenoses, stent fractures and aortic wall injuries, is crucial on follow-up. Restenting can be an effective and safe option, when an indication for reintervention arises.

148. TRANSCATHETER CLOSURE OF MULTIPLE ATRIAL SEPTAL DEFECTS

Ahmet Çelebi, İlker Kemal Yücel, Mustafa Orhan Bulut, Emine Hekim Yılmaz, Selma Oktay Ergin

Siyami Ersek Hospital for Cardiology and Cardiovascular Surgery, Istanbul, Turkey

Introduction: Atrial septal defects may be multiple in about 10-15 % of the patients. Several different transcatheter strategies for treatment of multiple interatrial communications have been described.

Method: During the study period, 1310 patients underwent percutaneous ASD closure at our institution. Among these subjects, 119 (9%) had multiple interatrial communications. Mean age of the patients was 14 ± 10 years and mean weight was 38 ± 22 kg. If the tissue separating the defects was < 8 mm, a single device was used. If the distance between the defects was > 8 mm, balloon sizing with compliant balloon was performed to the larger defect and distance between the defects evaluated again. If the distance between defects became < 8 mm, a single device which was identical to the sizing diameter was used. When the tissue separating the defects was still > 8 mm following the sizing procedure, with low pressure balloons balloon septoplasty to the larger defect was performed to be able to use a single device. While Multifenestrated/PFO device was preferred for multiple small defects, multiple device was used for the defects well away from each other.

Results: Device implantation was successfully performed in all 119 patients. While ninety six case was having

2 defects, 23 cases was having 3 defects. 41% of cases was associated with aneurysm of the interatrial septum. Mean diameters of larger and smaller defects were 15.7 ± 4.5 (9-30)mm and 6.3 ± 2 (2-9) mm respectively. Mean distance between defects was 7.4 ± 3.6 (2-14) mm. Stretch diameter obtained by balloon sizing was 19 ± 5.7 (8-34) mm. As their defects were close to each other standard transcatheter ASD closure procedure was performed in 52 cases (43%). In 28 cases, subsequent to balloon sizing defects got closer to each other so single device was able to occlude them. In 26 cases following the septoplasty with low pressure balloons, defects became nearby so occlusion with a single device was possible. While Multifenestrated/PFO device was used in 6 cases, double device was used in 6 cases. One case managed with three devices. Mean diameters of devices were 19.5 ± 5 (8-36) mm. Immediate complete occlusion was achieved in 83 (70%) cases and one year after the procedure minimal residual shunt was detected only in 1% (no: 12) of cases. Among 3 cases in whom device migration was detected, surgical defect closure was performed in one, in the other two cases device was caught with a snare catheter and the procedure was completed with a larger device with the same route. At mean follow-up of 50 ± 32 (2-156) months, no further complications occurred.

Conclusion: When <8 mm of tissue separated the defects, it is advised to use single device, however usage of >1 device should be suggested if the tissue separating the defects was >8 mm. Oversizing the larger defect or septoplasty with low pressure balloons which brings the defects closer reduce the incidence of multiple device usage. Transcatheter closure of multiple interatrial defects is feasible, effective, and safe.

149. CT-GUIDED ENDOVASCULAR REPAIR OF PSEUDOANEURYSM LATE AFTER SURGICAL PALLIATION OF COMPLEX COARCTATION

Zhongyu Li¹, Charudatta S. Bavare², John M. Neill², Michael Reardon^{2,1}, Thomas E. MacGillivray², Ponraj Chinna Durai³, C. Huie Lin^{2,1}

¹Houston Methodist Research Institute, Houston, USA. ²Houston Methodist Hospital, Houston, USA. ³Siemens Medical Solutions USA, Inc., Princeton, USA

Arteriopathy can complicate the course of patients with coarctation of the aorta both early and late after intervention. Certain forms of surgical palliation have been associated with late development of aneurysm and pseudoaneurysm. We report successful advanced-imaging guided re-intervention of coarctation and pseudoaneurysm late after surgical palliation.

Case: A 64-year-old woman presented with episodes of chest pain, hemoptysis, and hypertension and was found to have a 5 cm pseudoaneurysm of the left subclavian artery on chest CTA. She had previously undergone palliation of a severe coarctation with an 18mm Hemashield left subclavian to distal descending thoracic aortic graft approximately 10 years prior, and reported a history of chest pain and hemoptysis for ~ 1.5 years. Prior workup had revealed no occult chest malignancy or infection, but a bicuspid aortic valve without AR or AS. Brain imaging revealed a hypoplastic left posterior circulation and dominant right vertebral artery. True 3D analysis was performed on an Echo Pixel workstation and endovascular strategy devised. Following multidisciplinary review, given the morbid nature of a surgical approach, decision was made to approach the lesion endovascular with a back-up hybrid approach.

Procedure: In the hybrid operating room, two orthogonal fluoroscopic views were obtained to perform 2D/3D fluoro-CT fusion to register and import the pre-operative gated CT. Overlay of the CT images was then used to guide retrograde crossing of the coarc with a Wholley wire which was then snared to form an arterial-arterial loop via right radial access for optimal support. The coarc was then initially treated with a 6mm Mustang balloon to allow retrograde passage of a 16 French Mullins sheath. A 24x6cm covered CP stent was then deployed across the take-off of the left subclavian artery and coarctation by CT-overlay guidance. Left subclavian angiography (via left radial access) demonstrated exclusion of the ostium of the subclavian artery. 28mm and 31mm overlapping Gore C-Tag stent grafts were then deployed to cover from the left carotid and over the distal return site of the prior subclavian graft. Finally, a 16mm Amplatzer Vascular Plug 2 was deployed retrograde from the left radial in the subclavian artery proximal to the thyrocervical trunk to exclude retrograde filling of the pseudoaneurysm after which a surgical left carotid to subclavian bypass was performed to ensure perfusion of the left arm.

Follow-up: One month post-procedure, the patient no longer requires anti-hypertensives and reports normal left arm function and no further chest pain or hemoptysis. Repeat CT imaging demonstrates no opacification of the pseudoaneurysm and no endograft leak.

Conclusion: Import of advanced imaging into the hybrid operating room and cath lab can facilitate complex endovascular interventions by potentially reducing contrast, fluoroscopy, and cineangiography as well as providing 3D context to fluoroscopy. 2D/3D fusion workflow can

expedite this process with reduced x-ray and contrast dose as well as allow iterative re-registration during the procedure.

150. SURGICAL IMPLANTATION OF MELODY™ TRANSCATHETER PULMONARY VALVE IN THE NATIVE PULMONARY VALVE OF A NEONATE

Shireen Mukadam¹, Mehmet Gulecyuz², Dhaval Patel¹, Michel Ilbawi¹

¹Advocate Children's Heart Institute, Oak Lawn, USA. ²Illinois Institute of Pediatric Cardiology, Naperville, USA

Background: Neonatal repair of congenital absence of the pulmonary valve may require placement of a valved conduit or monocusp valve due to severe pulmonary insufficiency. The natural history of these valves often involves future re-intervention and possibly repeat sternotomy for replacement.

Case: We describe the case of a term newborn male with a prenatal diagnosis of absent pulmonary valve and aortopulmonary window. He was emergently intubated within the first two hours of life due to respiratory distress, and was noted to have retrognathia with concern for Pierre Robin sequence. Initial postnatal echocardiogram demonstrated severe stenosis and insufficiency of the pulmonary valve, a large type B patent ductus arteriosus, massive hypertrophy of the right ventricle, and dilated pulmonary arteries and ascending aorta. Microarray revealed 15q11.2 deletion syndrome. He was taken to surgery at 6 days of life, and intraoperatively was found to have nearly absent pulmonary valve except for nubbing of dysplastic residual leaflets. Due to significant pulmonary insufficiency, decision was made to implant a competent pulmonary valve using a Melody™ transcatheter pulmonary valve 20 (Medtronic Inc., Minneapolis, Minnesota). The valve was tested in a saline bath and deployed over a Mustang™ 10mmx30mm PTA Balloon Dilatation catheter (Boston Scientific, Marlborough, MA). The valve was immediately implanted by the surgical team, externally sutured into the right ventricular outflow tract with 5-0 Prolene. The outflow tract was then closed with a CardioCel patch. Intraoperative transesophageal echocardiogram showed a well-functioning Melody™ valve with no significant stenosis or insufficiency. The valve was noted to extend significantly into the body of the right ventricle at that time. His postoperative course was uncomplicated and he was discharged home at one month of age. At two months follow-up, he had developed mild stenosis of the Melody™ valve with moderate valvar and paravalvar regurgitation. By one year of follow-up, there was persistent mild pulmonary stenosis and moderate regurgitation which had not progressed. His

most recent echocardiogram at 14 months of age demonstrated mild Melody™ valve stenosis with estimated peak gradient 28 mmHg, mean gradient 14 mmHg. There was moderate regurgitation which was mostly valvar, with mild paravalvar leak. There was mild right ventricular hypertrophy and a prominent muscle bundle at the right ventricular apex, with qualitatively normal right ventricular systolic function. He has been maintained on daily aspirin, and is an active child who has been demonstrating adequate weight gain. His saturations are 100% on room air. We will likely perform further transcatheter balloon dilation of the valve in the near future.

Conclusion: To our knowledge, this is the first known report of Melody™ valve implantation in the native right ventricular outflow tract (RVOT) of a neonate. This technique may potentiate future transcatheter intervention for ballooning or valve replacement. Primary transcatheter valve placement in the native RVOT may help minimize the need for additional sternotomies in the future, or eventually allow for a catheter-based approach to initial pulmonary valve replacement.

151. LONG-TERM CLINICAL OUTCOMES IN CHILDREN AND ADOLESCENTS WITH TRANSPLANTED RENAL ARTERY STENOSIS

Célia Maria Camelo Silva, Ana Carolina Buso Faccinnetto, Gustavo Rocha Feitosa Santos, Atílio Galhardo, Gabriel Kanhouche, Henry Orellana, Manoela Linhares, Juliana Cristina Taguchi, Yan Sasaki, Wagner Granelli Jr, Walessa Pereira Mota, Nathalie Jeanne Magioli Bravo Valenzuela, João Chaker Saba, Hélio Tedesco, José Medina Pestana, Adriano H. P. Barbosa

Federal University of São Paulo, São Paulo, Brazil

Background: Transplanted renal artery stenosis (TRAS) is the main vascular complication of patients undergoing transplantation and may require surgical or percutaneous intervention (PI). The incidence of TRAS in children and adolescents is between 5-9%.

Objective: To evaluate the long-term effects of PI in children and adolescents with TRAS.

Methods: Retrospective and longitudinal study from a single center. Between January 2007 and December 2014, 38 children and adolescents ≤18 years with suspected of TRAS had been submitted to renal angiography. Two patients had complex stenosis and weren't angioplasted and thus excluded. Of these, 20 had significant stenosis >50% and had went to PI renal stenting at the same procedure (TRAS+), the remain 16 hadn't significant stenosis

≤50% was kept only on medical treatment (TRAS-). Mean follow-up time was 7,6(4-11) years. Primary endpoints combined were death and graft failure and secondary endpoints were clinical and laboratory parameters consisted of: serum creatinine level (Scr), systolic (SBP) and diastolic blood pressure (DBP), all patients underwent to reassessment at one month and one year after arteriography.

Results: Comparing both groups results was observed respectively TRAS+ and TRAS-: the median age 14,75±3,29 vs. 15,5±1, 96 years $p=0,23$, male predominance 11(55%) vs. 15(93,75%) $p=0,010$, mean body mass index 19,17 vs. 19,11 $p=0,95$, mean pre-transplantation dialysis time of 14,85±6,25 vs. 9,93±5,53 months $p=0,01$, prevalent disease that caused the renal transplant was unknown cause 7(35%) vs. 4(25%) $p=0,936$, with an average transplant time by the time 11,3 vs. 14,9 $p=0,67$ months, deceased donor was 20(100%) vs. 13(81,25%) $p=0,043$, organ preservation time 166 vs. 41,6 min $p=0,68$, cold ischemia time 24,92 vs. 21,89 hours $p=0,11$. These population (TRAS+20 vs. TRAS-16), the therapeutic immunosuppression (ISS) scheme was used by 34 patients (94,44%) and it was respectively: TRAS+19(55,88%) vs. TRAS-15(44,11%). One patient from each group didn't use ISS 1(5%) vs. 1(6,25%). The most used ISS scheme was used by 23 patients (67,64%) consisted of tacrolimus, azathioprine and prednisone 14(60,86%) vs. 9(39,13%). Twenty four patients had hypertension (66,67%), each group presented TRAS+(N=20) vs. TRAS-(N=16): 12(60%) vs. 12(75%). All patients were on antihypertensive therapy and the commonly antihypertensive agent used was calcium channel blocker 15(62,5%), it was respectively: 7(46,67%) vs. 8(53,33%). At the follow up TRAS+ and TRAS- respectively found 1 vs. 0 deaths $p=0,495$ and 4 vs. 2 grafts failure $p=0,495$, there wasn't statistically significant difference neither for primary outcomes of death nor graft failure. The Scr pre procedure was 1,68 vs. 1,87 mg/dl $p=0,9601$ and the SBP and DBP was respectively 134 vs. 129 mmHg $p=0,5822$ and 87 vs. 79 mmHg $p=0,1406$ and the secondary outcomes were after 1 month of TRAS+ vs. TRAS- was Scr 1,64 vs. 1,65 mg/dl $p=0,5516$, SBP 126 vs. 130 mmHg $p=0,8024$, DPB 79 vs. 75 mmHg $p=0,3347$ and after 1 year: Scr 1,45 vs. 1,46 mg/dl $p=0,1549$, SBP 128 vs. 118 mmHg ($p=0,1671$) and DPB 80 vs. 76 mmHg $p=0,4689$.

Conclusion: Both groups had similar outcomes either in death and graft failure's. TRAS+ was effective as well as TRAS- in improving Scr and BP levels at 1 month and 1 year. We can speculate that without a PI the TRAS+ patients could have a worse outcome. There is limitations on our study, for being a specific sample, thus new studies are needed.

152. ROUTINE RECOVERY OF INTERSTAGE SINGLE VENTRICLE PATIENTS IN THE CARDIAC INTENSIVE CARE UNIT AFTER CATHETERIZATION: PUTTING ONE CENTER'S STANDARD OF CARE TO THE TEST

Steven Healan, Joe Stidham, Thomas Doyle, George Nicholson, Dana Janssen

Vanderbilt Children's Hospital, Nashville, USA

Background: Single ventricle patients carry high mortality (~12%) between stage I and stage II surgical palliation (interstage period). Due to their relative fragility, interstage patients at our institution who have undergone planned catheterization are routinely admitted to the intensive care unit (ICU) for observation. Prior to 2010, they were usually admitted to the general floor. In this study, we examined whether routine ICU admission improved outcomes, or changed overall length of stay (LOS) or exposure to interventions during admission.

Methods: We conducted a retrospective chart review of 191 interstage patients at our institution who underwent planned catheterization to determine suitability for stage II surgical palliation between 2006-2018. Subjects already admitted to the ICU, those who experienced a catheterization complication, and patients not extubated after catheterization were excluded. Differences between the groups admitted to the ICU and the general floor were analyzed using the Mann-Whitney U and Fisher's exact tests.

Results: Out of 191 patients identified, 134 met inclusion criteria. 101 were admitted to the ICU after catheterization, and 33 to the floor. There was a longer median LOS for patients admitted to the ICU compared with the floor (2 days [1.15-3.0] versus 1 [1.0-1.67], $p=0.04$). Two of 33 patients admitted to the floor required ICU transfer (6.1%), one for sedation to obtain venous access; one for poor perfusion and cyanosis. No patients admitted to the floor required cardiopulmonary resuscitation (CPR) and there were no deaths prior to stage II palliation. A higher percentage of ICU patients received supplemental oxygen (48.8% versus 21.9%, $p=0.01$), and there was a trend toward a higher percentage who had their feeds held (25.7% versus 12.1%, $p=0.08$). There was no difference in age at catheterization (109 days [104-120.9] versus 105 [96.7-123], $p=0.68$), history of necrotizing enterocolitis ($p=0.36$), ECMO requirement after stage I ($p=0.16$), or prior hospital LOS after stage I (43 days [15-171] versus 41 [14-133], $p=0.37$). There was no difference in serum lactic acid at the time of catheterization (0.9 [0.51 - 1.39] versus 0.85 [0.60 - 1.41], $p=0.44$). Patients in the current era (after 2010) were more likely to have received an intervention as part of their catheterization (46% versus 17% prior to 2010, $p=0.016$).

Among patients undergoing diagnostic catheterization without intervention, there was still a trend toward longer LOS with ICU admission compared with the floor (2 days [1.0-2.9] versus 1 [1.0-1.1], $p=0.07$).

Conclusions: Despite similar baseline characteristics, interstage patients have longer LOS when admitted to the ICU for observation versus the general floor after planned catheterization. They may also be exposed to extra interventions such as supplemental oxygen and feeding interruptions. Patients admitted to the floor uncommonly require transfer to the ICU and have no difference in survival to the next surgical palliation. While ICU admission after catheterization may be appropriate for some interstage patients, our findings suggest that routine ICU admission does not provide benefit. Future work will investigate the resource utilization implications of these findings as related to overall cost and ICU bed space availability.

153. DILATED CARDIOMYOPATHY SECONDARY TO MIDDLE AORTIC SYNDROME: PALLIATIVE ENDOVASCULAR TREATMENT. CASE PRESENTATION AND LITERATURE REVIEW

Justo Santiago, Yudisay Molina, Andrea Lozano, Javier Castro, Camilo Espinel

Colombian cardiovascular foundation, Floridablanca, Colombia

Introduction: The medium aortic syndrome or coarctation of the abdominal aorta is a anomaly of idiopathic etiology or secondary to vasculitis of great vessels, characterized by a diffuse narrowing of the distal descending aorta or abdominal aorta (1). There are few reports at an early age and can rarely be presented as dilated cardiomyopathy (2).

Objective: We describe the clinical presentation of dilated cardiomyopathy secondary to aortic obstruction in a large area at the thoraco-abdominal level and the results of the endovascular palliative management.

Clinical Case: Female infant who, from 5 months of age, presented respiratory distress and radiological findings of cardiomegaly in control with diagnosis of dilated cardiomyopathy. At 8 months it was assessed in our institution, determining an ejection fraction of the left ventricle of 18%. And the finding was found to decrease the diameter of the descending and abdominal aorta to 2.6 mm, for which aortic aortic syndrome was suspected; corroborating findings in angiotomography. Initial cerebral natriuretic peptide levels were elevated (2606 pg / ml), showing progressive rise until reaching 4400 pg / ml despite optimal medical treatment. Therefore, it was decided to perform cardiac catheterization and salvage aortic angioplasty.

A peak to peak gradient between Aorta was determined during catheterization Thoracic and Abdominal Aorta of 34 mmHg and the aortogram corroborated the presence of a extensive area (57 mm long) of narrowing in the aorta towards thoraco-abdomen, with a diameter of 2.5 mm and irregular edges, extending to the emergency of the mesenteric arteries.

Rescue angioplasty was performed with balloon 6 x 20 mm. Control angiography showed increase in the contrast column without dissection image or aneurysm. During the clinical control, at 6 months after the procedure, the patient presented improvement clinical and decreased levels of BNP. But the echocardiogram maintained a fraction of low ejection (25%) so a new catheterization was performed, finding an area of stenosis with images suggestive of dissection that were corroborated by ultrasound intravascular. Angioplasty was performed with a 9 mm x 45 mm stent, increasing the narrow area and limit the area of dissection. The subsequent clinical evolution was favorable with greater decrease in the BNP levels and increase in the ejection fraction to 30%.

Conclusion: The present case raises that endovascular treatment is feasible as a measure palliative to achieve recovering cardiac function in a small patient with this pathology.

154. EARLY RESULTS WITH THE VENUS P-VALVE PERCUTANEOUS IMPLANTATION IN NATIVE OUTFLOW TRACTS. A SINGLE CENTER EXPERIENCE

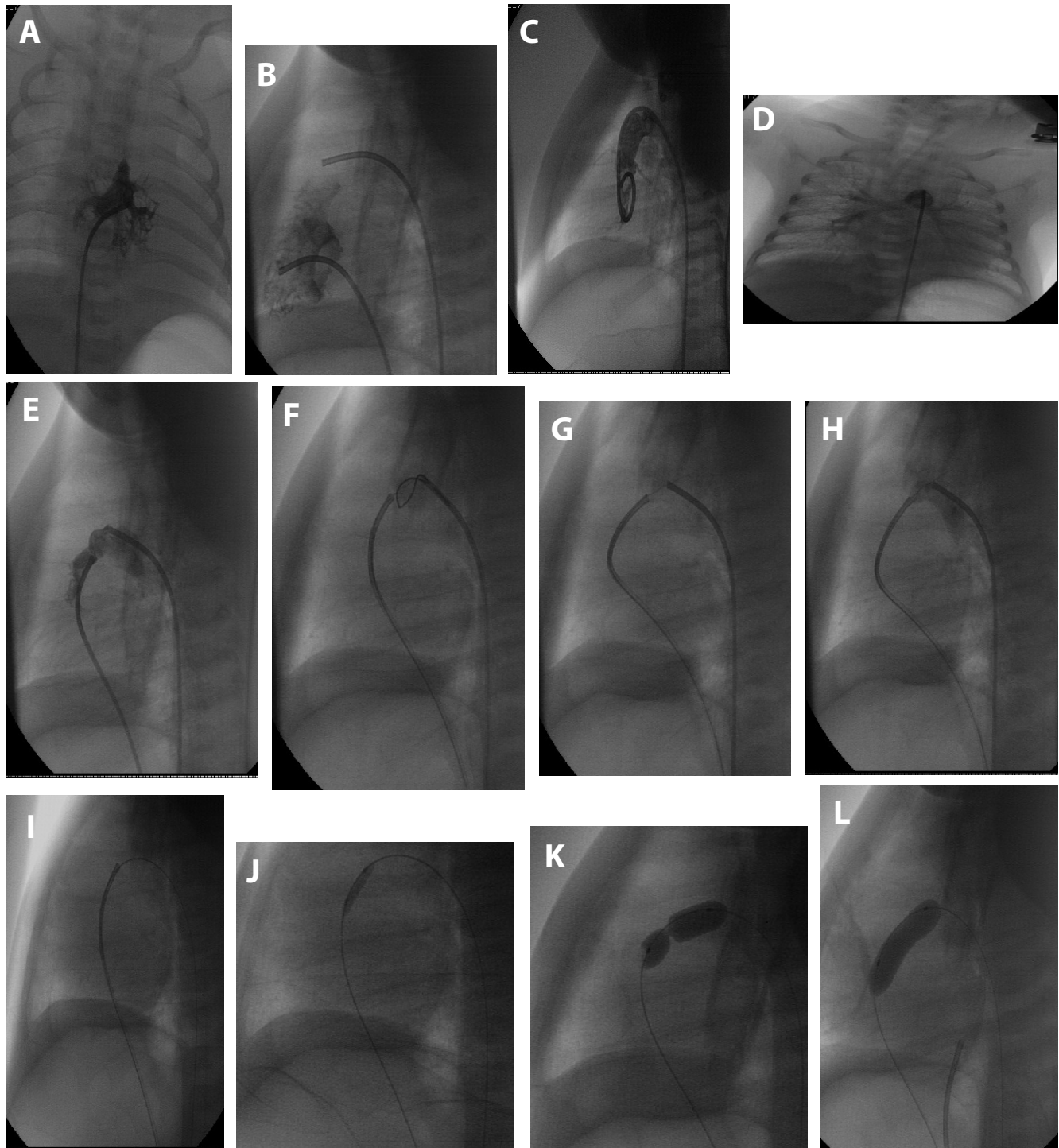
Diego Antoni¹, German Henestrosa², Oscar Mendiz²

¹Hospital Universitario Fundación Favaloro, Buenos Aires, Argentina. ²Hospital Universitario Fundación Favaloro, Buenos Aires, Argentina

Introduction: Chronic pulmonary valve regurgitation is the culprit of mid and long term complications in patients with Tetralogy of Fallot and transannular patch surgical procedure. The Venus p-valve is a self expanding percutaneous heart valve designed to be implanted in a native patched right ventricle outflow tract. The worldwide clinical experience with this valve is just beginning.

We present our initial experience implanting the Venus p-valve in patients with Tetralogy of Fallot and transannular patch repair.

Methods: 10 patients were evaluated and 6 were selected for percutaneous Venus p-valve implantation. 4 women, 2 men. Mean age was 34 years old (23-46), mean weight 57.5 kg (40-75). All were Tetralogy of Fallot with transannular



155. Figure 1. Pulmonary Valve Perforation procedure. *Panel A.* RVA(AP) showing the tripartite right ventricle. *Panel B.* RVA (lateral) showing the tripartite right ventricle. *Panel C.* Aortogram no coronary sinusoids. *Panel D.* Well developed pulmonary artery branches. *Panel E.* Simultaneous injection with one catheter at the end of the ductus and second catheter facing the pulmonary valve dimple demonstrating the site of the membrane. *Panel F.* A 5 mm goose neck snare to give a clear demarcation of its site. *Panel G.* The stiff end of the coronary wire perpendicular on the membrane. *Panel H.* Control hand injection noRVOT perforation. *Panel I.* AV loop. *Panel J.* A coronary balloon inf. *Panel K.* BPV1. *Panel L.* BPV2.

patch with severe pulmonary regurgitation, right ventricle dilation and dysfunction, reduction in their NYHA class, criteria for pulmonary valve replacement.

Results: The implantation procedure was successful in all the patients resulting in an immediately functional valve. One patient had AV block that resolved after 24 hours. 1 valve had an infolding when implanted that resolved with balloon dilation, the valve maintained competent. Short term follow up, mean of 6 month (2-10) resulted in an improvement in NYHA class. Still no pulmonary valve regurgitation, reduction in right ventricle volumes from 150 ml/m² (112-181) to 99 ml/m² (78-119), less impressive reduction in ejection fraction on cardiac magnetic resonance. No stent fractures were observed at 6 months radioscapy.

Conclusion: Percutaneous pulmonary valve replacement with the Venus p-valve was safe and effective in our selected patients during the procedure and short time follow up.

155. TRANSCATHETER PERFORATION OF ATRETIC PULMONARY VALVE BY THE STIFF END OF A CORONARY WIRE IN NEONATES WITH PULMONARY ATRESIA WITH INTACT VENTRICULAR SEPTUM: A SOLUTION IN DEVELOPING COUNTRIES.

Sahar Elshedoudy, eman eldokla, Reem Rashed

Tanta University Hospital, Tanta, Egypt

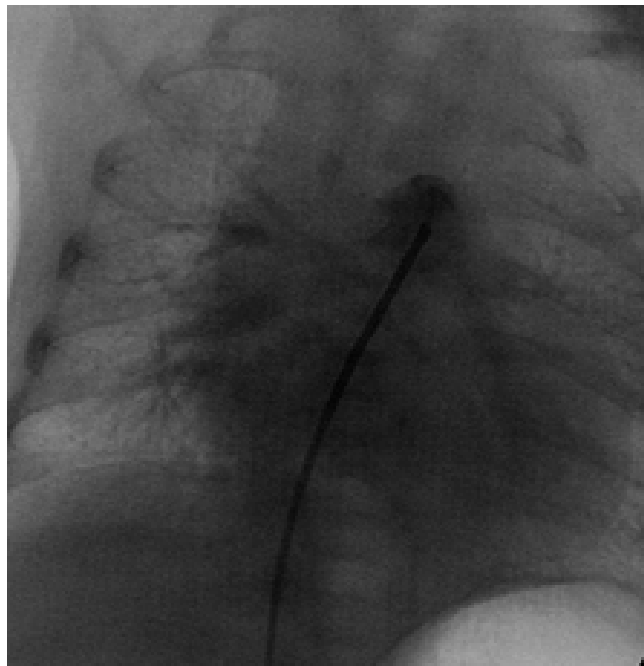
Objectives: To evaluate the safety of using the stiff end of a coronary wire to perforate an atretic pulmonary valve (PV) in patients with pulmonary atresia with intact ventricular septum (PAIVS).

Background: Radiofrequency perforation is an accepted modality to perforate the PV in patients PAIVS. However, the high cost precludes its widespread use.

Patients and methods: This is a single-center experience that spanned from March 2013 to January 2016 and involved 13 neonates who were severely cyanotic with PAIVS and with ductal-dependent pulmonary circulation.

The stiff end of a coronary wire was used to perforate the atretic PV anterogradely, followed by balloon pulmonary valvuloplasty.

Results: The mean age of patients was 3.9 ± 2.7 days and their mean weight was 2.8 ± 0.19 kg. The mean oxygen saturation was $77.1 \pm 3.2\%$. All had membranous pulmonary atresia, with patent infundibulum and tripartite right



155. Figure 2. Controle angio by the end.

ventricle. The valve was successfully perforated in 11 out of 13 patients. Death occurred in two patients (15.4%) owing to heart failure and sepsis. Patent ductus arteriosus stenting was performed 2 days after the procedure in one patient because of cyanosis followed by one and half ventricle repair at of age 5 months. Two patients (15.4%) had one and a half ventricle repair at age of 5 months and 6 months owing to insufficient anterograde pulmonary flow. Two patients (15.4%) underwent second intervention with balloon dilatation of the valve. The remaining seven patients (53.8%) had no further intervention. Two cases (15.4%) had femoral artery thrombosis treated with streptokinase. The mean duration of follow-up was 13.17 ± 7 months. There was significant improvement in the degree of tricuspid incompetence. There was a significant growth in the tricuspid valve annulus during the follow-up (the mean Z score increased from -0.8 ± 0.9 to 0.1 ± 0.9) ($p = 0.003$). There was also a significant increase in the tricuspid valve annulus/mitral valve annulus ratio as its mean increased from 0.73 ± 0.10 to 0.86 ± 0.11 during follow-up ($p < 0.001$).

Conclusion: Perforation of the atretic PV in selected cases with membranous atresia and patent infundibulum using the stiff end of a coronary wire is an effective alternative to using radiofrequency perforation.

156. IMPACT OF PERCUTANEOUS CLOSURE OF ATRIAL SEPTAL DEFECTS ON QUALITY OF LIFE IN ADULTS IN THE UNITED STATES

Mary Heitschmidt

Rush University Medical Center, Chicago, USA

Background: In 2010, 2.4 million people, of which 1.4 million were adults >18 years, were estimated as living with a CDH in the US. The US prevalence of atrial septal defect (ASD), the most common defect in adults, is greater than 100,000. An ASD is a hole between the atria of the heart that allows blood to shunt from the left to the right atrium. Increased pressure in the right side of the heart, increased pressure in the lungs, paradoxical embolisms, arrhythmias, and symptoms of fatigue, dyspnea, palpitations, and recurrent respiratory infections may occur if ASD is left untreated at the second decade of life or later. Percutaneous interventional repair of ASD is increasingly prevalent, as a substitute for surgery, and continues to be a safe and effective procedure since approved by the US Food and Drug Administration in 2001. To determine the effect of cardiac device implantation on a patient's overall life experiences the assessment of quality of life is necessary to help address health care needs and guide care of these patients, however minimal information describing QOL in these patients is available.

Objective: The purpose is to prospectively evaluate changes in health related QOL (HRQOL) and health status in newly diagnosed adult patients with an ASD before and post percutaneous closure of the ASD.

Methods: A longitudinal design was used to measure subjects HRQOL and health status pre-ASD device closure and at 1 and 6 months post closure procedure. A demographic form, Ferrans and Powers QOL Index (QLI) Cardiac IV Version, SF-36v2 Health Survey, and a linear analog scale (LAS) QOL measure were completed.

Results: Sixteen subjects ranged in age from 22-65 years (mean 43.13), 81.3% were white, 75% female, 56% married, and college was the highest education level for 62.5%. Fourteen subjects received the Amplatzer™ Septal Occluder device. SF36v2 determined the following at 6 months: moderate effect size (.36) in *Physical Health Summary* score; increase in all mean sub-scale scores; and a moderate effect size in *Physical Function* (.51), *Bodily Pain* (.40), and *Role-Physical* (.39) subscales but were not significant. LAS scores increased from 72.0 mean + 20.1 pre closure to 78.2 mean + 20.0 at 6 months with a moderate effect size (.31) but were not statistically significant. Overall mean health QLI scores increased at 6 months to 22.05

+ 6.22 from 20.89 + 5.66 pre closure and all sub-scores increased at 6 months except the psych/spiritual social subscale, with a moderate effect size seen in the QLI *Health function* (.29) and the *Family subscale* (.26). All mean QLI scores decreased from 1 to 6 months.

Conclusion: Six months post ASD closure improved HRQOL and health status was found using a general, cardiac specific, and self-rating QOL measures but were not significant due to the small sample. Providers should consider objective assessment of HRQOL to promote optimal care for this population. The need for further research with larger sample sizes is warranted to further determine HRQOL changes in patients who receive interventional ASD closure.

157. VIABAHN VBX STENT IN THE TREATMENT OF VASCULAR STENOSIS IN CHILDREN

John Lozier, Martin Bocks

Rainbow Babies and Children's Hospital, Cleveland, OH, USA

Background: Covered, pre-mounted stents provide an attractive option for the treatment of certain vascular stenoses in children with congenital and acquired heart disease. The ideal stent has yet to be identified, however desirable characteristics of these stents include structural integrity over a wide range of diameters, the ability to 'unzip' safely to allow dilation at higher diameters, low profile for delivery through a small sheath, and PTFE covering to improve safety during high-risk dilations. The Gore® Viabahn® VBX Balloon Expandable Stent (VBX) is approved for adult peripheral vascular disease. We present a series of five children treated with this stent.

Methods: Retrospective chart review was performed in all cases in which VBX stents were used to treat vascular stenoses in our institution. Data collected included patient demographics, indications for using the VBX stents, procedural characteristics, procedural outcomes and limited follow-up. Successful interventions were defined as resolution of a high-risk vascular obstruction, or relief of vascular obstruction with concomitant elimination of an adjacent unwanted vascular communication.

Results: Five children, ages 1.6 to 10.3 years (median 4.2 years) were treated with VBX stents. Four were treated with a single stent and one patient was treated with three stents. Two VBX stents were delivered in stenotic left pulmonary arteries, one in a long-segment aortic coarctation, one in a nearly occluded iliac vein, and three were delivered into a chronically occluded superior vena cava through which

vascular access was needed for a plasmapheresis catheter in a kidney transplant recipient.

VBX stents were chosen over bare metal stents due to concern for the severity of stenosis and risk for vascular injury in four of the cases. In one patient a VBX stent was chosen in order to exclude pulsatile antegrade flow while simultaneously treating LPA stenosis in a Fontan patient. In one patient a VBX stent was implanted within coronary stents which had previously been placed to treat critical neonatal coarctation during emergency resuscitation. After placement of the VBX stent, the coronary stents were safely unzipped with high-pressure balloon dilation.

VBX stents were delivered through 7 or 8 French sheaths in all cases except one, in which it was delivered through a 14 French sheath which had been placed for another procedure. A single complication occurred in the patient with acquired SVC occlusion; the length of stent required to bridge the occluded segment of SVC was underappreciated, resulting in a large right hemothorax. This was treated with the placement of two additional VBX stents, which restored flow through the SVC without residual vascular leak.

Conclusions: We report the successful implant of VBX stents in five children with congenital or acquired vascular stenoses. Relief of obstruction was achieved in all cases, and a single complication occurred. In vitro bench testing of the VBX stent has demonstrated the possibility of opening the side struts and unzipping the stent. The VBX stent is a unique, balloon-expandable covered stent that may hold greater potential for the treatment of vascular stenosis in children.

158. PERCUTANEOUS OCCLUSION OF CORONARY ARTERY FISTULA IN AN INFANT PRESENTING WITH SUDDEN CARDIAC ARREST POST TETRALOGY OF FALLOT REPAIR

Marisha McClean, Konstantin Averin, Darren Freed, Lindsay Ryerson, Andrew Mackie, Cameron Seaman
University of Alberta, Edmonton, Canada

Background: Isolated coronary artery fistulae (CAF) are usually asymptomatic in children. Pre-existing or acquired CAF created by muscle resection may result in inadequate myocardial protection during administration of cardioplegia and subsequent myocardial dysfunction following repair of Tetralogy of Fallot (TOF).

Case Description/Methods: A 7 day old female infant with TOF underwent urgent central shunt for profound

hypoxaemia. An anomalous left anterior descending (LAD) coronary from the right coronary artery (RCA) prohibited neonatal complete repair. TOF repair with transannular patch and right ventricle muscle bundle resection was performed at 6 months and 6.2 kg. Biventricular dysfunction resulted in cardiac arrest 2 hrs post-operatively and required extracorporeal cardiopulmonary resuscitation. Echocardiogram post arrest showed a CAF to the right ventricular outflow tract (RVOT). Cardiac catheterization day 1 post arrest showed an unobstructed left main coronary artery (LMCA), left circumflex (LCx) and RCA ostium giving rise to the LAD. There was a small CAF from the proximal LCx to the RVOT. The RCA was occluded distal to the LAD origin due to compression by the venous extracorporeal membrane oxygenation (ECMO) cannula. Immediately post catheterization, the ECMO cannula position was revised with attempted surgical ligation of the CAF however biventricular dysfunction persisted and she returned to the catheterization laboratory 5 days later due to failure to wean from ECMO.

Results: Femoral venous and arterial access was obtained. Angiography showed persistent LCx CAF, which increased in size with prominent flow into the RVOT and minimal filling of distal LCx. The RCA and LAD were unobstructed. The proximal CAF measured 1.6 mm and narrowed to <0.5 mm. The LMCA was engaged with a 4 Fr RIM catheter; a 0.014" BMW wire and microcatheter were advanced to the distal CAF. The CAF was successfully occluded using 3 x Cook Tornado 0.018" 3-2 mm Embolization Coils with no residual flow and improved distal LCx perfusion. Serial echocardiograms showed normalization of LV function and improved RV function, with successful decannulation day 2 post CAF occlusion.

Conclusion: Hemodynamically significant CAF may result in impaired myocardial perfusion and ventricular dysfunction following cardiac surgery. This case demonstrates the value of invasive CA imaging for an unexplained arrest post cardiac surgery. It also demonstrates that CAF occlusion can be safely and successfully performed in small children, resulting in increased distal coronary perfusion.

159. TRANSCATHETER TRICUSPID/PULMONARY VALVE-IN-VALVE REPLACEMENT: INITIAL EXPERIENCE USING A BRAZILIAN BIOPROSTHESIS

Giolana Mascarenhas da Cunha, Germana Cerqueira Coimbra, Luiz Junya Kajita, Henrique Ribeiro, José Honório Palma, Raul Arrieta
Heart Institute - University of Sao Paulo Medical School, São Paulo, Brazil

159. Table 1. Basal clinical characteristics.

Variables	N=10
Tricuspid	8
Male	62.5% (5)
Age (years)	30, 49 (11, 9-46, 8)
Weight (kg)	63 (26-96)
NYHA III-IV class, n (%)	4 (50%)
Previous interventions ≥ 3 times, n (%)	6 (75%)
Pulmonary	2
Male	100% (2)
Age (years)	19, 7 (16, 8-22, 6)
Weight (kg)	65, 7 (58, 5-73)
NYHA III-IV class, n (%)	0
Previous interventions ≥ 3 times, n (%)	2 (100%)

Introduction: Transcatheter tricuspid and pulmonary valve-in-valve replacement (TTVR and TPVR) has emerged as an alternative to high-risk open-heart surgery for patients with degenerated bioprostheses, who usually

require valve replacement and future reinterventions with high morbidity and mortality. Our aim: present an alternative on *off-label* TTVR and TPVR using a bioprosthesis developed and manufactured in Brazil and demonstrate our initial experience in these positions, since this prosthesis was initially designed for use in aortic position.

Methods:

Case report. The procedures were performed in a hybrid suit. The bioprosthesis used Braile Inovare (Braile Biomedical, Brazil). The valve is a balloon-expandable prosthesis with a lozenge cobalt-chromium frame, 20mm height and a single sheet of bovine pericardium composing the leaflets with diameters: 20 to 28 mm. Vascular access: right jugular vein by dissection and femoral vein; one case required mini-thoracotomy. Pre-dilatation and balloon measurement were performed before implantation of the bioprosthesis. The procedures were guided using 3D transesophageal echocardiography (TEE) and fluoroscopy.

Results

Were performed 10 cases using the Braile Inovare valve: 8 in tricuspid and 2 in pulmonary position. Inclusion criteria:

159. Table 2. Clinical and procedural characteristics.

Individual characteristics				Procedure		Clinical outcomes						
Age	Gender	Weight (kg)	Initial Diagn.	Approach	Valve x Balloon size (mm)	Echo pre	Echo post	Discharge (days)	FC pre	FC post	Followup (days)	
Tricuspid valve in valve												
1	32	M	60	Ebstein Anomaly	RJV	26 / 28	6	3	18	I	I	1162
2	21	M	70	Infective endocarditis (IE)	RJV	26 / 28	12	5	11	II	II	1138
3	42	F	70	Ebstein Anomaly	atrial	28 / 30	9	3	7	III	I	724
4	16	M	50	T4F + tricuspid IE	RJV	28 / 30	9	5	18	III	I	270
5	34	F	59	VSD + tricuspid. Regurgitation	RJV	30 / 30	11	6	10	II	III	741
6	46	F	96	Ebstein Anomaly	RVJ	30 / 30	13	5	8	II	II	417
7	37	M	73	Reumatic fever	RVJ	30 / 30	8	4	18	III	II	574
8	11	M	26	Tricuspid dysplasia	RFV	30 / 30	13	9	16	III	II	705
Pulmonary valve in valve												
1	22	M	58	T4F	RFV/LFV	20 / 22	96	38	20	I	-	-
2	16	M	73	Pulmonar atresia	RFV	20 / 22	48	80	36*	II	II	24

IE: Infective endocarditis; T4F: Fallot Tetralogy; *death of sepsis

tricuspid or pulmonary valve dysfunction of congenital or acquired childhood etiology.

Conclusion: In this initial experience, the percutaneous implantation of the Braile Inovare bioprosthesis in the tricuspid and pulmonary position was effective and safe for patients with important dysfunction of the previously surgically implanted bioprosthesis; the use is capable of providing encouraging results with increased functional and structural cardiac improvement.

160. MESENTERIC ISCHEMIA AFTER STENT IMPLANTATION IN NATIVE AORTIC COARCTATION

Renata Mattos, Herica Falci, Victor Hugo Oliveira, Luiz Carlos Simões

Instituto Nacional de Cardiologia, Rio de Janeiro, Brazil

Background: Mesenteric ischemia is well known complication after aortic surgery, but there aren't many reported cases after percutaneous procedures.

Case Report: A 6-year-old boy had clinical and echocardiographic diagnosis of severe aortic coarctation and persistent ductus arteriosus with moderate left heart enlargement. We opted to implant a covered CP stent for treatment of both lesions at the same time and achieved a good hemodynamic result. He was admitted to the pediatric ward just. After about 24 hours he started complaining of abdominal pain and distension. Serial abdominal x-rays and abdominal CT were made. He was examined by the general pediatric surgeon who suspected of mesenteric ischemia. The patient was admitted to the ICU and treated conservatively with fasting and antibiotics. He got better and was discharged after 72 hours.

Discussion: In our hospital, we frequently treat aortic coarctation with stent implantation. In the last 10 years, we had less than 1% complications, all of them related to the vascular access. It was our first mesenteric ischemia during this period. Opposite to post-surgical mesenteric ischemia, which is related to the time of aortic clamping, with percutaneous treatment the aortic flow is interrupted for a minimal amount of time. It is known that ischemia leads to progressive tissue damage, but paradoxically the reperfusion lesion after flow restoration is even more damaging.

This case showed us that mesenteric ischemia following percutaneous aortoplasty, however rare, is potentially fatal if not diagnosed before intestinal perforation. This has led to a change in our routine post-aortoplasty, with a prolonged fasting time.

161. OFF-LABEL USE OF A PFO DEVICE FOR OCCLUSION OF A RESIDUAL LEFT ATRIAL APPENDAGE SHUNT

Renata Mattos

Instituto Nacional de Cardiologia, Rio de Janeiro, Brazil

Case Report: A 17 year-old boy had obstructive hypertrophic cardiomyopathy and mitral regurgitation. He had surgical miectomy and mitral valve replacement in March 2017. During the surgery the left atrial appendage (LAA) was excluded.

In November 2018 he was admitted after incidental echocardiographic finding of a thrombus in the left atrium and a residual shunt from the LAA. Clinical treatment with enoxaparin and warfarin was started. After thrombus resolution, it was decided that the LAA communication should be closed.

The procedure was made in the cath lab under general anesthesia with transesophageal echocardiographic (TEE) guidance. Transeptal puncture was performed with Brockenbrough needle and we managed to assess the LAA with a JR catheter. TEE and radioscopic images confirmed that the communication was a small hole in the surgical patch. We then safely positioned a stiff guide wire inside the LAA to allow us to insert a 7 French long sheath and the Occlutech 16/18 PFO occluder.

Immediately after implant, TEE showed minimal residual shunt through the device.

Because of the mitral prosthetic valve, he still takes warfarin. In January 2019 he was again admitted in the hospital for symptomatic atrial fibrillation, which was treated with amiodarone. TEE in this occasion showed the device well positioned with no residual shunt.

Discussion: Closure of surgical residual shunts might be challenging, because the anatomic structures may be distorted and we are dealing with foreign materials. Therefore, planning ahead and pre-procedure imaging is very important. Similarly, good TEE imaging is vital during the procedure.

Since these defects are unique, there are no specific designed devices. Therefore, off-label use of PFO, ASD, VSD, vascular plug and other devices is mandatory.

162. WHEN PERCUTANEOUS TREATMENT IS NOT THE BEST CHOICE: THE ASDS WE DIDN'T CLOSE

Rafael Agostinho, Renata Mattos

Instituto Nacional de Cardiologia, Rio de Janeiro, Brazil

Background: The study aims to evaluate a phenomenon known in the cath lab during percutaneous occlusion of atrial septal defects (ASD): the crossover for surgery. We evaluated, among the surgical ASD closures performed in our hospital in a given period, the patients who underwent previous catheterization and, if the intention was the percutaneous closure, what was the reason for referring to surgery. We classified according to the type of ASD, the absolute size of the defect and its relation to the body surface, as well as the justification that motivated the indication of open surgery.

Methods: We reviewed the hospital records of all the patients referred for percutaneous ASD closure from 2010 to 2017. Patients referred to surgery for defects other than ostium secundum ASD were excluded.

General anesthesia and transesophageal echocardiography were performed in all patients. Some cases were excluded at this point. After this evaluation we proceeded to the right heart catheterization. If the pulmonary artery pressure and resistance were normal, we evaluated the septal defect with a sizing balloon, which was another stage when some patients were excluded. After positioning of the device, echocardiographic evaluation of its stability and relationship to adjacent structures was the final stage when some cases were referred to surgery.

Among the cases referred to surgery, we analyzed several factors of the defect, such as the biggest diameter and its rims.

Results: From 2010 to 2017, there were 80 surgeries for isolated ASD repair, among which 18 had been previously referred for percutaneous intervention. In the same period 221 patients were referred for percutaneous closure, so the crossover to surgery happened in 8,2% of those 221 cases.

We found that the absence of adequate rims and a high ASD size to body surface area (higher than 30) were the most prevalent factors influencing the decision to abort the percutaneous procedure.

Conclusion: We know that giving up percutaneous closure of some ASDs in the cath lab, after balloon sizing and echocardiographic evaluation, is inevitable.

Based on the factors examined in this study, we found that some patients could be referred directly to surgery, thus avoiding one unnecessary procedure under general anesthesia. This approach is specially important in the public health system.

163. DIAGNOSIS OF DIASTOLIC DYSFUNCTION DURING ROUTINE PRE-FONTAN CATHETERIZATION: THERE IS NEVER TOO MUCH INFORMATION

Renata Mattos, Victor Hugo Oliveira, Rafael Agostinho

Instituto Nacional de Cardiologia, Rio de Janeiro, Brazil

Background: The Fontan completion is one of the strategies for single ventricle patients. Among several variables that influence the prognosis of these patients, occult diastolic dysfunction (ODD) is a key element which is frequently undiagnosed. We used a simple volume stress test to access ventricular diastolic function in patients undergoing routine catheterization before Fontan surgery.

Methods: Patients who had bidirectional Glenn surgery and were scheduled to undergo Fontan surgery were selected to catheterization under general anesthesia. Besides routine hemodynamic assessment of the pulmonary circulation, study of the systemic venous system, ventricle and aorta, and also occasional occlusion of an aortopulmonary collateral, we performed the volume stress test. This test consists in rapid infusion (over five minutes) of 15ml/kg of saline. Ventricular end diastolic pressure (EDP) was measured before and five minutes after the infusion. EDP above 15mmHg before or after the test mean that ODD is present. Afterwards we reviewed the hospital records of the patients who had the test and went to Fontan surgery.

Results: From January 2018 to April 2019 there were eight pre-Fontan hemodynamic studies including assessment of ODD in the cath lab. Their ages ranged from 10 to 19 years with an average of 13 years old. The average of time since the Glenn surgery was 4 years. Two of them had high pulmonary arterial pressure and therefore didn't go to surgery. Among the six who had surgery, three had basal elevated EDP and the other three expressed DDO after the volume test. Two of them had fenestrated Fontan. Apart from one patient who had post-operative endocarditis, the average length of hospital stay was 29 days and the average thoracic draining time was 11 days.

Conclusion: Echocardiographic assessment of the single ventricle is challenging. ODD is relevant in these patients, even in those with normal systolic fraction, since it might direct medical therapy towards lusitropic drugs instead

of pulmonary vasodilators. In addition, we believe that knowledge of diastolic function might help the surgical team decide if a fenestrated Fontan is a better strategy.

Since we still have little data and all of our patients had ODD, we couldn't detect any clinical impact of the test.

However, cardiac catheterization is a routine procedure in all patients scheduled to Fontan surgery. Since the volume test had no additional cost or complications, we believe it can easily provide one more information about the physiology of each individual patient.

164. INTERVENTIONS USING AXILLARY ARTERY IN PEDIATRIC PATIENTS WITH CONGENITAL HEART DISEASE

Giolana Mascarenhas Cunha, Germana Cerqueira Coimbra, Luiz Junya Kajita, Raul Arrieta

Heart Institute of University of Sao Paulo-Brazil, São Paulo, Brazil

Introduction: Vascular access is an important issue for interventional therapies in critical congenital heart diseases, specially in children weighing less than 20 kilograms.

The use of axillary vascular approach is not so frequent in pediatrics, but may be useful in several types of procedures.

We aimed to evaluate the use of the axillary artery in different procedures performed on children weighing less than 20 kilograms.

Methods: We performed a retrospective review of all patients under 20kg managed with therapeutic catheterization using axillary artery approach in a tertiary care center in South America since august 2013 until February 2019 (total 5515 cases). The medical records of these patients were reviewed to demographic and procedural details.

Procedural technique: The right axillary artery was used in all cases, direct percutaneous access to the right axillary artery was achieved using either ultrasound guidance or feel pulse. The puncture was performed with a 21 G needle, with the arm abducted at 90°, and a 0.014 inch guide-wire was positioned in the descending aorta. A 5 Fr x 11 cm pediatric introducer was initially used for the procedure and whenever required, it was replaced for a larger one. Manual compression hemostasis was performed after the intervention.

Results: Were included in the study 30 patients ≤ 20kg, in wich 26 cases(16 males), the axillary artery was the access via to therapeutic procedure. Median age and

weight were 1,7 yo (25 days – 7,7yo) and 9,0 (3,29-20kg) respectively.

Thirteen patients underwent intervention in aortic coarctation (balloon or stenting), six patients underwent stenting in mBT-shunt, four cases primary PDA stenting, one case aortic valvuloplasty and one coil embolization of MAPCAs. Nine procedures were classified as an emergency. The median fluoroscopy time was 17,58 min (17-33min).

There wasn't major complication linked to axillary access. Limb pulses and perfusion were monitored post procedure and remained normal. Technical success was observed in all patients.

164. Table 1.

	Study number (n=25)
Age (days-months)	20 (25d-93m)
Weight (kg)	9 (3,2-20kg)
Procedure	
BT shunt stenting	5
PDA stenting	4
Recoarctation stenting	6
Recoarctation balloon angioplasty	4
Aorta coarctation stenting	3
Pulmonary artery stenting	1
Balloon aortic valvuloplasty	1
Coiling in MAPCAs	1
Final sheath	
5Fr	12
6Fr	4
7Fr	7
8Fr	1
10Fr	1
Complications	
Local bleeding	2
Hematoma	2

Discussion: The use of the axillary artery was safe and effective in all patients included in our study; being an excellent alternative access route to treat different types of congenital heart diseases, besides it allows to conserve the other puncture sites for future interventions

165. CLOSURE OF HEPATIC LESIONS CAUSING CARDIOPULMONARY SYNDROME IN NEONATES. CASE SERIES OF HEPATIC LESIONS PRESENTED WITH CCF AND PAH IN ABSENCE OF HEPATIC FAILURE CLOSED WITH CHEMO AND COIL EMBOLIZATION

Sudeep Verma, Gouthami V, Ananta Ram V, Rajamannar K V, Nanda Kishore

Kims Hospital, Hyderabad, India

Introduction: Hepatic lesions causing cardiopulmonary syndrome in absence of liver failure and cholestasis are rarely seen in neonatal age. We are presenting three structural hepatic lesions of different etiology causing cardiopulmonary syndrome in neonatal age successfully treated with chemo or coil embolization.

CASE 1: HEPATIC TUMOUR WITH CARDIOPULMONARY SYNDROME. Full term neonate developed features of **CCF with hepatomegaly (till right iliac fossa)** on day one of life. Diagnosed to have **Hepatic angioendothelioma**, hence started on steroids, beta blocker, inotropic support and diuretics. On day 16 of life developed respiratory failure with CCF and severe PAH. CT scan showed **hepatic angioendothelioma with multiple large intralesional vascular lakes causing high output failure**. AFP was elevated in presence of thrombocytopenia and anaemia. In view of intractable cardiac failure, deliberate partial closure of the intralesional lakes was done using **ONYX (Ethylene Vinyl Alcohol- Micro therapeutics- Irvine USA) and embolization coils (Cook- Bloomington- USA) through right femoral artery access**. Subsequently clinical condition improved and discharged in a stable condition. 12 months follow up showed normal liver function, asymptomatic status with no cardiomegaly or hepatomegaly.

CASE 2: HEPATIC AVM CAUSING HIGH OUTPUT CARDIAC FAILURE AND PAH. 15 days old IUGR neonate weighing 1.7 kg presented with poor feeding and breathing difficulty. Referred for cardiac assessment in view of **cardiomegaly**. During echocardiography it was detected to have high hepatic venous return. Detailed evaluation revealed **large hepatic AVM involving left lobe of the liver**. In view of the poor response to medical therapy and increasing distress and cardiomegaly, it was decided to close the lesion. After securing right femoral arterial access- hepatic AVM was closed partially using multiple injections of **Onyx (Ethylene Vinyl Alcohol- Micro therapeutics- Irvine USA)**. Baby was discharged on beta blocker and diuretics. 6 months follow up showed good weight gain, asymptomatic status with normal cardiac size and no PAH. Residual small AVM was left unattended.

CASE 3: INTRAHEPATIC PORTOSYSTEMIC SHUNT TYPE 3 CAUSING PAH AND CARDIOMEGALY. One day old neonate presented with **respiratory distress soon after birth**. Evaluation revealed PAH and cardiomegaly not improving with medical and ventilatory management. Further evaluation showed **intrahepatic shunt between left portal vein and left hepatic vein connected through an aneurysm(-Type 3 Park)**. In view of worsening clinical status and persistent PAH closure was done on day 15 of life. After securing right internal jugular vein access, left hepatic vein was hooked and the aneurysm connecting it with the portal vein was closed using **multiple V Trek Microplex 18 coils (Terumo Corporation, Japan) and three 0.035 4-4 Embolization coils (Cook Medical Indiana, USA)**. Post procedure general condition of the baby improved and discharged in a stable condition. 8 months follow up showed asymptomatic status with no evidence of PAH with normal cardiac size.

Conclusion: Variety of structural hepatic lesions ranges from tumour, AVM or portosystemic shunt can cause cardiopulmonary syndrome in neonates. High index of suspicion and precise delineation is essential to formulate treatment plan. Such lesions can be treated with multidisciplinary approach using variety of embolisation agents.

166. STENTING IN NEAR-ATRETIC COARCTATION OF THE AORTA. ACUTE AND MEDIUM-TERM OUTCOMES IN A LARGE COHORT OF PATIENTS WITH COMPLEX AORTIC ANATOMY

Magaña KG, Guerrero C, García-Montes JA, Zabal-Cerdeira C, Molina-Sánchez T, Romero-Montalvo LA, Moreno-Salas JC, Sandoval JP.

Department of Intervention in Congenital Heart Disease, Ignacio Chavez National Institute of Cardiology, Mexico City.

Background: Endovascular repair has generally become the first-line therapy for most adolescents and adults with discrete coarctation of the aorta with excellent results. However, in situations where the obstruction is progressive and results in a visible lack of continuity at the isthmus level (so-called extreme or near-atretic coarctation), interventionists are faced with a challenging and technically demanding high-risk procedure with major potential complications including dissection, aortic rupture, massive bleeding and aneurysm formation.

Methods: Retrospective, single-center analysis including all patients who were diagnosed with near-atretic coarctation who underwent percutaneous intervention between March 2004 and March 2019 at the Ignacio Chavez National Institute of Cardiology.

Results: 772 patients underwent aortic balloon or stent angioplasty at our Institution over the last 15 years. Of these, 27 (3.5%) patients were considered to have an extreme/near-atretic coarctation and underwent aortic stenting at a median age of 20 years (7-49) and weight of 61kg (20-84). Male to female ratio was 2.3:1. Successful recanalization of the coarctation was achieved in all cases from an antegrade approach (from ascending to descending aorta) through the radial artery in 17 (62%) patients and the brachial artery in the remaining 10 (38%) patients. All but one patient (who required radiofrequency assisted perforation) were managed with mechanical guidewire-assisted crossing of the coarctation. Once the coarctation was crossed, wires were snared from the femoral access enabling the long sheath to be advanced retrogradely in usual fashion. Peak systolic gradient across the coarctation fell from 49mmHg (± 23) to 5mmHg (± 6) $p < 0.001$. Predilatation with standard PTA balloons prior to stent implantation was performed in all cases. Covered stents were used in 13 (48%) patients (Atrium $n=7$, CP Covered Stent $n=6$) and bare metal stents were deployed uneventfully in the remaining 14 (52%) patients. There were no deaths related to the procedure. One patient developed a small hematoma at the site of brachial artery entry with no sequelae. Acute aneurysm formation was encountered in one (3%) patient who developed a small contained vertebral artery aneurysm, interestingly after deployment of a covered stent. Follow up was available in 92% at a median time from intervention of 19 months (IQR 7-90). Two (8%) patients have required reintervention for additional stent angioplasty (one of them due to previous stent fracture). Fourteen (56%) patients remain hypertensive despite medication. Follow-up imaging was available in 11 (44%) patients showing an intact stent and no evidence of aneurysm formation.

Conclusions: Extreme/near-atretic coarctation of the aorta represents a complex lesion. Our experience shows stent angioplasty in this setting can be performed safely and effectively. Adequate management of coarctation can be achieved with both bare metal and covered stents. A significant proportion of patients will remain hypertensive despite obstruction relief.

167. TRANSCATHETER THERAPY FOR TREATMENT OF PULMONARY EMBOLISM IN CHILDREN: SINGLE TERTIARY CENTER EXPERIENCE WITH FOCUS ON CATHETER DIRECTED THROMBOLYSIS (CDT)

Varun Aggarwal, Athar M. Qureshi, Asra Khan, Henri Justino, Srinath T. Gowda

Texas Children's Hospital and Baylor College of Medicine, Houston, USA

Purpose: Acute pulmonary embolism (PE) is a life-threatening condition and rarely occurs in children. In adults, catheter-directed thrombolysis (CDT) emerges as a potentially safer and an effective therapeutic option. However, there is a paucity of data on the safety and efficacy of CDT for pulmonary embolism in children. We report a single-center experience of various transcatheter therapy including CDT for acute PE in children.

Materials and Methods: This is a retrospective study of children who had acute PE and underwent transcatheter therapy at Texas Children's Hospital and Baylor College of Medicine, Houston, TX during 8-year period from April 2010 to January 2019. Demographics, clinical data, transcatheter treatment, and complications associated with pulmonary embolism were collected along with the outcome. The PE was categorized as massive (hemodynamic instability) or submassive. Transcatheter therapy included; various mechanical thrombectomy techniques and CDT with EkoSonic ultrasound accelerated endovascular system (EKOS).

Results: A total of 17 patients of median age 13.2 years with the range from 8 days to 20.7 years received transcatheter therapy for acute PE. Among 17 patients, two patients had osteosarcoma and two were postoperative pulmonary artery stenosis (leading to thrombus formation in the distal PA); and therefore, were excluded from the review. 8/13 patients had massive PE and the rest were submassive. Among the 13 patients, seven received CDT using tissue plasminogen activator (tPA) through infusion catheters via the EkoSonic ultrasound-accelerated thrombolysis system (0.5-2mgs/hrs for 8-36hrs); and six underwent mechanical thrombectomy using various techniques (one Angiojet, one Angiojet and balloon angioplasty, four using Pronto catheter) and anticoagulation. All patients ($n=7$) treated with EKOS showed significant clinical improvement within 24 hours. Only three of six patients had successful mechanical thrombectomy. Of the three patients with unsuccessful mechanical thrombectomy, two patients had resolution of PE with systemic anticoagulation. The third patient died due to rejection of the transplanted heart and multiple comorbidities. Among 12 patients who survived, there was no major procedure related or systemic / local bleeding complications with median hospital stay of 13 days with the range from 4-184 days.

Conclusions: CDT is an emerging alternative therapy for massive and sub-massive pulmonary embolism in children. In our experience, CDT was found to be a relatively safe and effective treatment option for acute massive or submassive PE without any procedural morbidity or

mortality in children. At experienced centers, CDT may be considered as a first-line treatment for patients with acute massive PE. The precise dosage and duration of CDT needs further investigation.

168. NOVEL TECHNIQUE FOR SELECTIVE LYMPHATIC EMBOLIZATION USING AN ANTI-REFLUX SUREFIRE INFUSION CATHETER IN A PATIENT WITH A HISTORY OF HYPOPLASTIC LEFT HEART SYNDROME (HLHS)

Sanjay Sinha^{1,2}, Aarti Luhar¹, Ashley Prosper¹, Takegawa Yoshida¹, Paul Finn¹, Daniel Levi¹, Edward Lee¹

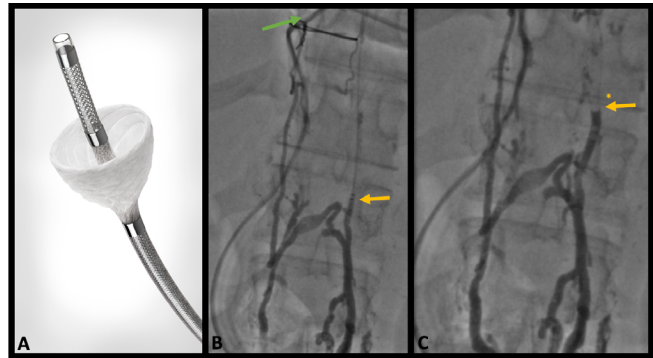
¹UCLA, Los Angeles, USA. ²UC Irvine, Orange, USA

Objective: Demonstrate a novel technique in selective glue embolization of lymphatic vessels in a patient with congenital heart disease and a chylous leak after heart transplant using an anti-reflux catheter with a dynamic expandable tip.

Background: Lymphatic interventions have become life-saving in those with lymphatic flow disorders. There is a new found understanding that a working lymphatic system is essential in these patients, and selective embolization of target vessels is necessary. Reflux of embolic material during targeted interventions into the thoracic duct causing paradoxical emboli and strokes has been described. This case demonstrates a novel use of a chemotherapeutic delivery catheter, utilizing its retractable anti-reflux "cone" to ensure entirely antegrade delivery of embolic material to sub-selective vessel targets.

Methods: This is a retrospective review of a single case wherein this delivery system was used for the first time to occlude a chylous leak. The patient first underwent a dynamic contrast enhanced lymphangiography (DCMRL) to map his lymphatics and a subsequent heart catheterization. The thoracic duct was accessed percutaneously from the left supraclavicular area and the Surefire Infusion system was directed into a branch of the thoracic duct found to be leaking into the pleural space. N-BCA glue was delivered to this area with deployment of the anti-reflux cone. Demographics, procedure details, procedure related complications and follow up data were collected and shown.

Results: One patient with a history of HLHS orthotopic heart transplant (OHT) underwent successful treatment of a refractory chylothorax after his second transplant using this technique. Pre-intervention thoracic duct angiography showed no evidence of a cisterna chyli, and the presence of an abnormal network of abdominal lymphatics. Post intervention of there was no undesired reflux of glue embolic material. Given the volume of his leak, the decision was



168. Figure 1. Surefire Infusion catheter (A) with an ePTFE cone to prevent reflux of flow. Selective embolization of a vessel with chylous leak (green arrow) is seen with the catheter in place (yellow arrow), without evidence of reflux of n-BCA glue (yellow arrow with asterisks).

made to also conduct a thoracic duct embolization. His pre-procedural chest tube output was an average of 4.3 liters of chylous output per day. This was reduced to less than 600mls by 4 days after the procedure. His chest tubes were removed on post procedural day 12. Subsequent chest x-rays showed no significant re-accumulation of pleural fluid there-after. The patient did, however develop chylous ascites requiring intermittent paracentesis. This was felt to be due to complete thoracic duct embolization reversal of flow to an abdominal lymphatic tract.

Conclusion: Use of a selective anti-reflux catheter can allow direct delivery of embolic material to small branches of the thoracic duct to treat patient with pulmonary lymphatic perfusion syndrome (PLPS). The catheter can be easily advanced over 0.018 inch wires via conventional percutaneous routes. It is essential to attempt selective vessel embolization and avoid complete thoracic duct embolization if possible, to avoid complications such as stasis or reversal of lymphatic flow seen in this case as chylous ascites.

169. THE PULMONARY ARTERY STENT (PAS) STUDY-A RETROSPECTIVE STUDY IN COLLABORATION WITH THE FDA AND INDUSTRY: A NEW PATHWAY TO PRE-MARKET APPROVAL FOR PEDIATRIC DEVICES

Frank Ing¹, Aimee Armstrong², Jeff Delaney³, Howaida El-Said⁴, Bryan Goldstein⁵, Don Hagler⁶, Ralf Holzer⁷, Sok-Leng Kang⁸, Asra Khan⁹, Daisuki Kobayashi¹⁰, Andy Pelech¹, Patrick Sullivan¹¹, Andrea Wan⁸, Thomas Forbes¹⁰

¹UC Davis Children's Hospital, Sacramento, USA. ²Nationwide Children's Hospital, Columbus, USA. ³University of Nebraska Children's Hospital, Omaha, USA. ⁴Rady Children's Hospital, San Diego, USA. ⁵Cincinnati Children's Hospital, Cincinnati, USA. ⁶Mayo Clinic, Rochester, USA. ⁷Weill Cornell Medical Center, New

York City, USA. ⁸The Hospital for Sick Children, Toronto, Canada. ⁹Texas Children's Hospital, Houston, USA. ¹⁰Children's Hospital of Michigan, Detroit, USA. ¹¹Children's Hospital Los Angeles, Los Angeles, USA

Background: Stent treatment for branch pulmonary arteries (BPAS) has been a standard of care for 3 decades, but is still considered "off-label use". This retrospective multi-institutional study was designed in collaboration with Congenital Cardiovascular Interventional Study Consortium, the FDA and industry (CardinalHealth™) as a new pathway to pre-market approval (PMA) of an existing FDA-approved stent (Genesis XD).

Methods: Patients with two-ventricle physiology, weighing ≥ 10 kg, who received a Genesis XD stent for unilateral BPAS from 1/2006-12/2014 were included. Patient profile, cath lab hemodynamic and angiographic data, pre, post and 1-year follow-up echocardiographic and advanced imaging data (CTA or MRI when available) were evaluated. Objective performance criteria (OPC) developed in collaboration with the FDA included primary endpoints of technical success defined as one of the following: 1) Increase vessel minimum diameter by $\geq 50\%$, or 2) Decrease systolic gradient by $\geq 50\%$, or 3) Decrease right ventricle (RV)/systolic blood pressure (SBP) ratio to $\leq 50\%$ and serious adverse events $\leq 9\%$. Secondary endpoint was preservation of improved diameter ($\geq 50\%$ of original stenotic diameter) and physiology at 1-year follow-up (FU).

Results: The study included 112 pts (11 institutions) with mean age and wt of 17 ± 9.2 yrs and 31.7 ± 22.2 kg respectively. LPA stenosis was found in 72 (64%) and 104 (93%) had prior cardiac surgery. TOF, PA, and truncus arteriosus were the most common cardiac diagnoses (77/112). Stent implant was successful in 98.2% (110/112) but primary endpoints were achieved in 97.3% (109/112). One failed primary endpoint criteria with stented vessel diameter increasing only 38%. Mean minimal vessel diameter increased from 4.96 ± 2.25 mm to 10.82 ± 3.16 mm. RV/SBP ratio decreased from $52.5 \pm 16.4\%$ to $43.8 \pm 13.7\%$. Three (2.7%) serious adverse events were encountered (stent embolization in 2 requiring surgical repair and ventricular tachycardia in 1 with successful cardioversion and stent implantation). Adequate FU data was available in 92.9% (104/112) with inadequate data in 5. At 1-yr echo FU, mean vessel diameter was preserved at 9.55 ± 2.56 mm (N=68). Mean vessel gradient remained low at 17.4 ± 10.34 mmHg (N=40) (from 30.6 ± 14.93 mmHg pre-intervention) and RV/SBP ratio remained low at $34.8 \pm 0.12\%$ (N=28). Available CTA (N=4) and MRI (N=14) showed improvement of flow to affected lung from mean $23.5 \pm 7.5\%$ to $37.6 \pm 8.2\%$ at mean

FU of 15.7 ± 18.8 months. Secondary endpoint success was seen in 90.2% (101/112) while 3 failed secondary endpoint criteria for success. Excluding the 5 with inadequate FU data, 94.4% (101/107) met both primary and secondary endpoint success. Further intervention was performed in 5 at mean FU of 25.3 months for "relative" obstruction due to normal somatic growth. Successful further dilation was achieved to match normal adjacent diameters in all. No stents fractures were observed during the study period.

Conclusion: Treatment of BPAS using the Genesis XD stent is safe and effective with preservation of vessel diameter and physiology in over 94% at 1 year FU. Further stent dilation to match normal somatic growth is possible. Based on these results, PMA application is currently in progress under a new FDA pathway for pediatric devices.

170. PARTIAL OCCLUSION OF A LARGE PDA IN THE SETTING OF SEVERE PULMONARY HYPERTENSION USING A MANUALLY FENESTRATED AND STENTED MUSCULAR VSD DEVICE.

Amr Matoq¹, Gareth Morgan², Dunbar Ivy², Michael Ross²

¹Nemours/Alfred I. duPont Hospital for Children, Wilmington, USA. ²Children's Hospital Colorado, Aurora, USA

Background: A large patent ductus arteriosus (PDA) both pressure loads and volume loads the pulmonary vascular bed and can lead to irreversible pulmonary vascular disease (PVD). Managing a large PDA in the setting of significant long-standing pulmonary artery hypertension (PAH) is challenging. Elimination of the left to right shunt is important to protect the pulmonary vascular bed, but in the setting of irreversible PVD, closing the PDA can precipitate low cardiac output and right ventricular failure. Fenestrated closure of atrial septal defects as well as intentional creation of a connection between the aorta and pulmonary arteries have been reported, however manual fenestration of PDA devices is rarely performed.

Objective: We present a case of PAH with bidirectional shunting at a large PDA, who underwent a manually-fenestrated and stented muscular VSD device for partial closure of the PDA.

Case: A 10-year-old female presented with exercise intolerance. Echocardiography showed a large PDA with bidirectional shunting and evidence of PAH. Cardiac catheterization confirmed the diagnosis, elevated pulmonary vascular resistance (PVR) that was not responsive to 100% FiO₂ and inhaled nitric oxide. There was no change to pulmonary arterial pressures with PDA test occlusion. The patient was started on dual oral PAH therapy and oxygen.

One year later, repeat cardiac catheterization and partial PDA occlusion was performed.

Procedure: The PDA ampulla measuring 14.2 mm with a minimal diameter of 11.7 mm. The decision was made to use a 14 mm Amplatzer VSD device. It was fenestrated manually by sharp and blunt dissection of the fabric weave. The delivery sheath was positioned in the usual manner across the PDA and a 0.014" GrandSlam wire positioned through the sheath into the descending aorta. The back-end of the GrandSlam was passed through the fenestration prior to loading the device and advancing it into the sheath. The device was successfully deployed. We were initially unable to pass a 4mm x 15mm Resolute Onxy coronary stent across the previously made fenestration. The GrandSlam wire was therefore snared in the descending aorta and a 4-Fr long sheath was inserted into the femoral artery over the GrandSlam. The stent was advanced retrograde and with using the two long sheaths to stabilize the VSD device, the stent was able to be pushed through the fenestration and deployed successfully. The most recent echocardiogram at approximately 6 months showed good device position and restrictive left to right flow across the stent with mild septal flattening.

Discussion and Conclusion: This represents to our knowledge the first reported use of a manually fenestrated, stented Amplatzer muscular VSD device in the ductal position. Given the intrinsic tendency of nitinol to reassume it's nominal shape, we felt using a stent to mechanically displace the nitinol and leave a lasting fenestration to be a preferred over simply distracting the fabric weave. Until a fenestrated device is commercially available for implantation in the duct, a muscular VSD device serves as good substrate in some cases for deployment and fenestration with a coronary stent.

171. SHORT-TO-MIDTERM OUTCOMES OF SURGICAL VS HYBRID PULMONARY VALVE REPLACEMENT

Lamya Mubayed, Kim Ray, John Bokowski, Joshua Murphy
Rush University Medical Center, Chicago, USA

Introduction: Hybrid pulmonary valve placement (PVR) involving surgical plication of the main pulmonary artery followed by transcatheter PVR is an alternative to surgical PVR requiring cardiopulmonary bypass (CPB) for patients with a dilated right ventricular outflow tract (RVOT). Previously reported immediate outcomes of hybrid PVR suggested that the procedure is comparable to surgical PVR with the additional advantage of no cardiopulmonary bypass (CBP) and lower transfusion rates.

Objective: We sought to examine the short to midterm outcomes of surgical vs hybrid pulmonary valve replacement at a tertiary care medical center.

Methods: Retrospective chart review of patients who underwent surgical or hybrid PVR at our center from June 2012 through June 2015.

Results: 8 patients (age 31.5±17.4yr) underwent hybrid PVR during the review period, vs .13 patients (31±18.4yr) with surgical PVR. Follow-up ranged from 1-45 months in the hybrid PVR group and 1-61 months in the surgical PVR group (p=0.11). Pulmonary regurgitation occurred in 33% of the surgical group vs 14% of the hybrid group (p=0.31). Max pressure gradient across the implanted valve was higher than the surgical group (mean 25.4 vs 10.0, p=0.04). Exercise intolerance was in the surgical group was 33% vs 14% in the hybrid group. New onset arrhythmia was seen in one patient in the in the surgical group vs none in the hybrid group (p= 0.34).

Conclusion: Hybrid PVR is a viable option for patients with RVOTs that are too large for standard percutaneous PVR. Despite being higher in the hybrid group, the peak pressure gradient across the implanted pulmonary valves was not elevated enough to require further intervention during this study period. Early to mid outcomes from this study are comparable to previously published studies comparing surgical vs standard PVR.

172. MANAGEMENT OF FIRST DEGREE HEART BLOCK AFTER PERCUTANEOUS ATRIAL SEPTAL DEFECT DEVICE CLOSURE-AN ENIGMA!

Sripadh Upadhya

Health City Cayman Islands, Grand Cayman, Cayman Islands

Percutaneous device closure of the Secundum Atrial septal defect (ASD) is a proven therapy for the defect and Heart Block is one of the major, though rare complications especially with the larger devices and particularly with the Amplatzer Septal Occluder (ASO).

3 year old Girl weighing 14kg, diagnosis of 12mm secundum ASD, Left to Right shunt with adequate rims with a total septal length of 30mm, ECG revealed sinus rhythm with a PR interval of 0.16 sec. 14 mm ASO was implanted. The rhythm was sinus throughout the procedure with no change in the PR interval. After the device was released, the ECG showed prolonged PR interval of 0.20sec. The echocardiography was done which showed device insitu with no complications. Oral steroid was given as TID dose. Repeat ECG at 4pm showed PR prolongation (0.22sec). Next

day 24 hour Holter revealed average PR interval of 0.166sec with maximum interval of 0.188sec and minimum interval of 0.146sec. Pt was discharged with 2 days of oral steroids along with Aspirin with an advice of more frequent ECG follow up. The ECG at 1 week and 2 week follow up revealed PR interval of 0.16 sec.

Conduction defects may be present in patients with ASDs at baseline, possibly due to hemodynamic changes and the proximity of the AV node in the triangle of Koch to the location of the defects. This risk of arrhythmias after percutaneous device closure it is about 1–6%. The onset may be as early as during device deployment even before the device is released to as late as few days to weeks. One of the case reports illustrates late progression of first degree AVB to complete heart block four years after ASD device closure. The etiology of the conduction blocks after ASD device closure has been attributed at least partly to the inflammation and edema caused around the AV node by the atrial discs. This is one of the bases for the administration of steroids empirically in such cases. However there have been cases in which steroids have not helped and hence the recommendations on this issue are not quite clear. Risk factors for development of AVB include hemodynamically significant defect with QP/QS ratio >2.8, larger defects, greater device/height ratio, larger devices, short distance between right atrial disk to tricuspid valve, deficient postero-inferior rim <5 mm, and weight <15 kg.

Transcatheter ASD device closure in small children may be associated with increased complications. Despite adequate postero-inferior margin Heart Block may still occur in small children. Heart block is a rare but worrying complication of ASD device closure, especially occurring in high-risk patients. Though in most of the cases it is a transient phenomenon resolving either spontaneously or with anti-inflammatory therapy, in some of the case it requires surgical removal of the device and closure of ASD. There are no consensus for the management of first degree and second degree heart block. Decision should be taken case by case basis and close monitoring and surgical back-up are essential requirement for these patients.

173. BALLOON ATRIAL SEPTOSTOMY IS A NEGATIVE PREDICTIVE FACTOR FOR SURVIVAL IN PATIENTS WITH PULMONARY ATRESIA INTACT VENTRICULAR SEPTUM

Nicole Herrick¹, Asimina Courelli¹, Nicholas Dreger², Jesse Lee², Kanishka Ratnayaka², Laith Alshawabkeh¹, John Moore², Howaida El-Said²

¹UC San Diego, San Diego, USA. ²Rady Childrens Hospital San Diego, San Diego, USA

Introduction: Pulmonary atresia with intact ventricular septum (PA/IVS) compromises less than 1% of all congenital heart disease. Management strategies for PA/IVS are evolving as the role of catheter based intervention is expanding.

Methods: Retrospective review of patients at a large academic center with a diagnosis of PA/IVS from 1988 to 2018. Clinical records, procedural reports and angiograms were reviewed. Here we compare the interventions from the newborn to determine if there is a correlation with ultimate surgical anatomy and mortality.

Results: Ninety patients had a diagnosis of PA/IVS, 57.3% were male. RV dependent coronary sinusoids were present in 47.8%. Seventy-two percent (n=65) were managed surgically in the newborn period; of those 13.3% (n=12) had a preceding balloon atrial septostomy (BAS) and 5.6% (n=5) had a preceding radiofrequency perforation and pulmonary valvuloplasty. Eighty-three percent of patients managed surgically were eventually palliated to single ventricle physiology. Twenty-six percent (n=24) were managed exclusively via catheterization based intervention as a newborn; 18.9% (n=17) had primary PDA stenting (accompanied by RF perforation in 2.2%, pulmonary valvuloplasty in 6.7%, or both in 10%), 5.6% (n=5) had isolated BAS, and 2.2% (n=2) had BAS and PDA stenting. Of those managed with primary PDA stenting, 77.8% (n=14) ultimately underwent a bi-ventricular repair. One patient had a transplant in the newborn period. After median 8.0 years follow up (Q1 2.0, Q3 17.25), mortality was 10% (n=9), two patients received a heart transplant. Median age at death was 4.5 months (Q1 0.77, Q3 6.63). Undergoing a BAS in the newborn period was predictive of early mortality (p=0.00, 95% CI 0.27-0.54), even after adjusting for the presence of RV coronary sinusoids. Patients with an isolated BAS had the highest mortality (80%), followed by those who underwent BAS and PDA stenting (50%), and BAS and surgical shunt (33%, chi-squared p=0.00). There was no significant difference in survival for patients with and without RV coronary sinusoids (p=0.47). There were no deaths to date in the 17 patients who underwent PDA stenting without BAS.

Conclusions: Patients with PA/IVS who require a BAS at birth, regardless of the presence of RV dependent coronary sinusoids, have a significantly higher mortality, especially in the newborn period. The need for BAS performed in the newborn period may reflect the severity of disease. Given the high mortality in this group, these patients may benefit from consideration for transplantation.

174. TRANSCATHETER CLOSURE OF CONGENITAL CORONARY ARTERY FISTULA WITH VASCULAR PLUG: INTERMEDIATE OUTCOME AND FOLLOW-UP ANGIOGRAPHY IN SINGLE CENTER EXPERIENCE

Jakyoungh Yoon, Seongho Kim, Soick Jang, Sujin Park, Eunyoungh Choi, Jiseok Bang, Jungyun Kim

Sejong general hospital, Bucheon, Korea, Republic of

Background: Congenital coronary artery fistula (CAF) is a rare congenital anomalous connection between the coronary arteries and a cardiac chamber or great vessel. Transcatheter closure of symptomatic CAF has become an alternative to surgical closure but limited data are available in the pediatric population. This study sought to assess clinical and angiographic outcomes in a series of 8 children who underwent successful transcatheter closure of CAF

Method: We retrospectively reviewed medical records of all patients with CAF who underwent transcatheter closure between 2006 and 2019 in infant and children in single heart center. Patients with other complex cardiac lesions and those requiring surgery were excluded.

Results: Eight children (6 girls), with median age 1.77 of years [0.18-8.5] and weighing 10.7 of kg [5.17-24.8] with CAF underwent 9 transcatheter closure procedures without significant complication. Coronary artery fistula arose from the right (n=7) and left (n=2) coronary artery and single coronary artery (n=1). Drainage sight was to the superior vena cave or right atrium or right ventricle, left ventricle. The mean Qp/Qs was 1.54 ± 0.28 and all patients showed dilated left ventricle chamber. Transcatheter closure of the fistula was carried out using an Amplatzer vascular plug II (AVP II) in 7 patients and 1 patient who failed coil embolization 7 years prior using the retrograde approach rather than anterograde. Anterograde approach was performed in 2 patients and retrograde approach was performed in 6 patients. Successful closure occurred immediately in all patients with no residual flow 6 (75%) and with trivial flow in 2 (25%). A follow-up angiogram was obtained in 7 patients with median time from closure of 1.18 years. Five patients (71%) had prominent regression of proximal dilated coronary artery before fistula. Anti-platelet agent was maintained in 4 and anti-coagulant agent in 3. One patient was taking antiplatelet and anticoagulant agent before follow-up angiography. All patients were alive and doing well with normal resting ECGs and normal both ventricular function on echocardiography with no significant complication after a median follow up of 3.32 years.

Conclusion: Transcatheter closure appears to be safe and effective treatment for congenital coronary artery fistula in

pediatric population. AVP II is considered the good treatment of option, especially in isolated large CAF in children.

175. PULMONARY VALVE SPARING REPAIR OF TETRALOGY OF FALLOT USING INTRAOPERATIVE BALLOON VALVULOPLASTY: EXPERIENCE IN A SINGLE CARDIAC INSTITUTE

Su-Jin Park, Seong-Ho Kim, So-ick Jang, kyoung Yoon, Eun-Young Choi, Ji-Seok Bang, Chang Ha Lee

Sejong Hospital, Bucheon, Korea, Republic of

Balloon pulmonary valvuloplasty has been the treatment of choice in patients with pulmonary valve (PV) stenosis. During the inflation of the balloon, valve dilation occurs in a static position, and the transmission of the radial force causes splitting of the fused or incomplete leaflet commissures along with dilation and stretching of the valve annulus. In Tetralogy of Fallot (ToF) patients, right ventricular outflow tract (RVOT) transannular patch technique still remains the most frequent approach, followed by a transatrial approach. However, whenever the use of TAP is necessary, progressive PV regurgitation will develop, leading to right ventricular dilation and dysfunction, and eventually leading to impaired functional capacity. To minimize these detrimental prognosis, surgeons have developed different techniques to preserve the PV during the initial total correction stage. Since the year of 2013, our cardiac team has adapted the technique to use an intra-operative PV balloon dilatation (IBPV) during TA TOF repair in selected group of patients with milder forms of pulmonary stenosis (PS), consisting of PV annulus Z score between -2~-4. The purpose of this study was to evaluate the short and mid-term results of these patients, treated in a single cardiac institute.

Result: From January of 2013 to April of 2019, total of 12 patients underwent IBPV (Male:Female=6:6). The median age was 4.5 months (2 months to 10 months), the median weight was 6.2 kg (5.0 to 9.6 kg), the median PV annulus size was 6.4mm (5.0 to 9.2mm), median z value of PV was -2.7 (-2.0 to -3.9), and the size of balloon used was 6 to 10mm. Echocardiographic data showed mild pulmonary regurgitation in all 12 patients and moderate PS in 3 patients, and mild PS in 8 patients. One patient underwent percutaneous pulmonary valvuloplasty and there was 1 mortality unrelated to the procedure (adrenal insufficiency).

Conclusion: The use of balloon angioplasty during TA TOF repair in selected group of patients is a feasible option of treatment. However, meticulous repair of the valve morphology after ballooning by the surgeon is mandatory and the selection of the appropriate balloon size is the key to

the success of this procedure. Further study in larger population and longer follow up period to determine the strategic approach for this group of patients is warranted.

176. LONG-TERM OUTCOMES AND REINTERVENTIONS AFTER PULMONARY ARTERY STENT IMPLANTATION IN INFANTS AND SMALL CHILDREN (LESS THAN 12 KG)

Stephen Nageotte¹, Patrick Sullivan², Sagar Pathak³, Howaida El-Said¹, John Moore¹, Frank Ing⁴

¹Rady Children's Hospital, San Diego, USA. ²Children's Hospital Los Angeles, Los Angeles, USA. ³UCSD, San Diego, USA. ⁴UC Davis Children's Hospital, Davis, USA

Background: Use of stents to treat branch pulmonary artery (BPA) stenosis is the standard of care. However, long-term outcomes data after BPA stenting in infants and small children are scarce.

Methods: Pts ≤ 12 kg who underwent PA stenting at a single institution 10/1997-6/2006 were included in a retrospective review.

Results: 64 pts were initially identified, however, 8 were lost to follow-up after initial catheterization. The remaining 56 pts with a mean weight and age of 8.1 ± 2.4 kg and 13.2 ± 8.4 months respectively underwent implantation of 74 stents, with 18 pts undergoing bilateral stenting. 12 stents were placed intraoperatively. Table 1 summarizes the initial pre and post and final cath data at mean follow-up duration of 10.2yrs. Patients on average gained 25.1kg over 8.1yrs and minimum stented diameters increased from 3.2 to 10.2mm.

Stents underwent a median of 2 reinterventions (range 0-6). Median times to 1st, 2nd, and 3rd reinterventions were 1.6yrs (n=68; IQR: 0.6-3.2yrs), 2.4yrs (n=44; IQR: 0.8-4.9yrs), and 2.8yrs (n=23; IQR: 1.3-5.3yrs). There were 2 major complications at initial intervention: vessel tear during an intraoperative deployment requiring patch repair (1) and entrapment of a dilator tip in a stent (used in a novel front-loading technique) requiring surgical removal at the time of RV-PA conduit replacement. No major complications occurred at reintervention. 18 vessels were re-stented at a follow-up catheterization due to adjacent stenosis. In

176. Table 1.

	Weight (kg)	Age (years)	Minimal BPA diameter (mm)	BPA diameter z-score	BPA pressure gradient (mmHg)*	RV/SBP (%)*
Initial Catheterization-pre stent measurements	8.1 \pm 2.4	1.1 \pm 0.7	3.2 \pm 1.3	-3.3 \pm 1.1	33 \pm 15	71 \pm 19
post measurements			7.2 \pm 1.6	0.3 \pm 1.1	10 \pm 10	52 \pm 16
Final Cath** (mean FU: 10.2 \pm 6.8yrs)	33.2 \pm 21	9.2 \pm 5.5	10.2 \pm 2.3	-0.3 \pm 1.1	10 \pm 8	50 \pm 20

* Patients with 2-ventricle physiology (N=46)

** N=74 stents

176. Table 2.

	Weight (kg)	Age (years)	Minimal BPA diameter (mm)	BPA diameter z-score	BPA pressure gradient (mmHg)*	RV/SBP (%)*
Initial Catheterization-initial measurements	8.6 \pm 2.0	1.2 \pm 0.6	3.4 \pm 1.1	-3.1 \pm 1.0	33 \pm 14	75 \pm 19
Initial Catheterization-final measurements			7.4 \pm 1.3	0.3 \pm 0.9	11 \pm 11	50 \pm 11
Final Cath** (mean FU duration: 12.7 yrs)	47.3 \pm 16	13.9 \pm 3.0	11.3 \pm 1.9	-0.6 \pm 0.9	11.8 \pm 7	46 \pm 11

* Patients with 2-ventricle physiology (N=18)

** N=37 stents

total, there were 152 reinterventions on these 74 stents. 75 were for somatic growth, 40 for intimal buildup, 19 for adjacent stenosis, and 5 for stent fracture. 12 of the stents were surgically removed at the time of required additional cardiac surgery.

Table 2 summarizes the sub-group of patients with a follow-up duration of ≥ 12 years (27 pts and 37 stents). Patients on average gained 38.7kg over 12.7yrs and minimum stented diameters increased from 3.4 to 11.3mm. Stented vessel gradient and RV/SBP remain low over this timeframe.

Conclusion: Stents can effectively relieve PA stenosis in infants and small children. Furthermore, serial stent expansion and additional stenting to accommodate somatic growth can be performed safely and effectively to maintain good hemodynamic and anatomic results from infancy to late adolescence and adulthood.

177. CATHETER STENT IMPLANTATION IN CLOSE PROXIMITY TO THE ORIFICES OF PULMONARY VEIN IN FONTAN PATIENT

Kenji Baba, Maiko Kondo, Yoshihiko Kurita, Takahiro Eitoku, Yuuki Imai, Yosuke Fukushima, Yusuke Shigemitsu, Kenta Hirai, Shin-ichi Ohtsuki

Okayama University Hospital, Department of Pediatric Cardiology, Okayama, Japan

Background: Pulmonary vein stenosis in Fontan patients is still a quite challenging disease. We present a patient with Fontan physiology who underwent catheter stent implantation in close proximity to the orifices of pulmonary veins.

Case: A five-years-old boy with hypoplastic left heart syndrome underwent staged palliation for Fontan physiology. He underwent Norwood-Sano procedure on 7 days after birth, bidirectional Glenn at age of 5 months, surgical left pulmonary vein stenosis release at age of 8 months, and Fontan operation and re-operation for left pulmonary vein stenosis at age of 3 years and 9 months. As acute heart failure occurred due to spontaneous fenestration closure on day 12 after Fontan operation, stent implantation (Express LD 7x17mm) for fenestration was performed. After fenestration stent deployment, his systemic oxygen saturation decreased to 60% despite receiving a FiO₂ of 1.0 and nitric oxide, so the fenestration size adjustment using stent-in-stent and a detachable coil was required. The technique of fenestration size adjustment was that Express SD 5x19mm was deployed inside the previous Express LD 7x17mm and detachable coil (IMWCE-6.5 PDA3) was positioned as an anchor between Express SD 5x19mm stent and Express LD 7x17mm stent. After the fenestration size adjustment,

his systemic oxygen saturation increased to 78% receiving FiO₂ 0.5. Fourteen months later after Fontan operation, he suffered from left lower lobe pneumonia which was resistant to antibiotics therapy. After balloon angioplasty for left lower and upper pulmonary vein were performed, he recovered from pneumonia. One month later after balloon angioplasty for pulmonary vein stenosis, catheter stent implantation for left lower pulmonary vein was planned. The orifice of left lower pulmonary vein was very close to that of the left upper pulmonary vein. After the left upper pulmonary vein flow was checked by transthoracic echocardiography under balloon inflation at left lower pulmonary vein, an Express SD, 6mm diameter and 18mm length stent was deployed at left lower pulmonary vein using 6French guiding catheter. After the stent deployment, the pressure gradient between left lower pulmonary vein and single atrium disappeared from 3 mmHg and the pressure gradient between left upper pulmonary vein and single atrium remained 2 mmHg without change. Ten months later after stent implantation for left lower pulmonary vein, the pressure gradient between left upper pulmonary vein and single atrium increased to 6 mmHg. An Express LD, 8mm diameter and 17mm length stent was deployed at left upper pulmonary vein using 6 French long sheath during balloon inflation at left lower pulmonary vein in order not to interfere the previous stent. After the procedure, the pressure gradient between left upper pulmonary vein and single atrium dropped to 2mmHg.

178. BIOABSORBABLE EVEROLIMUS-ELUTING STENT EXPERIENCE IN NEWBORNS AND INFANTS WITH CONGENITAL HEART DISEASE – CLINICAL APPLICATION AND PHARMACOKINETICS

Kyong-Jin Lee, Atsuko Kato, Lee Benson, Winnie Seto, Rajiv Chaturvedi

Hospital for Sick Children, Toronto, Canada

Background: There remains a role for small diameter stents in the management of blood vessels associated with congenital heart disease. Shortcomings of current stents have been the limited future expansion capabilities and in-stent stenosis.

The ABSORB stent (Abbott Vascular, Santa Clara, CA) is a bioabsorbable (PDLLA) everolimus-eluting coronary stent which disappears over 2 years with potential to restore the regular functions of the blood vessel wall. Furthermore, even prior to complete disappearance, these stents may be amenable to circumferential unzipping and earlier intervention.

Methods: This is a retrospective review of infants and children who underwent implantation of the bioabsorbable everolimus-eluting stents (Absorb) and everolimus pharmacokinetics.

Results: During the period between September 2016 and October 2017, 17 Absorb stents were implanted into 15 blood vessels of 13 patients. The median patient age and weight were 180 (17, 511) days and 6.0 (2.9, 12.2) kg respectively. Stented blood vessels were left pulmonary artery (n=7), lower left pulmonary artery (n=3), right pulmonary artery (n=1) and pulmonary vein (n=6). All stents were 3.5 mm nominal diameter inflated to 4.0 mm. Six (40%) of the blood vessels had ineffective balloon dilations prior to stent implantation. There were no procedural complications.

Peak serum everolimus level was 21.2 ng/mL at 1 hour. All patients were within or below therapeutic range at 24 hours and were all below therapeutic level by 5 days (n=11). No patient experienced adverse events related to the everolimus drug.

Thirteen (87%) stented vessels required and were successfully treated – balloon dilation alone (n=10), balloon dilation with additional stent implantation (n=1), additional stent (n=2) at a median interval of 96 (9, 356) days. Indications for intervention were progressive vessel narrowing in n=20 (80%) and need for further vessel enlargement in 5 vessels.

Conclusions: Bioabsorbable everolimus-eluting stents provided effective and safe improvement of severely stenotic blood vessels. The re-intervention rate was high but anticipated. Stented blood vessels were amenable to re-intervention prior to complete resorption.

179. THE MED-ZENITH PT-VALVE™FOR SEVERE PULMONARY REGURGITATION

John Cheatham¹, NianGuo Dong², Shu Chen², XiaoKe Shang², Qingliang Zhou², Sharon Cheatham¹, Jian Meng²

¹Nationwide Children's Hospital, Columbus, USA. ²Beijing Med-Zenith Medical Scientific Co, Beijing, China

In China, there are ~15,000 open-heart surgeries/yr for TOF, leaving most patients with life-long significant PR. Transcatheter pulmonary valve (TPV) therapy in 2000 did not initially address this problem. Designing TPV for severe PR is much more challenging and was 1st reported ~ 10 years ago. However, there have been few and slow advancements in the US, with more rapid progress in Asia in this therapy.

We are reporting the initial results of the Med-Zenith PT-Valve™for severe PR in China. The frame design is a unique, symmetric shape comprised of laser-cut nitinol covered with porcine pericardium, and a porcine pericardial valve sewn inside. Three anchors at the proximal frame for attachment to the delivery system allows easy loading, delivery, and controlled-release of the valve. Currently, there are 3 valve sizes (20, 23, and 26mm) and 5 frame dimensions (TPV2820, 3223, 3626, 4026, and 4426), with 2 additional larger frames with a 29mm valve being developed (TPV4829 and 5229). The current delivery profile is 21Fr, with a 24Fr profile required for the 2 new valves.

After bench testing, animal implants were performed in the US and in China followed by a Clinical Protocol submitted to the CFDA for 100 patients in 5-6 sites. Prior to the Clinical Trial, there have been 14 implants in China. Below are the preliminary results in these patients.

Patient Demographics, Valves Implanted, & Implant Sites:

AGE: 24-56y/o; WEIGHT: 42-75Kg; GENDER: M-10, F-4; VALVE SIZE: TPV4426-7, 3626-3, 4026-2, 3223-1, 2820-1; IMPLANT SITES: Wuhan-9, Anzhen-2, & 1 implant at 3 other sites.

Results: 14/14 successful implants. Post Implant: no significant PR/paravalve leak 14/14. No SAE. Longest follow up 1year.

Conclusions: 1) Early results of the Med-Zenith PT-Valve™for severe PR are promising. 2) An experienced proctor was available for the 1st case, but the other 13 implants were performed without an experienced proctor present...demonstrating ease of use. 3) The largest available PT-Valve was used in 7/14 cases, however 2 larger valve sizes are being developed. 4) Plans are to begin the Clinical Trial in China in 2019.

180. FEASIBILITY OF AIRWAY SEGMENTATION FROM THREE DIMENSIONAL ROTATIONAL ANGIOGRAPHY

Sebastian Goreczny^{1,2}, Alexander Haak^{3,4}, Gareth Morgan^{2,3}, Jenny Zablah²

¹Polish Mother's Memorial Hospital, Research Institute, Lodz, Poland. ²Children's Hospital Colorado, Aurora, Colorado, USA.

³University of Colorado Hospital, Aurora, Colorado, USA. ⁴Philips Healthcare, Andover, Massachusetts, USA

Background: Modern imaging platforms allow not only visualization of the three dimensional (3D) structure of the vascular anatomy, but also present the spatial relation of vascular segments to non-vascular structures such as

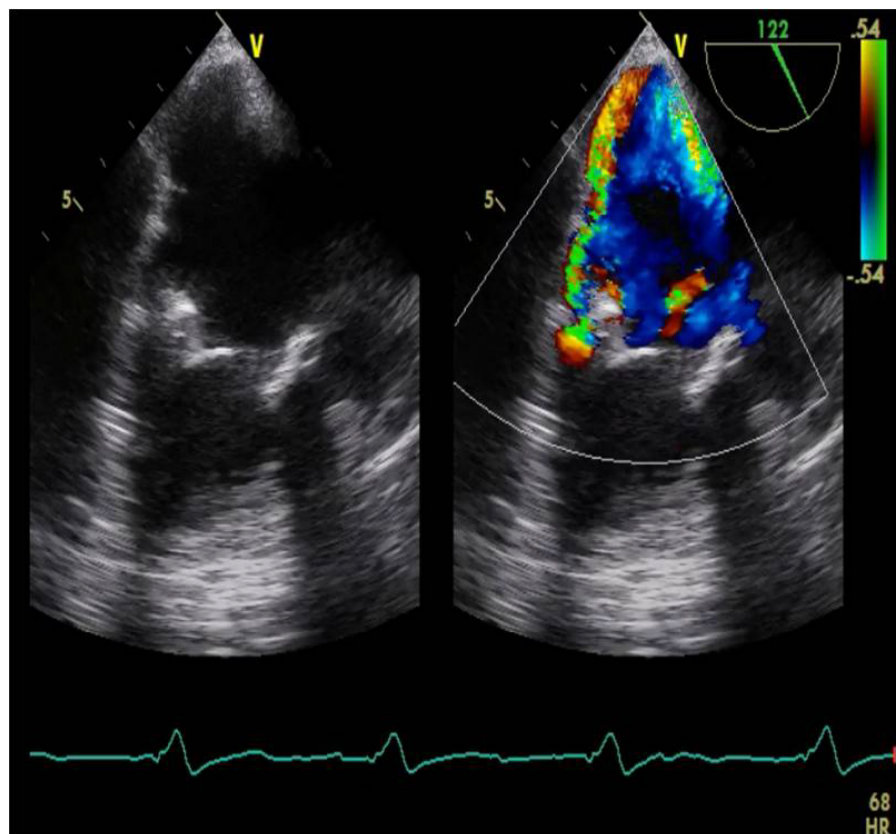
airways. In several congenital lesions like the left pulmonary artery stenosis in hypoplastic left heart syndrome, information about vessel-airway relation may potentially impact treatment strategy. Outside the interventional cardiology space, tools have been developed to visualize (segment) non-contrast regions in 3D rotational angiography (3DRA) such as biopsy or ablation targets.

Objectives: We investigated the feasibility of segmenting the airway from 3DRAs using commercially available tools.

Methods: A retrospective review of our institutional database was performed to identify all patients who underwent 3DRA with a new angiographic platform capable of airway segmentation (Philips Azurion, since 12/2018). Patients demographics and catheterization data were collected. Three-dimensional rotational angiographies including pulmonary arteries and airways were selected for further analysis. A segmentation tool (XperGuide, Philips Healthcare) allowing for a stepwise 3D segmentation of structures with a low contrast ratio and irregular boundaries was used to present airway-vessel (pulmonary artery) relation. Three independent operators performed airway segmentation

from blinded 3DRAs. Segmentation time and completeness of segmented airway were recorded for all 3D datasets.

Results: Between 12/2018 and 4/2019, 3DRA was performed in 42 patients including 23 patients in whom pulmonary arteries were visualized. In the latter group the mean patient age and weight were 3.7 years (range: 1 month – 17 years) and 16.7 kg (3.9 – 85 kg), respectively. Seventeen patients presented with biventricular anatomy, the remaining 6 were single ventricle patients at various stages of palliation. Airway segmentation was performed successfully in 21 patients (21/23, 91.3%). In one patient the isocenter was set to anteriorly resulting in only partial inclusion of the airway in the 3D volume. In another patient artifacts from multiple previously implanted coils did not allow accurate visualization of the airways for segmentation. The median time for segmentation was 2:27 min (range 0:49 – 3:49 min) with no significant differences between the three operators ($p=9$). Trachea was segmented in all patients (21), the left and right main bronchus in 21 (100%) and 20 (95%) patients, respectively. Proximal right and left lobar bronchi were segmented in 17 (81%) and 11 (52%) patients, respectively.



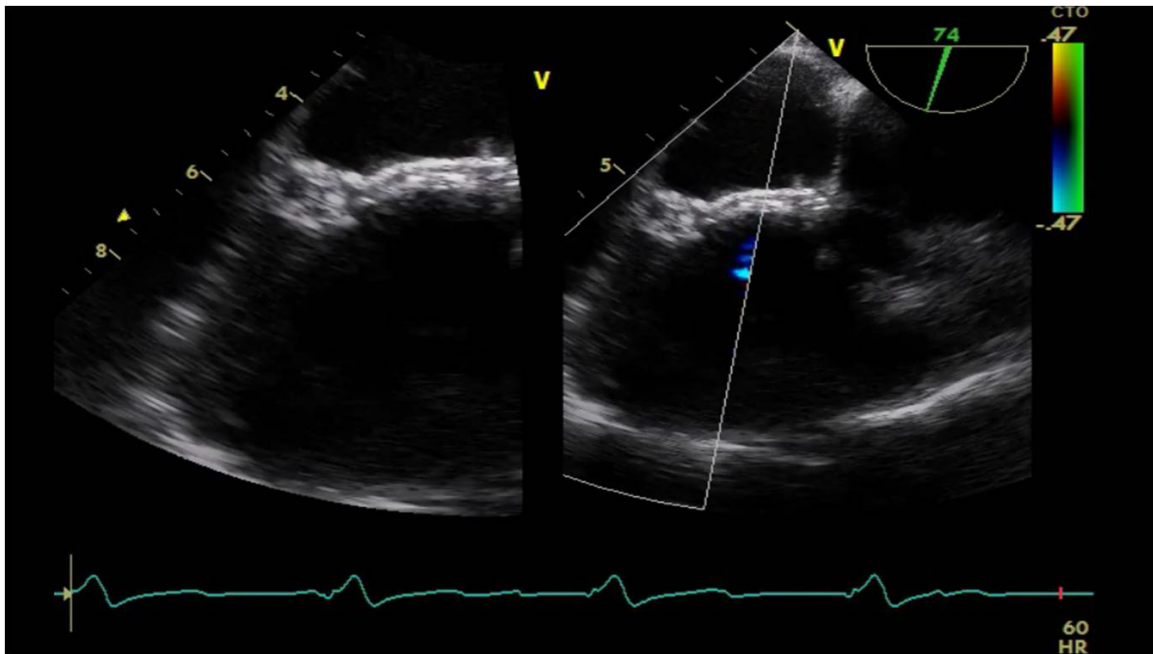
181. Figure 1.

Conclusions: This study shows feasibility of rapid airway segmentation from 3DRA. In the majority of patients segmentation of proximal airway was possible with decreasing percentage for the more distal airway branches. Further studies are warranted to explore clinical benefits of this technique of airway segmentation.

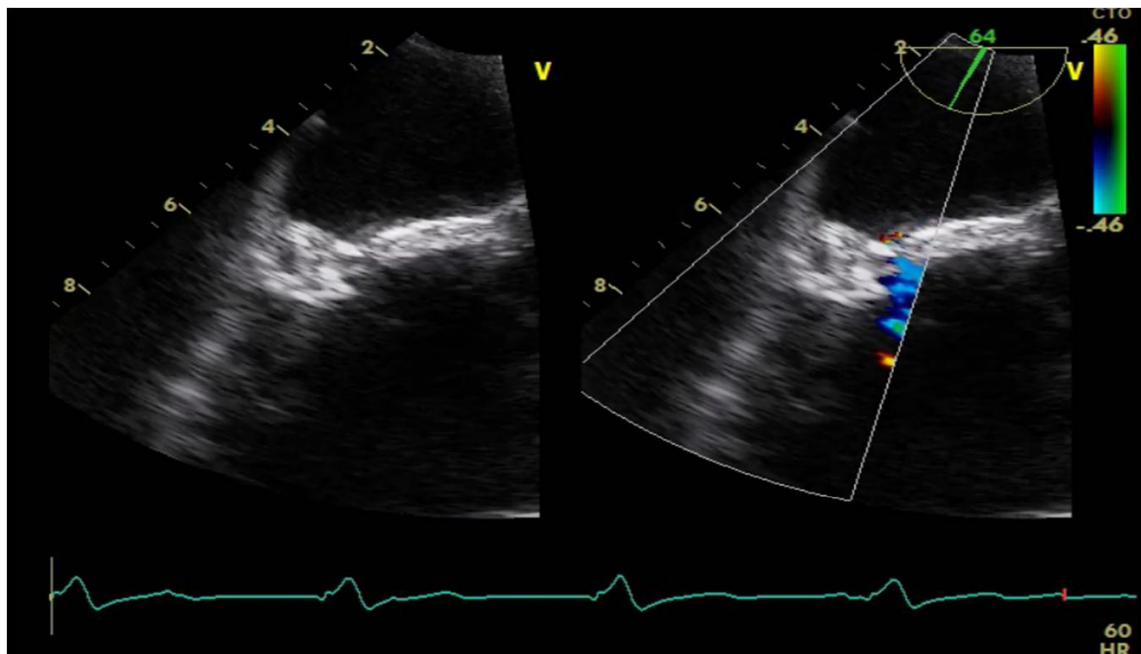
181. LEAK CLOSURE FOR SEVERE VALVULAR BIOLOGICAL PROSTHESIS WITH DEVICE IN PATIENT WITH EBSTEIN'S DISEASE

Donovan Espriu¹, Marco Solorzano²

¹Centro Medico del Bajío IMSS T1, Leon, Mexico. ²Instituto Nacional de Cardiología Ignacio Chavez, Ciudad de Mexico, Mexico



181. Figure 2.



181. Figure 3.

Introduction: The Ebstein anomaly covers less than 1% of cardiac malformations. The common feature of all cases is apical displacement and dysplasia of the septal valve of the tricuspid valve. Among the associated anomalies are the permeable foramen ovale or the atrial septal defect. 50% Interventricular communication or mitral valve disease.

Summary: This is a 42-year-old female patient with a significant history of diagnosis of Ebstein's Disease from the time of birth in treatment with furosemide, spironolactone and rivaroxaban. Biological valve replacement in tricuspid position Edwards Lifesciences 31 He began his condition 4 months after continuous biological valve replacement with presence of dyspnea of medium efforts with the presence of murmurs on auscultation. Physical examination revealed heart murmurs with murmur at the level of the tricuspid focus holisistolico IV / VI of Levine, which increases to the Rivero carballo maneuver without s3 s4 normal rest. With studies Hemoglobin 14.3 g / dl, Platelets 206,000 / ul Leukocytes 7.030ul Creatinine 0.5 mg / dl, Potassium 3.8 mmol / l Total bilirubin 0.7 mg / dl. Transthoracic echocardiogram biological prosthesis in tricuspid dysfunctional position, leakage for severe valvular at the level of lateral and posterior ring (Figure 1). Therefore it was decided to use a leak closure using a device during your stay without complications (Figures 2 & 3) with decreased paravalvular leak in ecocardiograma of control.

Justification: To evaluate the leakage closure for valvular tricuspid in patients with biological prosthesis with few reported cases.

Discussion: Ebstein's disease usually proceeds to the repair of the valve if it can not be replaced, generally by a bioprotetic valve. Valvular replacement has a less satisfactory prognosis. The insufficiency to valvulate after a valvular substitution the morbidity and mortality increases considerably the percutaneous closure with device has been limited in technical questions.

Conclusions: The leak for severe valve in tricuspid valve in Ebstein anomaly is very rare, there are no cases reported in our literature in Mexico, which is an interesting case

182. ACQUIRED TRICUSPID ATRESIA AFTER PULMONARY VALVE PERFORATION IN A CASE WITH PULMONARY ATRESIA – INTACT VENTRICULAR SEPTUM: IS IT A NEW FINDING?

Sonia El-Saiedi, Baher Matta, Al Hussein Sayed
Cairo University, Cairo, Egypt

Introduction: Pulmonary atresia with an intact ventricular septum (PA IVS) is still one of the most difficult congenital cardiac defects to treat. In cases with PA IVS when the heart is still developing in utero, very little blood flows into or out of the right ventricle (RV), thus the RV remains usually under-developed. The collagen matrix of the myocardium is the supportive framework. An increase in collagen in the pressure-overloaded ventricle early in life is known to cause myocardial stiffness.

Case Report: A female neonate 17 days presented to us 3.5 kg and 50 cm in length with echocardiographic diagnosis of pulmonary atresia intact ventricular septum. Severe TR PG > 100mm Hg. The PAs were confluent and supplied by a tortuous PDA. Lt sided aortic arch and a 5 mm non-restrictive PFO. TV annulus 7 mm (Z score -1.9) and MV annulus 14 mm and PA annulus 6 mm. She was scheduled to RF perforation the next day. JR catheter passed easily into the RV. RV pressure was 125/4/14. Injection of the RV showed an underdeveloped RV mostly bipartite as the apical portion did not fill properly. RF perforation was done using the Nykanen wire followed by ballooning of the PV using Tayshak II balloon 7mmx2cm then 9mmx2 cm. The decision to stent the PDA was taken and we used coronary stent 4mmx 14mm. The patient was extubated and transferred to CICU in a stable condition with saturation in the eighties.

In ICU patient was kept on primacore 0.5 mg/kg but the patient rapidly start to have desaturation again falling to sixties. Echocardiography the next day showed no forward flow through neither the tricuspid valve nor the pulmonary and the RV looked very hypoplastic compared to the ECHO the day before?!

The one explanation to this phenomenon was that the RV when decompressed shrunk and passed into total stunning and stiffness and the tricuspid valve leaflets stuck in its closed phase.

The patient remained hospitalized in CICU for 2 weeks receiving Milrinone. By the end of the second week the saturation started to rise to seventies. Re-echo showed the tricuspid valve allowing 1 mm flow across it. The patient was discharged and asked to come back after 2 weeks. When back the saturation had increased to eighties and the tricuspid valve showed more flow across it 3 mm and a subtle movement of the leaflets.

Two months later the saturation is still increasing and the tricuspid movement is getting better.

The idea of reporting the case is to show how the RV in cases of pulmonary atresia can be very stiff and non-compliant especially after suddenly decompressing it. The sudden drop of pressure can force the RV to pass into standstill phase with the tricuspid valve leaflets in its closed systolic position. Given time the RV can gradually recover but will never be totally normal.

This is the first case in the literature to document this amazing phenomenon.

183. VALVE SPARING STENTING OF THE RIGHT VENTRICULAR OUTFLOW TRACT IN FALLOTS: IS IT WORTH THE EFFORT?

Rizwan Rehman¹, Chetan Mehta², Vinay Bhole², Milind Chaudhari², Rami Dhillon², John Stickle², Oliver Stumper²

¹Birmingham Womens and Children's Hospital, Birmingham, United Kingdom. ²Birmingham Womens and Childrens Hospital, Birmingham, United Kingdom

Introduction: Stenting of the right ventricular outflow tract (RVOT) is a safe and effective technique in the initial palliation of selected patients with Fallot type lesions. Stenting of the RVOT increases pulsatile forward flow of systemic venous blood to the pulmonary arteries. This results in a greater rise in systemic oxygen saturations and promotes better pulmonary arterial growth compared to BT Shunt palliation.

Objective: We hypothesized that infants and neonates with a valve sparing RVOT stenting would alter surgical strategy and outcomes. Conceptually, not crossing the PV should have many advantages: potential for the pulmonary valve to grow, avoidance of free regurgitation and likelihood of later repair without trans-annular patch. Our objectives were to look for any true benefits of valve sparing RVOT stenting as per our hypothesis.

Methods: Retrospective, non-randomized, single centre review of patients with Tetralogy of Fallot and its variants, who underwent RVOT stenting followed by complete repair between 2010-2018. Pulmonary valve growth was assessed by serial echocardiography. We collected all data including surgical techniques.

Results: 64 patients were studied. Stents were placed crossing the valve in 29 patients (45%) and sparing the valve in 35 patients (54%). The median weight at the time of stent implantation in the valve sparing group was 3.76 kg with the smallest patient being 1.72 kg. There was a significant growth of the PV annulus (z score - 4.02 at the time of stent and - 2.95 at pre-surgical assessment in the valve

sparing group).[p < 0.01 ; two tailed t-test]. There were 2 procedure related deaths, 1 in each group.

Valve preserving Fallot repair was achieved in 4 cases (11%) of cases after valve sparing stent. There was no difference in the rate of trans-annular repair between the 2 groups. There was a lower need for conduit repair in the valve sparing stent group. (26 % vs 41%) [p < 0.03]

Conclusions: Initial palliation of Fallot with stenting the RVOT compares favourably to other forms of surgical palliation to augment pulmonary blood flow. Stenting the RVOT in Fallot lesions without crossing the pulmonary valve promotes growth of the PV annulus and thereby has potential for facilitating valve sparing corrective surgery at a later stage. This approach should be favoured in cases with hypoplastic pulmonary arteries, anomalous coronary arteries or those with associated cardiac lesions or syndromes.

184. ATRIAL SEPTAL STENTING- OUTCOMES FORM A SINGLE CENTRE.

Chetan Mehta¹, Vinay Bhole², Milind Chaudhari³, Rami Dhillon¹, Oliver Stumper¹

¹Birmingham Womens and Childrens Hospital, Birmingham, United Kingdom. ²Birmingham Womens and Children's Hospital, Birmingham, United Kingdom. ³Birmingham Women's and Children's Hospital, Birmingham, United Kingdom

Background: Atrial septal stenting provides a reliable access to Left Atrium for repeated pulmonary venous interventions. An unrestricted atrial communication is essential in maintaining adequate physiology in palliation of uni-ventricular hearts.

Aim: To review our experience of Atrial Septal stenting and its outcomes.

Methods: Retrospective review of case records of all children, who had Atrial Septal stenting procedure.

Results: Over a period from 2008 to 2018, we found 22 patients who had an attempt at Atrial Septal stenting. Percutaneous Atrial Septal stenting was attempted in 20 patients and 2 had Hybrid intervention for Hypoplastic Left Heart syndrome (HLHS) with intact atrial septum. There were 3 patients with biventricular circulation and rest were single ventricular circulation with details in Table below.

	Hybrid/PAB/ Damus	Post Glenn	Post Fontan
Hypoplastic Left Heart Syndrome	N=2, (2.5 and 2.9kg)	N=5, (Median wt 10.6)	N=1 (16.7 kg)
DILV	N=1, (4.35kg) No previous Interventions	N=1, (9.8 kg) Post Surgery for palliation	N=1, (15.8kg)
Univentricular miscellaneous	N=1, (2.1kg)	N=6 (Median wt 5.375kg)	

There were 18 patients who had successful implantation, with 1 procedure related death in a baby who had 2 failed attempts. 1 another patient died during the study period unrelated to the procedure. All stents were patent on last follow up or till the next surgical palliation. There was no re-intervention for dilation of the stent.

Conclusion: Atrial septal stenting is reliable to provide patent atrial communication. It can achieve good haemodynamic result in restrictive atrial communication at all stages of univentricular palliation.

185. REHABILITATION OF CONGENITALLY DISCONNECTED OR NON-CONFLUENT PULMONARY ARTERIES - ROLE OF DIAGNOSTIC AND INTERVENTIONAL CARDIAC CATHETERISATION

Chetan Mehta, Sarvanan Durairaj, John Stickley, David Barron, Oliver Stumper

Birmingham Womens and Childrens Hospital, Birmingham, United Kingdom

Background: Congenital disconnected or non-confluent pulmonary artery (CDPA) is a rare condition which can be associated with other congenital heart disease. With current technological advances in cross sectional imaging of CT/MRI scan, the role of cardiac catheter is limited. We looked at the role of Cardiac Catheter in diagnosis and rehabilitation of CDPA.

Aim: To identify the role of diagnostic/interventional cardiac catheterization in rehabilitation of congenitally disconnected non-confluent branch pulmonary artery (CDPA). We studied the pattern of presentation, diagnostic modalities and outcomes including death.

Methods: Retrospective review of all children with CDPA between 1989 and 2017 at a single centre. The data was collected from our local database and clinical notes review.

We included all non-confluent branch pulmonary arteries with or without alternate lung supply and excluded acquired disconnection of pulmonary arteries.

Results: We identified 50 patients with CDPA. 85% of our population presented during infancy (age range from 4 days to 17years). The majority of CDPA were associated with Cono-truncal abnormalities (Tetralogy Of Fallot 13, Truncus arteriosus 9, PA/VSD/MAPCAs 9, Absent Pumonary Valve syndrome 2 and Interrupted Aortic arch 1). 5 cases were heterotaxy syndromes with 2 RAI and 3 LAI. 5 children had isolated CDPA with normal heart and 6 were in the miscellaneous group. The supply to the disconnected segments was from ductus arteriosus in 22 patients. Median age of patients at first intervention was 10 months (1 to 254 months). Commonest confirmatory diagnostic modality was cardiac catheterization in 35 patients with pulmonary vein wedge injections to confirm presence of disconnected pulmonary artery. 12 patients had intervention with stent to maintain patency of the disconnected pulmonary artery with 8 of them requiring recanalisation of the occluded ductal tissue prior to stenting. Mean number of procedures post initial treatment was 5.1 (range 1-9) in our series. One patient had unsuccessful recruitment. Status at last review was satisfactory in 45 patients doing well clinically, 1 with pulmonary hypertension, 1 remains cyanotic. 8 patients had associated genetic syndrome. Mortality in this series was three patients (6%).

Conclusion: Our experience suggests recruitment of CDPA is feasible and safe procedure with good outcomes. Most patients are likely to need initial palliation with cardiac catheterization and intervention before recruitment and full repair. The disconnected pulmonary artery is likely to need multiple interventions.

186. CARDIAC EROSIONS AFTER TRANSCATHETER ATRIAL SEPTAL DEFECT CLOSURE WITH THE OCCLUTECH FIGULLA FLEX DEVICE

Alain Fraisse¹, Johanne Auriou², Helene Bouvaist², Lars Aaberge³, Tadaaki Abe⁴, Ingo Dahnert⁵, Joseph Panzer⁶, Giuseppe Santoro⁷, Markus Khalil⁸, Ziyad M. Hijazi⁹

¹Royal Brompton Hospital, London, United Kingdom. ²University Grenoble Alpes, Grenoble, France. ³Oslo University, Oslo, Norway. ⁴Nigata City General Hospital, Niigata City, Japan. ⁵Leipzig Heart Center, Leipzig, Germany. ⁶Ghent University, Ghent, Belgium. ⁷University Naples, Massa, Italy. ⁸University Giessen, Geissen, Germany. ⁹Sidra Medicine, Doha, Qatar

Background and Method: Cardiac erosion after transcatheter closure of secundum atrial septal defect is a rare complication that is mainly reported with the Amplatzer

Septal Occluder. We report the first series of 7 cases of cardiac erosions occurring with the Occlutech Figulla Flex Occluder. The cases were retrospectively collected until February 2018.

Results: Median age was 8(4 to 38) year-old. There were 5 females and 5 subjects were less than 18-year-old. Three patients had aortic rim deficiency. One device was oversized. The mean time interval between device implantation and erosion was 36 ± 46.3 days. Four patients (57%) developed clinical symptoms within four days after the procedure whereas 3(43%) presented late, at 49, 78 and 116 days after the implantation. Six patients presented with pericardial effusion necessitating drainage whereas one patient was asymptomatic, diagnosed during follow-up. They all underwent urgent surgery with device removal and repair of the erosion. Intraoperative examination revealed that the erosion was located at the left (n=3) or right (n=1) atrium roof, whereas 3 were between the aorta and the right atrium. There were no deaths and no postoperative complications. Based on the estimation of more than 60000 implanted devices at the time of data collection, the rate of erosion with the Figulla Flex Occluder seems very low as compared to previously published data on other devices.

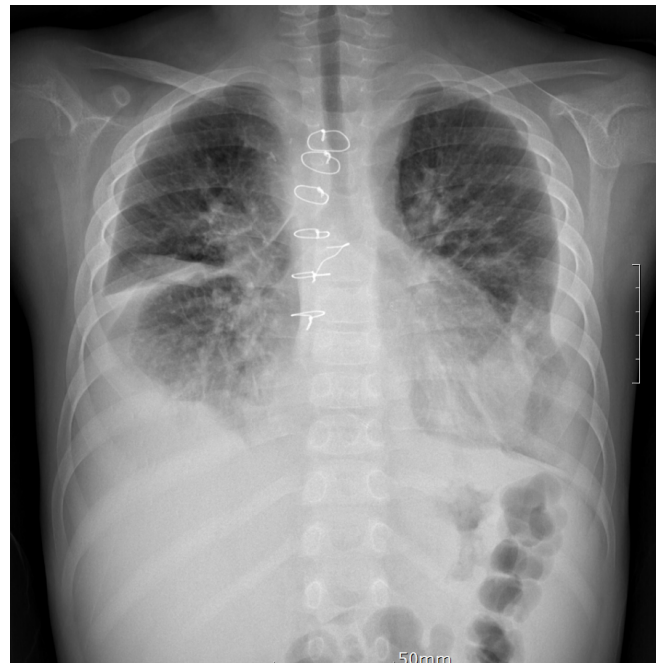Conclusion: Similar to other devices, cardiac erosion occurs with the Figulla Flex Occluder. We recommend regular short and long-term follow-up after percutaneous ASD closure with all devices to better clarify cardiac erosion rates and to identify high risk patients.

187. A CASE OF CREATION OF A TRANSCATHETER FENESTRATION IN FONTAN FAILURE WITH CHRONIC PLEURAL EFFUSION ASSOCIATED WITH HIGH ALTITUDE

Ju Ae Shin, Kyung Min Kim, Ji Hong Yoon, Jae Young Lee
Catholic University of Korea, Seoul, Korea, Democratic People's Republic of

Failed fontan circulation in single ventricle presented with low cardiac output, plastic bronchitis, protein-losing enteropathy, and recurrent pleural effusions. High altitude was known as a risk factor for fontan failure. We report the case of creation of a transcatheter fenestration in 9-years-old child who had chronic recurrent both pleural effusion due to failing fontan circulation associated with high altitude. He was diagnosed double-outlet right ventricle with remote ventricular septal defect in Ulaanbaatar, Mongolia at an altitude of 1350 meters. He was initially palliated with bilateral bidirectional Glenn shunt at 4-years-old in India, and underwent extracardiac

conduit Fontan operation (non-fenestration) in 7-years-old in Seoul St. Mary's Hospital, Korea. After returning to Mongolia, he had exertional dyspnea, facial edema, and cyanosis with chronic recurrent both pleural effusion for 2 years. Successful Fontan fenestration with stent implantation was performed in our institution. At 1-year follow-up, his symptoms of pleural effusion improved significantly. This case may help clinicians stratify patients at risk of fontan failure in advance and improve outcomes in these critically-ill patients.



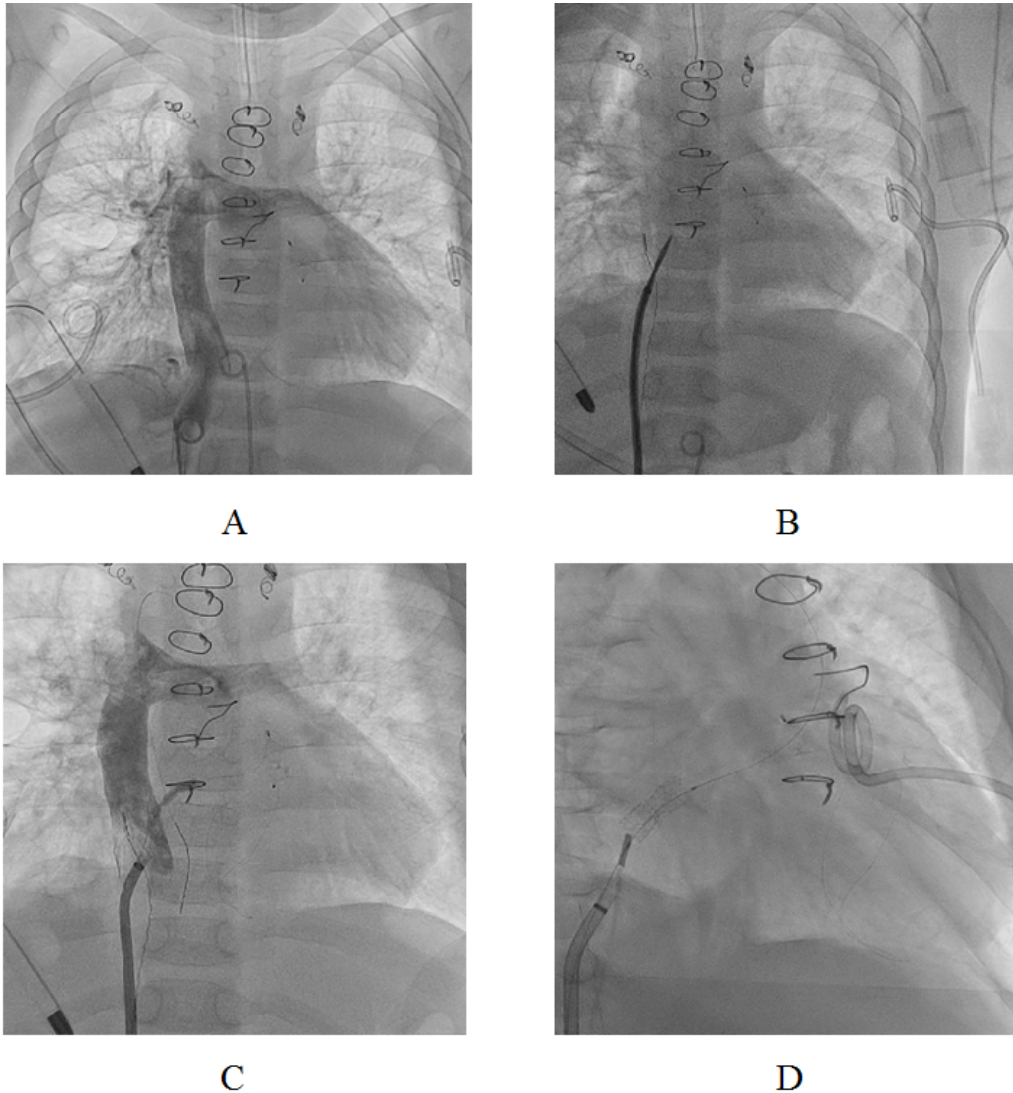
187. Figure 1. Frontal view of the chest radiograph shows both pleural effusions.

188. IMPACT OF CALPAIN-9 ON INTIMAL HYPERPLASIA IN HUMAN PULMONARY VEIN STENOSIS

Takahiro Inoue^{1,2}, Hiroshi Matsushita^{1,2}, Enoch Yeung¹, Sara Abdollahi¹, James Beckett¹, John Coulson¹, Harry Dietz¹, Narutoshi Hibino^{1,2,3}

¹Johns Hopkins, Baltimore, USA. ²University of Chicago, Chicago, USA. ³Advocate Children's Hospital, Chicago, USA

Objectives: Severe progressive pulmonary vein (PV) stenosis remains very difficult to manage with limited treatments. Several growth factors, including VEGF, PDGF and TGF- β 1, are involved in PV stenosis. However, increased knowledge of the downstream signaling cascades is needed to develop effective clinical interventions. Calpain provides an interesting candidate therapeutic target, since it is activated by EGF, PDGF and TGF- β 1. We have also



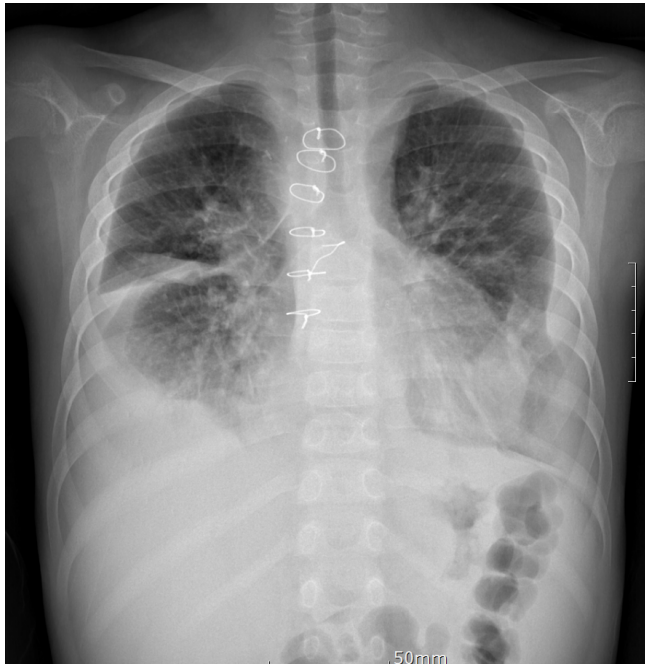
187. Figure 2. Panel A. Angiography of the inferior vena cava and Fontan tunnel. Panel B. After perforation of the conduit and atrial wall, the needle position within the atrial cavity is verified angiographically. Panel C. Exact placement of the stent within the septum is guided by angiograms obtained. Panel D. The desired configuration of the stent is achieved by slowly filling the balloon with diluted contrast medium. This allows expansion of the stent from both ends and results in a diabolo shape of the stent.

discovered that calpain-9 is associated with cell proliferation and fibrosis. In this study, we examined the role of calpain-9 in PV stenosis.

Methods: Non-stenosis (Ns-PV) and stenosis PV with vascular stents (S-PV) were harvested from a patient with congenital PV stenosis. H&E, Masson-Trichrome and calpain-9 staining were performed to measure intimal thickness and the number of calpain-9 positive cells. Furthermore, we examined the role of calpain-9 in neointimal hyperplasia using a mouse wire injury model.

Results: Intimal thickness of human PV was significantly greater in S-PV than Ns-PV (470.0 ± 123.6 vs $128.8 \pm 40.2 \mu\text{m}$, $P < 0.01$). The number of calpain-9 positive cells tended to be higher in S-PV than Ns-PV (16.6 ± 6.2 vs $13.7 \pm 4.5/\text{HPF}$, $P = 0.09$). In a mouse model, the number of calpain-9 positive cells were significantly higher in wire injury group with significant intimal hyperplasia formation compared to the control group (45.9 ± 10.9 vs $16.7 \pm 5.9/\text{intima}$, $P < 0.01$).

Conclusions: Calpain-9 is likely to be associated with intimal hyperplasia in human PV stenosis. Further study using



187. Figure 3. Frontal view of the chest radiograph shows improving of both pleural effusions after transcatheter fontan fenestration with stent implantation.

a mouse wire injury model will be able to identify the detail effect of calpain-9 on intimal hyperplasia, which could develop a new target for the treatment of PV stenosis.

188. PRELIMINARY ASSESSMENT OF PERCUTANEOUS RADIOFREQUENCY ABLATION BASED INTRA-ATRIAL SHUNT THERAPY IN HEART FAILURE WITH PRESERVED EJECTION FRACTION

Huayiyang Zou

Nanjing Medical University, Nanjing, China

Background: Standard medical or device therapy have limited effects on chronic heart failure with preserved ejection fraction (HFpEF). Increased left atrial pressure is thought to be a key contributor to the symptoms associated with HFpEF, especially during physical activity.

Objective: In this study we aim to evaluate the safety and efficacy of a novel approach for intra-atrial shunting by a percutaneous radiofrequency ablation device.

Methods: The percutaneous radiofrequency ablation based intra-atrial shunt (RFIAS) therapy was firstly tested in 12 domestic pigs under fluoroscopy and intracardiac echocardiography (ICE) guidance. Treatment parameters

were set as the first power of 45 watts for 60 seconds plus second power of 60 watts for 60 seconds. The diameter of the intra-atrial shunt was measured by ICE. The chamber filling pressure along with the oxygen saturation analysis of arterial and mixed venous blood were evaluated with high heart catheterization (RHC). Follow-up were performed at 1, 3, 6 months post-procedure and a gross anatomy examination was carried out after 6-month follow-up. A first-in-man study was then performed after the permission of the ethic committee of the First Affiliated Hospital of Nanjing Medical University. Ten patients with HFpEF were enrolled and receiving one-time RFIAS therapy and 6 months follow-up.

Results: 12 swine (52.3 ± 10.9 kg) received the RFIAS therapy under general anesthesia. Two swine were dead, 1 of which was dead for ventilator malfunction during the procedure and the other was dead for intestinal infection at the fourth month. None of the dead were associated with the procedure and no other major safety event was observed. For the 11 surviving swine, mean diameter of intra-atrial shunt and Qp/Qs post-procedure were 5.5 ± 2.2 mm and 1.2 ± 0.24 , respectively. The closure of intra-atrial shunt was observed in two swine at 3-m and one swine at 6-m follow-up. The remaining swine ($n=8$) showed a mean dimension of 4.1 ± 1.5 mm at 6-month. A subsequent first-in-man study of 10 symptomatic heart failure patients with preserved or mildly reduced ejection fraction, who received RFIAS therapy (mean diameter of 5.3 ± 0.95 mm) with the treatment power of 45w60s+60w60s, showed symptoms of relief with a reduction of NT-proBNP (-1630.1 ± 1346.5 ng/L, $p=0.004$) and an increase of 6-minute walk distance (129.2 ± 98.9 m, $p=0.003$) without major safety events at 6 months follow-up.

Conclusions: Our preclinical and clinical pilot studies suggest that a non-implantable radiofrequency ablation based intra-atrial shunt therapy may provide a new option for HFpEF. A further randomized study is needed to evaluate the long-term efficacy and safety.

Comment on this Article or Ask a Question

Cite this article as: Hijazi ZM. The Pediatric and Adult Interventional Cardiac Symposium (PICS/AICS) 22nd Annual Meeting, San Diego, CA. Structural Heart Disease. 2019;5(4):75-205. DOI: <https://doi.org/10.12945/j.jshd.2019.018.19>